

***Strongyloides stercoralis* hyperinfection associated with impaired intestinal motility disorder**

Cláudia Frangioia Figueira^a, Márcio Teodoro da Costa Gaspar^a,
Lynda Dorene Cos^a, Edson Yassushi Ussami^a, José Pinhata Otoch^{a,b},
Aloisio Felipe-Silva^c

Figueira CF, Gaspar MTC, Cos LD, Ussami EY, Otoch JP, Felipe-Silva A. *Strongyloides stercoralis* hyperinfection associated with impaired intestinal motility disorder. Autopsy Case Rep [Internet]. 2015; 5(2):27-34. <http://dx.doi.org/10.4322/acr.2015.005>

ABSTRACT

Infection by *Strongyloides stercoralis* is a highly prevalent helminthiasis, which is mostly distributed in the tropical and subtropical regions of the world. Although a substantial number of cases are asymptomatic or paucisymptomatic, severe and life-threatening forms of this infection still occur and not infrequently is lately diagnosed. Gram-negative bacteria septicemia, which frequently accompanies the severe helminthiasis, contributes to the high mortality rate. Severe infection is invariably triggered by any imbalance in the host's immunity, favoring the auto-infective cycle, which increases the intraluminal parasite burden enormously. Clinical presentation of severe cases is varied, and diagnosis requires a high suspicion index. Acute abdomen has been reported in association with *S. stercoralis* infection, but intestinal necrosis is rarely found during the surgical approach. The authors report the case of a man who sought the emergency unit with recent onset abdominal pain. Clinical and imaging features were consistent with obstructive acute abdomen. Scattered adhesions and a necrotic ileal segment with a tiny perforation represented the surgical findings. The patient outcome was unfavorable and respiratory distress required an open lung biopsy. Both surgical specimens showed *S. stercoralis* infection. Unfortunately the patient underwent multiple organ failure and septicemia, and subsequently died. The authors call attention to the finding of intestinal necrosis and impaired intestinal motility disorder as possibilities for the diagnosis and risk factor, respectively, for a severe infection of *S. stercoralis*.

Keywords

Strongyloidiasis; *Strongyloides stercoralis*; Intestinal Diseases; Parasitic

INTRODUCTION

Intestinal strongyloidiasis still represents a marked cause of overwhelming helminthiasis in the tropical and subtropical regions, which is strongly associated with poor sanitation and hygiene. It is estimated that

100 million people are infected in these regions; among them, 50% are asymptomatic.¹ However, when the equilibrium (maintained by the immune system) between the host and the parasite is impaired,

^a Surgical Division - Hospital Universitário - Universidade de São Paulo, São Paulo/SP – Brazil.

^b Department of Surgery - Faculdade de Medicina - Universidade de São Paulo, São Paulo/SP – Brazil.

^c Anatomy Pathology Service - Hospital Universitário - Universidade de São Paulo, São Paulo/SP – Brazil.



life-threatening infection ensues.¹⁻³ This frequently severe complication may happen up to 40 years from the time the infection was first acquired.⁴

Quite often, the diagnosis of strongyloidiasis is somewhat challenging or unnoticed due to some particularities of the worm’s biological cycle and the non-negligible number of the aforementioned symptomless cases.^{5,6} Although the infection occurs through the penetration of the infective filariform larvae into the skin, auto-infection does occur after the transformation of non-infective rhabditiform larvae into filariform inside the intestine, which invade the colonic mucosa or perianal skin (a process enhanced by corticosteroids). Therefore, in contrast to other nematodes species, the *Strongyloides stercoralis* may maintain its biological cycle without leaving the host.

The auto-infection phenomenon may explain the persistence of infection for a long time (even when the host is out of the endemic area) and the high-burden infections in the immunocompromised hosts.^{2,3,7} In this setting, hyperinfection syndrome comprises an increase in parasite burden due to acceleration of the auto-infection cycle restricted to the sites of the biological cycle; whereas the disseminated strongyloidiasis consists in a systemic spread of filariform larvae to sites outside their normal migration pattern. The hyperinfection is usually accompanied by Gram-negative septicemia somehow facilitated by the infective filariform larvae through the intestinal mucosa.^{8,9}

CASE REPORT

A 52-year-old Caucasian male sought the emergency facility complaining of a 1-week history of abdominal pain and distension followed by vomiting. His past medical history included hypertension, previous ischemic stroke, and a laparotomy for trauma 15 years ago. He denied tobacco smoking but drank alcoholic beverages.

Physical examination on admission revealed an afebrile, ill-looking patient, with tachypnea and tachycardia. Blood pressure was 100/60 mmHg and body mass index was 29. Pulmonary and cardiac examination was normal, but the abdomen was distended, with rebound tenderness. Bowel sounds were present and hypodynamic. The initial laboratory work-up is shown in Table 1.

The abdominal radiograph showed air-filled dilated bowel loops with fluid levels consistent with the diagnosis of small bowel obstruction. No sign of pneumoperitoneum was evidenced.

Facing the clinical features, laboratory results, and imaging data, the diagnosis of obstructive acute abdomen was made. Considering the previous laparotomy, abdominal adhesion was the main suspected etiology. The patient underwent an exploratory laparotomy that – besides multiple adhesions of the omentum to the visceral peritoneum, and adhesions between duodenal loops – showed a necrotic jejunal area measuring 25 cm at its longest axis with a tiny perforation (Figure 1) 20 cm from the Treitz angle. The adhesions were manually released and

Table 1. Initial laboratory work-up

Exam	Result	RV	Exam	Result	RV
Hemoglobin	16.3	12.3–15.3 g/dL	Potassium	3.7	3.5–5.0 mEq/L
Hematocrit	47.8	36.0–45.0%	Sodium	140	136–146 mEq/L
Leukocytes	11.540	4.4–11.3 × 10 ³ /mm ³	Urea	134	5–25 mg/dL
Segmented	47	45–70%	Creatinine	1.41	0.4–1.3 mg/dL
Eosinophil	0	1–4%	CRP	170	< 5 mg/L
Basophil	0		Lactate	15.3	4.5–19.8 mg/dL
Lymphocyte	8	18–40%	Anti-HIV	negative	
Monocytes	17	2–9%			
Platelets	339	150–400 × 10 ³ /mm ³			

CRP = C-reactive protein. RV = reference value.

the necrotic jejunal segment was resected followed by enteroanastomosis.

The post-operative follow-up was troublesome. Although the patient was prescribed a broad-spectrum antimicrobial regimen, he presented respiratory failure with disseminated rales and wheezing on the very first postoperative day, which required corticotherapy (hydrocortisone 100 mg/daily) and mechanical ventilatory support. The thoracic computed tomography (CT) showed cystic bronchiectasis in the upper right lobe, confluent cavitation centrilobular nodules, and ground glass opacity (Figures 2 and 3).

The bronchoscopy showed a huge amount of purulent secretion in both lungs, edematous and hyperemic respiratory tree mucosa. Bronchoalveolar lavage was undertaken, and the acid-fast bacilli research was negative, unfortunately *S. stercoralis* larvae was not researched because the lack of clinical suspicion. An open lung biopsy was performed; the histologic examination revealed diffuse alveolar damage with focal chronic inflammatory process

characterized by eosinophil aggregates and epithelioid granulomas, and the presence of parasites consistent with filariform larvae of *S. stercoralis* (Figure 4). Acid-fast bacilli research by Ziehl-Neelsen staining was negative.

In the meantime, the histologic examination of the resected necrotic jejunal segment showed chronic inflammatory infiltration in the intestinal wall with marked eosinophilia, granulomas through the intestinal wall and serosa, rare giant multinucleated cells, with focal necrosis and ulceration and venous thrombosis, besides the presence of structures consistent with *S. stercoralis* (Figure 5). Perforation was focal, probably related to parasite migration, with concurrent serositis.

Although the patient was treated with ivermectin, albendazol, and a broad-spectrum antibiotic regimen, the outcome was unfavorable with multiple organ failure. He died on the thirty-second day of hospitalization.

DISCUSSION

Although half of the cases of *S. stercoralis* remain asymptomatic for a long time, mild or moderate gastrointestinal symptoms represent the majority of symptomatic cases. However, severe and life-threatening infection does occur and should always be included in the differential diagnosis of acute abdomen in the endemic areas. These cases occur when the auto-infective cycle takes place and the intraluminal burden of parasites increases. In this setting, hyperinfection syndrome or disseminated disease may occur, which is often accompanied by

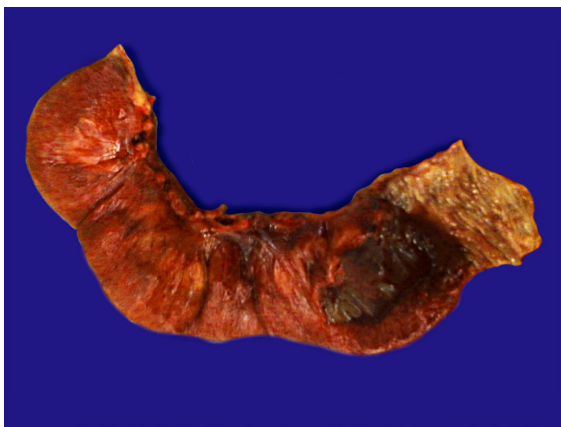


Figure 1. Gross view of the resected jejunal loop showing the transmurular hemorrhagic necrosis.

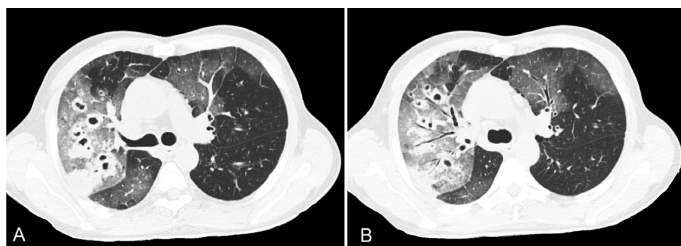


Figure 2. Chest axial CT. **A** and **B** – Large ground glass opacities involving both lungs, air bronchograms, and multiple large nodules in the right lung and smaller in the left lung. Some of the nodules in the right lung are cavitated.

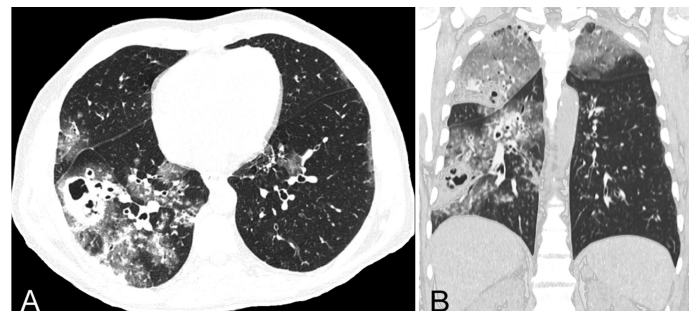


Figure 3. Chest CT. **A** – Axial plane showing multiple bilateral scattered nodules, ground glass opacity, and cavitation in the lower right lobe. **B** – Scattered bilateral nodules, ground glass opacities in both upper pulmonary lobes, and cavitation in the inferior right lobe.

intestinal-bacteria septicemia. Respiratory symptoms also occur during the auto-infective cycle and may be represented by pneumonia or asthma-like features.¹⁰

All these severe cases are invariably associated with a clear cause of immunosuppression, namely: corticotherapy^{5,6} and/or chemotherapeutic agents,^{1,11} chronic immunodeficiency,¹² chronic renal failure,¹³ diabetes mellitus,¹⁴ burns,^{11,13} gut motility-impairing disorder,¹⁵ malnutrition,^{11,13} alcoholism,¹¹ hypochloridria,¹⁶ malignancies,^{11,17} leprosy,¹³ post transplantation,¹⁸ and HTLV-1 infection.¹⁹ HIV infection also constitutes a risk factor for severe strongyloidiasis, but contrary to what one might expect, there are few case reports on this association.²⁰⁻²²

Clinically, these severe forms of infection may be preceded by diarrhea, steatorrhea,⁴ and weight loss, which may be of indolent or of subtle onset.

Hematemesis, partial small bowel obstruction,²³⁻²⁵ and adynamic ileus,²⁶ have also been reported, but necrosis of the intestinal wall is rarely described. In 2006, Giavina-Bianchi et al.⁸ reported a case of hemorrhagic necrosis of the intestinal muscular layer in an immunodeficient patient, and prior to that, in 1975, Ali-Khan and Seemayer²⁷ had reported a case with necrosis of the small bowel and right colon due to obliterative arteritis secondary to *S. stercoralis* infection. In 2001, Rodrigues et al.⁹ described the case of an obstructive acute abdomen caused by a narrowed ileal segment in an old man taking corticosteroids for osteoarthritis who, despite surgical treatment, died because of Gram-negative septicemia. In our case report, the surgical finding was a necrotic segment of ileal loop with a tiny perforation, probably related to parasite migration and causing serositis. Adhesions did exist and a suspicion of internal hernia was

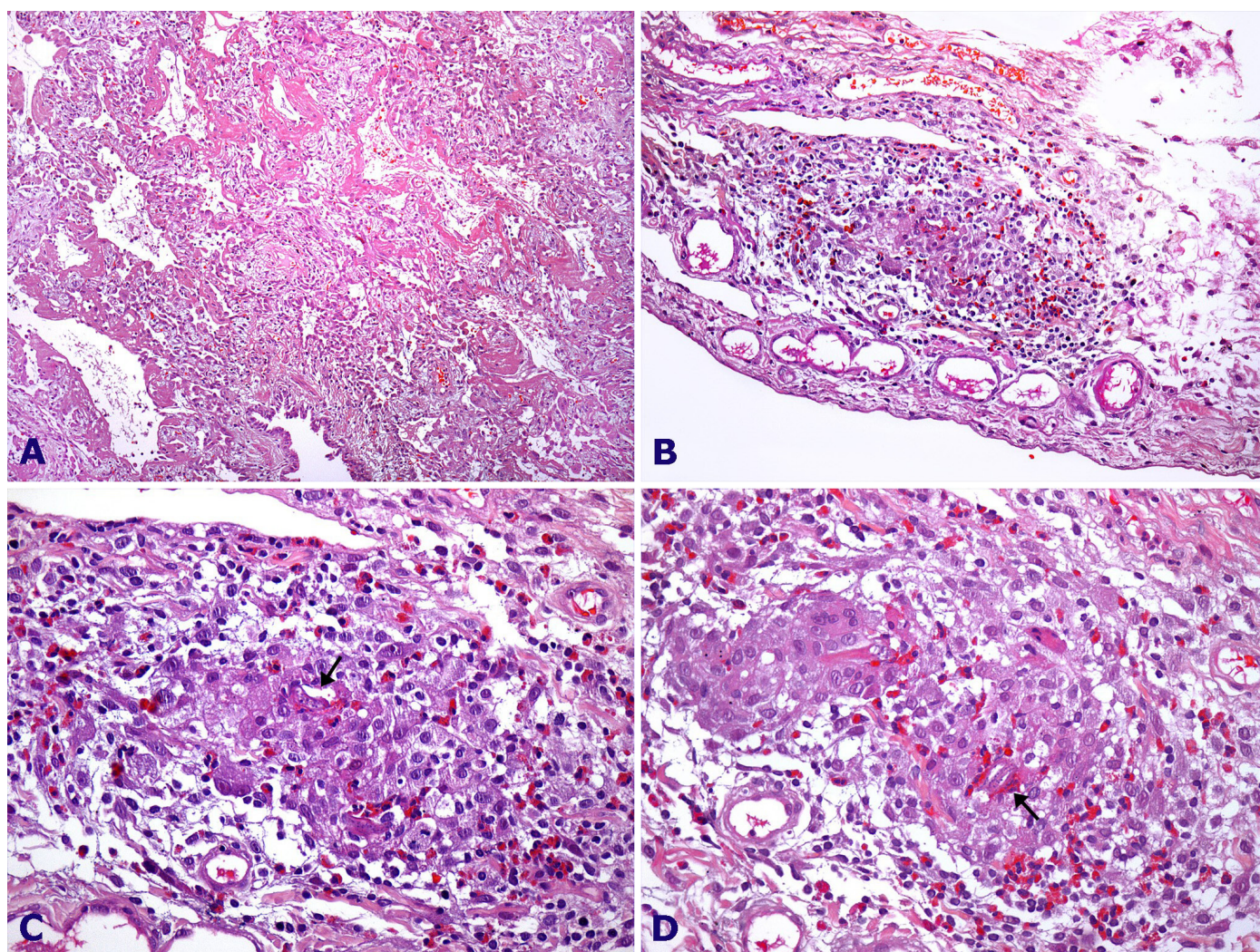


Figure 4. Photomicrography of the lung showing in **A** – diffuse alveolar damage (100x). **B** – Subpleural well-formed granuloma (200x) and in **C** and **D** well-formed granulomas with eosinophils and *S. stercoralis* larvae (arrows) (400x).

also suspected during surgery, and could justify the intestinal vascular suffering. However, we dare to consider that the intestinal necrosis due to the internal hernia was corroborated by the *S. stercoralis* infection as well. The presence of adhesions and the subtle impaired intestinal motility derangement could explain a prone situation for the development of the parasite's auto-infective cycle. In 1996, Gutierrez et al.,²⁸ described six cases of *Strongyloides stercoralis* eosinophilic granulomatous enterocolitis, which presents similar histological findings found in this case report. However in our case diarrhea did not take part of the clinical features neither the colonic involvement was present. Moreover in our case the pulmonary involvement was outstanding, a different feature of the

cases described by Gutierrez. Indeed, the histological findings of *Strongyloides stercoralis* hyperinfection in non immunocompromised patients are represented by intestinal wall (small intestine and colon) penetration of the filariform larvae accompanied by inflammatory response that varies from mild to marked infiltration of lymphocytes, plasma cells, histiocytes, neutrophils and giant cells. Intestinal obstruction caused by paralytic ileus or mechanical obstruction is well known complications of *Strongyloides stercoralis* hyperinfection.

Respiratory complaints are present in up to 68% of cases of hyperinfection syndrome and are represented by bronchitis, asthma, bronchopneumonia, and adult respiratory distress syndrome.^{11,23,29} Pulmonary

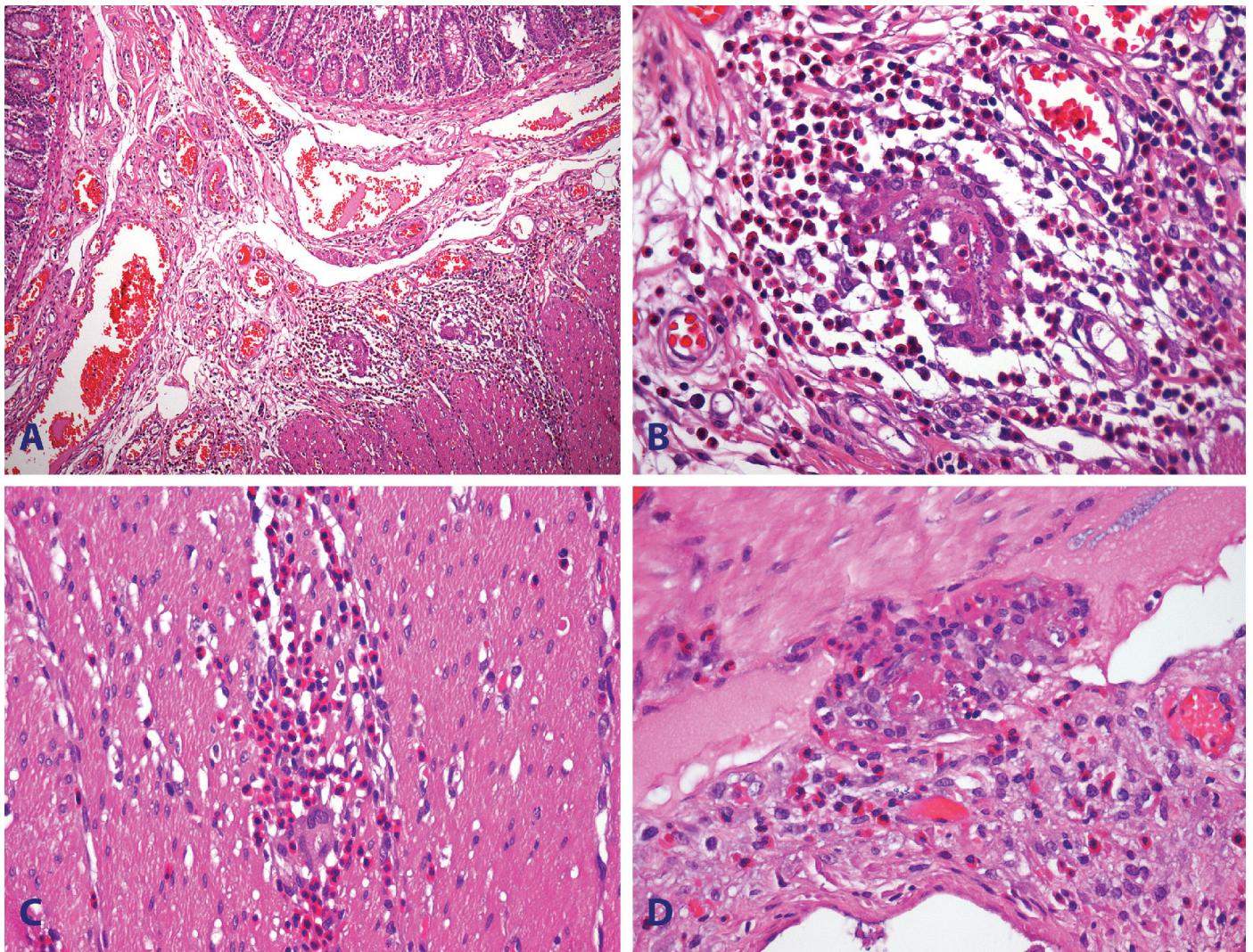


Figure 5. Photomicrography of the jejunum showing in **A** – chronic inflammatory infiltration with eosinophils and congestion in submucosa (100x); **B** – detail of penetrating filariform larva of *S. stercoralis* surrounded by eosinophils (400x). **C** – Eosinophilic infiltration of muscular layer with a giant cell (400x), and **D** – Serosal granuloma with focal central necrosis and transversal section of larvae. Serosa is inflamed (400x).

imaging studies may reveal the presence of fine miliary nodules, interstitial infiltrates, pleural effusion, and lung cavitation (secondary to bacteria septicemia). Our patient presented respiratory symptoms, and the pulmonary CT findings were typical.

The high index of suspicion is of paramount importance for the diagnosis of severe strongyloidiasis. Unfortunately, the severe cases are not accompanied by eosinophilia, which, indeed, may be normal or decreased, in some cases due to corticotherapy. In these cases, serologic tests are not as useful as they are in asymptomatic cases where eosinophilia is present. Therefore, diagnosis of strongyloidiasis is based on the finding of larvae in the stools, sputum, bronchial, gastric or duodenal aspirates, or gastric and/or duodenal or pulmonary biopsy.

Regardless of the type of infection, every patient diagnosed with *S. stercoralis* should be treated to prevent severe forms of the disease. Currently, the treatment of choice is made with ivermectin,³⁰ although thiabendazol has been used for years with the cure ratio of 67–91%.³¹

Interestingly, the patient presented herein did not present any known cause of immunosuppression, but he presented abdominal adhesions and an internal hernia suspicion, which could favor the development of the severe infective form of *S. stercoralis*. A corticosteroid was used during the patient's respiratory failure, which most probably was due to the worm pulmonary cycle and the Gram-negative bronchopneumonic foci.³²

Our patient presented a recent history of symptoms consistent with acute obstructive abdomen diagnosis, which became more evident with the imaging studies. Abdominal adhesion was the preoperative diagnosis, since he'd had a previous laparotomy. The diagnosis of strongyloidiasis was made only with the histological examination. We can only consider this case as a *S. stercoralis* hyperinfection since the parasite was not found in any other site outside its biological cycle.

The diagnosis of severe forms of *S. stercoralis* infection is challenging and therefore a high level of suspicion is required. Imaging studies are non-specific and eosinophilia is an exceptional finding. In our case, the 6% of eosinophils in the initial blood cell count was helpless.

Quite often, incidental diagnoses through surgical specimens are done.³³ In our case it was a surprise

when in both surgical specimens *S. stercoralis* was the causative agent.

The treatment of choice for *S. stercoralis* infection is ivermectin 20 mcg/kg for 2 or 3 days and may be repeated after 14 days, and this should always be prescribed when, for any reason, the immune system is jeopardized, since disseminated strongyloidiasis has a mortality rate of 85–100%.^{7,34}

Some investigators advocate the use of ivermectin combined with albendazol, but this concept requires more controlled studies. Other routes of administration, rather than the oral one, may be used for these drugs.³⁵

REFERENCES

1. Concha R, Harrington W Jr, Rogers AI. Intestinal strongyloidiasis: recognition, management, and determinants of outcome. *J Clin Gastroenterol*. 2005;39(3):203-11. <http://dx.doi.org/10.1097/01.mcg.0000152779.68900.33>. PMID:15718861.
2. Benincasa CC, Azevedo FO, Canabarro MS, et al. [Strongyloides Stercoralis hyperinfection syndrome: case report]. *Rev Bras Ter Intensiva*. 2007;19(1):128-31. <http://dx.doi.org/10.1590/S0103-507X2007000100018>. PMID:25310671.
3. Puthiyakunnon S, Boddu S, Li Y, et al. Strongyloidiasis: an insight into its global prevalence and management. *Plos Neg Trp Dis*. 2014;6:e3018. <http://dx.doi.org/10.1371/journal.pntd.0003018>.
4. Bannon JP, Fater M, Solit R. Intestinal ileus secondary to Strongyloides stercoralis infection: case report and review of the literature. *Am Surg*. 1995;61(4):377-80. PMID:7893110.
5. Sudré AP, Macedo HW, Peralta RHS, Paeralta JM. Diagnóstico da estrogiloidíase humana: importância e técnicas. *Revista de Patologia Tropical*. 2006;35:173-84.
6. Miller A, Smith ML, Judd JA, Speare R. Strongyloides stercoralis: systematic review of barriers to controlling strongyloidiasis for Australian indigenous communities. *PLoS Negl Trop Dis*. 2014;8(9):e3141. <http://dx.doi.org/10.1371/journal.pntd.0003141>. PMID:25254655.
7. Suputtamongkol Y, Premasathian N, Bhumimuang K, et al. Efficacy and safety of single and double doses of ivermectin versus 7-day high dose albendazole for chronic strongyloidiasis. *PLoS Negl Trop Dis*. 2011;5(5):e1044. <http://dx.doi.org/10.1371/journal.pntd.0001044>. PMID:21572981.
8. Giavina-Bianchi P, Silva FS, Toledo-Barros M, Birolini D, Kalil J, Rizzo LV. A rare intestinal manifestation in a patient with common variable immunodeficiency and strongyloidiasis.

- Int Arch Allergy Immunol. 2006;140(3):199-204. <http://dx.doi.org/10.1159/000093205>. PMID:16682801.
9. Rodrigues MAM, Fróes RC, Anefalos A, Kobayasi S. Invasive enteritis by *Strongyloides stercoralis* presenting as acute abdominal distress under corticosteroid therapy. *Rev Hosp Clin Fac Med Sao Paulo*. 2001;56(4):103-6. <http://dx.doi.org/10.1590/S0041-87812001000400002>. PMID:11717716.
 10. Ferreira CM, Barbosa NS, Ferreira WA, et al. Infecção pulmonar por *Strongyloides stercoralis* em paciente tratado com imunossuppressores. *Rev. Patol. Trop*. 2008;37:275-80.
 11. Igra-Siegman Y, Kapila R, Sen P, Kaminski ZC, Louria DB. Syndrome of hyperinfection with *Strongyloides stercoralis*. *Rev Infect Dis*. 1981;3(3):397-407. <http://dx.doi.org/10.1093/clinids/3.3.397>. PMID:7025145.
 12. Shelhamer JH, Neva FA, Finn DR. Persistent strongyloidiasis in an immunodeficient patient. *Am J Trop Med Hyg*. 1982;31(4):746-51. PMID:7102907.
 13. Purtilo DT, Meyers WM, Connor DH. Fatal strongyloidiasis in immunosuppressed patients. *Am J Med*. 1974;56(4):488-93. [http://dx.doi.org/10.1016/0002-9343\(74\)90481-1](http://dx.doi.org/10.1016/0002-9343(74)90481-1). PMID:4818417.
 14. Coovadia YM, Rajput MC, Bhana RH. Disseminated strongyloidiasis in a diabetic patient. *Trop Geogr Med*. 1993;45(4):179-80. PMID:8236470.
 15. Scowden EB, Schaffner W, Stone WJ. Overwhelming strongyloidiasis: an unappreciated opportunistic infection. *Medicine*. 1978;57(6):527-44. <http://dx.doi.org/10.1097/00005792-197811000-00004>. PMID:362122.
 16. Giannella RA, Broitman SA, Zamcheck N. Influence of gastric acidity on bacterial and parasitic enteric infections. A perspective. *Ann Intern Med*. 1973;78(2):271-6. <http://dx.doi.org/10.7326/0003-4819-78-2-271>. PMID:4567180.
 17. Genta RM, Miles P, Fields K. Opportunistic *Strongyloides stercoralis* infection in lymphoma patients. Report of a case and review of the literature. *Cancer*. 1989;63(7):1407-11. [http://dx.doi.org/10.1002/1097-0142\(19890401\)63:7<1407::AID-CNCR2820630729>3.0.CO;2-I](http://dx.doi.org/10.1002/1097-0142(19890401)63:7<1407::AID-CNCR2820630729>3.0.CO;2-I). PMID:2646009.
 18. Morgan JS, Schaffner W, Stone WJ. Opportunistic strongyloidiasis in renal transplant recipients. *Transplantation*. 1986;42(5):518-23. <http://dx.doi.org/10.1097/00007890-198611000-00016>. PMID:3097891.
 19. Gotuzzo E, Terashima A, Alvarez H, et al. *Strongyloides stercoralis* hyperinfection associated with human T cell lymphotropic virus type-1 infection in Peru. *Am J Trop Med Hyg*. 1999;60(1):146-9. PMID:9988339.
 20. Lessnau KD, Can S, Talavera W. Disseminated *Strongyloides stercoralis* in human immunodeficiency virus-infected patients. Treatment failure and a review of the literature. *Chest*. 1993;104(1):119-22. <http://dx.doi.org/10.1378/chest.104.1.119>. PMID:8325052.
 21. Ferreira MS, Nishioka SA, Borges AS, et al. Strongyloidiasis and infection due to human immunodeficiency virus: 25 cases at a Brazilian teaching hospital, including seven cases of hyperinfection syndrome. *Clin Infect Dis*. 1999;28(1):154-5. <http://dx.doi.org/10.1086/517188>. PMID:10028097.
 22. Brandão RM, Brandão RPM, Gonçalves ACMA, Laborda LS, Lima PP, Campos FPF. *Strongyloides stercoralis* disseminated infection and schistosomiasis in an AIDS patient. *Autopsy Case Rep*. 2012;2(4):35-44. <http://dx.doi.org/10.4322/acr.2012.035>.
 23. DeVault GA Jr, King JW, Rohr MS, Landreneau MD, Brown ST 3rd, McDonald JC. Opportunistic infections with *Strongyloides stercoralis* in renal transplantation. *Rev Infect Dis*. 1990;12(4):653-71. <http://dx.doi.org/10.1093/clinids/12.4.653>. PMID:2201067.
 24. al-Bahrani ZR, al-Saleem T, al-Gailani MA. Sub-acute intestinal obstruction by *Strongyloides stercoralis*. *J Infect*. 1995;30(1):47-50. [http://dx.doi.org/10.1016/S0163-4453\(95\)92847-2](http://dx.doi.org/10.1016/S0163-4453(95)92847-2). PMID:7751666.
 25. FriedenberG F, Wongpraparut N, Fischer RA, et al. Duodenal obstruction caused by *Strongyloides stercoralis* enteritis in an HTLV-1-infected host. *Dig Dis Sci*. 1999;44(6):1184-8. <http://dx.doi.org/10.1023/A:1026636509713>. PMID:10389694.
 26. Nonaka D, Takaki K, Tanaka M, et al. Paralytic ileus due to strongyloidiasis: case report and review of the literature. *Am J Trop Med Hyg*. 1998;59(4):535-8. PMID:9790425.
 27. Ali-Khan Z, Seemayer TA. Fatal bowel infarction and sepsis: an unusual complication of systemic strongyloidiasis. *Trans R Soc Trop Med Hyg*. 1975;69(5-6):473-6. [http://dx.doi.org/10.1016/0035-9203\(75\)90101-7](http://dx.doi.org/10.1016/0035-9203(75)90101-7). PMID:1228984.
 28. Gutierrez Y, Bhatia P, Garbadawala ST, Dobson JR, Wallace TM, Carey TE. *Strongyloides stercoralis* eosinophilic granulomatous enterocolitis. *Am J Surg Pathol*. 1996;20(5):603-12. <http://dx.doi.org/10.1097/00000478-199605000-00007>. PMID:8619425.
 29. Sen P, Gil C, Estrellas B, Middleton JR. Corticosteroid-induced asthma: a manifestation of limited hyperinfection syndrome due to *Strongyloides stercoralis*. *South Med J*. 1995;88(9):923-7. <http://dx.doi.org/10.1097/00007611-199509000-00007>. PMID:7660209.
 30. Luvira V, Watthanakulpanich D, Pittisuttithum P. Management of *Strongyloides stercoralis*: a puzzling parasite. *Int Health*. 2014;6(4):273-81. <http://dx.doi.org/10.1093/inthealth/ihu058>. PMID:25173343.
 31. Swanson SJ, Phares CR, Mamo B, Smith KE, Cetron MS, Stauffer WM. Albendazole Therapy and Enteric Parasites.

- in United States—Bound Refugees. *N Engl J Med*. 2012; 366:1498-507.
32. Porto MA, Muniz A, Oliveira J Jr, Carvalho EM. Clinical and immunological consequences of the association between HTLV-1 and strongyloidiasis. *Rev Soc Bras Med Trop*. 2002;35(6):641-9.
33. Gokhale VA, Pillai R, Al-Mammari S, Al-Layla D. Hyperinfection by *Strongyloides stercoralis*. *OMJ*. 2010;25. <http://dx.doi.org/10.50001/omj.2010.47>.
34. Luna B, Grasselli R, Ananias M, et al. Estrongiloidíase disseminada: diagnóstico e tratamento. *Rev Bras Terapia Intensiva*. 2007; 19:463-68.
35. Mejia R, Nutman TB. Screening, prevention, and treatment for hyperinfection syndrome and disseminated infections caused by *Strongyloides stercoralis*. *Curr Opin Infect Dis*. 2012;25(4):458-63. <http://dx.doi.org/10.1097/QCO.0b013e3283551dbd>. PMID:22691685.

Conflict of interest: None

Submitted on: January 12, 2015

Accepted on: March 1, 2015

Correspondence

Marcio Teodoro da Costa Gaspar
Surgery Service Clinica Multiperfil Luanda Angola
Surgery Division Hospital Universitario USP
Hospital Universitário
Av. Professor Lineu Prestes, 2565, São Paulo/SP – Brazil
CEP: 05508-000
Phone: +55 (11) 94836-3866
E-mail: marcio85gaspar@gmail.com