

Peripheral pulmonary artery aneurysm presenting as a solitary pulmonary nodule

Mauro Federico Luis Tamagno^a, Jussara Bianchi Castelli^b,
Benoit Jacques Bibas^a, Helio Minamoto^a

Tamagno MFL, Castelli JB, Bibas BJ, Minamoto H. Peripheral pulmonary artery aneurysm presenting as a solitary pulmonary nodule. *Autopsy Case Rep* [Internet]. 2015; 5(2):49-53. <http://dx.doi.org/10.4322/acr.2015.007>

ABSTRACT

We report the case of a 63-year-old female patient who was evaluated due to a solitary pulmonary nodule. The final diagnosis was a solitary peripheral pulmonary artery saccular aneurysm. The patient was submitted to a pulmonary lobectomy with excellent recovery. Peripheral pulmonary artery aneurysms that arise from segmental or intrapulmonary branches are extremely rare, and their management is still controversial.

Keywords

Solitary Pulmonary Nodule; Aneurysm; Pulmonary Artery.

INTRODUCTION

Pulmonary artery aneurysm (PAA) is rare. It has been associated with congenital cardiac anomalies associated with pulmonary hypertension, pulmonary valve stenosis, Behcet's disease, infection, trauma, and vasculitis.^{1,2} PAAs associated with congenital cardiac lesions are often treated concomitantly with the underlying anomaly.²

In contrast, isolated idiopathic PAA has been thought to be due to an inherent weakness of the arterial wall, known as cystic medial degeneration (CMD), represented by mucoid material deposition sometimes forming the so-called mucoid "lakes." It usually involves the main pulmonary arteries, and the aneurysms can reach immense proportions before the

diagnosis.² The presentation of a PAA as a periphery solitary nodule comprises only a few cases.^{1,3-5} There are no definitive guidelines on the management of this type of aneurysm. We report the case of a 63-year-old female patient who was evaluated due to a solitary pulmonary nodule. The final diagnosis was a solitary peripheral PAA.

CASE REPORT

A 63-year-old woman of Japanese ethnic background was evaluated at the thoracic surgery outpatient clinic due to a round, 2 cm diameter lesion in the right hemithorax, which was found incidentally

^a Thoracic Surgery Department - Heart Institute (InCor) - Hospital das Clínicas - Faculdade de Medicina - Universidade de São Paulo, São Paulo/SP - Brazil.

^b Laboratory of Pathology - Heart Institute (InCor) - Hospital das Clínicas - Faculdade de Medicina - Universidade de São Paulo, São Paulo/SP - Brazil.



on a routine chest radiograph. The patient had a history of controlled hypertension as well as a 40 packs year history of cigarette smoking prior to quitting 4 years earlier. She had no history of chest pain, dyspnea, or cough. All laboratory studies, including serum tumor markers, were within normal limits. A computed tomography (CT) of the chest confirmed the presence of a 2 × 1.6-cm, well-defined, circumscribed, and round right middle lobe nodule in the projection of the pulmonary artery (Figure 1).

Bronchoscopy showed no abnormalities, and cytological brushing was negative for neoplasia. The diagnosis of a solitary peripheral PAA was considered, and surgery was recommended. A right muscle-sparing fifth intercostal space thoracotomy was performed. Examination revealed a 2 cm peripheral, pulsating nodule in the medial segment of the middle lobe. The nodule was soft and had a palpable thrill. No other lung or vascular lesions were identified. After dissection of the oblique and horizontal fissures, the interlobar artery and the main arteries to the middle lobe had a normal appearance. Due to the risk of bleeding, the lesion was not biopsied. A middle lobectomy was performed. The patient had an uneventful recovery and was discharged from the hospital on the fifth post-operative day.

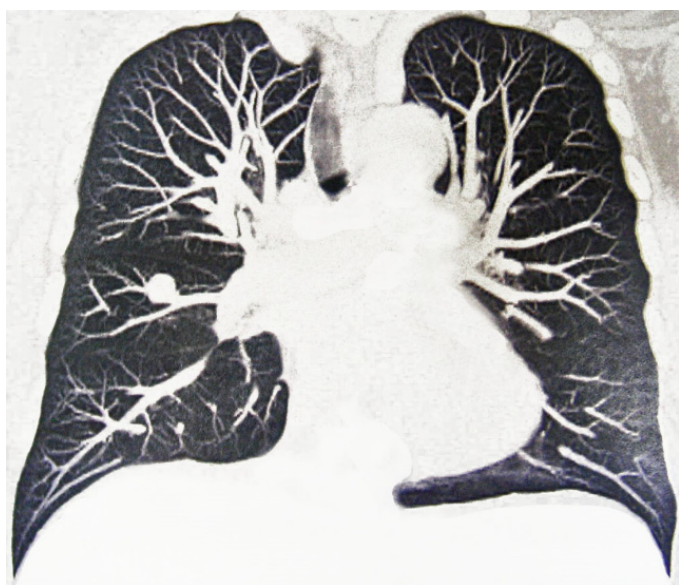

Figure 1. CT of the thorax (coronal reconstruction) suggesting that the pulmonary nodule might be a small PAA.

At gross examination, the pulmonary arteries to the middle lobe were dissected into the intraparenchymal level, and serial sections were performed. It showed an isolated saccular aneurysmal vascular formation at the anterior arterial division close to the pleura, which was filled with blood clots and measured up to 1.6 cm in diameter, with a very thin wall, with only an area of whitish thickening (Figure 2A). The surrounding parenchyma showed no macroscopic peculiarities. At the histology, the vascular defect consisted of severe irregularity of the arterial wall thickness. The aneurysmatic wall portion was very thin, with a decreased number of, and an anomalous distribution of, smooth muscle cells, which are associated with the multiplication of elastic fibers and abundant lacunae of mucoid deposition, which is typical of CMD (Figure 2B, 2C and Figure 3). The thickened region shown in Figures 2 and 3 reveals an aspect of a dysplastic-forming wall with a disruption of the normal structure, which could suggest a congenital anomaly. There was no evidence of previous inflammation (as proliferating or neoformation of the vasa vasorum at the arterial wall) and/or mycotic or thrombotic phenomena related to the described vascular changes.

DISCUSSION

The diagnosis of solitary pulmonary nodule is challenging and includes a list of diseases, which can be summarized as follows: infectious benign lesions (such as tuberculosis, histoplasmosis, blastomycosis); benign tumors (lipoma, hamartoma, fibroma); vascular lesions (congenital or acquired malformations); inflammatory (granulomatosis with polyangiitis, rheumatoid nodules); primary and metastatic malignant tumors; and miscellaneous (infarction, amyloid deposits, intrapulmonary lymph node, hematoma, foreign body, and atelectasis).

The estimated incidence of PAA is 1 in 14,000 autopsies, and these lesions fall into two categories: (1) central aneurysms involving the pulmonary trunk, right or left main pulmonary artery (70%); and (2) peripheral aneurysms that arise from segmental or intrapulmonary branches (30%).⁶ An intrapulmonary solitary aneurysm is the rarest form.^{1,3-5}

The majority of PAAs are seen in patients with structural cardiac defects in which pulmonary

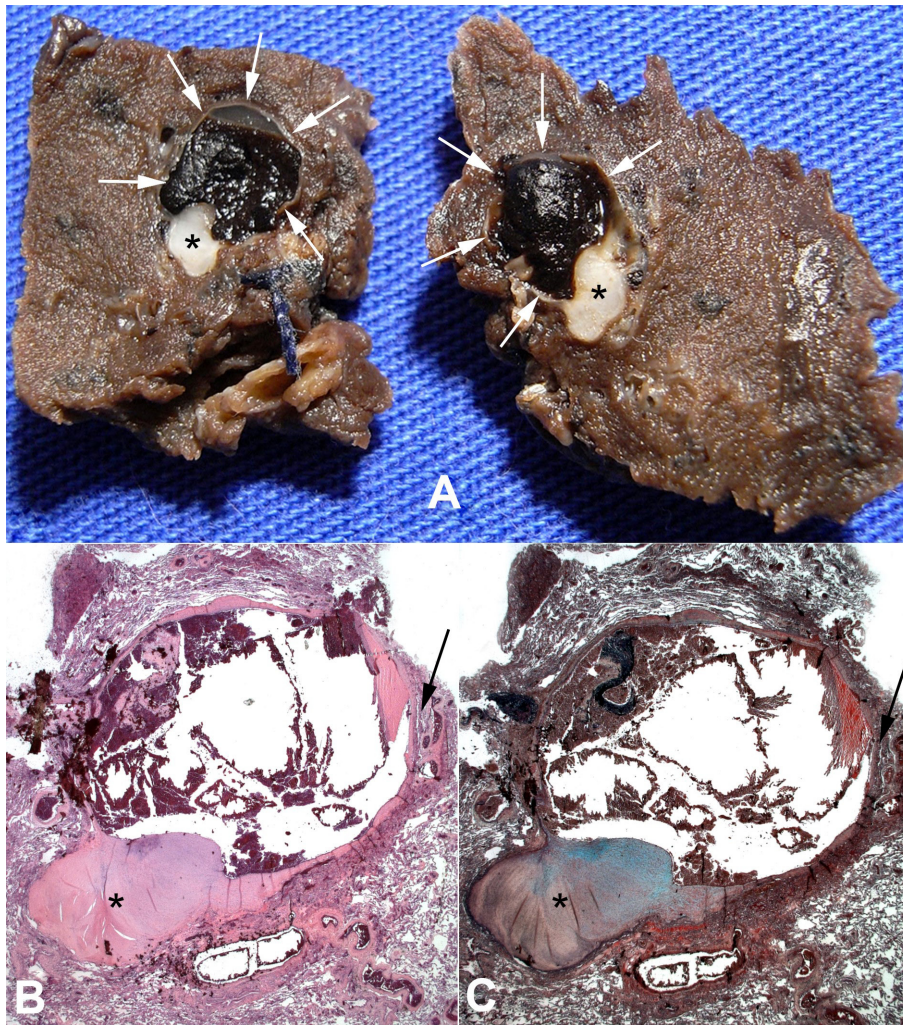


Figure 2. A – Gross view of the tissue block showing the arterial sacular aneurysm in the half-sectioning aspect, filled by blood clots. The aneurysm wall is thin (white arrows), with a localized area of whitish thickness (asterisks). **B** and **C** – Histology of the tissue block of image A, which details the thin wall (black arrows) and the area of whitish thickness (asterisks), which is showed in Figure 3 (H&E, 2.5X in B); (Movat stain, 2.5X in C).

hypertension is a prominent factor.^{1,2} These include patent ductus arteriosus, tetralogy of Fallot, truncus arteriosus, tricuspid atresia, and less commonly, mitral stenosis.¹ Other causes, such as infections (bacterial or mycotic endocarditis, syphilis, tuberculosis), arteriosclerosis, degenerative changes of elastic media, CMD, vasculitis, hypertension, trauma, and arterial-venous fistula may be involved in the etiopathogenesis.¹

Idiopathic PAA is rare, with poorly understood pathogenesis. In order to be classified as idiopathic, the following criteria must be present: (1) the simple involvement of the pulmonary artery with or without involvement of the arterial trunk; (2) the absence of abnormal intracardiac or extracardiac shunts; (3) the absence of chronic cardiac or pulmonary disease,

both clinically and at autopsy; (4) the absence of arterial disease, such as syphilis, and more than simple atheromatosis or arteriolar sclerosis.⁷ PAA are subjected to the same hemodynamic forces as aortic aneurysms, and in the presence of CMD, these aneurysms are prone to dissection and rupture.² Thus, CMD seems to play an important role in the development of idiopathic PAA. In fact, 60% of the patients with idiopathic PAA operated by Deb et al.² had histological confirmation of CMD, such as the patient in our case.

Most patients present with unremarkable symptoms, as dyspnea on exertion, cough, chest pain or hoarseness, due to stretching of the recurrent laryngeal nerve, and are referred due to vascular dilatation on a chest radiograph. If the pulmonary

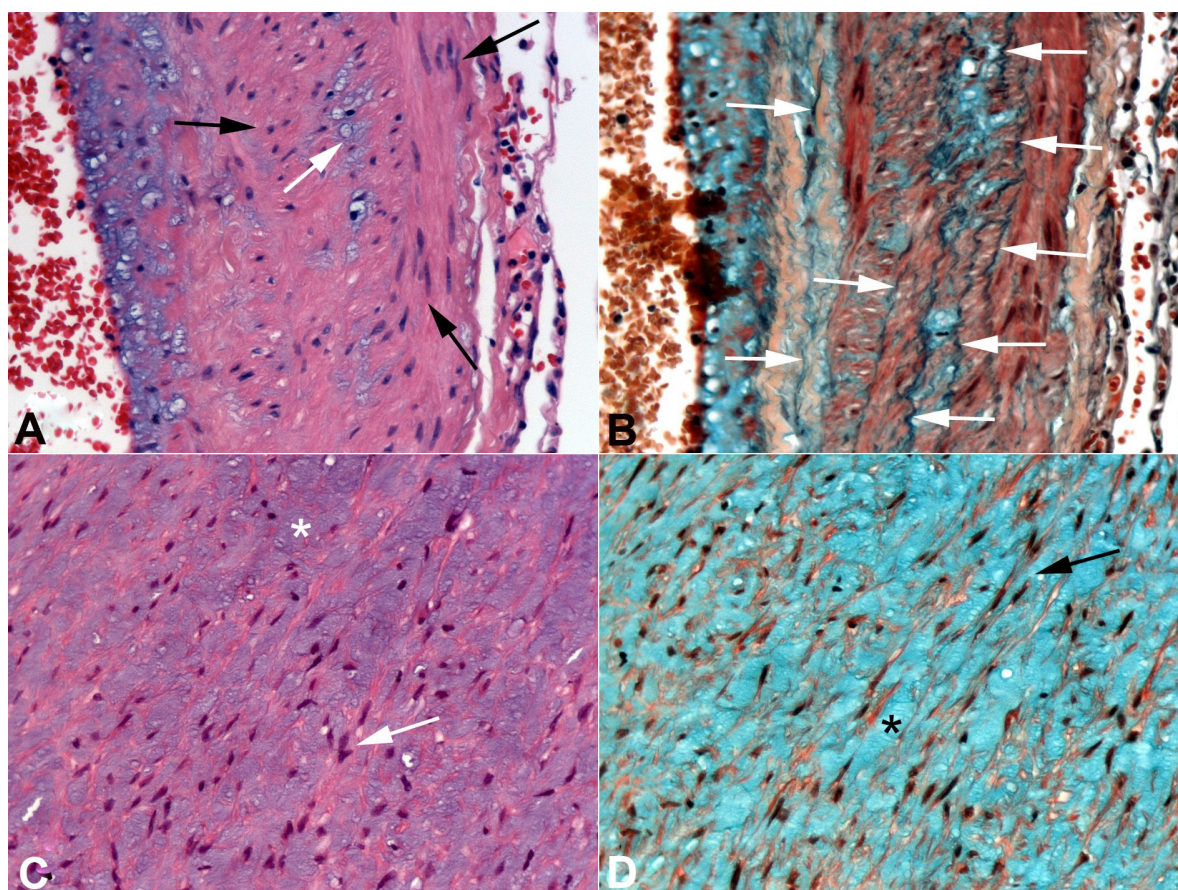


Figure 3. Photomicrography of the aneurysm wall. **A** – The black arrows indicate the disorganized smooth muscle cells; the white arrow indicates one of the mucoid bluish lacunae present in all extensions of the arterial aneurysm wall. **B** – The white arrows show the multiplication of the elastic fibers. **C** and **D** – The asterisk and arrows indicate the mucoid lacuna and smooth muscle cells, respectively, in the localized area of thickness of the aneurysm wall. (H&E in A and C; Movat stain in B and D; original magnification of 40X in A and B, and 20X in C and D).

valve is incompetent, signs of right heart failure may manifest.^{1,2} Sometimes, hemoptysis may be the presenting symptom, which may lead to death.⁵ The diagnosis of a PAA can be established through invasive or non-invasive diagnostic imaging modalities, such as echocardiography, pulmonary angiography, magnetic resonance imaging or CT.⁸ In our case, a CT-guided biopsy was not requested because of the suspicion of an aneurysm.

The management of PAA is not clearly established. When it involves the pulmonary trunk, or the main pulmonary arteries, the treatment may include aneurysm plication, pericardial patch reconstruction, and interposition grafting with allografts or synthetic textile grafts.² Solitary peripheral PAA have been managed most often by lobectomy, but occasionally by aneurysmectomy and pulmonary artery repair.^{1,6} The possibility of endovascular treatment in the present case was considered; however, it was not performed, due to the lack of experience of the radiologists.

Rastogi et al.³ recently described a minimally invasive approach to a peripheral PAA. In our case, as the PAA occurred distally in the middle lobe artery, and the patient had no pulmonary impairment, we chose to perform a middle lobectomy.

The natural history of peripheral solitary PAA is conjectural, given the small number of reported cases.² Nevertheless, there are enough reports of spontaneous rupture to warrant aggressive surgical treatment, especially in young, healthy individuals.^{2,4-6}

PAA should be included in the differential diagnosis of pulmonary nodules.

REFERENCES

1. Gruber PJ, Askin FB, Heitmiller RF. Pulmonary artery aneurysm in a pregnant woman. *Ann Thorac Surg.* 2001;71(3):1023-5. [http://dx.doi.org/10.1016/S0003-4975\(00\)02386-9](http://dx.doi.org/10.1016/S0003-4975(00)02386-9). PMID:11269421.

2. Deb SJ, Zehr KJ, Shields RC. Idiopathic pulmonary artery aneurysm. *Ann Thorac Surg.* 2005;80(4):1500-2. <http://dx.doi.org/10.1016/j.athoracsur.2004.04.011>. PMID:16181901.
3. Rastogi N, Kabutey NK, Kim D, Norbash A. Percutaneous management of segmental pulmonary artery aneurysm in a patient without pulmonary artery hypertension. *Vasc Endovascular Surg.* 2011;45(3):283-7. <http://dx.doi.org/10.1177/1538574411399160>. PMID:21478248.
4. Fukai I, Masaoka A, Yamakawa Y, et al. Rupture of congenital peripheral pulmonary aneurysm. *Ann Thorac Surg.* 1995;59(2):528-30. [http://dx.doi.org/10.1016/0003-4975\(94\)00582-R](http://dx.doi.org/10.1016/0003-4975(94)00582-R). PMID:7847985.
5. Monchik J, Wilkins EW Jr. Solitary aneurysm of the middle lobe artery. A case report and review of solitary peripheral pulmonary artery aneurysms. *Ann Thorac Surg.* 1974;17(5):496-503. [http://dx.doi.org/10.1016/S0003-4975\(10\)65686-X](http://dx.doi.org/10.1016/S0003-4975(10)65686-X). PMID:4823862.
6. Murphy JP, Adyanthaya AV, Adams PR, McArthur JD, Walker WE. Peripheral pulmonary artery aneurysm in a patient with limited respiratory reserve: controlled resection using cardiopulmonary bypass. *Ann Thorac Surg.* 1987;43(3):323-5. [http://dx.doi.org/10.1016/S0003-4975\(10\)60624-8](http://dx.doi.org/10.1016/S0003-4975(10)60624-8). PMID:3827377.
7. Muthialu N, Raju V, Muthubaskaran V, Chandrasekar P, Muralidharan S, Kuppanna PJ. Idiopathic pulmonary artery aneurysm with pulmonary regurgitation. *Ann Thorac Surg.* 2010;90(6):2049-51. <http://dx.doi.org/10.1016/j.athoracsur.2010.05.071>. PMID:21095366.
8. Güler N, Sakarya ME, Eryonucu B, Demirbao R. Transesophageal echocardiographic detection of a pulmonary artery aneurysm complicated by thrombus. *Heart Lung.* 2003;32(3):159-61. [http://dx.doi.org/10.1016/S0147-9563\(03\)00033-5](http://dx.doi.org/10.1016/S0147-9563(03)00033-5). PMID:12827100.

Conflict of interest: None

Submitted on: March 12, 2015

Accepted on: May 1, 2015

Correspondence:

Jussara Bianchi Castelli

Laboratory of Pathology, Heart Institute (InCor), Hospital das Clínicas da Faculdade de Medicina da Universidade de São Paulo.

Av. Dr. Enéas de Carvalho Aguiar, 44, São Paulo/SP - Brazil

CEP: 05403-900

Phone: + 55 (11) 2661-5252 / Fax: + 55 (11) 2661-5279

E-mail: jussara.castelli@incor.usp.br