

The first three years of *Autopsy and Case Reports*: an interesting journey

Aloísio Felipe-Silva^a

Felipe-Silva, A. The first three years of *Autopsy and Case Reports*: an interesting journey [editorial]. *Autopsy Case Rep* [Internet]. 2014; 4(1): 1-5. <http://dx.doi.org/10.4322/acr.2014.001>

Autopsy and Case Reports (A&CR) completes three years of uninterrupted publication this month: March 2014. During these initial years, significant advancements have been made in the process of consolidating a reference journal in the fields of autopsy pathology, anatomoclinical correlation, and medical education.

A total of 5 original research articles, 51 clinical case reports, 40 autopsy reports, 12 editorials, and 2 letters to the editor were published in the first three volumes. The section *Image in Focus* (in which iconic diagnostic images are discussed) was launched in 2013. Major achievements during this period include a broader international readership, constant improvements in graphics, preparation for insertion into scientific databases, and the rise of articles from other institutions that cite A&CR.

Some of our editorial decisions are taken based on quantitative and qualitative analysis of the statistics from the A&CR website, as provided by the Google Analytics™ tool. In the period from April 2011 (the first month after launching and the beginning of the statistics) until December 2013, there were 16,881 website visits by 11,475 unique visitors in a total of 76,785 webpage views. Several factors can influence these metrics, such as the bounce rate (when someone exits the website without interacting with it—currently cumulated at 53.5%), which limits a finer analysis. However, the major trends seem to be valid and can be interpreted under the light of editorial policy.

Figure 1 shows the total number of visits in these three years as well as the number of visits

by visitor language as identified by the software. In the years 2011 and 2012, we used systematic active advertisements, either in print, e-mail or through links in reference websites. The higher average number of monthly visits during this period (563/month) when compared to 2013 (422/month) probably reflects that policy. In fact, the maximum number of monthly visits (May 2011) coincided with the months after launching and the period of maximum publicity. On the other hand, 2014 is a promising year based on the months of January and February, when we received the highest number of visits since October 2011, but in this case, without any specific advertisement strategy.

Since December 2011, the articles and the homepage have been published in English with the aim of increasing the journal's access and visibility overseas. Moreover, we have the fundamental collaboration of international partners in the publishing process. Apparently, this was a wise move since we can note a clear increase in the number of English-speaking visitors and improved access from other countries. The rate of visits from English speakers reached 20.2% and 32.2% in March 2012 and August 2012, respectively. The first time that the rate of English-speakers' visits (46.2%) exceeded the rate of Portuguese speakers (38.3%) was May 2013. Spanish speakers are the next highest number to access the journal's website, with a cumulative rate of 1.9%. The cumulative rate of visitors that speak other languages is 5.1%.

Another indicator of a broader international readership is the greater diversity of countries that visit the journal website (Table 1). The number

^a Anatomic Pathology Service – Hospital Universitário – Universidade de São Paulo, São Paulo/SP – Brazil.

Table 1 – Share of A&CR webpage visits per year

Year	2011	2012	2013
	Total visits		
	5599	4607	5063
Country	Visits share (%)		
Brazil	89.87	74.18	56.43
USA	3.05	7.40	13.57
India	0.38	1.38	3.54
UK	0.45	1.53	3.26
Portugal	0.86	1.50	0.61
Australia	0.30	0.68	1.64
Canada	0.27	0.84	1.60
Phillipines	0.13	0.59	1.44

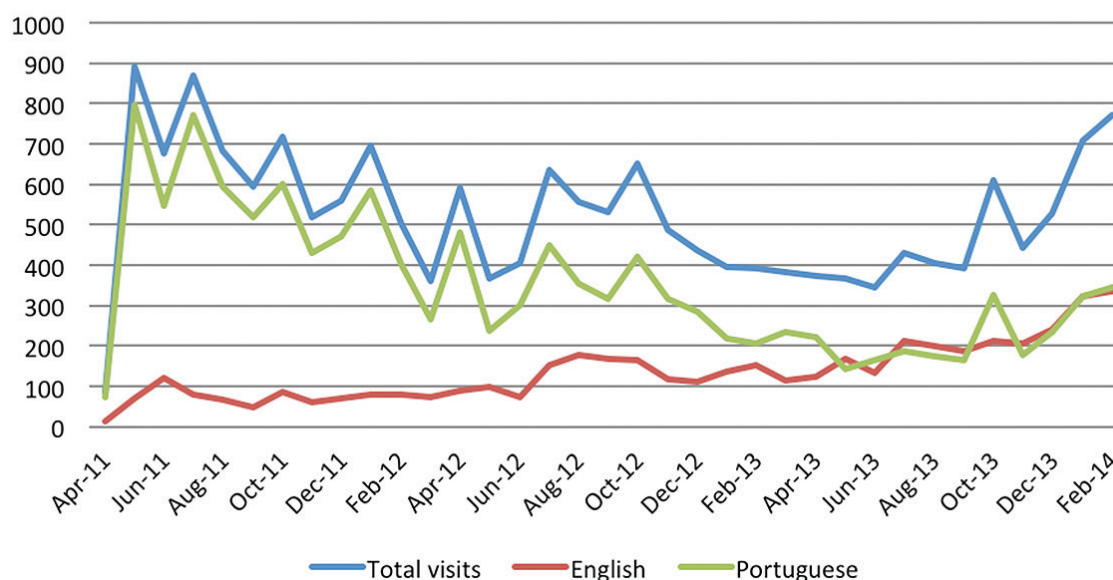
USA (United States of America); UK (United Kingdom). Shares >1% are highlighted.

of countries with more than a 1% share of visits jumped from two in 2011 to five in 2012 and then to seven in 2013.

Access to the journal content has been fairly balanced between autopsy reports and clinical reports or investigative articles. Five of the top 10 article webpage views were autopsy reports (Table 2).¹⁻¹⁰ In a total of 7557 abstract pages viewed, 4 of the top 10 most accessed were related to autopsies (Table 3).^{2,10-18} Finally, in a total of 675 full-text downloads, 2 of the top 10 downloaded articles were autopsy reports (Table 4).^{4,6,19-26}

During the past two years, the first citations began to emerge.²⁷⁻³¹ If we exclude self-citations and consider only citations in indexed journals, the citation per article index in two years (calculated

**A&CR website visits (visitors' language)
2011-2013**

**Figure 1 – Visits to Autopsy and Case Reports website.****Table 2 – Top 10 A&CR articles by webpage views (2011-2013)**

Rank	Ref.	Title	Views
1	[1]	Primary aorto-esophageal fistula: a rare cause of acute upper gastrointestinal bleeding	467
2	[2]	Using the Graf method of ultrasound examination to classify hip dysplasia in neonates	299
3	[3]	Duodenal pseudomelanosis (pseudomelanosis duodeni): a rare endoscopic finding	288
4	[4]	Schistosomiasis: a case of severe infection with fatal outcome	206
5	[5]	Autopsy: a powerful tool for teaching and learning	202
6	[6]	Chronic meningococemia: a rare presentation of meningococcal disease: case report	195
7	[7]	Acardiac fetus: a challenge to pathologists, obstetricians, and neonatologists	191
8	[8]	Hepatic necrosis associated with drug-induced hypersensitivity syndrome	184
9	[9]	Pyogenic liver abscess and pulmonary septic emboli in a diabetic woman	179
10	[10]	Acute coronary syndrome in young patients with atypical symptoms	178

Highlighted ranks are related to autopsies. Ref. = reference number in this editorial.

Table 3 – Top 10 A&CR abstract views (2011-2013)

Rank	Ref.	Title	Views
1	[10]	Acute coronary syndrome in young patients with atypical symptoms	376
2	[11]	Síndrome de Baggio-Yoshinari: relato de caso	292
3	[12]	Tuberculous peritonitis: experience in a community hospital	177
4	[13]	Tribute to the centenary of Waterhouse-Friderichsen syndrome: a case report	166
5	[14]	Carcinomatous transformation of retroperitoneal endometriosis	156
6	[15]	Blunt traumatic diaphragmatic rupture	153
7	[16]	Fatal pulmonary thromboembolism associated with hemoglobin SC disease in a 15-year-old boy	136
8	[2]	Using the Graf method of ultrasound examination to classify hip dysplasia in neonates	130
9	[17]	Lemierre Syndrome – The forgotten disease	128
10	[18]	Adipositas cordis: a challenging differential diagnosis	126

Highlighted ranks are related to autopsies. Ref. = reference number in this editorial.

Table 4 – Top 10 A&CR downloaded articles (2011-2013)

Rank	Ref.	Title	Downloads
1	[4]	Schistosomiasis: a case of severe infection with fatal outcome	135
2	[19]	Spindle-cell carcinoma of the prostate	75
3	[20]	Nodular lymphocyte predominance Hodgkin lymphoma of the parotid gland: a case report	59
4	[21]	“Nutrothorax” complicating a misplaced nasogastric feeding tube in a severely ill patient	57
5	[6]	Chronic meningococemia: a rare presentation of meningococcal disease: case report	54
	[22]	Descending necrotizing mediastinitis secondary to a dental infection	54
7	[23]	What does the future hold?	51
	[24]	Aortic dissection-induced acute flaccid paraplegia treated with cerebrospinal fluid drainage	51
9	[25]	Pyopericarditis and tropical pyomyositis: unusual concomitance	41
10	[26]	Is an interatrial communication the same as an atrial septal defect?	38

Highlighted ranks are related to autopsies. Ref. = reference number in this editorial.

just as the Impact Factor) for 2013 (concerning the 2011-2012 biennium) is 0.0469. It is a modest but encouraging start, since self-citations are not included and some older indexed Brazilian journal rates are not much higher (0.06-0.08).^{32,33}

There are still many challenges facing the A&CR journal. The institutional concentration of authors is decreasing, but it is still high. Submissions from other institutions are still infrequent, and probably depend on the indexing in databases such as PubMed and SciELO. A graphic and editorial renovation that incorporates new technologies is on the way, and it should facilitate the entry into more selective databases of greater impact.

In our view, the balance of our progress over these three years is positive. We have started a free access online journal focusing on academic autopsies and anatomoclinical correlations with

global visibility, increasing international participation and a rising number of citations to its content. We will seek to consolidate this journal in the forthcoming years. The road ahead is long, and there is every reason to believe that our journey will continue with many exciting possibilities and achievements along the way.

REFERENCES

1. Gomes SIM, Campos FPF, Martines BMR, Martines JAS, Tafner E, Maruta LM. Primary aorto-esophageal fistula: a rare cause of acute upper gastrointestinal bleeding. *Autopsy Case Rep* [Internet]. 2011;1(4):57-63. <http://dx.doi.org/10.4322/acr.2011.018>
2. Jacobino BCP, Galvão MD, Silva AF, Castro CC. Using the Graf method of ultrasound examination to classify hip dysplasia in neonates. *Autopsy Case Rep* [Internet]. 2012;2(2):5-10. <http://dx.doi.org/10.4322/acr.2012.018>

3. Felipe-Silva A, Campos FPF, Silva JGN. Duodenal pseudomelanosis (pseudomelanosis duodeni): a rare endoscopic finding. *Autopsy Case Rep* [Internet]. 2011;1(4):39-44. <http://dx.doi.org/10.4322/acr.2011.015>
4. Ferreira CR, Campos FPF, Ramos JG, Martines JAS, Kim EIM, Smeili LAA. Schistosomiasis: a case of severe infection with fatal outcome. *Autopsy Case Rep* [Internet]. 2012;2(1):7-17. <http://dx.doi.org/10.4322/acr.2012.002>
5. Zerbini MCN. Autopsy: a powerful tool for teaching and learning. *Autopsy Case Rep* [Internet]. 2011;1(2):1-2.
6. Brandão AAGS, Prokopowitsch AS, Campos FPF, Yoshihara LAK. Chronic meningococemia: a rare presentation of meningococcal disease: case report. *Autopsy Case Rep* [Internet]. 2012;2(1):29-35. <http://dx.doi.org/10.4322/acr.2012.005>
7. Ferreira CR, Simões AB, Quintal VS, Zerbini MCN. Acardiac fetus: a challenge to pathologists, obstetricians, and neonatologists. *Autopsy Case Rep* [Internet]. 2011;1(1):13-9.
8. Campos FPF, Lima PP, Maragno L, Watanabe FT. Hepatic necrosis associated with drug-induced hypersensitivity syndrome. *Autopsy Case Rep* [Internet]. 2012;2(4):5-14. <http://dx.doi.org/10.4322/acr.2012.029>
9. Felipe-Silva A, Laborda L. Pyogenic liver abscess and pulmonary septic emboli in a diabetic woman. *Autopsy Case Rep* [Internet]. 2011;1(1):33-41.
10. Daher G, Staniak HL, Bittencourt MS, Sharovsky R. Síndrome coronariana aguda em paciente jovem com sintomas atípicos. *Autopsy Case Rep* [Internet]. 2011;1(1):63-7.
11. Saraiva MD, Santomauro Junior AC, Simis NPB, Degenszajn J, Kim EIM. Síndrome de Baggio-Yoshinari: relato de caso. *Autopsy Case Rep* [Internet]. 2011;1(2):63-7.
12. Fonseca LG, Campos FPF, Felipe-Silva A. Tuberculose peritoneal: experiência em um hospital geral. *Autopsy Case Rep* [Internet]. 2011;1(2):3-9.
13. Shieh HH, Góes PF, Lima FR, Zerbini MCN, Bouso A. Tributo ao centenário da Síndrome de Waterhouse-Friderichsen: relato de caso. *Autopsy Case Rep* [Internet]. 2011;1(1):42-52.
14. Martines JAS, Martines BMR, Garzi DR, Lovisollo SM, Mitteldorf C, Margarido PFR. Transformação carcinomatosa de endometriose retroperitoneal. *Autopsy Case Rep* [Internet]. 2011;1(2):31-40.
15. Nogueira AC, Bazzi M, Soriano FG, et al. Rotura diafragmática no trauma abdominal fechado. *Autopsy Case Rep* [Internet]. 2011;1(3):39-45. <http://dx.doi.org/10.4322/acr.2011.007>
16. Amancio TT, Costa ACL, Borsato ML, Marins L, Bacchi LM, Zerbini MCN. Fatal pulmonary thromboembolism associated with hemoglobin SC disease in a 15-year-old boy. *Autopsy Case Rep* [Internet]. 2011;1(3):15-22. <http://dx.doi.org/10.4322/acr.2011.004>
17. Marcello CE, Kim EIM, Smeili LAA, Bianqui L, Bazzi M. Síndrome de Lemierre – A doença esquecida. *Autopsy Case Rep* [Internet]. 2011;1(3):53-8. <http://dx.doi.org/10.4322/acr.2011.009>
18. Ferreira CR, Campos FPF, Garcia Paez JI. Adipositas cordis: um difícil diagnóstico diferencial. *Autopsy Case Rep* [Internet]. 2011;1(1):20-32.
19. Silva CHW, Rojas Claros O, Amselem I, Sá Filho NS, Fugita OEH. Spindle-cell carcinoma of the prostate. *Autopsy Case Rep* [Internet]. 2012;2(1):55-61. <http://dx.doi.org/10.4322/acr.2012.009>
20. Alves CAF, Gouveia MM, Queiroz AGS, et al. Nodular lymphocyte predominance Hodgkin lymphoma of the parotid gland: a case report. *Autopsy Case Rep* [Internet]. 2012;2(1):43-7. <http://dx.doi.org/10.4322/acr.2012.007>
21. Felipe-Silva A, Campos FPF. “Nutrothorax” complicating a misplaced nasogastric feeding tube in a severely ill patient. *Autopsy Case Rep* [Internet]. 2012;2(1):19-23. <http://dx.doi.org/10.4322/acr.2012.003>
22. Oliveira Junior EM, Moreira RT, Cavalcante TC. Descending necrotizing mediastinitis secondary to a dental infection. *Autopsy Case Rep* [Internet]. 2012;2(1):37-42. <http://dx.doi.org/10.4322/acr.2012.006>
23. Campos FPF. What does the future hold? [editorial]. *Autopsy Case Rep* [Internet]. 2012;2(1):3-5. <http://dx.doi.org/10.4322/acr.2012.001>
24. Adam EL, Staniak HL, Sharovsky R, Silva AF, Castro CC, Bittencourt MS. Aortic dissection-induced acute flaccid paraplegia treated with cerebrospinal fluid drainage. *Autopsy Case Rep* [Internet]. 2012;2(1):25-8. <http://dx.doi.org/10.4322/acr.2012.004>
25. Melo PHMC, Staniak HL, Felipe-Silva A, Santos IS, Bittencourt MS. Pyopericarditis and tropical pyomyositis: unusual concomitance. *Autopsy Case Rep* [Internet]. 2012;2(1):49-53. <http://dx.doi.org/10.4322/acr.2012.008>
26. Anderson RH. Is an interatrial communication the same as an atrial septal defect? [editorial]. *Autopsy Case Rep* [Internet]. 2011;1(4):1-2. <http://dx.doi.org/10.4322/acr.2011.010>
27. Raso P, Raso LAM, Melo FA, Tafuri WL. Schistosoma mansoni granuloma in late evolutive phase, in a case of tumoral form in man. *Rev Soc Bras Med Trop* [online]. 2012; 45(5):627-32. <http://dx.doi.org/10.1590/S0037-86822012000500016>
28. Wanderley BR, Maquiné GA, Vieira GN, Tallo FS, Lopes RD, Lopes AC. Tuberculose peritoneal: um diagnóstico diferencial no abdômen agudo: relato de caso [Peritoneal tuberculosis: a differential diagnosis in acute abdomen: case report]. *Rev Bras Clin Med. São Paulo*, 2012;10(6):544-6. Portuguese.
29. Deshmukh G. The role of ligamentum flavum calcification at lumbar spine causing cauda equina syndrome and lumbar radiculopathy: case report. *J Evol Med Dent Sci* [online]. 2013;2(42):8150-5.

30. Kumar S, Sharma N, Singh R, Bhalla A, Varma S. Pyopericardium complicated with cardiac tamponade: an unusual presenting manifestation of primary pyomyositis. *Trop Doct.* 2013;43(1):39-40.
31. Majid N, Bernoussi Z, Mrabti H, Errihani H. Celiac disease, enteropathy-associated t-cell lymphoma, and primary sclerosing cholangitis in one patient: a very rare association and review of the literature. *Case Rep Oncol Med.* 2013, 2013:838941. doi:10.1155/2013/838941
32. Scientific Electronic Library Online – SciELO. *Jornal Brasileiro de Patologia e Medicina Laboratorial* [Internet]. [cited 2014 Mar 03]. Available from: http://statbiblio.scielo.org//stat_biblio/index.php?state=05&lang=en&country=scl&issn=1676-2444&CITED%5B%5D=JORNAL+BRASILEIRO+DE+PA+TOLOGIA+E+MEDICINA+LABORATORIAL&YNG%5B%5D=2013
33. Scientific Electronic Library Online – SciELO. *Revista Brasileira de Cirurgia Plástica* [Internet]. [cited 2014 Mar 03]. Available from: http://statbiblio.scielo.org//stat_biblio/index.php?state=05&lang=pt&country=scl&issn=1983-5175&CITED%5B%5D=REVISTA+BRASILEIRA+DE+CIRURGIA+PLASTICA&YNG%5B%5D=2013

Correspondence: Aloisio Felipe-Silva
Scientific Editor Autopsy and Case Reports
Chief of Anatomic Pathology Service
Hospital Universitário – Universidade de São Paulo, São Paulo/SP – Brazil
E-mail: aloisiosilva@hu.usp.br
