

Chylous ascites secondary to Hodgkin's lymphoma in a HIV/aids patient: case report and literature review

Ascite quilosa secundária a linfoma de Hodgkin em paciente com HIV/aids: relato de caso e revisão da literatura

Mário Luciano de Mélo Silva Júnior¹, Hildenice Ferreira Bernardes Leonídio¹, Mariana Montenegro de Melo Lira², Luciana Cardoso Martins Arraes³, Carlos Eduardo Guimarães Padilha³, Paulo Sérgio Ramos de Araújo^{3,4}

ABSTRACT

Study design: case report. **Case report:** Man, 42 years old, diagnosed with aids two years ago, had developed enlarging in abdominal volume six months from admission. Computed tomography imaging showed free liquid in peritoneal cavity and increased retroperitoneal and mesenteric lymph nodes, besides splenomegaly. Ascitic fluid had milky appearance and high triglycerides levels. Hodgkin's lymphoma (mixed cellularity) was confirmed by histopathological analysis of a video-laparoscopic lymph node biopsy, Ann Arbor IIIS staging. Chemotherapy and continuation of highly active antiretroviral therapy resulted in weight gain and reduction of abdominal volume. Chylous ascites is a rare condition, which has a vast differential diagnosis. **Discussion:** In our review, the majority (15/18, 83%) of chylous ascites in HIV/aids-patients are due to infectious causes (mainly *Mycobacterium avium* complex and tuberculosis infection), in highly immunocompromised patients (mean TCD4=87cell/mL). To the best of our knowledge, this is the first case of chylous ascites secondary to Hodgkin's lymphoma in a patient with aids.

Key-words: Chylous Ascites. AIDS. Hodgkin Disease. Venous Thrombosis. Lymphoma, AIDS-Related

RESUMO

Tipo de estudo: relato de caso. **Relato de caso:** Homem, 42 anos, diagnosticado com aids há dois anos, desenvolveu aumento de volume abdominal há seis meses da admissão. Tomografia computadorizada mostrou líquido livre na cavidade peritoneal, além de linfonodos mesentéricos e esplenomegalia. O líquido ascítico tinha aspecto leitoso e alto nível de triglicérides. Após amplo diagnóstico diferencial, diagnosticamos linfoma de Hodgkin tipo celularidade mista por biópsia linfonodal via videolaparoscópica, Ann Arbor IIIS. Quimioterapia e continuação da terapia antirretroviral de alta potência resultaram em ganho de peso e redução do volume abdominal. Ascite quilosa é uma entidade rara, que possui vários

1. Médico residente, Hospital das Clínicas da Universidade Federal de Pernambuco, Av. Prof. Moraes Rego, 1235, Recife-PE, CEP 50670-901, Brazil
2. Departamento de Patologia, Hospital das Clínicas da Universidade Federal de Pernambuco
3. Departamento de Medicina Tropical, Hospital das Clínicas da Universidade Federal de Pernambuco
4. Centro de Pesquisa Aggeu Magalhães – Fiocruz, Recife-PE

Os autores negam conflitos de interesse
Os aspectos éticos foram respeitados

CORRESPONDÊNCIA:
Mário Luciano de Mélo Silva Júnior
Hospital das Clínicas da
Universidade Federal de Pernambuco
Av. Prof. Moraes Rego, 1235,
CEP 50670-901, Recife-PE.

Recebido em 17/04/2017
Aprovado em 26/09/2017

diagnósticos diferenciais. **Discussão:** Em nossa revisão, a maioria (15/18, 83%) dos casos de ascite quilosa em paciente com HIV/aids deveu-se a causa infecciosa (especialmente pelo *Mycobacterium avium* complex e tuberculose), em pacientes gravemente imunocomprometidos (linfócitos T-CD4 médio=84células/mm³). Até onde sabemos, este é o primeiro caso de ascite quilosa secundária a linfoma de Hodgkin em paciente com aids.

Palavras-chave: Ascite Quilosa. AIDS. Doença de Hodgkin. Linfoma Relacionado a AIDS. Trombose Venosa.

Introduction

Hodgkin’s lymphoma (HL) is a non-defining human immunodeficiency virus (HIV)-associated disease that seems to be increasing in occurrence among HIV-infected people, while other lymphomas became less frequent.¹ Chylous ascites (CA) is a

condition known since 16th century, but it is an infrequent manifestation of malignancies, and it is even uncommon as presentation of HL.² In HIV/aids population, the occurrence of CA seems to be mainly due to infectious diseases (Table 1). In this report, we present the first case of CA secondary to HL in a HIV-infected patient.

Table 1: Review of case reports on chylous ascites in HIV-infected people

Author	Age	CD4	Etiology	ART	Outcome ^a
Shaik et al, 2014 ³	44	103	MAC/IRIS	Y	Good
Shen et al, 2012 ⁴	47	66	<i>Penicillium marneffe</i>	N	Good
Summachiwakij, 2012 ⁵	39	-	Tuberculous pericarditis	Y	Good
Rabie, 2010 ⁶	3	4	Tuberculosis/IRIS	Y	Good
Philips, 2009 ⁷	38	210	MAC/IRIS	Y	Good
	40	150	MAC/IRIS	Y	Poor
	43	150	MAC/IRIS/Septic thrombophlebitis	Y	Poor
	42	60	MAC/IRIS	Y	Good
	34	30	MAC/IRIS	Y	Good
Foschi et al, 2007 ⁸	23	110	MAC/IRIS	Y	Poor
	43	205	B-cell NHL	Y	Poor
Sathiravikarn et al, 2006 ⁹	30	19	Tuberculosis	N	Good
Ekwcani, 2002 ¹⁰	53	-	Tuberculosis	N	Good
Keaveny et al, 1999 ¹¹	35	20	MAC	N	Good
Rollhauser et al, 1996 ¹²	42	0	MAC	Y	Poor
Arsura et al, 1994 ¹³	41	-	Tuberculosis	Y	Good
Lin, 1994 ¹⁴	43	-	Kaposi	N	Poor

^aMedian follow-up of 6 months for Good (=no recurrence, 12/18, 67%) and 7 months for Poor (=death or recurrence, 6/18, 33%). Age in years old, all patients were men. ART=Antiretroviral therapy when diagnosis (Y=yes, 13/18, 72%; N=no/information no available, 5/18, 28%), NHL=non-Hodgkin’s lymphoma, MAC=*Mycobacterium avium* complex, IRIS=Immune reconstitution inflammatory syndrome, -=no information available.

Case report

Man, 42 years old, living with HIV, on irregular use of efavirenz + lamivudine + tenofovir as highly active antiretroviral therapy (HAART) since diagnosis, HIV viral load=3000 copies/mL, count TCD4=318/mL, had developed enlarging in abdominal volume six months from admission in our Infectology service, with no constitutional symptoms. HIV infection was diagnosed 2 years ago in a neurotoxoplasmosis presentation. On physical examination, he presented lipodystrophy, oedema in lower limbs (right bigger than left), temporal wasting, globose abdomen (94cm in circumference), shifting dullness to percussion, fluid waves. No signs of liver disease or palpable lymph nodes.

Ultrasonography/computed tomography imaging showed free liquid in peritoneal cavity and increased, but usual aspect retroperitoneal and mesenteric lymph nodes, discrete splenomegaly (Figure 1) and no special comments for liver including venous system. Doppler venous ultrasonography showed extensive thrombosis in right common femoral vein. Study of this ascitic fluid revealed milky appearance and high triglyceride levels (708mg/dL, cell count = 1,170/mm³ [45% neutrophils, 25% lymphocytes). Polymerase chain reaction for *Mycobacterium tuberculosis*, Gram stain and cultures (pyogenic and fungal) were negative in ascites, as well no neoplastic cells were found. Immunochromatographic test for filariasis was also negative. Pancreatic, liver and esophagogastroduodenoscopy showed no abnormalities. Lymphoscintigraphy resulted normal. Videolaparoscopic assessment revealed thickened peritoneum, enlarged mesenteric lymph nodes (biopsy was performed) and limited further evaluation because of the opaque liquid.

During investigation, patient was in full anti-coagulation and on hipolipidic and supplemented with medium chain triglycerides diet. Although, he had evolved with weight loss and new large deep venous thrombosis (DVT) in the left leg. Additionally, this patient has left pleural effusion, which we had not punctured. Origin of this pleural effusion (cardiac, chylous or both) was not defined.

Histopathologic data from mesenteric ganglia were suggestive for classic mixed cellularity HL, which was confirmed by imunohistochemistry (CD45-, CD15+, CD30+) (Figure 2). Bone marrow

study was negative for lymphoma infiltration. HL staging resulted in Ann Arbor IIIS.

Treatment with AVBD scheme (adriamycin, vinblastine, bleomycin, dacarbazine) and maintenance of HAART resulted in reduction of abdominal volume and weight gain. At six months' evaluation patient had no complaints flaccid abdomen with 80cm of circumference, undetectable viral load and count TCD4=213/mL.

We performed an integrative review of literature in Pubmed, LILACS and BIREME with "hiv OR

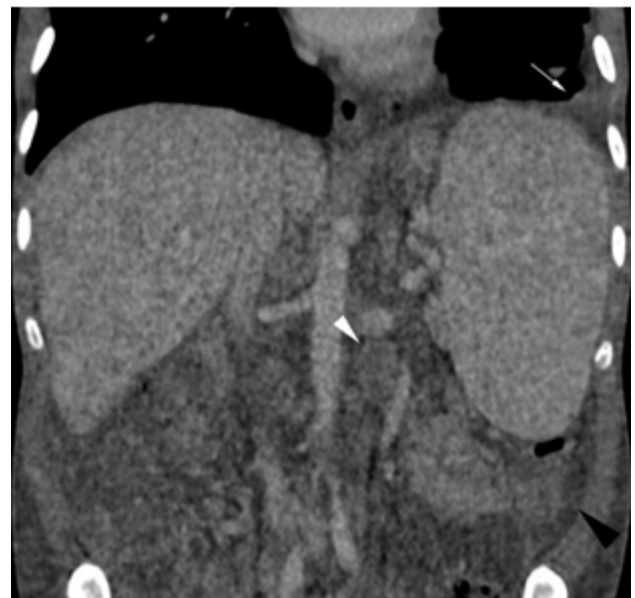


Figure 1: Computed tomography with ionic contrast of thoraco-abdominal region. White arrow points to left pleural effusion, white arrow-head indicates to 3 cm retro-peritoneal lymph node, black arrow-head shows ascitic fluid. Note splenomegaly.

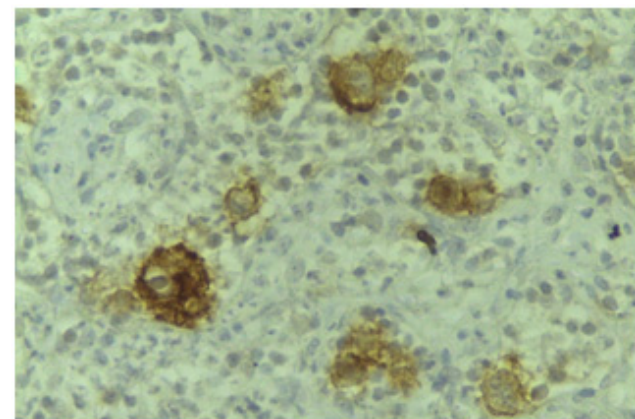


Figure 2: Mesenteric lymph node biopsy. Strong CD30 positivity in Hodgkin's cellules.

aids AND chylous ascites OR chyloperitoneum” terms; only articles which abstract was not accessible were excluded. Results are discussed in text and summarized in Table 1. Informed consent was obtained from the patient prior to produce this manuscript.

Discussion

CA is a rare condition (1:20,000 admissions in general hospital, but 1:2,248 HIV hospital interments)⁷ first described in 1691, which has a vast differential diagnosis,¹⁵ such as trauma, post abdominal surgery, liver cirrhosis, cancer, infectious (tuberculosis, *Mycobacterium avium complex*, filariasis, paracoccidioidomycosis),¹⁶ pancreatic, yellow-nail syndrome, lymphatic malformation, among others. Although lymphoma is frequently remembered in differential diagnosis of CA (expected frequency of 33-50% of all cases), recent review cites frequency of 8% among adult cases,¹⁵ and in HIV population this frequency seems to be even lower. We reviewed the all 18 published cases of CA in HIV/aids population, most of them (15/18, 83%) caused by infectious diseases, markedly tuberculosis and *Mycobacterium avium complex*, in highly immunocompromised patients (mean TCD4=87cell/mL, mean age=38yr-old) (Table 1). Kaposi's sarcoma¹⁴ and non-Hodgkin's lymphoma⁸ were already reported as causative diseases of CA, but to the best of our knowledge this is the first case of CA associated with classic HL in a HIV/aids patient.

Mechanisms of CA genesis in these cases are secondary to lymph node fibrosis, obstruction or both caused by malignant infiltration that leads to high pressure in pre-nodal lymphatic vessels and exudation from subserosal lymphatics into peritoneal cavity. CA is an infrequent condition and, between lymphomas, presentation with CA is more common in non-HL due to more prominent mesenteric adenopathy.² We believe that the higher inci-

dence of non-HL and its preference for abdominal region justify this relation with CA, nevertheless HL in HIV/aids is usually aggressive, presenting with extra-nodal disease in 74-92%.¹⁷ Curiously, all reported cases of CA in HIV were in men.

HL associated to HIV seems to be increasing in frequency,^{1,18} due reduction of incidence of others cancers caused by HAART. This entity has a different epidemiological profile in HIV people compared with non-HIV ones¹⁹: a) the incidence peak occurs ten years later; b) it has an incidence tenfold higher; c) the most common histological subtype is mixed cellularity (as this case) in contrast with nodular sclerosis in non-HIV; and d) bone marrow infiltration is more frequent. Recent data suggests no association between TCD4 or HIV counts and risk for HL. HL treatment in HIV-infected people has shown favourable outcomes compared whit pre-HAART era. Currently, complete remission is achieved in 87% of patients staged as III/IV in AVBD + HAART scheme.¹⁹

Recurrent DVT during full anticoagulation is not frequent and suggest a highly thrombogenic status. HIV itself promotes perturbation in coagulation homeostasis (deficiency of proteins C and S, heparin cofactor II and antithrombin, among others), leading to a risk for DVT tenfold higher than HIV-negative population.²⁰ Also in CA patients, adding to Virchow's triad, is noted stasis caused by increase in inferior cava vein pressure (in this review we found a frequency of 19% of lower leg oedema at presentation of CA).

Conclusion

CA is a challenging symptom owning its vast differential diagnosis. We presented a case of CA secondary to HL (mixed cellularity) in a HIV-infected patient, which was never previously reported. Although in HIV/aids population infectious causes are the most common, HL should be remembered.

References

1. Franceschi S, Lise M, Clifford GM, Rickenbach M, Levi F, Maspoli M, et al. Changing patterns of cancer incidence in the early- and late-HAART periods: the Swiss HIV Cohort Study. *Br J Cancer*. 2010; 103: 416–22.
2. Hufford S, Hu E. Lymphoma and chylous ascites. *West J Med*. 1988;148:581-3.
3. Shaik IH, Gonzalez-Ibarra F, Khan R, Shah S, Syed AK, Lintz D. Chylous ascites in a patient with HIV/AIDS: a late complication of mycobacterium avium complex-immune reconstitution inflammatory syndrome. *case reports in infectious diseases* 2014;2014:268527.
4. Shen YZ, Wang ZY, Lu HZ. *Penicillium marneffeii* chylous ascites in acquired immune deficiency syndrome: a case report. *World J Gastroenterol*. 2012; 18: 5312–4.
5. Summachiwakij S, Tungsubutra W, Koomanachai P, Charoenratanakul S. Chylous ascites and chylothorax due to constrictive pericarditis in a patient infected with HIV: a case report. *J Med Case Rep*. 2012;6:163.
6. Rabie H, Lomp A, Goussard P, Nel E, Cotton M. Paradoxical tuberculosis associated immune reconstitution inflammatory syndrome presenting with chylous ascites and chylothorax in a HIV-1 infected child. *J Trop Pediatr*. 2010;56:355-8.
7. Phillips P, Lee JK, Wang C, Yoshida E, Lima VD, Montaner J. Chylous ascites: a late complication of intra-abdominal Mycobacterium avium complex immune reconstitution syndrome in HIV-infected patients. *Int J STD AIDS*. 2009;20:285-7.
8. Foschi D, Rizzi A, Corsi F, Trabucchi E, Corbellino M. Chylous ascites secondary to B-cell non Hodgkin's lymphoma in a patient with the acquired immune deficiency syndrome (AIDS). *Digestive and Liver Disease*. 2008;40: 481–2.
9. Sathiravikarn W, Apisarnthanarak A, Apisarnthanarak P, Bailey TC. Mycobacterium tuberculosis associated chylous ascites in HIV-infected patients: case report and review of the literature. *Infection* 2006;34:230-3.
10. Ekwacani CN. Chylous ascites, tuberculosis and HIV/AIDS: a case report. *West Afr J Med*. 2002;21:170-2.
11. Keaveny AP, Karasik MS, Farber HW. Successful treatment of chylous ascites secondary to Mycobacterium avium complex in a patient with the acquired immune deficiency syndrome. *Am J Gastroenterol*. 1999;94:1689-90.
12. Rollhauser C, Borum M. Case report: a rare case of chylous ascites from Mycobacterium avium intracellulare in a patient with AIDS: review of the literature. *Dig Dis Sci*. 1996;41:2499-501.
13. Arsurua EL, Ismail Y, Civrna-Karalian J, Johnson RH. Chylous ascites associated with tuberculosis in a patient with AIDS. *Clin Infect Dis*. 1994;19:973.
14. Lin O, Scholes JV, Lustbader IJ. Chylous ascites resulting from Kaposi's sarcoma in an AIDS patient. *Am J Gastroenterol*. 1994;89:2252-3.
15. Steinemann DC, Dindo D, Clavien PA, Nocito A. Atraumatic chylous ascites: systematic review on symptoms and causes. *J Am Coll Surg*. 2011;212:899-905 e1-4.
16. Fernandes FF, Alves VO, Sanchez TE, Paula WD, Santana AN. Chylothorax in Paracoccidioidomycosis. *Rev Inst Med Trop*. Sao Paulo. 2016;58:57.
17. Yotsumoto M, Hagiwara S, Ajisawa A, Tanuma J, Uehira T, Nagai H, et al. Clinical characteristics of human immunodeficiency virus-associated Hodgkin lymphoma patients in Japan. *Int J Hematol*. 2012;96:247-53.
18. Hoffmann C, Hentrich M, Gillor D, Behrens G, Jensen B, Stoehr A, et al. Hodgkin lymphoma is as common as non-Hodgkin lymphoma in HIV-positive patients with sustained viral suppression and limited immune deficiency: a prospective cohort study. *HIV Med*. 2015;16:261-4.
19. Hentrich M, Spina M, Montoto S. (2016) HIV-Associated Hodgkin Lymphoma. In: Hentrich M, Barta S. (eds) HIV-associated Hematological Malignancies. Springer, Cham. pp 119-32.
20. Saber AA, Aboolian A, LaRaja RD, Baron H, Hanna K. HIV/AIDS and the risk of deep vein thrombosis: A study of 45 patients with lower extremity involvement. *Am Surg*. 2001;65:645-7.