

RELATO DE CASO

Possible cause-effect relation between estrogen and focal nodular hyperplasia. Case report

Possível relação de causa-efeito entre estrogênio e hiperplasia nodular focal. Relato de caso

Ana Carolina Delazia Albuquerque Santana¹, Daniel Ferracioli Brandão², Orlando de Castro e Silva³

ABSTRACT

A 22-year-old female patient sought medical care due to an asymptomatic solid nodule in the liver, incidentally diagnosed by abdominal ultrasound. She reported the use of an estrogen-based oral contraceptive for approximately 3 years. She denied smoking or alcohol drinking. Her mother had a history of nonalcoholic steato-hepatitis and her maternal grandmother had a hepatic hemangioma. Physical examination revealed an asymptomatic patient with discretely painful palpation of the right hypochondrium close to the xiphoid appendix. Ultrasound examination revealed a 5.9 x 4.1 cm hypoechogenic nodule in the left lobule and computed tomography revealed a 5.3 x 6.3 x 4.5 cm focal lesion in the 2/3 segments. Other tests of hepatic function proved to be normal, except for serum gammaglutamyl transferase, which was increased by approximately two times the mean reference value. With a diagnosis of focal nodular hyperplasia, she was submitted to exploratory laparotomy followed by partial hepatectomy (segment III, Figure 1). With a macroscopic diagnosis of hepatic adenoma, the anatomopathological report was focal nodular hyperplasia. At present, after four years of postoperative follow-up, the patient is well and is taking progesterone instead of the estrogen-based anovulatory agent.

Key words: Liver. Focal nodular hyperplasia. Estrogen. Anovulatory. Progesterone.

Introduction

Cavernous hemangiomas, tumors of blood vessels, are the most common benign hepatic lesions. They occur as soft blue-red nodules, usually single, individualized, smaller than 2 cm, and located below Glisson's capsule.

Focal nodular hyperplasia (FNH) mainly occurs among young women up to the third and fourth dec-

ades of life and consists of a lesion of well demarcated mass, encapsulated, usually yellow in color and lighter than surrounding hepatic tissue. A typical pattern of FNH presentation is a scar containing large arterial vessels that exhibit fibromuscular hyperplasia. This scar is depressed, central and interspersed with fibrous septa containing intense proliferation of bile ducts along its margin and an expressive lymphocyte infiltrate that irradiate towards the periphery.

¹ Graduate Student, Faculty of Medicine of Ribeirao Preto, University of Sao Paulo (FMRP-USP), Ribeirao Preto, Sao Paulo, Brazil, President of the Surgery and Transplant League - Centro Acadêmico Rocha Lima (CARL)

² Assistant Physician, Department of Pathology FMRP-USP, Ribeirao Preto, Sao Paulo, Brazil

³ Chairman and Head of the Department of Surgery and Anatomy, FMRP-USP, Ribeirao Preto, Sao Paulo, Brazil

Correspondência:

Departamento de Cirurgia e Anatomia.
Faculdade de Medicina de Ribeirão Preto-USP
Av. Bandeirantes, 3900

Artigo recebido em
Aprovado para publicação em

Hepatic adenomas, benign hepatocyte neoplasias, also occur among young women in association with the use of estrogen-based contraceptives. They appear as pale well demarcated nodules which can be found throughout the liver parenchyma. They are bronze in color and are often colored with bile. Consisting of laminae and cell cords without expressive atypia showing variations both in size and in nucleus, they sometimes present a lighter cytoplasm due to the abundant presence of glycogen. When their location is subcapsular, they tend to rupture, usually during pregnancy, due to the action of estrogen.¹

We report here the case of a patient with a hepatic nodule submitted to surgical treatment.

Case report

A 22-year-old female patient from Limeira, São Paulo, sought medical care due to an asymptomatic solid nodule in the liver incidentally diagnosed by abdominal ultrasound (US). She reported the use of an estrogen-based oral contraceptive for approximately 3 years. She denied smoking or alcohol drinking or the

use of illicit drugs. Her mother had a history of non-alcoholic steato-hepatitis and her maternal grandmother had a hepatic hemangioma. She denied other gastrointestinal neoplasias in the family. Physical examination revealed an asymptomatic patient with discretely painful palpation of the right hypochondrium close to the xiphoid appendix.

At admission, the patient brought a US exam in which a hypoechogenic nodule was visible in the left lateral segment, measuring 5.9 x 4.1, and a computed axial tomography showing a focal lesion in the left lateral segment measuring 5.3 x 6.3 x 4.5 cm compatible with FNH but also possibly representing a hepatic adenoma (Figure 1).

Biochemical blood exams were normal, with a discrete elevation of gamma glutamyltransferase (99 U/L; normal levels: 5 to 55 U/L). Serologic tests for hepatitis B and C were negative. With a preoperative diagnosis of FNH or possible hepatic adenoma, the patient was then submitted to exploratory laparotomy and to partial hepatectomy (segment III, Figure 2) by Chevron incision.

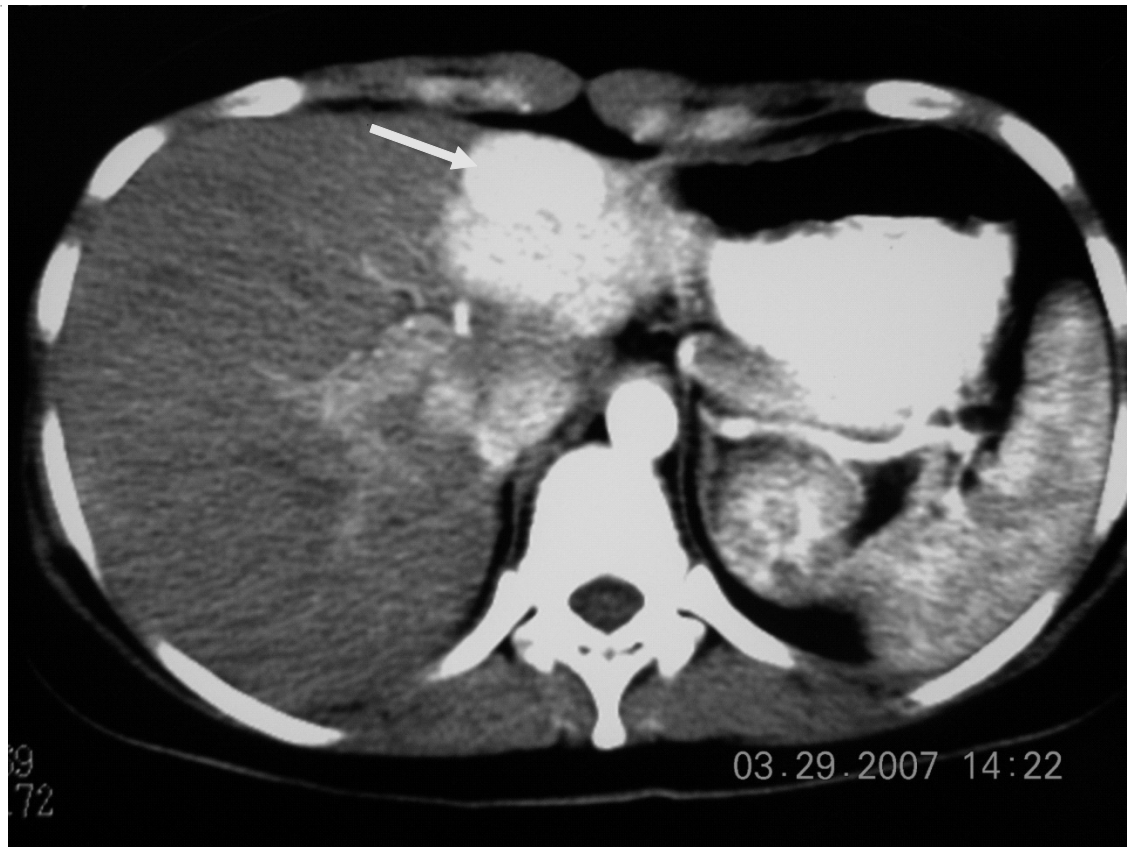


Figure 1: Computed axial tomography with a hepatic nodule in segment 2 of the liver (arrow).

The surgical finding was a liver with a hardened lesion between segments II and III (Figure 2), with no distant lesions and with the remaining liver showing the habitual wine-colored aspect.

Anatomopathological analysis revealed macroscopically an oval, well-delimited and encapsulated lesion measuring 5.5 x 5.0 x 3.3 cm white-yellowish in color, lobulated, elastic, subcapsular and close to the raw margin of surgical resection, as can be seen in Figure 3. Histological sections revealed an encapsu-

lated, well-delimited nodular structure filled with nodules of hepatic tissue intermingled with thick and incomplete fibrous septa, with the latter showing bile ducts as well as dilated vessels with thickened or thinned walls. The hepatocytes inside the nodules were of normal to slightly enlarged size, with the nuclei showing no atypia. The perilesional hepatic tissue exhibited preserved architecture and mild cholestasis. On this basis, a diagnosis of FNH was determined, with a resection margin close to the lesion (figures 4 and 5).

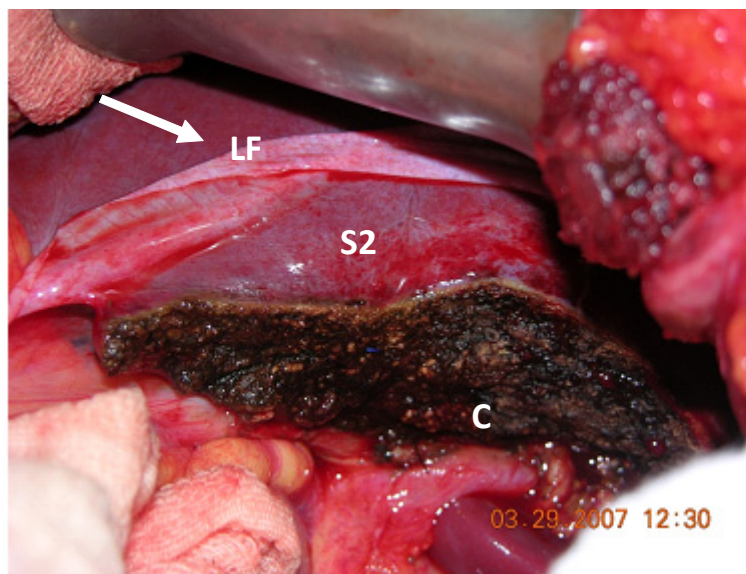


Figure 2: operated liver: LF- falciform ligament C- raw resection area with fulguration with an electric surgical knife ; S2- segment 2.

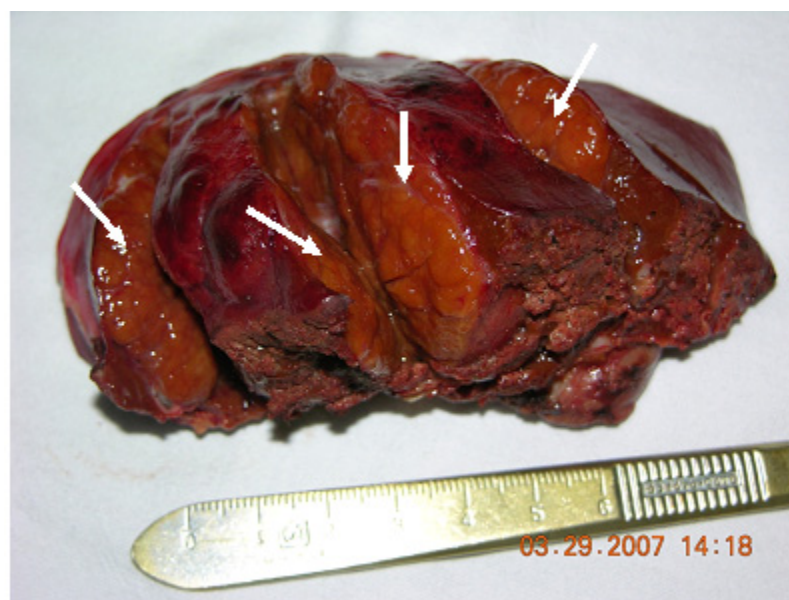

Figure 3: Surgical specimen with a hepatic nodule (arrow) in the resected segment.

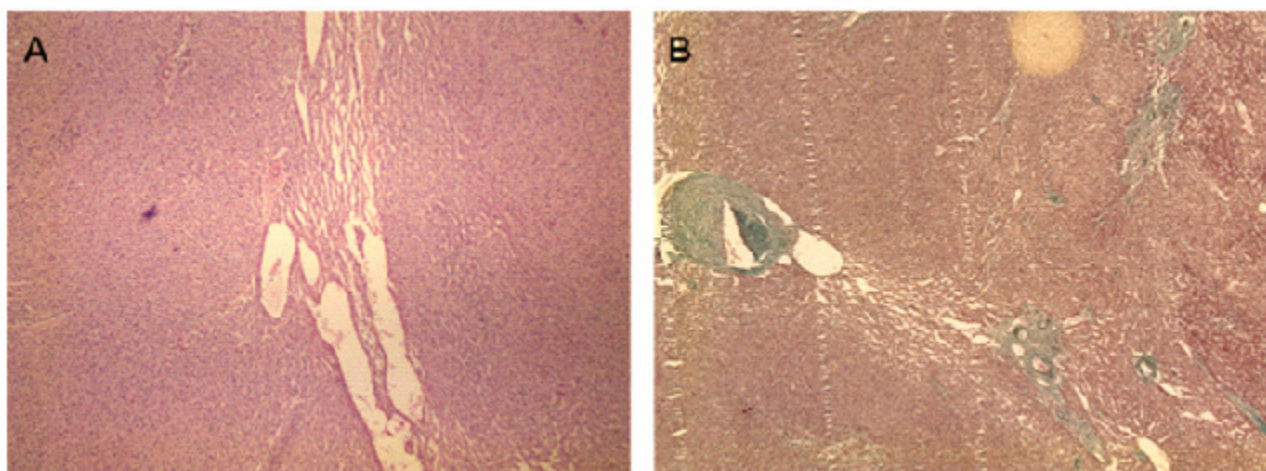


Figure 4: Histological aspect of the hepatic lesion. Hematoxylin-Eosin 40X - Panoramic view showing a band of fibrosis with prominent vessels in the midst of hepatocellular proliferation without atypia (Panel A). Masson Trichrome 25X - Panoramic view showing structures of the portal space type, with collagen staining green (Panel B)

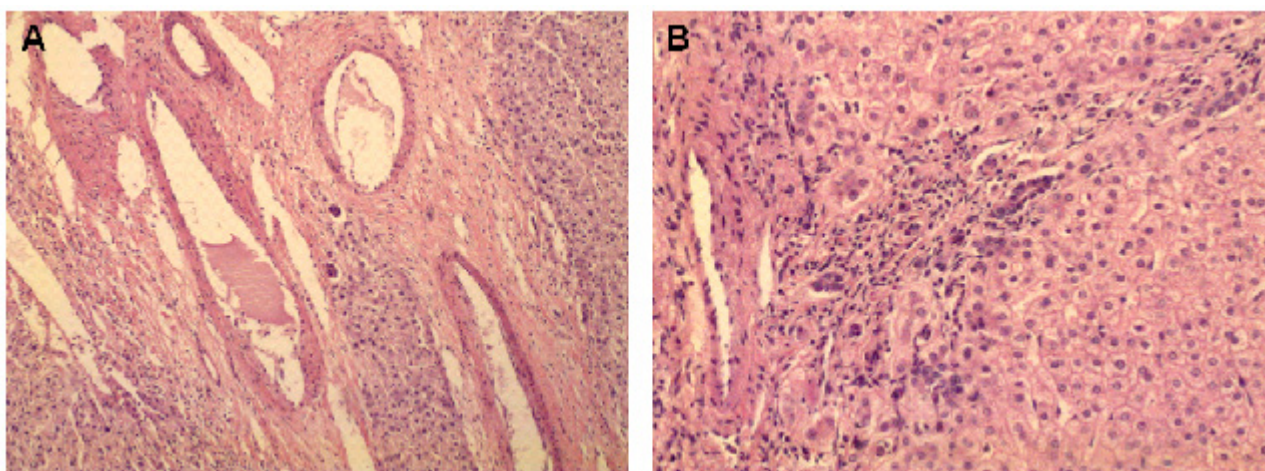


Figure 5: Histological aspect of the hepatic lesion. Hematoxylin-Eosin 100X – Enlarged view showing prominent and irregular blood vessels in the midst of fibrosis and areas containing hepatocyte trabeculae without atypia (Panel A). HE 200X – Enlarged view showing blood vessels and proliferated bile ducts in the midst of hepatocyte trabeculae without atypia (Panel B).

The immediate surgical evolution of the patient was good, without interurrences; the surgical wound was dry and clean and drains, nasogastric tube and central access were removed early, with the patient being discharged from the hospital, with a free return.

The patient returned after 2 years, asymptomatic. In the subsequent year, 2010, hepatic function exams were normal and magnetic resonance imaging showed a suspicion of FNH in segment VII, which was ruled out after discussion with the radiology team. The patient was counseled to use progesterone-based contraception.

Discussion

FNH is the second most common benign hepatic tumor, corresponding to approximately 66 to 86% of these benign tumors. In relation to primary hepatic tumors, it corresponds to 8%,² with its incidence being only lower than that of hepatic hemangiomas that affect approximately 20% of the population.³ In the case of hepatocellular adenomas, the incidence of these benign tumors showed an expressive increase with the introduction of contraceptives, with the current estimate being 34/100,000 women taking contra-

ceptives.⁵ The risk is higher for women older than 30 years and taking high doses of estrogen-based contraceptives for more than 5 years.⁴

The incidence of these three types of benign neoplastic lesions is higher among women. Hemangiomas are more frequent among women aged 30 to 40 years and among neonates. FNH is more prevalent among women of fertile age, i.e., 8 women: 1 man.⁵

Another similarity among these benign lesions is that affected patients usually are asymptomatic and the tumor is detected incidentally during indirect imaging exams or at autopsy.⁶

Symptoms that may occasionally occur are liver tumoration and pain. Pain occurs when there is rupture or hemorrhage of the nodule, a more frequent situation among women using estrogen-based oral contraceptives or during pregnancy, when women are under estrogen stimulation.¹ Laboratory tests usually show no changes.

The influence of sex hormones such as estrogen present in oral contraceptives on the pathogenesis of hepatic adenomas has been demonstrated in the scientific literature^{5,7,8}, but their role in FNH is still debatable and has not been fully clarified. It is believed that there may be an association between the use of these contraceptives and FNH, in which the use of these agents would accelerate tumor growth. In some patients, after discontinuation of an oral contraceptive there was a spontaneous regression of FNH; however oral contraceptives do not seem to be the cause of the lesion since cases of FNH have been observed

in children, men, women who never took contraceptives, and in some patients before the introduction of the hormones.⁹

In contrast to adenomas, FNH is not a premalignant lesion.² On this basis, removal of the tumor is indicated only in rare conditions such as cases of complications (rupture or hemorrhage), or when tumors are larger than 8 cm. Under other conditions, the treatment indicated for FNH is tumor embolization by arteriography or simply a conservative conduct with periodic clinical follow-up. However, since adenomas have a carcinogenic potential and a high risk of rupture, surgical treatment is the direct indication regardless of the size of the lesion. In addition, in situations of doubtful diagnosis, as in the present case, the option is for surgical treatment, as done here.

Although a relationship between the use of oral contraceptives and FNH has not been confirmed, in the present case we took into consideration the following factors:

- 1- The history of the development of a neoplasia
- 2- The fertile age of the patient, with the possibility of her getting pregnant (a risk factor for the rupture of adenomas)
- 3- The relation between the use of estrogen and adenomas

Thus, in the present case contraceptive therapy based on progesterone was recommended since no literature reports were found showing an association between progesterone and hepatic tumors.

RESUMO

Paciente do sexo feminino, 22 anos, procurou auxílio médico devido a um nódulo sólido no fígado, assintomático, diagnosticado incidentalmente por ultrassonografia de abdome. Relatava uso de anticoncepcional oral, à base de estrógeno, por cerca de 3 anos. Negava tabagismo e etilismo. Mãe apresentava história de esteato-hepatite não alcoólica e avó materna era portadora de hemangioma hepático. Ao exame físico, apresentava-se assintomática, com palpação discretamente dolorosa do hipocôndrio direito próximo ao apêndice xifóide. Ao exame ultrasonográfico apresentava um nódulo hipoecogênico no lóbulo esquerdo de 5,9 x 4,1 cm e à tomografia computadorizada apresentava lesão focal nos segmentos 2/3 de 5,3 x 6,3 x 4,5 cm. Foram colhidos outros exames representativos da função hepática, que se revelaram normais com exceção da gama glutamiltransferase sérica, que apresentava-se aumentada aproximadamente duas vezes o valor médio de referência. Com diagnóstico de hiperplasia nodular focal foi submetida à laparotomia exploradora e realizada hepatectomia parcial (segmento III, figura 1). Com diagnóstico macroscópico de adenoma hepático, o laudo anatomopatológico foi hiperplasia nodular focal. Atualmente, com quatro anos de acompanhamento pós-operatório encontra-se bem, tendo sido feita substituição do anovulatório à base de estrógeno por progesterona.

Palavras-Chave: Fígado. Hiperplasia nodular focal. Estrógeno. Anovulatório. Progesterona.

Referências

1. Kumar,V; Abbas, A. K; Fausto, N. Robbins & Cotran:Patologia -Bases Patológicas das Doenças. 7ª Ed.; Elsevier; 2004. p. 966-72
2. Teixeira,Marise Silva et al . Hiperplasia nodular focal do fígado: apresentação de um caso e revisão da literatura. Radiol. Bras., 2007; 40, n. 4.
3. Costa SRP, Speranzini MB, Horta SH, Miotto MJ, Myake A, Henriques AC. Surgical treatment of painful hepatic hemangioma. Einstein. 2009;7:88-90.
4. Korula J, Yellin A, Kanel G, Campofiori G, Nichols P. Hepatocellular carcinoma coexisting with hepatic adenoma. Incidental discovery after long-term oral contraceptive use. West J Med 1991;155:416-8.
5. Giannitrapani, L., M. Soresi, E. La Spada, M. Cervello, N. D'Alessandro, and G. Montalto. Sex hormones and risk of liver tumor. Ann. N. Y. Acad. Sci. 2006; 1089:228-36.
6. Vilgrain V. Focal nodular hyperplasia. Eur J Radiol 2006;58:236-245.
7. Heinemann, L. A. J., T. DoMinh, I. Guggenmoos-Holzmann, C.Thiel & E. Garbe: Oral contraceptives and liver cancer. Results of the multicentre international liver tumour study (MILTS). Contraception 1997a, 56, 275-84.
8. Vecchia, C. La, Tavani A. : Female hormones and benign liver tumours. Digestive and Liver Disease (38) 2006; 535-6
9. Kerlin P, Davis GL, McGill DB, Weiland LH, Adson MA, Sheedy PF. Hepatic adenoma and focal nodular hyperplasia: clinical, pathologic, and radiologic features. Gastroenterology 1983; 84(5 Pt 1):994-1002.