

Coccidioidomycosis: first cases reported in Pernambuco, Brazil

Paulo Sergio Ramos de Araújo^{1,2,3}, Valter Romão de Souza Junior², Carlos Eduardo Padilha¹, Marta Iglis de Oliveira¹, Luciana Cardoso Arraes¹, Roberto Vieira⁴, Ana Antunes⁵, Reginaldo Goncalves de Lima Neto⁶, Armando Marsden⁶

ABSTRACT

Coccidioidomycosis is a fungal infection caused by *Coccidioides immitis* or *Coccidioides posadasii*. These fungi are known to thrive in desert climate. Fungi produce infectious arthroconidia in soil, they are aerosolized in the air and when inhaled by humans, usually cause infections such as pneumonia. The first cases of coccidioidomycosis in Brazil were reported in 1978. Since then, there have been other reports mainly from desert regions of Northeastern Brazil. The present report describes three cases of coccidioidomycosis on male farmers from Serra Talhada county, Pernambuco State, who developed pneumonia and were subsequently diagnosed with pulmonary coccidioidomycosis. These three farmers were successfully treated with oral fluconazole. They reported having hunted armadillos in a rural and arid area of Pernambuco State. Armadillos are known to be carriers of *Coccidioides*. This is the first report of infection caused by *Coccidioides* in Pernambuco State, Brazil.

KEYWORDS: Coccidioidomycosis. Pneumonia. Armadillos. Brazil. *Coccidioides immitis*

BACKGROUND

Coccidioidomycosis (CDM) is a fungal infection caused by *Coccidioides immitis* or *Coccidioides posadasii*. These two species inhabit arid soil of certain American States such as California, Arizona and Texas, are also found in Mexico, as well as in Central and South America. The infection begins with the inhalation of arthroconidia from sandy and dry soil¹. Most individuals exposed to this fungus will develop only mild symptoms without significant illness. The community-acquired pneumonia is the most common presentation. Clinical findings began with fever, cough and fatigue, occasionally with arthralgia and cutaneous manifestations such as erythema nodosum. Disseminated infections can occur, especially in immunocompromised individuals². Notably in Brazil, there is a strong association between hunting armadillo and CDM³.

The first cases of CDM in Brazil were reported in Bahia State by Gomes *et al.*⁴ in 1978. In 1979, Vianna *et al.*⁵ reported another case in Piauí, while Sidrim *et al.*⁶ also reported four cases of CDM in Ceará. Other cases came from four States of the semiarid Northeast region, Bahia, Piauí, Ceará and Maranhão, but there were no reports of CDM from Pernambuco. The Northeastern Brazilian States of Bahia, Maranhão, Piauí and Ceará constitute the most recent endemic area of coccidioidomycosis (Table 1)⁷. Nevertheless, the current incidence of CDM in Brazil is unknown, because this infection is not notified to the Ministry of Health.

¹Universidade Federal de Pernambuco, Hospital das Clínicas, Serviço de Infectologia, Recife, Pernambuco, Brazil

²Universidade Federal de Pernambuco, Departamento de Medicina Tropical, Recife, Pernambuco, Brazil

³Fundação Oswaldo Cruz, Instituto Aggeu Magalhães, Recife, Pernambuco, Brazil

⁴Hospital Regional de Serra Talhada, Pernambuco, Brazil

⁵Secretaria Estadual de Saúde, Vigilância Epidemiológica, Recife, Pernambuco, Brazil

⁶Universidade Federal de Pernambuco, Departamento de Micologia, Recife, Pernambuco, Brazil

Correspondence to: Paulo Sergio Ramos de Araújo
Universidade Federal de Pernambuco, Departamento de Medicina Tropical, Av. Prof. Moraes Rego, N° 1235, Cidade Universitária, CEP 50670-901, Recife, PE, Brazil
Tel: +55 81 9972-6433

E-mail: psergiora@gmail.com

Received: 18 June 2018

Accepted: 25 October 2018

This report is to inform clinicians about the first cases of CDM in Serra Talhada county, Pernambuco State (Figure 1).

Table 1 - Number of reported cases of coccidioidomycosis by State in Northeast Brazil.

STATES	CASES REPORTED
Pernambuco (PE)	3
Maranhao (MA)	more than 10
Piauí (PI)	more than 10
Ceara (CE)	more than 10
Bahia (BA)	more than 10
Paraíba (PB)	0
Rio Grande do Norte (RN)	0
Sergipe (SE)	0
Alagoas (AL)	0

CASE PRESENTATION

Three adult males from the same family, aged 32, 40 and 71 years, farmers, reported having lived in the rural area of Serra Talhada county, Pernambuco State for all their lives. They were admitted to the Clinical Hospital of the Federal University of Pernambuco between March and April 2017. The three patients have presumably been infected at the same time, around 11 days after an armadillo (*Dasypus novemcinctus*) hunting in rural areas of Pernambuco State. Armadillos are known to be reservoir for *Coccidioides*³.

On admission, they presented with dry cough, fever, anorexia and night sweats. The chest x-ray of patient 1 showed diffuse and bilateral pulmonary nodules with

irregular and spicule-shaped lesions on chest tomography (Figures 2A and 2B). Patient 2 also had bilateral pulmonary lesions. Patient 3 had fever and transient hyperemic papular skin lesions on both forearms. Chest x-ray and tomography showed multiple diffuse and bilateral lesions in all three patients.

Bronchoscopy with bronchoalveolar lavage was performed in all three patients. Direct examination of expectorated sputum was negative for acid-fast bacilli and fungi. However, examination of induced sputum of the three patients treated with potassium hydroxide (KOH) showed multiple spherules (Figure 2C) typical of *Coccidioides spp.* Culture, as well as molecular biology tests were not performed due to limited laboratory facilities. Following the diagnostic confirmation, 400 mg/day of oral fluconazole therapy was started in all three patients who were followed up on an outpatient basis for one year before discharge. Patients have clinically improved as well as their pulmonary x-rays.

DISCUSSION

CDM or valley fever should be suspected in patients with cough and fever who live in endemic areas⁸. However, the diagnosis can be difficult in areas, such as Pernambuco State where the levels of suspicion is low as no cases of CDM have been reported so far, patients present with a variety of clinical manifestations and access to diagnostic tests is poor. CDM was difficult to diagnose because the presence of this infection was previously unknown in Pernambuco. The lack of a routine diagnostic laboratory testing specific for CDM makes the diagnosis very difficult⁹.

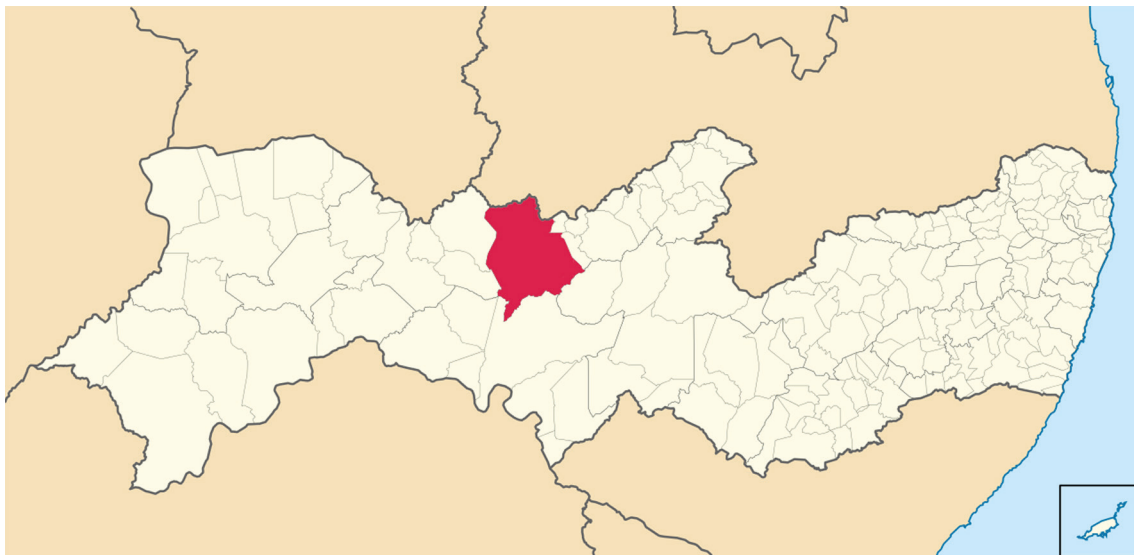

Figure 1 - Serra Talhada county, the place where the three patients acquired CDM, was highlighted within the territory of Pernambuco State.

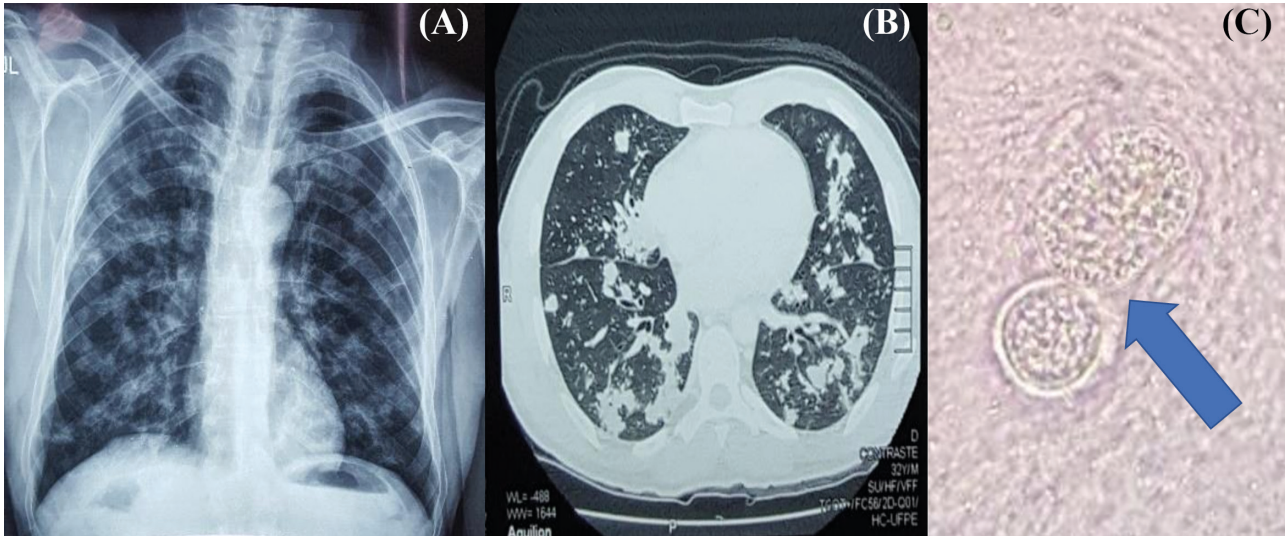


Figure 2 - A) Chest x-ray of patient one; B) Chest tomography of patient one; C) Direct examination of sputum with KOH demonstrating a spherule (arrow).

Histological lesions of both tuberculosis (TB) and CDM can be granulomatous, leading to diagnostic errors¹⁰.

Early identification of CDM has many benefits, such as relieving the patient's anxiety and ruling out the possibility of cancer, simultaneously. It also reduces the need for additional diagnostic testing by eliminating the empirical use of antibiotics and reducing morbidity due to extrapulmonary complications^{10,11}. This infection can have serious consequences in immunocompromised individuals from endemic areas, including patients undergoing chemotherapy for malignancies, those infected by HIV, among others¹⁰.

All three patients lived in Serra Talhada county, in the semiarid region, in the shade of the Borborema Plateau which blocks the rain, throwing a "shade" of dryness behind them. In this region, the mean temperature (23.8 °C) and the annual rainfall (16 cm/year) during rainy season (January to April) are favorable conditions for *Coccidioides*¹². Furthermore, this is an agricultural region, whose main product is cotton¹².

Endemic areas of *Coccidioides* usually have annual temperatures between 0.5 °C and 24.4 °C, low annual rainfall and hot summers. They also tend to be at lower altitudes, in sandy soil areas¹³. However, Serra Talhada county is situated at 444 m altitude¹²; thus suggesting that high altitude is not a major determinant for *Coccidioides* growth. Local environmental conditions and the participation of agricultural workers in armadillo hunting have led to the suspicion that exposures have occurred during activities that resulted in soil disruption, in several locations of Serra Talhada county.

Animals such as dogs and cats are carriers of *Coccidioides*, which explains why organisms can be

found in non-endemic areas¹³. Mechanisms by which dissemination of *Coccidioides* spreads through animals is not fully understood. Some studies suggested that carcasses of infected animals may carry *Coccidioides* and, therefore, this fungus can be dispersed in soil for long distances through the wind. The migration of infected mammals and birds contributes to fungi dispersal in the environment¹³.

Standardized tests are available to diagnose *Coccidioides* infection. The test of choice will depend on clinical circumstances¹⁴. Most outpatients suspected of having CDM can be evaluated by serological tests such as enzyme immunoassays (EIA) for specific anti-IgM and anti-IgG detection¹⁴. The use of molecular techniques allows the genotyping of *Coccidioides* isolates, improving the understanding of their mode of reproduction, genetic variation and speciation. We did not have access to serological tests or the isolation of fungi by cultures; therefore, spherules detection using potassium hydroxide on the sputum sample was the diagnostic method for MDC. Most *Coccidioides* infections are not treated in hospitals or other health facilities because most people have subclinical manifestations and do not seek medical attention¹⁵. For those who develop a primary clinical infection, it manifests most frequently as pneumonia about 7 to 21 days after exposure¹⁴. The most common symptoms are chest pain, cough and fever, which were reported by our patients 1 and 2, as well as fever, night sweats and weight loss². Some patients also develop systemic complaints such as fatigue that can persist post-infection for months, interfering with daily routine activities¹⁶. Only patient 3 complained of skin rashes and joint pain. Persistent arthralgia associated with this infection characterize the alternative name of

this disease, the desert rheumatism. Common cutaneous manifestations in primary infection with *Coccidioides* include erythema nodosum and erythema multiforme¹⁵.

Although there are no randomized controlled trials to determine whether antifungal therapy improves the outcome of uncomplicated infections, it can prevent complications in patients with severe infections or at increased risk of dissemination¹⁷. We started antifungal therapy according to the guidelines of the Infectious Diseases Society of North America (IDSA)¹⁵.

Further studies are needed to determine the presence of new outbreaks of *Coccidioides* in Pernambuco State. The history and laboratory work on our three cases pointed to newly acquired infections, presumably related to exposure to some *Coccidioides* habitats. It is well known that armadillos are susceptible to *Coccidioides* infections³. CDM was not initially suspected because there were no previous reports of coccidioidomycosis in Pernambuco State.

CONCLUSION

From now on physicians and other health professionals should be aware that CDM can occur in Pernambuco State. Physicians should strongly suspect CDM especially in patients with fever and abnormal chest X-rays. It is likely that all States in Northeastern Brazil harbor *Coccidioides*. New skin tests need to be developed and used to define the current prevalence of CDM in Northeastern Brazil.

CONSENTS

The three patients have signed informed consents to participate in this study and for publishing the case report and the accompanying images

CONFLICT OF INTERESTS

The authors declared no potential conflicts of interest with respect to the research, authorship and/or publication of this case report.

DATA AVAILABILITY AND MATERIALS

Data supporting the findings of this study are available in the Clinical Hospital of UFPE, but restrictions may apply to data availability. Data were used under license for this study, and as so they are not publicly available. However, data are made available by the authors upon reasonable request and with permission of the Clinical Hospital of UFPE.

FUNDING

There is no funding for this publication.

REFERENCES

1. Shah RA, Vempilly JJ, Noor UI, Husnain SM, Hegde P. Combined endosonography reduces time to diagnose pulmonary coccidioidomycosis. *J Bronchology Interv Pulmonol*. 2018;25:152-5.
2. Malo J, Luraschi-Monjagatta C, Wolk DM, Thompson R, Hage CA, Knox KS. Update on the diagnosis of pulmonary coccidioidomycosis. *Ann Am Thorac Soc*. 2014;11:243-53.
3. Brillhante RS, Moreira Filho RE, Rocha MF, Castelo-Branco DS, Fechine MA, Lima RA, et al. Coccidioidomycosis in armadillo hunters from the State of Ceará, Brazil. *Mem Inst Oswaldo Cruz*. 2012;107:813-5.
4. Gomes OM, Serrano RP, Pradel HO, Barros Moraes NL, Varella AL, Fiorelli AI, et al. Coccidioidomycose pulmonar: primeiro caso nacional. *Rev Assoc Med Bras*. 1978;24:167-8.
5. Vianna H, Passos HV, Sant'ana AV. Coccidioidomycose: relato do primeiro caso ocorrido em nativo do Brasil. *Rev Inst Med Trop São Paulo*. 1979;21:51-5.
6. Sidrim JJ, Silva LC, Nunes JM, Rocha MF, Paixão GC. Le Nord-Est Brésilien; région d'endémie de coccidioidomycose? A propos d'une micro-épidémie. *J Mycol Med*. 1997;7:37-9.
7. Cordeiro RA, Brillhante RS, Rocha MF, Bandeira SP, Fechine MA, de Camargo ZP, et al. Twelve years of coccidioidomycosis in Ceará State, Northeast Brazil: epidemiologic and diagnostic Aspects. *Diagn Microbiol Infect Dis*. 2010 Jan;66:65-72.
8. Garoon RB, Foroozan R, Vaphiades MS. Don't drink in the valley. *Surv Ophthalmol*. 2017;62:383-6.
9. Chin D, Wada K, Holmes WN, Singh J. Mimicking the great mimicker: disseminated coccidioidomycosis masquerading as classic tuberculosis. *J Pediatr Infect Dis*. 2014;9:109-14.
10. Martinez-Del-Campo E, Kalb S, Rangel-Castilla L, Moon K, Moran A, Gonzalez O, et al. Spinal coccidioidomycosis: a current review of diagnosis and management. *World Neurosurg*. 2017;108:69-75.
11. Malik U, Cheema H, Kandikatla R, Ahmed Y, Chakrala K. Disseminated coccidioidomycosis presenting as carcinomatosis peritonei and intestinal coccidioidomycosis in a patient with HIV. *Case Rep Gastroenterol*. 2017;11:114-9.
12. Instituto Brasileiro de Geografia e Estatística. Serra Talhada. [cited 2018 Jul 18]. Available from: https://biblioteca.ibge.gov.br/visualizacao/periodicos/2980/momun_ne_pe_serratalhada.pdf
13. Del Rocío Reyes-Montes M, Pérez-Huitrón MA, Ocaña-Monroy JL, Frías-De-León MG, Martínez-Herrera E, Arenas R, et al. The habitat of *Coccidioides* spp. and the role of animals as reservoirs and disseminators in nature. *BMC Infect Dis*. 2016;16:550.

14. Gabe LM, Malo J, Knox KS. Diagnosis and management of coccidioidomycosis. *Clin Chest Med.* 2017;38:417-33
15. Galgiani JN, Ampel NM, Blair JE, Catanzaro A, Geertsma F, Hoover SE, et al. 2016 Infectious Diseases Society of America (IDSA) Clinical Practice Guideline for the Treatment of Coccidioidomycosis. *Clin Infect Dis.* 2016;63:e112-46.
16. Stockamp NW, Thompson GR 3rd. Coccidioidomycosis. *Infect Dis Clin North Am.* 2016;30:229-46.
17. Ampel NM. The treatment of coccidioidomycosis. *Rev Inst Med Trop Sao Paulo.* 2015;57 Suppl 19:51-6.