

Complications of chronic necrotizing pulmonary aspergillosis: review of published case reports

Aleksandra Barac¹, Tatjana Adzic Vukicevic^{2,3}, Aleksandra Dudvarski Ilic^{2,3},
Salvatore Rubino⁴, Vladimir Zugic^{2,3}, Goran Stevanovic^{1,2}

ABSTRACT

Chronic necrotizing pulmonary aspergillosis (CNPA), a form of chronic pulmonary aspergillosis (CPA), affects immunocompetent or mildly immunocompromised persons with underlying pulmonary disease. These conditions are associated with high morbidity and mortality and often require long-term antifungal treatment. The long-term prognosis for patients with CNPA and the potential complications of CNPA have not been well documented. The aim of this study was to review published papers that report cases of CNPA complications and to highlight risk factors for development of CNPA. The complications in conjunction associated with CNPA are as follows: pseudomembranous necrotizing tracheobronchial aspergillosis, ankylosing spondylarthritis, pulmonary silicosis, acute respiratory distress syndrome, pulmonary Mycobacterium avium complex (MAC) disease, superinfection with Mycobacterium tuberculosis, and and pneumothorax. The diagnosis of CNPA is still a challenge. Culture and histologic examinations of bronchoscopically identified tracheobronchial mucus plugs and necrotic material should be performed in all immunocompromised individuals, even when the radiographic findings are unchanged. Early detection of intraluminal growth of *Aspergillus* and prompt antifungal therapy may facilitate the management of these patients and prevent development of complications.

KEYWORDS: Chronic necrotizing pulmonary aspergillosis. Complications. *Aspergillus*.

INTRODUCTION

Aspergillus infection of the lung manifests in a wide spectrum of conditions ranging from saprophytic colonization to hypersensitivity reactions to necrotizing pneumonia with angioinvasion¹. In the saprophytic form of the disease, aspergillomas establish themselves in pre-existing cavities. The chronic cavitary form of aspergillosis, which produces a slowly progressive infiltrate that may include mycetoma, was proposed in 1981 as a new category of semi-invasive pulmonary² or chronic necrotizing pulmonary aspergillosis (CNPA)³. CNPA is a form of chronic pulmonary aspergillosis (CPA), often presenting with rapid progressive infection (< 3 months) in moderately immunocompromised patients, which should be managed as invasive aspergillosis¹. *Aspergillus* has a propensity to invade pulmonary blood vessels, resulting in pulmonary infarction and subsequent development of necrotic cavities and bronchus dilatation⁴. Lung conditions affecting the pulmonary defense system, such as previous surgical resection, ionizing radiation therapy, or chronic obstructive pulmonary disease (COPD), allow *Aspergillus* to penetrate the lung through enzyme secretion despite the absence of cavities⁵. In addition to COPD, other conditions commonly associated with CNPA include previous pulmonary

⁽¹⁾ Clinical Centre of Serbia, Clinic for Infectious and Tropic Diseases, Belgrade, Serbia

⁽²⁾ University of Belgrade, School of Medicine, Belgrade, Serbia

⁽³⁾ Clinical Centre of Serbia, Clinic for Pulmonology, Belgrade, Serbia

⁽⁴⁾ University of Sassari, Department of Biomedical Sciences, Sassari, Italy

Correspondence to: Aleksandra Barac. Clinical Centre of Serbia, Clinic for Infectious and Tropic Diseases, Bulevar Oslobođenja 16, 11000, Belgrade, Serbia.

E-mail: aleksandrabarac85@gmail.com

Received: 6 November 2016

Accepted: 9 March 2017

tuberculosis (TB), atypical *Mycobacterium tuberculosis* infection, cystic fibrosis, pulmonary infarction, pulmonary fibrosis, previous surgery, and pneumoconiosis⁶⁻⁸. Other conditions that may be associated with the development of CNPA include lung cancer, stage III or IV fibrocystic pulmonary sarcoidosis, and silicosis⁶⁻⁸. Other immunosuppression conditions such as diabetes mellitus, malnutrition, alcoholism, connective tissue diseases, and prolonged corticosteroid therapy also increase the risk for development of CNPA^{1,2}. Complications of CNPA usually occur because of leakage of air from an air-filled lung cavity into the pleural space. These conditions are associated with high morbidity and mortality and often require long-term antifungal treatment⁹. The long-term prognosis for patients with CNPA and potential complications of CNPA have not been well documented. The aim of this study was to review published papers reporting cases of CNPA complications and to highlight risk factors for development of CNPA.

Pseudomembranous necrotizing tracheobronchial aspergillosis and CNPA

The Oh *et al.*¹⁰ reported a case of pseudomembranous necrotizing tracheobronchial aspergillosis in an immunocompetent host. They reported a rare case of *Aspergillus* pseudomembranous tracheobronchitis without an invasion of the pulmonary parenchyma that developed in an immunocompetent patient¹⁰. *Aspergillus* tracheobronchitis was confined, at least initially, to the airways with only a superficial mucosal invasion, and the diagnosis was delayed because of non-specific signs, symptoms, and lack of radiographic abnormalities¹¹. Pseudomembranous necrotizing tracheobronchial aspergillosis has been reported recently as an uncommon form of airway invasive aspergillosis in immunocompromised patients^{10,12-15}. In a review of the literature on *Aspergillus* tracheobronchitis, including all forms of tracheobronchial involvement, reports indicated that the disease was progressive and fatal in about 40% of cases^{10,13-15}. This was apparently a lethal variant of tracheobronchial aspergillosis with a markedly higher mortality rate and more parenchymal lung involvement (65%) compared with all cases of *Aspergillus* tracheobronchitis (45%)^{10,15}. It presents an extensive transmural necrotizing bronchitis with pseudomembrane formation that develops in immunocompromised patients, and it is usually characterized by a limited extension of inflammation and hyphae into the peribronchial tissue, without an invasion of the pulmonary parenchyma^{10,12}. Involvement of the bronchial tree can be invasive, leading to a pseudomembranous tracheobronchitis with extensive

bronchial hemorrhage and invasion of the bronchial walls and vessels. In the literature review, we found reports of 22 cases with this variant of tracheobronchial involvement by *Aspergillus*¹²⁻¹⁵. There are published only five reports of this disease developing in an immunocompetent or mildly immunocompromised patient. The first case revealed cutaneous anergy and lymphopenia involving T cells and NK cells, related to a recent influenza A infection¹⁶. In the second case, there were “grayish” mucus plugs in several segmental bronchi on autopsy and focally limited extension into the adjacent lung parenchyma¹⁷. The third case revealed the presence of fungal invasion through the bronchial wall into the adjacent lung parenchyma and pulmonary arteries¹⁷. The fourth case was a 70-year-old man with many risk factors, including corticosteroid use. The fifth case was a 66-year-old with underlying COPD¹⁷. This patient had no risk factors associated with an immunocompromised state, and had no invasion of the parenchyma, or atelectasis, but his condition rapidly progressed to severe CO₂ retention and respiratory failure. Pseudomembranous necrotizing tracheobronchial aspergillosis should be considered as potential complication of CNPA even in an immunocompetent host^{10,15,16}.

Ankylosing spondylarthritis and CNPA

Fibro-bullous disease is a late complication of ankylosing spondylarthritis^{17,18}. Its radiologic features frequently mimics tuberculosis or excavated neoplasm. About 50 to 65% of patients with ankylosing spondylarthritis have chronic *Aspergillus* colonization of their airways¹⁷. Pulmonary aspergillosis infection occurs in 10 to 30% during evolution. Pontier *et al.* reported two cases of patients with spondylarthritis who developed chronic necrotizing pulmonary aspergillosis¹⁷. Diagnosis was based on serology, mycologic examination of expectoration and in one case, on histology obtain by transbronchial biopsies. Pulmonary complications due to *Aspergillus* species frequently reveal associated fibro-bullous disease in patients with ankylosing spondylarthritis. The fibroblastic disease is often asymptomatic and, as in the reported cases, its clinical revelation is often linked to a complication (bacterial or fungal infections, tuberculosis, pneumothorax, etc.). In one case, it was associated with unilateral, pseudo-tuberculosis, with a preferential apical location and pleural involvement. In cases with ankylosing spondylarthritis and CNPA, there is usually bilateral and asymmetric pachypleuritis¹⁷⁻¹⁹. This is a rare complication of spondylitis in about 1.3% of patients¹⁸, with male predominance and it is estimated that it is revealed on average 17 years after the spinal signs. There

is no specific predictive factor (HLA B27 antigen positive in 50% of cases)¹⁸. The two patients reported by Pontier *et al.*¹⁷, had no previously known pulmonary pathology¹⁷. At the anatomo-pathologic level, lesions of inter-alveolar fibrosis with hyaline fibrosis and non-specific lymphocytic and macrophage infiltrates were found¹⁷. The origin of this fibrosis is currently unknown but several hypotheses have been suggested: an inflammatory fibrosis aggravated or caused by repeated infectious episodes, a hypoventilation of the apexes favored by the restrictive syndrome and systemic inflammatory attack comparable with the involvement of other organs¹⁷⁻¹⁹. The evolution can be towards chronic respiratory insufficiency.

Semi-invasive pulmonary aspergillosis or CNPA occurs in 10-30% of cases of fibroblastic disease. It is a frequent mode of revelation¹⁷⁻¹⁹. Unlike aspergilloma, there is no pre-existing cavity, and no walls are built. It is probably favored by hypoventilation of the vertices during spondylitis. It may develop into fibroblastic sequelae. The question arises as to whether fibroblastic disease is a sequela of semi-invasive pulmonary aspergillosis or pre-existing in asymptomatic form. In both cases, semi-invasive aspergillosis is manifested as severe broncho-pneumonia, resistant to antibiotics, and potentially fatal¹⁷. The general clinical sign predominates and distinguishes it from aspergilloma. Pontier *et al.*¹⁷ describe the acute form, evolving in a few weeks towards pneumonic block and signs of suppuration, and sub-acute form, with a pseudo-tuberculous picture evolving towards necrosis. In the cases presented by Pontier *et al.*¹⁷, a radio-clinical picture of intra-cavitary aspergillosis was demonstrated after favorable response to antifungal treatment. Although cases of isolated aspergilloma have been described in patients with ankylosing spondylitis with fibroblastic lesions¹⁷⁻¹⁹, in the two cases published by Pontier *et al.*¹⁷, were probably a result of low-lying progression of semi-invasive aspergillosis previously incompletely controlled by medical treatment.

Pulmonary silicosis and CNPA

Blanco *et al.*²⁰ reported three cases with a long history of exposure to silica dust with pulmonary aspergillosis complicated by progressive massive fibrosis (PMF)²⁰. Pneumoconiosis, which causes deterioration of local immunity, is less frequent, limited to 2% and 3% of cases^{21,22}. The three cases presented by Blanco *et al.*²⁰ presented had a history of tuberculosis, which was variably described in the literature (between 11% and 93%)^{21,22}. Frequent treatment with steroids in the first patient and a history of alcoholism in the second patient probably contributed to the predisposition for CNPA²⁰. On the other

hand, all three had been active smokers²⁰, a history referred to in 53% of the patients reported by Nam *et al.*²³ but not mentioned in the other series. Compared with Nam *et al.*²³ reports, in which the youngest patient was 48 years old and only 20% had large opacities, patients reported by Blanco *et al.*²⁰ were younger and PMF was observed in all three cases. These patients usually present with fever, cough and weight loss, and less frequently dyspnea or chest pain. The three patients reported by Blanco *et al.*²⁰ had hemoptysis and mycetoma²⁰, which is reported in 49% and 90% of cases in the literature²¹⁻²³. Radiologically, the presence of infiltrates in the upper lobes, cavitation, nodular opacities, and pleural thickening are the most common findings that coincide with silicosis in patients with CNPA²⁰⁻²³.

CNPA can be serious, fatal if untreated, and may be accompanied by acute respiratory distress syndrome²³⁻²⁴. CNPA can also play a relevant role in the mortality of patients with silicosis. The study by Iossifova *et al.*²⁵ showed that people with CNPA and silicosis are almost 10 times more likely to die than people without silicosis. In addition, in young patients, lung transplantation could be contraindicated, as shown in the first case reported by Blanco *et al.*²⁰.

Given the high mortality, the diagnosis of CNPA in patients with silicosis should be considered as soon as possible, especially if there are any signs of new infiltrates, mycetomas, and anamnestic data of active smoking or a history of TB²⁰⁻²⁴.

Acute respiratory distress syndrome and CNPA

Yano²⁴ published a report of a patient with acute respiratory distress syndrome (ARDS) who died because of CNPA. This patient had pulmonary fibrosis of unknown cause with a right upper bulla. Mycetoma in the bulla, invaded the tissue adjacent to the bulla, as the wall of the right upper bulla became thicker with surrounding lung infiltration²⁴. This patient developed ARDS because of CNPA after *Aspergillus* invaded these tissues leading to fatal respiratory failure. The patient had a cerebral accident 6 days after respiratory failure, probably as a result of septic emboli accompanied with CNPA. Depending on the size of the emboli, nuclear magnet resonance (NMR) findings may vary from major arterial branch infarction to multiple small abscesses located at the gray-white matter junction, secondary to occlusion of small arteries and arterioles^{25,26}. Small abscesses are accompanied by surrounding oedema and mass effect, which is well demonstrated on NMR¹. One day before the first cerebral accident in case reported by Yano²⁴, the percentage of serum eosinophils increased to 13%; after the first cerebral attack, the increased percentage

of eosinophils persisted at around 13-22%. This peripheral eosinophilia may reflect activation of the lung aspergillus lesion. It is important to consider that ARDS may occur in cases of CNPA and that peripheral eosinophilia might forebode worsening of CNPA²⁴⁻²⁸.

Pulmonary *Mycobacterium avium* complex disease and CNPA

Pulmonary aspergilloma is an important complication occurring in cavities remaining after pulmonary TB, and it has been reported as a complication in 15% of patients with sequelae of pulmonary TB²⁸⁻³⁰. Although the most frequent underlying disease with pulmonary aspergillosis was pulmonary TB²⁹, there are no detailed reports regarding the formation of pulmonary aspergilloma including CNPA with a fungus ball in a cavity formed by pulmonary *Mycobacterium avium* intracellular complex (MAC). Kobashi *et al.*³⁰ reported a case of CNPA in which a fungus ball appeared in a growing cavity transitionally formed by pulmonary MAC, during a follow-up period after treatment³⁰. The most frequently reported underlying disease in cases of pulmonary aspergilloma including CNPA is sequela of pulmonary TB (25-72%), secondary to a pre-existing intrapulmonary cavity such as a pulmonary cyst^{29,31,32}. There have been a few reports of superinfection by *Aspergillus* spp. of pulmonary lesions caused by *Mycobacterium xenopi*^{33,34}. However, the frequency of nontuberculous mycobacteria (MAC, etc.) has recently increased among patients with pulmonary mycobacterial diseases, especially in industrialized nations²⁹. In addition, there are many cases in previous reports in which the underlying disease of pulmonary aspergilloma including CNPA was a cavity formed by a pulmonary nontuberculous mycobacterial, rather than a cavity formed by pulmonary TB²⁹⁻³⁴. The clinical symptoms caused by pulmonary aspergilloma vary in accordance with the severity of the underlying pre-existing pulmonary disease, but a common characteristic has been hemoptysis or haemoptysis²⁹⁻³⁴. The chief complaint in the case presented by Kobashi *et al.*³⁰ was continuous fever, which suggests that the patient probably developed the condition, which suddenly destroyed the lung, as semi-invasive pulmonary aspergillosis or CNPA, rather than pulmonary aspergilloma. Denning³¹ also reported that patients with pulmonary aspergilloma with clinical symptoms such as fever and cachexia usually have undiscovered CNPA, rather than pulmonary aspergilloma. The patient presented by Denning³¹ had a mixed infection caused by *A. niger* and *M. avium*, although it has been commonly mentioned that *A. fumigatus* is the most frequent isolate from patients with CNPA. Kawamura *et al.*³⁰ and

Perfect *et al.*³² reported isolation rates of *A. fumigatus* of 75% and 80%, respectively; the rates for *A. niger* were 9% and 10%, respectively.

With regard to the laboratory findings, it has been reported³²⁻³⁵ that tumor markers (carcinoembryonic antigen, squamous cell carcinoma antigen, carbohydrate antigens sialyl Lewis, and sialyl SSEA-1) are often increased in several benign diseases such as pulmonary mycobacterial diseases, and the percentage increase of these tumor marker is 15-62%. Histologically, these tumor markers were expressed in mucous cells of the bronchial gland and the surface of bronchiolar surface epithelium cells^{29,31-33}. Consequently, it is suspected that serum tumor markers are increased in cases of hyperplasia of bronchiolar epithelium cells or mucous cells of bronchial gland, because of the existing chronic respiratory infection with bronchiectasis caused by pulmonary MAC^{29,31-33}. The case presented by Kobashi *et al.*³⁰ serves as a reminder that pulmonary nontuberculous mycobacterial disease has become one of the underlying pulmonary diseases complicated by CNPA. In order to detect fast CNPA with a fungus ball as a complication, it is important to perform periodic radiological examinations (chest computed tomography [CT]), serological examinations (anti-*Aspergillus* antibody) and sputum culture examinations during the follow-up period of an underlying respiratory disease²⁹⁻³⁴.

Superinfection by *Mycobacterium tuberculosis* and CNPA

Although aspergillosis is commonly found in old tuberculous cavities, pulmonary aspergillosis is rarely complicated by active pulmonary TB^{34,35}. Kohno *et al.*³⁶ presented a rare case of CNPA complicated by active pulmonary TB. The case is unusual because the necrotic granuloma of aspergillosis contained a few acid-fast bacilli in the necrotic foci. Colonization of pre-existing TB pulmonary lesions by *Aspergillus* species is well known; however, superinfection by *Aspergillus* of a cavity already infected by *Mycobacterium* is rare³⁴. Binder *et al.*³ reported a case of CNPA with a moderate number of acid-fast bacilli, but commented that this might have been colonization by non-tuberculosis mycobacteria. Because the necrotic granuloma consisted mainly of *Aspergillus* hyphae, it is more likely that aspergillosis was the main lesion with *M. tuberculosis* superinfection. It is impossible to completely rule out the possibility that this case was an instance of aspergillosis invading a healed tuberculous lesion, but the pathologic features of CNPA are unique and characteristic³⁴. Superinfection of CNPA with *Xanthomonas maltophilia* has also been reported, but it is rare³.

Pneumothorax and CNPA

Adzic-Vukovic *et al.* reported a rare and unusual case of pneumothorax in an immunocompetent patient with CNPA³⁵. To our knowledge, this is the first reported case in Europe. A 40-year old woman, with body mass index less than 15 kg/m² and high-grade fever developed symptoms of acute onset of breathlessness, dry cough, and chest pain on the left side. The left side of the chest was hyper-resonant and breath sounds were weak. Laboratory results excluded common variable immune deficiencies, but on the other hand, the patient could not be considered as clinically immunocompetent because she had end-stage COPD and cachexia. Radiography showed a left-sided pneumothorax with contralateral cavitation and an intercostal drainage underwater seal was applied (Figure 1). Four days later, CT scan of the thorax indicated the presence of possible necrotizing lesions bilaterally (Figure 1). Fiber-optic bronchoscopy was done and a tissue sample was taken. Serological analyses revealed a positive galactomannan index (2.19) in bronchoalveolar lavage (BAL), as well as a positive value for anti-*Aspergillus* IgG Ab in serum (280 UI/mL). Patho-histologic analyses of the tissue sample confirmed the presence of fungal hyphae, and culture was positive for *A. fumigatus* (Figure 1). The patient responded positively to antifungal therapy; her general condition improved with rapid radiographic improvement in 2 weeks. During a follow-up period of 1 year, there was no disease regression³⁵.

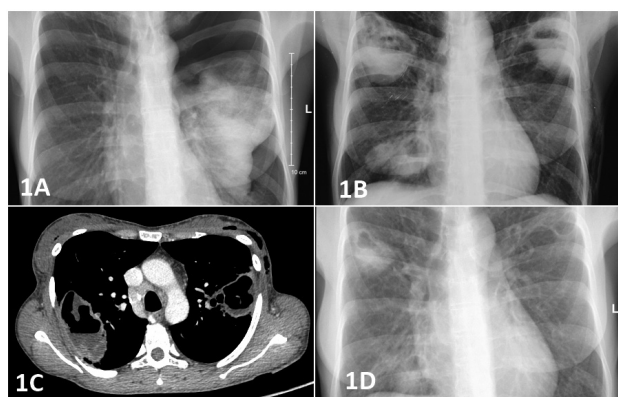


Figure 1 - 1A) Left sided pneumothorax with a contralateral cavitation; 1B) Bilateral cavity lesions; 1C) Computed tomography scan showed bilateral necrotising pulmonary lesions; 1D) Radiographic regression after two weeks of voriconazole treatment.

Pneumothorax as a result of rupture of aspergilloma into the pleural space in non-immunocompromised patients is extremely rare⁸. Pneumothorax has been reported in granulocytopenic patients undergoing intensive cytotoxic therapy for hematologic malignancies⁸. In this case, the

patient was immunocompetent according to the laboratory parameters, but clinically she was immunocompromised with end-stage COPD and cachexia³⁵. Surprisingly, the patient developed pneumothorax as a complication of the rupture of aspergilloma into the pleural space. Long-term weight loss, low body mass index and untreatable end-stage COPD should be considered as possible cause of spontaneous pneumothorax in this patient. Pneumothorax increases both short-and long-term morbidity and mortality in patients with CNPA and causes significant deterioration of their quality of life. This case highlights that a diagnosis of CNPA should be considered in patients with end-stage COPD, a low body mass index, or patients who develop pneumothorax.

CONCLUSION

Diagnosis of CNPA is still a challenge. A chest radiograph is not helpful to the diagnosis for several reasons: (1) usually because of normal radiologic findings, intraluminal mycetomas may not be readily detectable, (2) *Aspergillus* may enlarge so rapidly that recent chest radiographs may not reveal atelectasis, and (3) the lung parenchyma is usually unaffected³⁷. A chest CT scan is much more helpful in the early diagnosis and aids further diagnostic studies, such as bronchoscopies and open-lung biopsies. Although a CT scan is helpful in the diagnosis of airway aspergillosis, diagnosis of this specific disease cannot be made based on imaging features alone. Bronchoscopy, apart from providing specimens for microbiological examination, is a useful method for detecting infections with endobronchial manifestations³⁷. It should be recommended as early as possible for diagnosis and to maintain airway patency, at a time when it is most feasible³⁷⁻³⁹. A presumptive diagnosis is made when the fungus is isolated from bronchial aspirates or BAL cultures, and a definitive diagnosis is made when there is histologic demonstration of invasion of the mucosa by hyphae³⁷⁻³⁹. Therefore, culture and histologic examinations of bronchoscopically identified tracheobronchial mucus plugs and necrotic material should be performed in all immunocompromised individuals, even when the radiographic finding are unchanged. Early detection of intraluminal growth of *Aspergillus* and prompt antifungal therapy may facilitate the management of these patients and prevent development of complications.

ACKNOWLEDGEMENT

The paper has been published with the support of the Ministry of Education, Science and Technology of the Republic of Serbia (Project No. III45005).

CONFLICT OF INTERESTS

Authors declare there is no conflict of interests.

REFERENCES

- Denning DW, Cadranel J, Beigelman-Aubry C, Ader F, Chakrabarti A, Blot S, et al. Chronic pulmonary aspergillosis: rationale and clinical guidelines for diagnosis and management. *Eur Respir J*. 2016;47:45-68.
- Gefter WB, Weingrad TR, Epstein DM, Ochs RH, Miller WT. "Semi-invasive" pulmonary aspergillosis: a new look at the spectrum of aspergillus infections of the lung. *Radiology*. 1981;140:313-21.
- Binder RE, Faling LJ, Pugatch RD, Mahasaen C, Snider GL. Chronic necrotizing pulmonary aspergillosis: a discrete clinical entity. *Medicine (Baltimore)*. 1982;61:109-24.
- Pittet D, Huguenin T, Dharan S, Sztajzel-Boissard J, Ducloux G, Thorens JB, et al. Unusual cause of lethal pulmonary aspergillosis in patients with chronic obstructive pulmonary disease. *Am J Respir Crit Care Med*. 1996;154:541-4.
- Kibbler CC, Milkins SR, Bhamra A, Spiteri MA, Noone P, Prentice HG. Apparent pulmonary mycetoma following invasive aspergillosis in neutropenic patients. *Thorax* 1988;43:108-12.
- Attaway AH, Jacono F, Gilkeson R, Faress JA. Subacute invasive pulmonary aspergillosis associated with ankylosing spondylitis. *Am J Respir Crit Care Med*. 2016;193:572-3.
- Peghin M, Ruiz-Camps I, Garcia-Vidal C, Cervera C, Andreu J, Martin M, et al. Unusual forms of subacute invasive pulmonary aspergillosis in patients with solid tumors. *J Infect*. 2014;69:387-95.
- Gupta PP, Fotedar S, Agarwal D, Magu S, Saini K. Pneumothorax: a rare presentation of pulmonary mycetoma. *Ann Thorac Med*. 2007;2:171-2.
- Walsh TJ, Anaissie EJ, Denning DW, Herbrecht R, Kontoyiannis DP, Marr KA, et al. Treatment of aspergillosis: clinical practice guidelines of the Infectious Disease Society of America. *Clin Infect Dis*. 2008;46:327-60.
- Oh HJ, Kim HR, Hwang KE, Kim SY, Ahn SH, Yang SH, et al. Case of pseudomembranous necrotizing tracheobronchial aspergillosis in an immunocompetent host. *Korean J Intern Med*. 2006;21:279-82.
- Sayiner A, Kursat S, Toz H, Duman S, Onal B, Tumbay E. Pseudomembranous necrotizing bronchial aspergillosis in a renal transplant recipient. *Nephrol Dial Transplant*. 1999;14:1784-5.
- Ahn MI, Park SH, Kim JA, Kwon MS, Park YH. Pseudomembranous necrotizing bronchial aspergillosis. *Br J Radiol*. 2000;73:73-5.
- Silveira F, Paterson DL. Pulmonary fungal infections. *Curr Opin Pulm Med*. 2005;11:242-6.
- Kim JS, Rhee Y, Kang SM, Ko WK, Kim YS, Lee JG, et al. A case of endobronchial aspergilloma. *Yonsei Med J*. 2000;41:422-5.
- Clarke A, Skeleton J, Fraser RS. Fungal tracheobronchitis: report of 9 cases and review of the literature. *Medicine (Baltimore)*. 1991;70:1-14.
- Boots RJ, Paterson DL, Allworth AM, Faoagali JL. Successful treatment of post-influenza pseudomembranous necrotizing bronchial aspergillosis with liposomal amphotericin, inhaled amphotericin B, gamma interferon and GM-CSF. *Thorax*. 1999;54:1047-9.
- Pontier S, Bigay L, Doussau S, Recco P, Lacassagne L, Didier A. Aspergillose pulmonaire nécrisante chronique et spondylarthrite ankylosante. *Rev Mal Respir*. 2000;17:683-6.
- Peltier P, Germaud P, Martin M, Barrier J, Cottin S, Grolleau JY. Fibrose pulmonaire et pelvi-spondylite rhumatismale: à propos de 5 cas. *Sem Hop*. 1982;58:596-600.
- Bourgeois P. Manifestations systémiques de la spondylarthrite ankylosante. In: Kahn MF, Peltier AP, Meyer O, Piette JC, éditeurs. *Les maladies systémiques*. 3^{ème} ed. Paris: Médecine-Sciences Flammarion; 1991. p.839-55.
- Blanco JJ, Barcala FJ, Moure MA, Mao MC. Aspergilosis pulmonar necrotizante crónica como complicación de silicosis. *An Sist Sanit Navar*. 2011;34:109-14.
- Hohl TM, Feldmesser M. *Aspergillus fumigatus*: principles of pathogenesis and host defense. *Eukaryot Cell*. 2007;6:1953-63.
- Denning DW, Riniotis K, Dobrashian R, Sambatakou H. Chronic cavitary and fibrosing pulmonary and pleural aspergillosis: case series, proposed nomenclature change, and review. *Clin Infect Dis*. 2003;37 Suppl 3:S265-80.
- Nam HS, Jeon K, Um SW, Suh GY, Chung NP, Kim H, et al. Clinical characteristics and treatment outcomes of chronic necrotizing pulmonary aspergillosis: a review of 43 cases. *Int J Infect Dis*. 2010;14:e479-82.
- Yano S. Acute respiratory distress syndrome due to chronic necrotizing pulmonary aspergillosis. *Intern Med*. 2007;46:889-91.
- Iossifova Y, Bailey R, Wood J, Kreiss K. Concurrent silicosis and pulmonary mycosis at death. *Emerg Infect Dis*. 2010;16:318-20.
- Parker JC Jr, Dyer MC. Neurologic infections due to bacteria, fungi, and parasites. In: Davis RL, Robertson DM, editors. *Textbook of neuropathology*. Baltimore: Williams & Wilkins; 1985. p. 632-703.
- Whiteman ML, Boman BC, Post MJ, Bell MD. Intracranial infection. In: Atlas SW, editor. *Magnetic resonance imaging of the brain and spine*. 2nd ed. New York: Raven; 1996. p.729-32.
- Alan MS, Elizabeth AO. Aspergillus syndrome, mucormycosis and pulmonary candidiasis. In: Fishman AP, editor. *Fishman's pulmonary diseases and disorders*. 3rd ed. New York: McGraw-Hill; 1998. p.2265-8.

29. Kawamura S, Maesaki S, Tomono K, Tashiro T, Kohno S. Clinical evaluation of 61 patients with pulmonary aspergilloma. *Intern Med.* 2000;39:209–12.
30. Kobashi Y, Yoshida K, Miyashita N, Niki Y, Matsushima T. Chronic necrotizing pulmonary aspergillosis complicated by a cavitary lesion caused by Pulmonary Mycobacterium-avium complex disease. *Intern Med* 2005; 44(3):246-50.
31. Denning DW, Pleuvry A, Cole DC. Global burden of chronic pulmonary aspergillosis complicating sarcoidosis. *Eur Respir J.* 2013;41:621-6.
32. Perfect JR, Cox GM, Lee JY, Kauffman CA, de Repentigny L, Chapman SW, et al. The impact of culture isolation of *Aspergillus* species: a hospital-based survey of aspergillosis. *Clin Infect Dis.* 2001;33:1824-33.
33. Johnston ID. Mycobacterium xenopi infection and aspergilloma. *Tubercle.* 1988;69:139-143.
34. Choudat D, Horreard P, Pretet S, Grosset J, Toty L. Superinfection by *Aspergillus fumigatus* of a pulmonary lesion caused by *Mycobacterium xenopi*. *Tubercle.* 1986;67:71-4.
35. Vukicevic TA, Dudvarski-Ilic A, Zugic V, Stevanovic G, Rubino S, Barac A. Subacute invasive pulmonary aspergillosis as a rare cause of pneumothorax in immunocompetent patient: brief report. *Infection.* In Press 2017.
36. Kohno S, Hatano T, Yamada H, Maesaki S, Yasuoka A, Kaku M, et al. Superinfection of chronic necrotizing pulmonary aspergillosis by *Mycobacterium tuberculosis*. *Intern Med.* 1992;31:540-3.
37. Patterson TF, Thompson GR 3rd, Denning DW, Fishman JA, Hadley S, Herbrecht R, et al. Practice guidelines for the diagnosis and management of aspergillosis: 2016 update by the Infectious Diseases Society of America. *Clin Infect Dis.* 2016;63:e1-e60.
38. Cadranet J, Philippe B, Hennequin C, Bergeron A, Bergot E, Bourdin A, et al. Voriconazole for chronic pulmonary aspergillosis: a prospective multicenter trial. *Eur J Clin Microbiol Infect Dis.* 2012;31:3231–9.
39. Kono Y, Tsushima K, Yamaguchi K, Kurita N, Soeda S, Fujiwara A, Sugiyama S, et al. The utility of galactomannan antigen in the bronchial washing and serum for diagnosing pulmonary aspergillosis. *Respir Med.* 2013;107:1094-100.