

LETTER TO THE EDITOR

ANALOGIES IN MEDICINE: MARINE PILOT'S WHEEL

Belo Horizonte, September 2012

Dear Sir,

Together with the anchor, the ship's wheel is the recurrent symbol of ships and sea. It was introduced somewhere in the beginning of the 18th century. Early ships' wheels (c. 1700) were operated to correspond to the motion of the tiller, with a clockwise motion (corresponding to a right tiller motion) turning the rudder and thus the ship to the left. Eventually the control direction of the wheel was reversed to make it more consistent with the action of a motor vehicle's steering wheel. The design of ships' wheels probably influenced that of the modern steering wheel.

A ship's wheel is the modern method of adjusting the angle of a boat or ship's rudder in order to cause the vessel to change its course. Together with the rest of the steering mechanism it forms part of the helm. It is typically connected to a mechanical, electric servo, or hydraulic system. In some modern ships the wheel is replaced with a simple toggle that remotely controls an electro-mechanical or electro-hydraulic drive for the rudder, with a rudder position indicator presenting feedback to the helmsman.

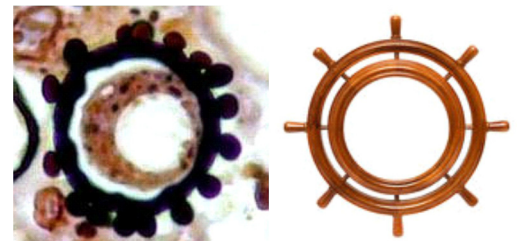


Fig. 1 - Polygemulating yeast and wooden ship's wheel.

Helmsmen on older ships used a tiller (a horizontal bar fitted directly to the top of the rudder post) or a whipstaff (a vertical stick acting on a tiller).

Paracoccidioidomycosis, also called Lutz-Splendore-Almeida disease and *South American blastomycosis* because it occurs almost exclusively in South and Central America, is a chronic granulomatous disease caused by *Paracoccidioides brasiliensis*. It was first described in Brazil by Adolfo Lutz in 1908. *P. brasiliensis* is a dimorphic fungus that gains entrance into the human body through inhalation and infects the lungs, where there is a subclinical infection, but with a tendency to disseminate to the mucous membranes and lymph nodes. The typical patient with clinical disease is an adult male with an indolent, slowly progressive course. The first clinical manifestation is usually in the oropharynx and on the gingivae or on the mucocutaneous junction in the nose. The lesions begin as papules and nodules that then ulcerate. Subsequently, extensive granulomatous, ulcerated lesions may develop in the mouth, nose and larynx. Untreated, extensive cervical lymphadenopathy develops, with suppuration of some lymph nodes. Through lymphatic and hematogenous spread, the disease may subsequently involve many other lymph nodes and the gastrointestinal tract. In cases with wide dissemination, the lungs are clinically involved, presenting a picture resembling pulmonary tuberculosis¹⁻⁴. The disease disseminates more rapidly in children. I have seen a severe case in a 4-year-old child with visceral and bone marrow involvement and bone osteolytic lesions in the clavicle and scapula with a fulminant course.

Examination of lesions reveals a granulomatous infiltrate showing epithelioid cells and Langhans' and foreign body giant cells in association with abscess formation. Spores may lie within giant cells or free in the infiltrate. They are best demonstrated with the PAS reaction or with methenamine silver. Pseudoepitheliomatous hyperplasia in the skin and mucous membranes may be marked. Many of the spores present in the tissue show only single, usually narrow-based buds or no buds at all. Whereas nonbudding or singly budding spores measures from 5 to 20 microns in diameter, spores with multiple budding may measure up to 60 microns in size. The distinctive feature of the fungus in tissue is this large cell which, when hemisected by a microtome, reveals many peripheral buds protruding from a thin-walled, large, round mother cell that is likened to a **marine pilot's wheel** (polygemulating yeast) (Fig.1). (Steering, marine or ship's wheel appearance). (Port. roda de leme ou timão. Esp. timón)²⁻³.

José de Souza ANDRADE-FILHO
Faculdade de Ciências Médicas de Minas Gerais
Belo Horizonte, Minas Gerais, Brasil
E-mail: labjsouzandrade@terra.com.br

REFERENCES

1. Elder DE, editor. Lever's histopathology of the skin. 9th ed. Philadelphia: Lippincott Williams & Wilkins; 2005. p. 617-8.
2. Pena GP, Andrade-Filho JS. Analogies in medicine: valuable for learning, reasoning, remembering and naming. Adv Health Sci Educ Theory Pract. 2010;15:609-19.
3. Andrade-Filho JS. Roda de leme ou timão. NewsLab. 2007;83:212.
4. Sampaio SAP, Rivitti EA. Dermatologia. São Paulo: Artes Médicas; 1998. p. 535-44.