

Rev. Inst. Med. Trop. Sao Paulo  
53(5):295-297, September-October, 2011  
doi: 10.1590/S0036-46652011000500010

## CASE REPORT

### A HISTORICAL NOTE ON AN IMPORTED CASE OF LOIASIS IN RIO DE JANEIRO, BRAZIL, 1964

Antonio GIARDULLI(1,2)\*, Guilherme Dolanda PAULO FILHO(2)\*, Giovanni Nicola Urberto Italiano COLOMBINI(1),  
Walter de Araújo EYER-SILVA(1) & Carlos Alberto BASILIO-DE-OLIVEIRA(1)

#### SUMMARY

Loiasis is a filarial disease transmitted by the *Chrysops* spp. tabanid flies in West and Central Africa. It is most commonly diagnosed by the clinical manifestations of Calabar swellings (transient localized inflammatory edema) or, most dramatically, by the appearance of a migrating worm through the conjunctival tissues or the bridge of the nose. We report the case of a 35-year-old resident in the city of Rio de Janeiro who displayed a moving *Loa loa* in the bulbar conjunctival tissue two years after returning from a six-month trip to Uganda. Surgical removal of the worm was performed.

**KEYWORDS:** Brazil; *Loa loa*; Loiasis; Uganda.

#### INTRODUCTION

The African eye worm *Loa loa* belongs to the family Onchocercidae, superfamily Filarioidea. It is found only in Africa, most commonly around the Gulf of Guinea, but extends into Central Africa into Chad, Sudan and Uganda<sup>4,6,20</sup>. It is transmitted by tabanids belonging to the genus *Chrysops*, which possess mouth parts that can produce a painful bite. Most infected people are asymptomatic or present only mild signs and symptoms. Adult *Loa loa* live and move around the subcutaneous tissues of humans. The female produces embryos (microfilariae) which circulate in the blood stream with a diurnal periodicity and may be ingested by the day-biting vector fly during a blood meal. The microfilariae undergo a developmental cycle in the thoracic musculature of the vector and after 10 to 12 days reach the infective stage which can be transmitted to another human host during a subsequent bloodmeal<sup>4,6,20</sup>.

Diagnosis is usually made on the basis of clinical manifestations of transient localized inflammatory edema (Calabar swellings) and the appearance of a migrating worm through the conjunctival tissue across the eyeball or over the bridge of the nose. Clinical features of loiasis may appear as soon as five months after infection or as late as 17 years<sup>6,20</sup>. Surgical removal of the migrating worm when it passes under the conjunctiva most readily relieves symptoms. Diethylcarbamazine is the only macrofilaricidal drug and thus the only drug enabling the definitive cure of patients, although it can produce severe meningoencephalitis in heavily infected subjects and is considered contraindicated in areas where onchocerciasis is endemic<sup>13</sup>. We wish to report an imported

case of loiasis diagnosed in Rio de Janeiro in 1964. This case has been previously presented by late Professor Antonio Paulo Filho, Head of the Ophthalmology Department at Hospital Gaffrée e Guinle, in his Memorial Jubilee publication volume<sup>9</sup> and is not available in current electronic databases. He personally asked one of us (CABO) to report the present case in the medical literature.

#### CASE REPORT

The patient was a 35-year-old previously asymptomatic Spanish male who resided in Rio de Janeiro and displayed in March 1964 an intensely pruritic discomfort of a few hours duration in his right eye. He also referred foreign body sensation, photophobia and watering. He reported that in the previous few weeks he had experienced recurrent bouts of such crises which used to last for only a few minutes. There were no complaints in the left eye. He had returned from Uganda two years previously, where he served as a precision technician during a period of six months.

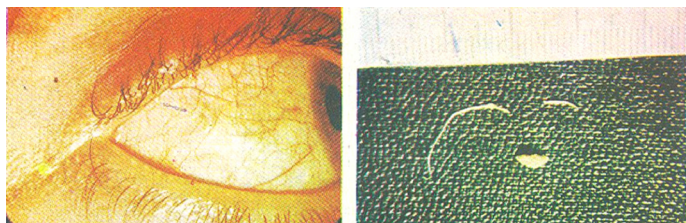
On examination, visual acuity was normal in both eyes (with lens correction for farsightedness). There were also no abnormalities on optic fundus, cornea, anterior chamber, aqueous humor, and no signs of uveitis. Marked conjunctival congestion in the palpebral and fornix area was recorded. Examination of the bulbar conjunctiva showed a long, freely moving adult worm (Fig. 1). Attempts to remove the worm were unsuccessful. The patient was then immediately referred to the surgical room. Due to its extreme mobility, successful removal was accomplished

(1) Hospital Universitário Gaffrée e Guinle, Universidade Federal do Estado do Rio de Janeiro, Rio de Janeiro, RJ, Brasil.

(2) Clínica de Olhos Paulo Filho, Rio de Janeiro, RJ, Brasil.

\* in memoriam

**Correspondence to:** Prof. Carlos Alberto Basilio-de-Oliveira, Serviço de Anatomia Patológica, Hospital Universitário Gaffrée e Guinle, Uni-Rio, Rua Mariz e Barros 775, 20270-004 Rio de Janeiro, RJ, Brasil. E-mail: basiliopatologia@br.inter.net



**Fig. 1** - (Left) Translucent elongated structure in the superior bulbar conjunctiva sharing resemblance with an engorged lymphatic vessel. It was, however, animated by rapid undulatory movements. (Right) A female adult *Loa loa* of around 3 cm is shown divided into two pieces by the suture line.

only after local anesthesia and conjunctival fixation of the worm with a suture line (Fig. 1). Microscopic examination of the parasite found that the morphologic features of the worm were consistent with an adult female *Loa loa*. Further details on such analysis are unavailable. The patient did not report other signs of loiasis. No blood sample had been taken to seek microfilariae and no information on follow-up is available.

## DISCUSSION

We are unaware of previous descriptions of loiasis in Brazil. Imported cases of *Loa loa* are rarely reported from the Americas<sup>7,17</sup>. In the United States, for instance, only 42 cases were referred to the National Institutes of Health between 1976 and 1990<sup>10</sup>. The ease of modern international travel and the growing cultural and economic relationships between Brazil and west and central African countries may expose Brazilian travelers to diseases such as loiasis while visiting endemic countries. Besides the classical features of Calabar swellings and actively migrating worms through subcutaneous or conjunctival tissues, loiasis should also be considered in cases of generalized pruritus, eosinophilia, and urticarial vasculitis in patients with a history of even short periods of travel to endemic areas. Interestingly, our patient seems to have acquired loiasis in Uganda, a country where this filarial disease is only rarely reported<sup>4,5,11,16</sup>.

The diagnosis of loiasis in a case such as this should generally be straightforward. Attempts to remove the worm should be performed for parasitological analysis and to rule out artifacts<sup>3</sup>. However, physicians need also be aware of a variety of other helminth infections that can compromise ocular tissues in a resident of Brazil with a history of travel to Africa. *Mansonella perstans* adult worms are largely non-pathogenic and live in serous cavities. They may produce small, yellowish bodies in the bulbar conjunctiva known as bung-eye, Kampala eye worm, or Ugandan eye worm<sup>2</sup>. Onchocercal adult worms tend to aggregate into palpable subcutaneous nodules and eye damage is mediated primarily by microfilariae<sup>21</sup>. Under unusual circumstances, an adult Bancroftian filariasis worm may cross the conjunctival tissue<sup>14</sup>. However, concomitant evidence of acute or chronic lymphatic disease elsewhere would be expected. Dracunculiasis may occur anywhere in the subcutaneous tissue and may emerge in the orbit<sup>21</sup>, but it is much larger than *Loa loa* and most frequently affects the foot or lower leg. *Toxocara* larvae are much smaller and may appear in the anterior chamber<sup>20</sup>. It may cause a granulomatous process around the macula known as ocular larva migrans<sup>21</sup>. Trichinosis larvae are also much smaller and characteristically produce circumorbital edema and chemosis<sup>1</sup>. *Dirofilaria* species may present as a nodule in the conjunctiva or eyelid or an adult worm may be found in eye tissues. They tend to be

large, robust worms with distinctive longitudinal and circular cuticular ridging<sup>15</sup>. Cysticercosis<sup>21</sup>, schistosomiasis<sup>18</sup>, echinococcosis<sup>19</sup> and sparganosis<sup>12</sup> may also present as cysts, nodules or tumors in eye tissues. Migrating infective larvae of hookworms and *Strongyloides stercoralis* are the cause of cutaneous larva migrans and larva currens, respectively. They move much more slowly, cause significantly worse subcutaneous irritation and should have a much shorter incubation period than *Loa loa*. These larvae may occasionally invade sub-retinal tissues to cause diffuse unilateral subacute neuroretinitis and optic disc edema<sup>8</sup>.

## RESUMO

### Nota histórica sobre caso importado de loíase no Rio de Janeiro, Brasil, 1964

A loíase é uma filariase transmitida por tabanídeos (mutucas) do gênero *Chrysops* na África central e ocidental, comumente diagnosticada pela apresentação clínica de edema de Calabar (edema inflamatório transitório e localizado) ou, mais dramaticamente, pela migração de um verme adulto pelo tecido conjuntival ou asa do nariz. Descrevemos o caso clínico de um paciente do sexo masculino, 35 anos, residente no Rio de Janeiro, que se apresentou com um verme adulto de *Loa loa* migrando sobre o tecido conjuntival bulbar dois anos após retornar de uma viagem de seis meses de duração a Uganda. Procedeu-se a remoção cirúrgica do verme.

## REFERENCES

1. Astudillo LM, Arlet PM. Images in clinical medicine. The chemosis of trichinosis. *N Engl J Med*. 2004;351:487.
2. Baird JK, Neafie RC, Connor DH. Nodules in the conjunctiva, bung-eye, and bulge-eye in Africa caused by *Mansonella perstans*. *Am J Trop Med Hyg*. 1988;38:553-7.
3. Beaver PC. Intraocular filariasis: a brief review. *Am J Trop Med Hyg*. 1989;40:40-5.
4. Boussinesq M. Loiasis. *Ann Trop Med Parasitol*. 2006;100:715-31.
5. Boussinesq M, Gardon J. Prevalences of *Loa loa* microfilaraemia throughout the area endemic for the infection. *Ann Trop Med Parasitol*. 1997;91:573-89.
6. Burnham G. Cutaneous filariasis. In: Warrell D, Cox T, Firth J, editors. *Oxford textbook of Medicine*. 5<sup>th</sup> ed. Oxford: Oxford University Press; 2010. p. 1145-53.
7. Caraballo A, Alvarado J. Report of imported cases of *Loa loa* in Venezuela. *Mem Inst Oswaldo Cruz*. 1990;85:485.
8. Dhir L, O'Dempsey T, Watts MT. Cutaneous larva migrans with optic disc edema: a case report. *J Med Case Reports*. 2010;4:209.
9. Giardulli A, Paulo-Filho G. Filaria *Loa loa* de localização conjuntival. In: Paulo-Filho Carvalho MH, Giardulli A, editores. *Jubileu magisterial do Professor Antonio Paulo Filho*. Rio de Janeiro: Borsoi; 1976. p. 173-178.
10. Klion AD, Massougbdji A, Sadeler BC, Ottesen EA, Nutman TB. Loiasis in endemic and nonendemic populations: immunologically mediated differences in clinical presentation. *J Infect Dis*. 1991;163:1318-25.
11. Klion AD, Nutman TB. Loiasis and *Mansonella* infections. In: Guerrant RL, Walker DH, Weller PF, editors. *Tropical infectious diseases: principles, pathogens and practice*. 3<sup>rd</sup> ed. Amsterdam: Saunders Elsevier; 2011. p. 735-740.
12. Mentz MB, Procianny F, Maestri MK, Rott MB. Human ocular sparganosis in southern Brazil. *Rev Inst Med Trop Sao Paulo*. 2011;53:51-3.

13. Molyneux DH, Bradley M, Hoerauf A, Kyelem D, Taylor MJ. Mass drug treatment for lymphatic filariasis and onchocerciasis. *Trends Parasitol.* 2003;19:516-22.
14. Nanavaty MA, Nanavaty AJ, Lakhani JD, Lakhani SJ, Vasavada AR. Subconjunctival adult bancroftian filarial worm. *Indian J Ophthalmol.* 2001;49:195-6.
15. Orihel TC, Eberhard ML. Zoonotic filariasis. *Clin Microbiol Rev.* 1998;11:366-81.
16. Poltera AA. The histopathology of ocular loiasis in Uganda. *Trans R Soc Trop Med Hyg.* 1973;67:819-29.
17. Rakita RM, White AC, Jr., Kielhofner MA. *Loa loa* infection as a cause of migratory angioedema: report of three cases from the Texas Medical Center. *Clin Infect Dis.* 1993;17:691-4.
18. Randriamora JT, Rabarijaona HZ, Rabearivony N, Bernardin P, Rasoavelonoro VA. Tumeur sous-conjonctivale bulbaire révélant un granulome bilharzien péri-oculaire. *J Fr Ophtalmol.* 2004;27:1043-5.
19. Sanli M, Sabuncuoglu H, Keskin T. Primary intraorbital hydatid cyst: an unusual location, case report and review of the literature. *Minim Invasive Neurosurg.* 2007;50:367-9.
20. Simonsen PE. Filariases. *In: Cook GC, Zumla AI, editors. Manson's tropical diseases.* 22<sup>nd</sup> ed. Amsterdam: Saunders Elsevier; 2009. p. 1477-514.
21. Yorston DH, McGavin DDM. Ophthalmology in the Tropics and Subtropics. *In: Cook GC, Zumla AI, editors. Manson's tropical diseases.* Amsterdam: Saunders Elsevier; 2009. p. 283-332.

Received: 10 April 2011

Accepted: 25 July 2011

# LIBRARY OF THE SÃO PAULO INSTITUTE OF TROPICAL MEDICINE

**Website:** [www.imt.usp.br/portal](http://www.imt.usp.br/portal)

**Address:** Biblioteca do Instituto de Medicina Tropical de São Paulo da Universidade de São Paulo  
Av. Dr. Enéas de Carvalho Aguiar, 470. Prédio 1 – Andar térreo.  
05403-000 São Paulo, SP, Brazil.

**Telephone:** 5511 3061-7003 - **Fax:** 5511 3062-2174

The screenshot shows the website for the Biblioteca do Instituto de Medicina Tropical de São Paulo. At the top left is the logo of the Instituto de Medicina Tropical de São Paulo (IMT USP) and the Universidade de São Paulo. To the right is an 'Intranet' button and social media icons. A navigation bar includes 'Início', 'Sobre o IMTSP', 'Pesquisa', 'Ensino', 'Extensão', and 'Buscar'. Below this is a secondary menu with 'Organização', 'Notícias', 'Administração', 'Biblioteca', 'Revista IMTSP', 'Apoio', 'Concursos e Editais', and 'Contato e Localização'. The main content area is titled 'Biblioteca do Instituto de Medicina Tropical de São Paulo' and includes a mission statement, objectives, and vision. It also features a 'Biblioteca Menu' with links to 'Guia do Usuário', 'Links', 'Livros com texto integral', 'Congressos da Sociedade Brasileira de Medicina Tropical', 'Espaço do Pós-Graduando', 'Pesquisa na Internet', 'Publicações da Biblioteca', 'Revistas Eletrônicas', 'Revistas Gratuitas', 'Sites (Bases de Dados)', and '+informações'. Logos for 'Lattes' and 'QUALIS' are displayed, along with contact information: 'Contato: bibimt@usp.br' and 'Atualizada em 01/12/2010'. A 'Voltar ao Topo' link is at the bottom left.

The Library of the São Paulo Institute of Tropical Medicine (IMTSP Library) was created on January 15, 1959 in order to serve all those who are interested in tropical diseases. To reach this objective, we select and acquire by donation and / or exchange appropriate material to be used by researchers and we maintain interchange between Institutions thorough the Journal of the São Paulo Institute of Tropical Medicine, since the Library has no funds to build its own patrimony.

The IMTSP Library has a patrimony consisting of books, theses, annals of congresses, journals, and reference works.

The collection fo journals existing in the Library can be verified through the USP – Bibliographic Database – OPAC – DEDALUS <http://dedalus.usp.br:4500/ALEPH/eng/USP/USP/DEDALUS/start> of the USP network.