

## CASE REPORT

### HUMAN OCULAR SPARGANOSIS IN SOUTHERN BRAZIL

Márcia Bohrer MENTZ(1), Fernando PROCIANOY(2), Marcelo Krieger MAESTRI(2) & Marilise Brittes ROTT(1)

#### SUMMARY

We report the first case of human ocular sparganosis in the state of Santa Catarina, southern Brazil. A young female patient presented with three periocular moveable inflammatory masses in her right eye, during two years. By surgical excisional biopsy, a helminth larval stage was removed and identified as sparganum. Clinical, laboratory and epidemiological data on this parasite are presented.

**KEYWORDS:** Human ocular sparganosis; *Spirometra*; *Sparganum*.

#### INTRODUCTION

Sparganosis is a parasitic infection caused by the second larval stage of a cestode of the class Cestoidea, order Pseudophyllida, family Diphylobothriidae, genus *Spirometra*. The natural hosts are wild and domestic canines and felines<sup>20</sup>. These animals release embryonated eggs (coracidia) in their feces. The parasite then passes through two intermediate hosts: the first is a member of one of several genera of cyclopoid copepod crustaceans. The copepod ingests the coracidia, which then develop in its tissues into the first larva (proceroid). The second larval stage (plerocercoid or sparganum) develops in the second intermediate host, a vertebrate, which may be an amphibian, reptile, bird, small rodent, nonhuman primate, or pig, when it ingests the infected crustacean<sup>8,25,30</sup>. Infection of human beings is accidental, and occurs worldwide, most often in Asia where hundreds of cases have been recorded<sup>1,4,7</sup>. Asian cases occur mainly through the local application of infected meat of snakes and frogs to the human skin, eyes and vagina, as an anti-inflammatory treatment<sup>5,13</sup>. In America, Europe and Australia, human infection is mainly caused by ingestion of water contaminated by infected copepods<sup>22,23</sup>. Because the sparganums do not mature to adults in these hosts, they encyst again after passing the intestinal wall, migrating through the tissues. In this manner, the sparganums have been found mainly in subcutaneous tissues, in lymph ganglia, in the conjunctiva, in the viscera and in the cerebrum, where they produce varied pathological changes with corresponding symptoms<sup>6,12,14,15,19,25</sup>.

In Brazil, studies by GUTIERREZ *et al.* (1977)<sup>11</sup> and OGASSAWARA & BENASSI (1980)<sup>24</sup> concluded that the species *Spirometra mansonioides* is indicated as one of the etiological agents of the disease.

The diagnosis is generally based on the identification of the worm, following biopsy<sup>26</sup>.

#### CASE REPORT

A young adult female patient, native to the interior of Santa Catarina State (SC), was referred to the ophthalmology service of the Hospital de Clínicas of Porto Alegre, in the state of Rio Grande do Sul (RS), complaining of pain in the right eye and frontal region. She reported the presence of three inflammatory nodules that had changed their location in the periocular region, including subpalpebral space, over the last two years. Two of them became stationary in the inferior temporal bulbar conjunctiva three weeks before the hospital consultation. The last one had been developing for three months, and over a 24-hour period, had moved to the nasal bulbar conjunctiva. Clinical examination revealed the presence of two non-specific inflammatory granulomatous masses in the inferior bulbar conjunctiva, with edema, and red spots on the lower eyelid. These granulomatous masses undergone excisional biopsy. During the surgical procedure an inert, whitish structure was identified inside each granuloma. They were enrolled during removal and revealed a flat, resembling a parasite, measuring approximately 0.3 X 5.5 cm.

After three months, the third mass reappeared and became fixed at temporal superior bulbar conjunctiva, at this time without granulomatous reaction (Fig. 1). The third parasite was either removed surgically. All the post-operative recoveries were uneventfully, with no damage to the patient's eyesight (Fig. 2). After the larvae were removed, the inflammation receded and her clinical picture improved. The formalin-preserved materials were sent to the Parasitology Laboratory of the

(1) Universidade Federal do Rio Grande do Sul, Departamento de Microbiologia do Instituto de Ciências Básicas da Saúde (ICBS/UFRGS), Porto Alegre, RS, Brasil.

(2) Departamento de Oftalmologia e Otorrinolaringologia (FAMED/UFRGS), Serviço de Oftalmologia do Hospital de Clínicas de Porto Alegre, Porto Alegre, RS, Brasil.

**Correspondence to:** Dra. Márcia Bohrer Mentz, Laboratório de Parasitologia, Instituto de Ciências Básicas da Saúde, Universidade Federal do Rio Grande do Sul, Rua Sarmento Leite 500, 90050-170 Porto Alegre, RS, Brasil. E-mail: m.mentz@uol.com.br; mbmentz@uol.com.br

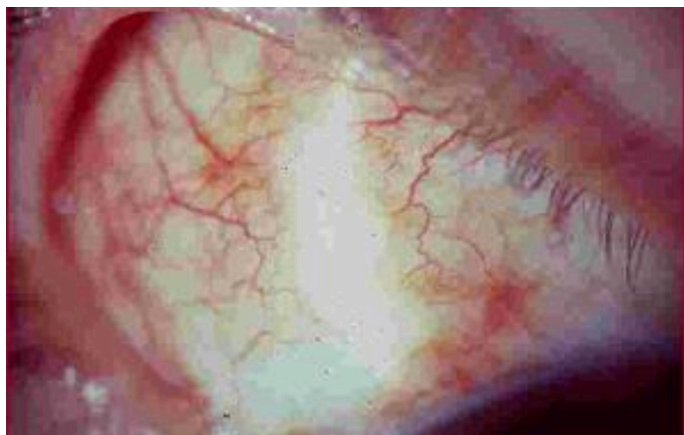

Fig. 1 - Cyst in the bulbar conjunctiva of the right eye.

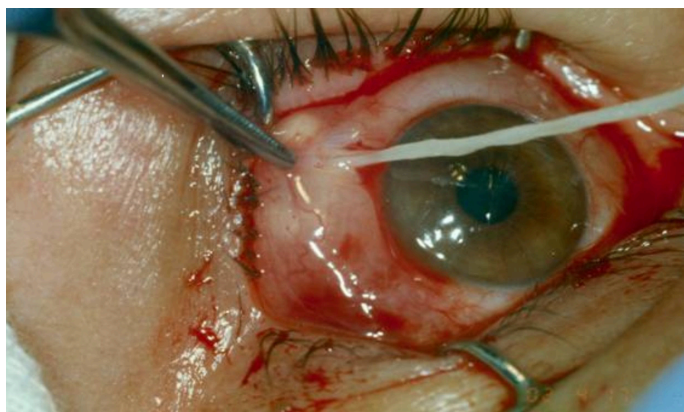

Fig. 2 - Surgical removal of the nodular mass, and appearance of an inert, whitish, flat structure.

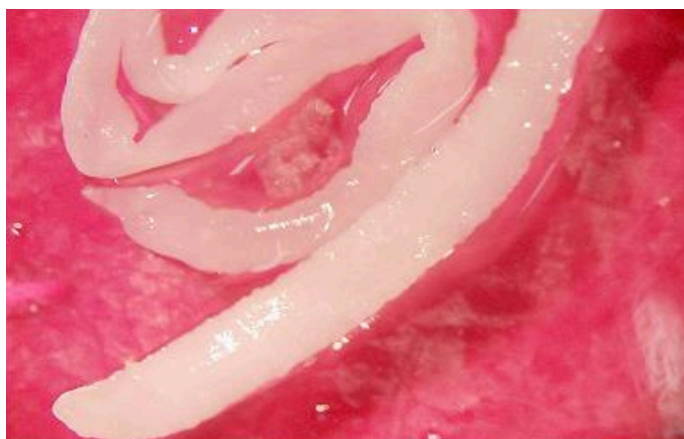


Fig. 3 - Anterior and posterior ends of the plerocercoid larva, viewed in a stereomicroscope (45 X).

Instituto de Ciências Básicas da Saúde of the Universidade Federal do Rio Grande do Sul (ICBS/UFRGS), where they were identified as a plerocercoid larva (sparganum), belonging to the genus *Spirometra* (Fig. 3).

## DISCUSSION

Resident of a small city in rural area, the patient reported that her diet included pork sausages and cold cuts, and that she had in the past eaten wild game such as paca, armadillo and coati. The water consumed by her family is piped from a hillside spring to a household storage tank that is covered and cleaned annually. No other member of her family showed a similar clinical picture.

The cases of human sparganosis reported in the literature are associated with ingestion of raw or insufficiently cooked meat of wild or domestic animals that are indicated as secondary hosts of the genus *Spirometra*, to the ingestion of water containing infected copepods, or to the topical use of meat from contaminated animals<sup>4,7,13,17,23</sup>.

Until the present time, there is no treatment available. Attempts to treat human cases with mebendazole and praziquantel have not been successful<sup>3,20,29</sup>. Therefore, the only available treatment consists of the surgical removal of the larva<sup>32</sup>. Measures to prevent infection include filtering or boiling drinking water, and adequate cooking of all meats that will be consumed, as well as treating parasitized dogs and cats<sup>8,26</sup>.

The location in the eye can be considered rare, with about 42 known cases worldwide. Most of these cases have been reported in Vietnam<sup>2</sup>, seventeen in Thailand<sup>26,33</sup>, two in India<sup>27,30</sup>, three in Korea<sup>28,34,35</sup>, and one in Ecuador<sup>16</sup>.

In Brazil, up to now only three cases of subcutaneous sparganosis have been described: the first in the state of Rio Grande do Sul, by FRÓES in 1967<sup>9</sup>, and the others in São Paulo<sup>10,18</sup>.

Therefore, because of the uncommon ocular location in humans and the rarity in our country this report is important. Furthermore, this is the first record of ocular sparganosis in southern Brazil.

We suggest that the patient may have become infected in one of two ways: by ingesting inadequately cooked or raw pork (in sausages or cold cuts), or by ingesting water containing copepods.

The diagnosis of this parasitosis is relevant and should be considered in cases of ocular disturbances accompanied by painful moveable masses of the conjunctiva and subpalpebral or periocular structures, in patients from endemic areas or who may have accidentally come in contact with sources of infection.

## RESUMO

### Esparganose ocular humana no sul do Brasil

Registra-se o primeiro caso de esparganose ocular humana no estado de Santa Catarina, sul do Brasil a partir de paciente adulta que apresentou três massas inflamatórias móveis perioculares, localizadas no olho direito, durante dois anos. Com a excisão cirúrgica o material foi para a biópsia e um estágio larval de helminto foi identificado como espargano. Dados clínicos, laboratoriais e epidemiológicos são apresentados neste trabalho.

## REFERENCES

1. Beaver PC, Jung RC, Cupp EW. *Clinical Parasitology*. 9<sup>th</sup> ed. Philadelphia: Lea & Febiger; 1984. p. 499-502.
2. Botterel F, Bourée P. Ocular sparganosis: a case report. *J Travel Med*. 2003;10:245-6.
3. Chai JY, Yu JR; Lee SH, Kim SI, Cho SY. Ineffectiveness of praziquantel for human sparganosis. *Seoul J Med*. 1988;29:397-9.
4. Cho SY, Bae JH, Seo BS, Lee SH. Some aspects of human sparganosis in Korea. *Korean J Parasitol*. 1975;13:60-77.
5. Cho SY, Hwang KI, Seo BS. On the *Sparganum mansoni* infections in some Korean terrestrial snakes. *Korean J Parasitol*. 1973;11:87-94.
6. Cho KJ, Lee HS, Chi JG. Intramural sparganosis manifested as intestinal obstruction: a case report. *J Korean Med Sci*. 1987;2:137-9.
7. Eduardo SL. Food-borne parasitic zoonoses in the Philippines. *Southeast Asian J Trop Med Public Health* 1991;22(Suppl):16-22.
8. Fortes E. *Parasitologia veterinária*. 4<sup>th</sup> ed. São Paulo: Ícone; 2004.
9. Fróes OM. Sparganose humana: o primeiro caso relatado para o Brasil. In: I Congresso Latinoamericano de Parasitología, 1967; Santiago, Chile. p. 143.
10. Gomes AHS, Cacciaccaro EN, Mangini ACS, Dias RMDs, Lapola SR, César NPA, et al. Esparganose humana. Relato de um novo caso no estado de São Paulo. *Rev Inst Adolfo Lutz*. 1996; 56(2):13-5.
11. Gutierrez VC, Fróes OM, Amato JFR. Identificação de um hospedeiro intermediário de *Spirometra mansonioides* Mueller, 1935 na área de Porto Alegre, Rio Grande do Sul, Brasil. *Rev Bras Biol*. 1977; 37:131-3.
12. Kittiponghansa S, Tesana S, Ritch, R. Ocular sparganosis: a cause of subconjunctival tumor and deafness. *Trop Med Parasitol*. 1988;39:247-8.
13. Ko RC. Current status of food-borne parasitic zoonoses in Hong Kong. *Southeast Asian J Trop Med Public Health* 1991;22(Suppl):42-7.
14. Kron MA, Guderian R, Guevara A, Hidalgo A. Abdominal sparganosis in Ecuador: a case report. *Am J Trop Med Hyg*. 1991;44:46-50.
15. Lee HB, Lee KW, Lee SB, Myung HJ. Clinical observation on cerebral sparganosis. *J Korean Neurol Assoc*. 1987;5:64-9.
16. León LA, Almeida R, Mueller JF. A case of ocular sparganosis in Ecuador. *J Parasit*. 1972;58:184-5.
17. Li MW; Lin HY, Xie W, Gao M J, Huang ZW, Wu JP, et al. Enzootic Sparganosis in Guangdong, People's Republic of China. *Emerg Infect Dis*. 2009;15:1317-8.
18. Maciel P, Haddad CM. Esparganose: primeiro caso no Brasil (nota prévia). *Rev Paul Med*. 1968;72:270.
19. Mendez-Medina R, Cataneda-Suardiaz J, Ravina-Cabrena MD. Subcutaneous sparganosis - a new case report. *Morfologia Normal y Patologica B*. 1983;7:285-92.
20. Moulinier R, Martinez E, Torres J, Noya O, de Noya BA, Reyes O. Human proliferative sparganosis in Venezuela: report of a case. *Am J Trop Med Hyg*. 1982;31:358-63.
21. Mueller JF. The biology of *Spirometra*. *J Parasitol*. 1974;60:3-14.
22. Mueller JF, Fróes OM, Fernández T. On the occurrence of *Spirometra mansonioides* in South America. *J Parasitol*. 1975;61:774-5.
23. Norman SH, Kreutner Jr A. Sparganosis: clinical and pathologic observations in ten cases. *South Med J*. 1980;73:297-300.
24. Ogassawara S, Benassi S. *Spirometra mansonioides* Mueller, 1935 em animal da espécie felina no Estado de São Paulo. *Arq Inst Biol*. 1980;47:43-6.
25. Oh SJ, Chi JG, Lee SE. Eosinophilic cystitis caused by vesical sparganosis: a case report. *J Urol*. 1993;149:581-3.
26. Rey L. Himenolepíases, difilobotríase e outros Cestóides. In: Rey L. *Parasitologia*. 3<sup>a</sup> ed. Rio de Janeiro: Guanabara Koogan; 2002. p. 544.
27. Sen DK, Muller R, Gupta VP, Chilana JS. Cestode larva (Sparganum) in the anterior chamber of the eye. *Trop Geogr Med*. 1989;41:270-3.
28. Shin DE, Min KH, Chai JY. A case of subconjunctival sparganosis. *J Korean Ophth Soc*. 1980;21:1449-52.
29. Sohn WM, Hong ST, Chai JY, Lee SH. Infectivity of the sparganum treated by praziquantel, gamma irradiation and mechanical cutting. *Korean J Parasitol*. 1993;31:135-9.
30. Subudhi BN, Dash S, Chakrabarty D, Mishra DP, Senapati U. Ocular sparganosis. *J Indian Med Assoc*. 2006;104:529-30.
31. Torres P, Figueroa L. Infection by *Spirometra mansoni* (Cestoda, Pseudophyllidea) in the south of Chile. *Bol Chil Parasitol*. 1982;37:72-73.
32. Valerio I, Rodriguez B, Chinchilla M. Primer hallazgo de *Spirometra mansoni* en *Felis domesticus* de Costa Rica. *Parasitol Latinoam*. 2004;59:162-6.
33. Wiwanitkit, V. A review of human sparganosis in Thailand. *Int J Infect Dis*. 2005;9:312-6.
34. Yang JW, Lee JH, Kang MS. A case of ocular sparganosis in Korea. *Korean J Ophthalmol*. 2007;21:48-50.
35. Yoon KC, Seo MS, Park SW, Park YG. Eyelid sparganosis. *Am J Ophthalmol*. 2004;138:873-5.

Received: 13 August 2010

Accepted: 3 November 2010