

CASE REPORT

ACUTE NEUROMUSCULAR MANIFESTATIONS IN A PATIENT ASSOCIATED WITH INGESTING OCTOPUS (*Octopus* sp.)

Vidal HADDAD JUNIOR(1,2,3) & Regina MOURA(1)

SUMMARY

The authors report neuromuscular manifestations in a 45-year-old woman after consuming octopus meat (*Octopus* sp.). The patient presented malaise, paresthesias in perioral and extremity areas, intense muscular weakness and arterial hypotension, followed by severe itch and disseminated cutaneous rash. Gastrointestinal manifestations and fever were not observed, reducing the probability of alimentary poisoning. The presence of muscular and neurological symptoms suggests neurotoxin action, which could have been ingested by the victim from the octopus salivary glands or from an accumulation of toxins in the meat, or by an unknown mechanism. There is little known about toxins of the *Octopus* genus and this communication is important alert to the possibility of poisoning in humans that eat octopus and its differentiation from alimentary poisonings arising from incorrect conservation of seafood.

KEYWORDS: Aquatic poisonous animals; Brazil; *Octopus* sp.; Octopuses; Poisoning, Venomous and poisonous marine animals.

INTRODUCTION

There are over 50,000 known species in the Phylum Mollusca. In general, mollusks have a head (with sense organs and a "brain"), a viscera mass, and a muscular foot-like structure, which is in contact with the substrate⁹.

Venomous animals are capable of inoculating venom to capture prey or defend themselves against predators, using their own apparatus. Poisonous animals can poison predators passively through toxins produced or stored in their bodies^{1,3}. There are poisonous and venomous mollusks. Some diseases from toxins can be caused by consuming poisonous clams and mussels, such as shellfish poisoning caused by a potent neurotoxin, saxitoxin, produced by dinoflagellates.

The most important venomous mollusks are from the Gastropoda and Cephalopoda classes. Gastropoda of the genus *Conus* contain mollusks able to envenom prey and occasionally even Man.

The Cephalopoda class contains squid, octopuses, cuttlefish, and nautilus which are widely distributed throughout tropical and temperate seas. Octopuses vary in size from a few centimeters to the giant octopus of the Pacific Ocean which can grow to over 10 m, but Brazilian octopuses rarely exceed 1 m. They have "feet" (mistakenly

called tentacles) and a horny "beak" used to capture prey, especially other mollusks (bivalves), but they also feed on Crustacea and fish. Octopuses have defense mechanisms that eject jets of water that move their bodies quickly in the opposite direction and they eject a cloud of dark ink that confuses predators. A third defense and attack mechanism exists; this is toxins found in the salivary glands, which are linked to their mandible or beak.

The blue-ringed octopus (*Hapalochlaena maculata* and *Hapalochlaena lunulata*) inoculates maculotoxin from their saliva glands through their horny beak (it was recently demonstrated that maculotoxin is identical to tetrodotoxin)¹⁰. Tetrodotoxin is a potent neurotoxin that blocks axonal sodium channels and provokes a muscular paralysis similar to that observed in accidents with *Conus* shells, including fatal respiratory arrest^{2,11,12}. In accidents caused by the blue-ringed octopus, initial pain is not so intense. The blue-ringed octopus is not found in the Atlantic Ocean.

It should be pointed out that there are enzymes to facilitate digestion and toxins to immobilize prey in the saliva glands of all octopuses, even those along the Brazilian coast. There are five species of octopuses recorded along the Northeast Coast of Brazil: *Octopus macropus*, *Octopus defilippi*, *Octopus* sp. C., *Octopus* cf *vulgaris*, and *Octopus filusus*, the first three are cosmopolitan and *Octopus filusus* is restricted

(1) Faculdade de Medicina de Botucatu, Universidade Estadual Paulista, Botucatu, SP, Brasil.

(2) Programa de Pós-Graduação em Zoologia, Instituto de Biociências de Botucatu, Universidade Estadual Paulista, Botucatu, SP, Brasil.

(3) Hospital Vital Brazil, Instituto Butantan, São Paulo, SP, Brasil.

Correspondence to: Vidal Haddad Junior, Caixa Postal 557, 18618-000 Botucatu, SP, Brasil. E-mail: haddadjr@fmb.unesp.br

to the Caribbean and the North and Northeast of Brazil. *Octopus* cf *vulgaris* is the most common octopus around the Brazilian and South American coast and does not present morphological differences with specimens from South and Southeast coast of Brazil^{6,8}. Recent reports have pointed to the presence of cephalotoxin, a glycoprotein, in the saliva of some octopus species, including the *Octopus macropus* and *Octopus vulgaris*⁷. These probable neurotoxins cause paralysis in crustaceans but there are no reported studies on their effect in mammals.

Reports of poisoning caused by ingesting cephalopods are rare with only one report of a series of poisoning outbreaks after ingestion of cephalopod meat in Japan⁵. The predominant symptoms were fever, diarrhea, abdominal pain, weakness, dehydration, and convulsions. The total number of patients observed was 758 and almost all presented gastrointestinal symptoms, but three developed convulsions and three presented muscular paralysis⁴.

CASE DESCRIPTION

A 45-year-old white female physician presented at our service for evaluation of intense itching and a general erythematous rash appearing after ingestion of octopus meat.

While on vacation in a northeast Brazilian coastal city she ate two helpings of semi-raw octopus meat. Some hours after the meal she felt a sensation of tingling in her face, mainly around the lips, followed by a similar sensation in the legs and arms and a sensation of illness followed by vertigo and arterial hypotension (70 x 40 mm Hg). She felt her radial pulse was weak, a cold sensation, and intense weakness in her extremities. She did not present fever or gastrointestinal manifestations but reported feeling dehydrated although she had ingested substantial liquid. She did not eat anything else but only drank carbohydrate-electrolyte drinks and water. This sensation persisted for some hours into the night, so she decided to use antihistamines (dexchlorpheniramine, 2 mg po). The following morning most of the manifestations had disappeared but vertigo remained. About 48 hours later an intense itch appeared in the superior members, followed by erythema in the trunk and a generalized erythematous rash when she presented for dermatological examination. The manifestations disappeared after five days. In a follow-up contact with the hotel, they sent us images of the octopus used in their cookery (Fig. 1 and 2); this was classified as the *Octopus* genus (*Octopus* sp.).

DISCUSSION

Most accidents caused by octopuses are traumatic and are from the mandible or beak, causing lacerations and bleedings. A small percentage show envenoming associated with salivary gland toxin inoculation via the beak. Poisoning is very rare and is seen after ingestion of mollusk meat.

The symptoms presented by this patient are compatible with neurotoxicity, especially perioral tingling, muscular weakness, and systemic hypotension. It is important to note the absence of fever and gastrointestinal manifestations, which practically eliminates the probability of poisoning from badly conserved octopus meat and shows a different profile to poisonings observed by KAWABATA *et al.* (1957), which mainly displayed gastrointestinal symptoms. It is very possible

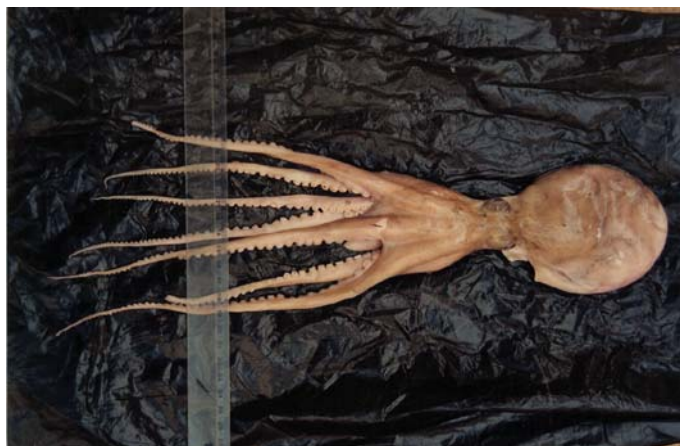


Fig. 1 - Common octopus (*Octopus* sp.), from the same region as the poisoning described here.

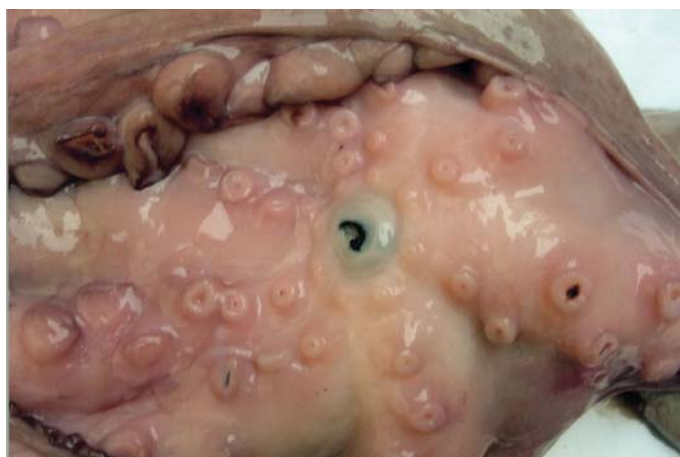

Fig. 2 - The chitinous beak of the octopus is medially located in the body of the mollusk.



Fig. 3 - Details of an octopus's beak. This structure is capable of breaking the hard shells of mollusks and crustaceans, lacerating soft tissues, and can be linked to venom glands with neurotoxic effects.

that the patient was poisoned by octopus toxins, but it is not possible to confirm whether the patient's manifestations resulted from ingesting toxins from the saliva glands of semi-raw octopus or from other toxins present in the actual meat of the animal, but the now widespread habit of eat raw fish and seafood in Japanese cooking can contribute to some poisonings.

Neurotoxins from the salivary glands can remain active in the presence of high temperatures, which could also have contributed to the poisoning. Despite octopuses of the *Octopus* genus having neurotoxins to paralyze their food, there are few reports on their action and the information that does exist was not sufficient for the evolution and prognosis of the accident, which seemed less serious than those caused by the blue ringed octopus. However, there is a need for more studies on their action.

The diagnosis of poisonings caused by venomous mollusks is based on clinical observation. There is no antidote to the toxins and severe envenomation or poisoning should be treated with artificial ventilation, the only effective measure, as there is no antivenom available¹⁰. Gravity depends on the time elapsed since envenomation or poisoning and the full appearance of the manifestations, as well as considering where the accident occurred, as lack of medical resources also influences prognosis. This report of an accident producing neuromuscular blockade symptoms in a patient after consuming octopus meat must alert us to the possibility of poisoning from consumption of these common mollusks, which must not be confused with food poisoning.

RESUMO

Manifestações neuromusculares agudas associadas à ingestão de polvo comum *Octopus* sp.

Os autores relatam um quadro manifestado por sintomas neurológicos e musculares em uma mulher de 45 anos, que surgiu após o consumo da carne de polvo comum (*Octopus* sp.). A paciente apresentou intenso mal estar, parestesias em extremidades e área perioral, fraqueza muscular intensa e hipotensão arterial, seguidos de prurido importante e uma erupção eritemato-descamativa disseminada tardia. Não foram observadas manifestações gastrointestinais ou febre, o que reduziu a probabilidade de uma intoxicação alimentar por conservação inadequada do molusco. A presença de sintomas neuromusculares é sugestiva de ação de neurotoxinas, comprovadamente existentes em muitos gêneros de polvos e que podem ter sido ingeridas através do consumo das glândulas salivares ou acúmulo das toxinas na carne, por algum mecanismo ainda desconhecido. As toxinas dos polvos do gênero *Octopus* são pouco estudadas e julgamos esta comunicação

importante por alertar para a possibilidade do envenenamento nos seres humanos que consomem carne de polvos e ainda sua diferenciação das intoxicações alimentares que ocorrem por conservação inadequada do animal.

REFERENCES

1. CARDOSO, J.L.C.; FRANÇA, F.O.S.; WEN, F.H.; MALAQUE, C.M.S. & HADDAD Jr., V. - **Animais peçonhentos no Brasil: Biologia, clínica e terapêutica dos acidentes**. São Paulo, Sarvier, 2003. p. 264-278.
2. FLECKER, H. & COTTON, B.C. - Fatal bite from an octopus. *Med. J. Aust.*, 2: 329-331, 1955.
3. HADDAD Jr., V. - **Atlas de animais aquáticos perigosos do Brasil: guia médico de identificação e tratamento (Atlas of dangerous aquatic animals of Brazil: a medical guide to identification and treatment)**. São Paulo, Roca, 2000. p. 28-35.
4. HALSTEAD, B.W. - **Poisonous and venomous marine animals of the world**. Princeton, Darwin, 1988. p. 296-328.
5. KAWABATA, T.; HALSTEAD, B.W. & JUDEFIND, T.F. - A report of a series of recent outbreaks of unusual cephalopod and fish intoxications in Japan. *Amer. J. trop. Med. Hyg.*, 6: 935-939, 1957.
6. LEITE, T.S. - **Caracterização da fauna de polvos (Cephalopoda: Família Octopodidae) de águas rasas do litoral e de ilhas oceânicas do Nordeste Brasileiro**. Rio Grande do Sul, 2002. (Dissertação de Mestrado - Fundação Universidade do Rio Grande).
7. MEBS, D. - **Venomous and poisonous animals: a handbook for biologists, toxicologists and toxinologists, physicians and pharmacists**. Boca Raton, CRC Press, 2002. p. 71-75.
8. ROPER, C.F.E.; SWEENEY, M.J. & NAUEN, C.E. - **Cephalopods of the world**. Rome, Food and Agriculture Organization, 1984.
9. RUPPERT, E.; FOX, E.R.S. & BARNES, R.D. - **Invertebrate Zoology, a functional evolutionary approach**. 7. ed. Belmont, Brooks/Cole-Thomson Learning, 2003. p. 414-422.
10. SHEUMACK, D.D.; HOWDEN, M.E.H.; SPENCE, I. & QUINN, R.J. - Maculotoxin: a neurotoxin from the venom glands of the octopus *Hapalochlaena maculosa* identified a tetrodotoxin. *Science*, 199: 188-189, 1978.
11. SUTHERLAND, S.K. & LANE, W.R. - Toxins and mode of envenomation of the common ringed or blue-banded octopus. *Med. J. Aust.*, 1: 893-898, 1969.
12. WALKER, D.G. - Survival after severe envenomation by the blue-ringed octopus (*Hapalochlaena maculosa*). *Med. J. Aust.*, 2: 663-665, 1983.

Received: 26 January 2006

Accepted: 17 July 2006