

Rev. Inst. Med. trop. S. Paulo
48(4):233-235, July-August, 2006

CASE REPORT

BRAIN ABSCESS SECONDARY TO FRONTAL OSTEOMYELITIS

Felipe Francisco TUON(1), Rachel RUSSO(1) & Antonio Carlos NICODEMO(1)

SUMMARY

Frontal osteomyelitis is a rare complication of sinusitis. Common intracranial complications of the frontal osteomyelitis are meningitis, epidural empyema, subdural empyema and brain abscess. We described a case of frontal osteomyelitis with brain abscess caused by *Staphylococcus aureus* with improve after needle aspiration and antibiotics to brain abscess for eight weeks and for chronic osteomyelitis for four months.

KEYWORDS: Osteomyelitis; Brain abscess; *Staphylococcus aureus*.

INTRODUCTION

Frontal osteomyelitis (FO) is a rare complication of sinusitis in the antibiotic era⁵. It is described at all ages, but occurs most frequently in teenagers with frontal sinusitis⁶. Intracranial complications of the FO include meningitis, epidural empyema, subdural empyema, brain abscess and cavernous sinus thrombosis³. Despite of septic microemboli from the chronic infection can result in brain abscess, the most common form of this rare complication is described by the contiguous focus of infection¹. Causative organisms are bacteria of chronic sinusitis, including *Streptococcus* spp., *Staphylococcus aureus* and anaerobes organisms⁶. We described a case of FO with brain abscess caused by *Staphylococcus aureus*.

CASE REPORT

A 21-year-old woman was admitted to the hospital in October 2005 with one week of headache and fever. She had a history of recurrent frontal headache and spontaneous drainage of suppurative material from frontal sinus region since 1999, but she was never investigated before. Brain computed tomography (CT) scan showed a right frontal hypodense lesion (2.8 cm of diameter) with a dense and well limited wall allowing the diagnostic of brain abscess (Fig. 1). Because of intense edema around the lesion with herniation, dexametasone was initiated together with metronidazol 1500 mg and ceftriaxone 4000 mg each day. The patient was submitted to total needle aspiration of the lesion without stereotaxy due easy access. The culture of material was positive for meticillin-sensible *Staphylococcus aureus*. Oxacillin was included to the current antimicrobial treatment. Echocardiography and chest X-ray were normal. Blood cultures were negative and erythrocyte

sedimentation rate of 43 mm/h. A sinus CT scan showed an inflammatory process in the frontal bone with obliteration of frontal sinus (Fig. 2). Tc 99m and 67 gallium scintigraphy of frontal bone was consistent with inflammatory activity and osteomyelitis. The patient received an intravenous treatment for eight weeks and completed four months more with clindamycin for chronic osteomyelitis with normal erythrocyte sedimentation rate (10 mm/h). No surgical debridement was needed.

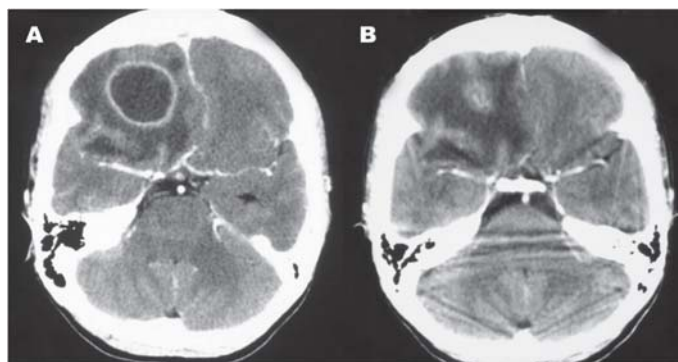


Fig. 1 - CT-scan showing a brain abscess before (A) and after (B) aspiration.

DISCUSSION

In most cases, osteomyelitis of the frontal bone occurs as a complication of sinusitis with eventual sinocutaneous fistula. The main clinical finding is mild headache, sometimes associated with frontal edema and recurrent spontaneous drainage.

(1) Department of Infectious and Parasitic Diseases, School of Medicine/University of São Paulo, SP, Brazil.

Correspondence to: A.C. Nicodemo, Departamento de Moléstias Infecciosas e Parasitárias (4º Andar) sala 4028 ou 4029, Hospital das Clínicas da Faculdade de Medicina da Universidade de São Paulo, Av. Dr. Enéas de Carvalho Aguiar 255, Cerqueira César, 05403-000 São Paulo, SP, Brasil. Phone: 55 11 30696530, Fax: 55 11 30697508. E-mail: ac_nicodemo@uol.com.br

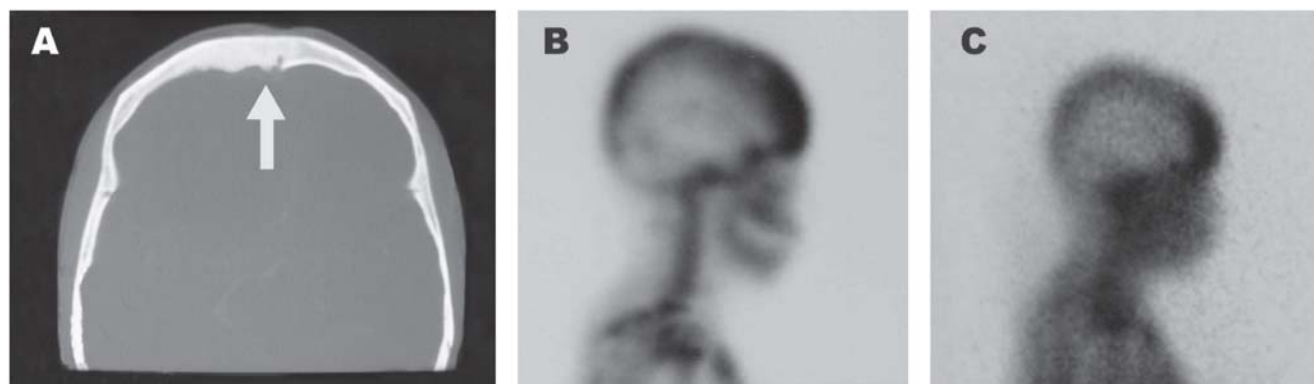


Fig. 2 - Sinus CT-scan with frontal inflammatory process (A) and scintigraphy with inflammatory activity and osteomyelitis with ^{99m}Tc (B) and ^{67}Ga (C).

A subperiosteal abscess and soft tissue swelling may develop resulting in a doughy pitting edema (Pott's puffy tumor)¹¹. Osteomyelitis causes an insufficiency of vascular supply and secondary thrombophlebitis which leads to areas of bony necrosis and progression of infection¹³. Since the thrombophlebitic process also extends posteriorly from the frontal sinus, patients may have concomitant complications, as a brain abscess. Brain abscess is the less common complication of FO, because sinocutaneous fistula formation is an early sign and thus antibiotic treatment is initiated. Sinus CT scan is the method of choice to evaluate frontal sinus and can suggest the diagnosis of FO when osteolysis and osteosclerosis are observed⁵.

Scintigraphy with ^{99m}Tc and ^{67}Ga scanning helps to confirm the diagnosis, determine the extent of disease and demonstrates the response to antibiotic therapy¹¹. Scintigraphy was important in this case to confirm the typical inflammatory aspect. Cultures must always be performed to improve antibiotic therapy. Microbiological diagnosis is possible in less than 50% of cases through culture examination⁹. Fungal cultures must be done for zygomycosis and aspergillosis in immunocompromised patients. The main agents in FO are *Streptococcus* spp., *Staphylococcus aureus* and anaerobes organisms, but the literature about this subject is poor with few case reports published. In the reported case, *Staphylococcus aureus* was isolated from the brain abscess by needle aspiration. The cause of the brain abscess was the FO, which was discovered during the beginning of the investigation. The cause of FO was not found, but acute and chronic frontal sinusitis are the most common causes of FO. There are no data about incidence of FO secondary to sinusitis, neither brain abscess related to FO. Various case reports about Pott's puffy tumor have been published^{2,12,14,15}. The Pott's puffy tumor had frontal edema and is associated with subgaleal empyema, which was not reported in this case. The presence of spontaneous drainage by a sinocutaneous fistula probably decreases the chance of a subgaleal empyema formation.

Surgical intervention of the brain abscess is important to decrease pus volume (by needle aspiration) and to identify etiologic agent. The excision of brain abscess is a surgical procedure indicated when the aspiration is insufficient or a strange body is found¹⁰. Corticosteroids are useful when a risk herniation or compression of important structures is identified. Although 25% of patients with brain abscess have convulsions, prophylaxis with anticonvulsivants is used when the patient have convulsion or alterations in the electroencephalogram. The

treatment described by some authors is surgical debridement associated with antibiotics. When associated with osteomyelitis, early antibiotic treatment, before extensive destruction of bone or necrosis when exists, produces the best results and must be administered parenterally for at least six weeks to achieve an acceptable rate of cure. In the absence of any persistent neurologic deficit and in the presence of a normal erythrocyte sedimentation rate, it is reasonable to discontinue systemic therapy after six weeks⁴. The drug of choice for *S. aureus* osteomyelitis is oxacillin. Second-generation cephalosporin, clindamycin, vancomycin, ciprofloxacin or levofloxacin in combination with rifampicin are also frequently used⁷. To reduce costs, various centers provide parenteral administration of antibiotics on an outpatient basis. The limited bioavailability of oral beta-lactam antibiotics or drugs without oral formulations available raises difficulties in an early intravenous-oral switch therapy. The pharmacologic properties and availability for oral administration make quinolones or clindamycin the drugs of choice in the treatment of osteomyelitis after intravenous therapy⁸. The persistent elevation of erythrocyte sedimentation rate or a return of symptoms, although not seen in our patient, would mandate repeat imaging, including gallium scanning. For some patients, mainly when antibiotic therapy is not sufficient, can be necessary an extensive bone removal and cranioplasty with placement of a prosthesis.

RESUMO

Abscesso cerebral secundário à osteomielite frontal

A osteomielite de osso frontal é uma complicação rara da sinusite frontal. As complicações intracranianas mais comuns da osteomielite frontal são: meningite, empiema epidural, empiema subdural e abscesso cerebral. Relatamos um caso de osteomielite frontal com abscesso cerebral cujo agente etiológico foi o *Staphylococcus aureus*. Houve melhora significativa após drenagem guiada por agulha e antibiótico por oito semanas e para a osteomielite crônica por quatro meses.

REFERENCES

1. ALTMAN, K.W.; AUSTIN, M.B.; TOM, L.W. & KNOX, G.W. - Complications of frontal sinusitis in adolescents: case presentations and treatment options. *Int. J. pediat. Otorhinolaryng.*, 41: 9-20, 1997.
2. BABU, R.P.; TODOR, R. & KASOFF, S.S. - Pott's puffy tumor: the forgotten entity. Case report. *J. Neurosurg.*, 84: 110-112, 1996.

3. CLAYMAN, G.L.; ADAMS, G.L.; PAUGH, D.R. & KOOPMANN Jr., C.P. - Intracranial complications of paranasal sinusitis: a combined institutional review. *Laryngoscope*, **101**: 234-239, 1991.
4. DUCIC, Y. - Management of osteomyelitis of the anterior skull base and craniovertebral junction. *Otolaryng. Head Neck Surg.*, **128**: 39-42, 2003.
5. DURISIN, M.; TESCHNER, M.; LENARZ, T. & STOVER, T. - The interesting case: case no. 65. *Laryngorhinootologie*, **83**: 750-753, 2004.
6. GUILLEN, A.; BRELL, M.; CARDONA, E.; CLARAMUNT, E. & COSTA, J.M. - Pott's puffy tumour: still not an eradicated entity. *Childs Nerv. Syst.*, **17**: 359-362, 2001.
7. LEW, D.P. & WALDVOGEL, F.A. - Osteomyelitis. *Lancet*, **364**: 369-379, 2004.
8. LEW, D.P. & WALDVOGEL, F.A. - Osteomyelitis. *New Engl. J. Med.*, **336**: 999-1007, 1997.
9. MARCHIORI, C.; TONON, E.; BOSCOLO-RIZZO, P. *et al.* - Brain abscesses after extracranial infections of the head and neck area. *HNO*, **51**: 813-822, 2003.
10. MICHAEL, W.; RICHARD, J. & CHRISTINA, M. - **Infections of the central nervous system**. New York, Lippincott Williams & Wilkins, 2004.
11. MONTGOMERY, W.W.; CHENEY, M.L. & JACOBS Jr., E.E. - Osteomyelitis of the frontal bone. *Ann. Otol. Rhinol. Laryngol.*, **98**: 848-853, 1989.
12. NOSKIN, G.A. & KALISH, S.B. - Pott's puffy tumor: a complication of intranasal cocaine abuse. *Rev. infect. Dis.*, **13**: 606-608, 1991.
13. PENDER, E.S. - Pott's puffy tumor: a complication of frontal sinusitis. *Pediat. Emerg. Care.*, **6**: 280-284, 1990.
14. PLAZA-MAYOR, G.; SENDRA-TELLO, J.; MARTINEZ-SAN-MILLAN, J. *et al.* - Pott's puffy tumor. *An. Otorrinolaring. ibero-amer.*, **27**: 145-154, 2000.
15. TUDOR, R.B.; CARSON, J.P.; PULLIAM, M.W. & HILL, A. - Pott's puffy tumor, frontal sinusitis, frontal bone osteomyelitis, and epidural abscess secondary to a wrestling injury. *Amer. J. Sports Med.*, **9**: 390-391, 1981.

Received: 25 November 2005

Accepted: 3 April 2006