

CASE REPORT

DISSEMINATED NOCARDIOSIS DUE TO *Nocardia farcinica*: DIAGNOSIS BY THYROID ABSCESS CULTURE

Cecília Bittencourt SEVERO(1), Flávio de Mattos OLIVEIRA(1), Lenine CUNHA(2), Vlademir CANTARELLI(3) & Luiz Carlos SEVERO(1)

SUMMARY

A previously healthy 75-year-old white male dentist presented with a 6-month history of low-back pain treated with chronic steroid therapy had a *Nocardia farcinica* infection diagnosed by aspirate of thyroid abscess and six blood cultures. Despite the treatment with parenteral combination of trimethoprim/sulfamethoxazole, the patient failed to respond and died after two days of therapy. Autopsy revealed disseminated nocardiosis, involving lungs with pleural purulent exudate in both sides, heart, thyroid, kidneys, brain, bones, and lumbosacral soft tissue with destruction of L2-L4.

KEYWORDS: *Nocardia*; *Nocardia farcinica*; Thyroiditis; Disseminated nocardiosis; Bacteremia; Osteomyelitis; Psoas Abscess.

INTRODUCTION

Nocardiosis is an uncommon but worldwide infectious disease, with reported cases increasing in number among patients with immunosuppression^{1,14}. In human, nocardiosis is most frequently caused by *Nocardia asteroides* complex that includes two established species, *N. nova* and *N. farcinica*. *N. farcinica* has been reported to cause a variety of infections and affecting almost every organ, but very rarely the infection is diagnosed by blood culture^{12,15,17,19,21} and from spine lesion⁶. To our knowledge, only four cases of *Nocardia* thyroiditis have been published^{3,13,22} and this is the first reported case on *N. farcinica* as the pathogen responsible for thyroid abscess.

The purpose of our report was to show that a negative diagnosis of malignancy is the key to a presumptive diagnosis of more rare infectious condition. Because of the considerable morbidity and mortality of untreated disease, we advocate a high index of suspicion for nocardiosis and routine microbiology should attempt to identify it.

CASE REPORT

A previously healthy 75-year-old white male dentist, with cough productive of purulent sputum and low-grade fever associated with a recurrent chronic low-back pain that began six months prior to admission was referred to our hospital in June 2001 for complementary investigation. He had been treated with various regimens of corticosteroids, especially prednisone (20-30 mg/d). On physical examination his temperature was 38 °C, heart rate was 100, respirations

were 22/min, and blood pressure was 130/80 mm Hg. There were no antibodies to the human immunodeficiency virus (HIV). Radiological studies, including computed tomography (CT) and magnetic resonance imaging (MRI) scan, revealed changes in soft tissue of lumbosacral region with partial destruction of L2-L4 vertebrae. With presumptive diagnosis of multiple myeloma or bone metastasis, four biopsies were performed on different occasions (three at vertebral bodies and one at scapula). No specific diagnosis was made. Based on clinical and radiological findings strongly suggestive of neoplasia the patient underwent radiotherapy for metastatic spine cancer and because of the deterioration of the physical conditions, persistent low-back pain, and elevation of intracranial pressure intravenous dexamethazone (4 mg every six hours) was instituted.

The patient was discharged from the hospital, with corticotherapy, but three days later he was readmitted to the hospital because of persistent fever and continued deterioration of clinical condition. On reexamination, a node was palpable at the thyroid right lobe and his chest showed signs of consolidation in both lower zones.

The contrast-unenhanced CT scan of the head showed two nodules that became hyperdense, located in the basal ganglia region. A MRI scan of the head showed the same two nodules.

A CT scan of the chest demonstrated multiple nodules and consolidation throughout both lungs, predominantly in the lower lobes (Fig. 1). Bilateral pleural effusions were also present.

(1) Laboratório de Micologia, Hospital Santa Rita, Santa Casa Complexo-Hospitalar, Porto Alegre, RS, Brasil.

(2) Serviço de Tomografia, Hospital Santa Rita, Santa Casa Complexo-Hospitalar, Porto Alegre, RS, Brasil.

(3) Biologia Molecular, Weinmann Laboratório, Porto Alegre, RS, Brasil.

Correspondence to: Dr. Luiz Carlos Severo, Laboratório de Micologia, Hospital Santa Rita, Santa Casa Complexo Hospitalar, Annes Dias 285, 90020-090 Porto Alegre, RS, Brasil. Phone: +55 51 32285208. E-mail: severo@santacasa.tche.br

The CT scan of thoracolumbar spine and pelvis showed iliac and sacral osteolytic lesions and partial destruction of several vertebral bodies in thoracic and lumbar spine. The osseous destruction was more extensive in L2-L4. T1-weighted MRI scan with gadolinium contrast demonstrated multiple lesions with hypointense (T1) and hyperintense periphery (T2) in thoracolumbar spine (Fig. 2). Abscesses formation in both psoas muscles was present.

A CT post contrast of the neck demonstrated hypodense lesion (66 UH) in the right thyroid lobe. This nodule was aspirated with a thick needle (Fig. 3) and four mL of a purulent liquid was obtained.

MICROBIOLOGIC METHODS

A gram-stained smear of the abscess fluid showed gram-positive filaments that were also stained positively by Ziehl-Neelsen stain (Fig. 4). Portion of the exudates was inoculated onto Sabouraud dextrose agar and blood agar. *Nocardia*-like organisms were noted after six days of incubation. Blood cultures were automatically checked for bacterial growth using BacT/ALERT® SA (Organon Tecnica) system, and the same *Nocardia*-like microorganisms was yielded from six different

culture bottles. Sputum examination revealed a gram-positive, acid-fast branching organism consistent with *Nocardia*, but cultures were all negative.

MOLECULAR IDENTIFICATION OF *Nocardia*

DNA was obtained from a bacterial suspension using the guanidine-isothiocyanate modified method⁹, and the 16S rRNA gene (ca. 1500 bp) was amplified using primers 285 (5' - GAGAGTTTGATCCTGGCTCAG - 3') and 261 (5' - AAGGAGGTGATCCAGCCGCA - 3')¹⁰, and GeneAmp™ PCR reagent kit (Applied Biosystems). PCR products were cleaned using shrimp alkaline phosphatase and Exonuclease I (USB). The firsts 500 bp nucleotides were determined using primers 352-F (5' - CAGACTCCTACGGGAGGC - 3') and 16S-R (5' - TATTACCGCRGCTGCTGG - 3') and big dye terminator DNA Sequencing kit (Applied Biosystems), as described elsewhere⁵. Homology search revealed 100% homology with several sequences of *N. farcinica* deposited in the GenBank. Moreover, we noted the presence of the sequence 5'-TTACATC-3' at the position 149 to 155 (compared to *N. asteroides* ATCC 19247), which is exactly the variable site for *N. farcinica* proposed by CONVILLE *et al.*⁴.

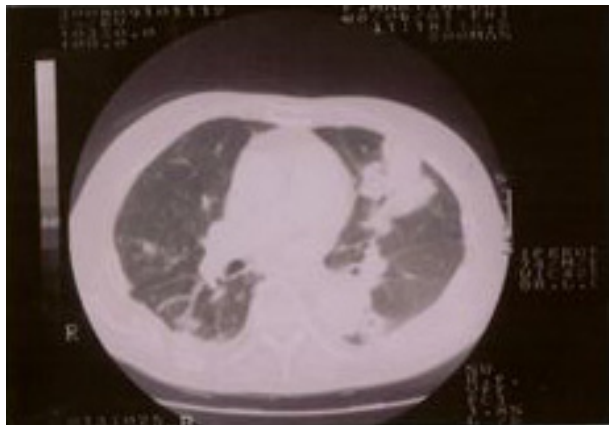


Fig. 1 - CT scan of the chest showing multiple nodules and consolidation throughout both lungs.

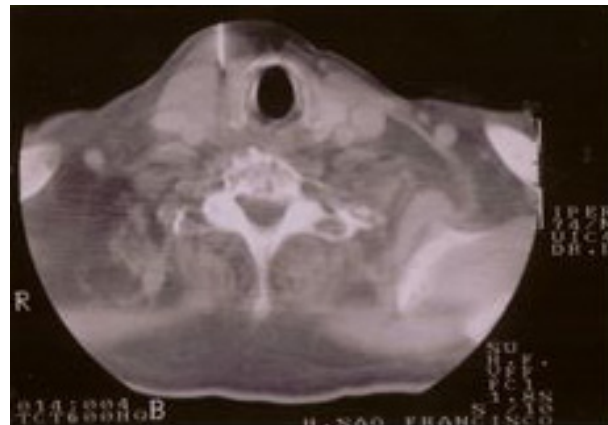


Fig. 3 - Axial CT scan of the neck showing the CT-guided needle biopsy of the thyroid abscess.

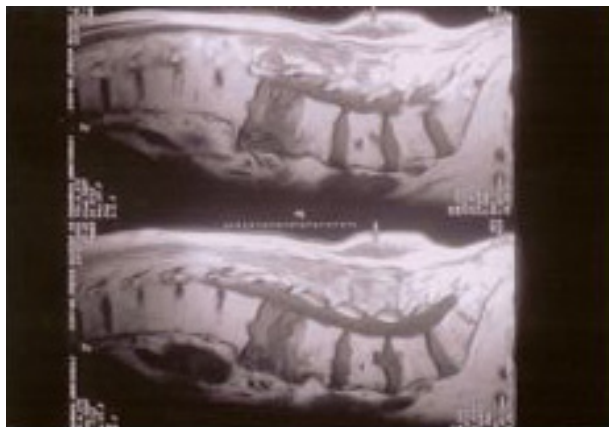


Fig. 2 - T2-weighted magnetic resonance imaging demonstrating destruction of the vertebral bodies of L2-L4.

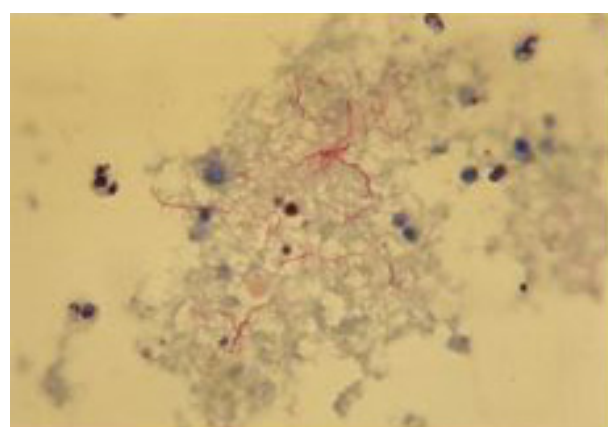


Fig. 4 - A smear of pus aspirated from thyroid abscess stained with Ziehl-Neelsen shows delicate branched, acid-fast filaments of *N. farcinica*.

Patient's evolution: Despite the prompt initiation of therapy with intravenous trimethoprim/sulfamethoxazole (TMP/SMX) 320/1600 mg every six hours, the patient rapidly developed respiratory distress and died on the second day of treatment.

At autopsy systemic nocardiosis was present. The histopathologic sections revealed multiple abscesses formation throughout the body organs including lungs with pleural purulent exudate in both sides, heart, thyroid, kidneys, brain, bones, and lumbosacral soft tissue with destruction of L2-L4. Special stain for acid-fast bacilli revealed numerous delicate, branched filaments within the purulent centers. Gram stain of tissue clearly demonstrate the same delicate gram-positive filaments. The searches for malignant cells in those organs were all negative.

DISCUSSION

In 1888, on the Guadeloupe Island, the veterinarian Edmond Nocard described *N. farcinica* by the first time, from a case of bovine farcy¹⁶. The increasing frequency of *N. farcinica* as a cause of severe human nocardiosis is because of AIDS and the resistance of this species of *Nocardia* to most antimicrobial agents².

The most common sites of infection are lung, pleural, and chest wall (43%). The clinical presentation is protean and the findings on chest radiographs are non-specific. The infection often spreads to the brain (30%), kidney, bones, and deep-seated soft tissues; usually the host has underlying immunosuppressive conditions (85%), specially impair of cell-mediated immunity by medications or serious underlying conditions²¹. We speculate that the use of corticosteroids over the course of many weeks led to unusual location (blood, spine, and thyroid) and the serious clinical manifestation of infection. This and the delayed institution of monotherapy with TMP/SMX⁷ both contributed to the death of this patient. We urge caution and restriction in the corticoids use.

N. farcinica infections in our patient bears both differences and similarities when compared with previously reported cases. First, no case of *N. farcinica* thyroiditis has been reported. The extreme rarity of suppurative thyroiditis is attributed to the anatomic isolation of the gland, its rich system of drainage, and the presumptive antibacterial effect of the high iodine concentration²². Second, only one other case of osteomyelitis has been reported⁶. Third, similarly to other reported case bacteremia was reported in a small number of cases as a preterminal finding^{12,15,17,19,21}. Is important to emphasise that cultures of *Nocardia* typically take more than five days. Because of this, *Nocardia* is often overlooked since routine cultures are discarded at three days. Fourth, as in our patient only occasionally psoas abscess is due to *N. farcinica*^{6,8,20}.

It is important to realize that *N. farcinica* has emerged as a pathogen that has often a wrong initial clinical diagnosis, as in the present case, that had clinical and radiological features strongly suggestive of cancer. By this reason, nocardiosis should always be considered in the differential diagnosis when a pulmonary mass with metastatic focuses develops in an immunocompromised patient.

Finally, we wish to emphasize the critical importance of early diagnosis to achieve good outcome. Only a high level of suspicion can make this with confirmation by biopsy. Microscopic study of stained smears of infected material could, in few minutes, direct one to appropriate therapy and culture gives the etiologic agent. Since phenotypic tests are too cumbersome or inaccurate to identify the species within the genera *Nocardia*¹¹, molecular methods such as 16S rRNA sequencing represent an important advance for rapid bacterial identification¹⁸. In the case of *Nocardia*, the correct identification of species is also warranted by the natural resistance of these organisms to most antimicrobial agents⁷.

RESUMO

Nocardiose disseminada por *Nocardia farcinica* diagnosticada através do cultivo de abscesso da tireóide

Paciente previamente hígido, homem de 75 anos, branco, dentista, apresentou história de seis meses de dor lombar, fez uso crônico de corticoterapia e teve diagnóstico de infecção por *Nocardia farcinica* através do aspirado de abscesso da tireóide e seis hemocultivos positivos. Apesar do tratamento com a combinação de sulfametoxazol/trimetoprim, o paciente não respondeu indo a óbito dois dias após. A necropsia revelou nocardiose disseminada, envolvendo ambos os pulmões, empiema bilateral, coração, tireóide, rins, cérebro, ossos, e tecidos moles lombossacrais, com destruição da L2-L4.

REFERENCES

1. BEAMAN, B.L. & BEAMAN, L. - *Nocardia* species: host-parasite relationships. **Clin. Microbiol. Rev.**, 7: 213-264, 1994.
2. BOIRON, P.; PROVOST, F.; CHEVRIER, G. & DUPONT, B. - Review of nocardial infections in France 1987 to 1990. **Europ. J. clin. Microbiol. infect. Dis.**, 11: 709-714, 1992.
3. CARRIERE, C.; MARCHANDIN, H.; ANDRIEU, J.M.; VANDOME, A. & PEREZ, C. - *Nocardia* thyroiditis: unusual location of infection. **J. clin. Microbiol.**, 37: 2323-2325, 1999.
4. CONVILLE, P.S.; FISCHER, S.H.; CARTWRIGHT, C.P. & WITEBSKY, F.G. - Identification of *Nocardia* species by restriction endonuclease analysis of an amplified portion of the 16S rRNA gene. **J. clin. Microbiol.**, 38: 158-164, 2000.
5. GERMER, J.J.; RYS, P.N.; THORVILSON, J.N. & PERSING, D.H. - Determination of hepatitis C virus genotype by direct sequence analysis of products generated with the Amplicor HCV test. **J. clin. Microbiol.**, 37: 2625-2630, 1999.
6. GRAAT, H.C.A.; VAN OOIJ, A.; DAY, G.A. & MCPHEE, I.B. - *Nocardia farcinica* spinal osteomyelitis. **Spine**, 15: E253-E257, 2002.
7. HITTI, W. & WOLFF, M. - Two cases of multidrug-resistant *Nocardia farcinica* infection in immunosuppressed patients and implications for empiric therapy. **Europ. J. clin. Microbiol. infect. Dis.**, 24: 142-144, 2005.
8. HOLM, P. - Seven cases of human nocardiosis caused by *Nocardia farcinica*. **Sabouraudia**, 13: 161-169, 1975.
9. JOHNSON, G.; NELSON, S.; PETRIC, M. & TELLIER, R. - Comprehensive PCR-based assay for detection and species identification of human herpesviruses. **J. clin. Microbiol.**, 38: 3274-3279, 2000.

10. KIRSCHNER, P.; MEIER, A. & BÖTTGER, E. - Genotypic identification and detection of mycobacteria – facing novel and uncultured pathogens. In: PERSING, D.H.; SMITH, T.F.; TENOVER, F.C. & WHITE, T.J., ed. **Diagnostic molecular microbiology principles and applications**. Washington, American Society for Microbiology, 1993.
11. KISKA, D.L.; HICKS, K. & PETTIT, D.J. - Identification of medically relevant *Nocardia* species with an abbreviated battery of tests. **J. clin. Microbiol.**, 40: 1346-1351, 2002.
12. KONTOYIANNIS, D.P.; RUOFF, K. & HOOPER, D.C. - *Nocardia* bacteremia: report of 4 cases and review of the literature. **Medicine (Baltimore)**, 77: 255-267, 1998.
13. LEONG, K.P.; TEE, N.W.; YAP, W.M.; CHEE, T.S. & KOH, E.T. - Nocardiosis in patients with systemic lupus erythematosus. The Singapore lupus study group. **J. Rheum.**, 27: 1306-1312, 2000.
14. McNEIL, M.M. & BROWN, J.M. - The medically important aerobic actinomycetes: epidemiology and microbiology. **Clin. Microbiol. Rev.**, 7: 357-417, 1994.
15. MINAMOTO, G.Y. & SORDILLO, E.M. - Disseminated nocardiosis in a patient with AIDS: diagnosis by blood and cerebrospinal fluid cultures. **Clin. infect. Dis.**, 26: 242-243, 1998.
16. NOCARD, E. - Note sur la maladie des boeufs de la Guadeloupe connue sous le nom de farcin. **Ann. Inst. Pasteur (Paris)**, 2: 293-302, 1888.
17. PETERS, B.R.; SAUBOLLE, M.A. & COSTANTINO, J.M. - Disseminated and cerebral infection due to *Nocardia farcinica*: diagnosis by blood culture and cure with antibiotics alone. **Clin. infect. Dis.**, 23: 1165-1167, 1996.
18. ROTH, A.; ANDREES, S.; KROPPESTEDT, R.M.; HARMSSEN, D. & MAUCH, H. - Phylogeny of the genus *Nocardia* based on reassessed 16S rRNA gene sequences reveals underspeciation and division of strains classified as *Nocardia asteroides* into three established species and two unnamed taxa. **J. clin. Microbiol.**, 41: 851-856, 2003.
19. SMILACK, J.D. - Images in clinical Medicine. Pulmonary and disseminated Nocardiosis. **New Engl. J. Med.**, 341: 885, 1999.
20. SMIT, L.H.M.; LEEMANS, R. & OVERBEEK, B.P. - *Nocardia farcinica* as the causative agent in a primary psoas abscess in a previously healthy cattle inspector. **Clin. Microbiol. Infect.**, 9: 445-448, 2003.
21. TORRES, O.H.; DOMINGO, P.; PERICAS, R. *et al.* - Infection caused by *Nocardia farcinica*: case report and review. **Europ. J. clin. Microbiol. infect. Dis.**, 19: 205-212, 2000.
22. VANDJME, A.; PAGEAUX, G.P.; BISMUTH, M. *et al.* - Nocardiosis revealed by thyroid abscess in a liver - kidney transplant recipient. **Transplant. Int.**, 14: 202-204, 2001.

Received: 27 April 2005

Accepted: 16 August 2005