

Rev. Inst. Med. trop. S. Paulo
46(1):43-46, January-February, 2004

RESPIRATORY TRACT INTRACAVITARY COLONIZATION DUE TO *Scedosporium apiospermum*. REPORT OF FOUR CASES

Luiz Carlos SEVERO(1), Flávio de Mattos OLIVEIRA(2) & Klaus IRION(3)

SUMMARY

Four cases of respiratory tract intracavitary colonization (fungus ball) due to *Scedosporium apiospermum* (teleomorph, *Pseudallescheria boydii*) are reported. The need for a careful search for anelloconidia, in order to establish the etiologic diagnosis in the clinical specimen by microscopy, is emphasized.

KEYWORDS: *Scedosporium apiospermum*; Scedosporiosis; *Pseudallescheria boydii*; Pseudallescheriosis; Respiratory intracavitary colonization; Fungus ball.

INTRODUCTION

Scedosporium apiospermum is classified as an ascomycetes; the homothallic teleomorph state is called *Pseudallescheria boydii*, previously named as *Allescheria* and *Petriellidium*. This fungus is ubiquitously found worldwide, occurring in nutrient-rich, poorly aerated environment, such as polluted water³.

The spectrum of disease in the respiratory tract is similar in terms of variety and severity to those caused by *Aspergillus*². Differential diagnosis¹ is mandatory because of the frequent resistance of *Scedosporium* to a variety of commonly used antimycotic agents⁶.

The noninvasive, colonization infection by *S. apiospermum* in a preformed¹⁰ or natural¹⁴ air space has been named in the literature as mycetoma^{13,15}, fungoma⁷, fungus ball^{8,10}, non-aspergillus aspergilloma⁵, and pseudallescherioma⁹. Mycetoma is recognized by tumefaction and draining sinuses, diagnosed by granules. Almost all cases of *S. apiospermum* infection are eumycotic white-grain mycetoma¹². Fungus ball consists of a mass of hyphal colonizing a cavity. The suffix "oma" must be restricted to fungal pulmonary nodule¹¹. An additional confusion arose from the SCHWARTZ¹² publication of a lung sequestrum by *S. apiospermum* termed fungoma (fungus ball). It is preferable to use intracavitary colonization because it encompasses the initial fungal growth or the true fungus ball⁵.

In this report, we describe four cases of *S. apiospermum* pulmonary intracavitary colonization (fungus ball) emphasizing the need for a careful search for histological demonstration of conidia, specially in cases without culture and in absence of *Aspergillus* conidial heads, because

some cases of scedosporiosis were mistakenly diagnosed on histologic examination as aspergillosis.

CLINICAL CASES

Case 1: A 45 year-old, white carpenter presenting rheumatic arthritis had been receiving prednisone (20 mg/day) for 4 years. At admission he complained of bouts of hemoptysis during the last two years. A chest x-ray revealed a cystic lesion occupying the apex of the right lung, with various oval masses in the dependent portion of this cavity (Fig. 1). No precipitin bands were obtained in immunodiffusion (ID) test with

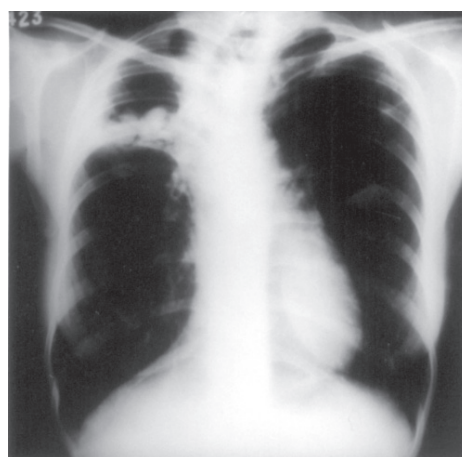


Fig. 1 - Case 1 - Chest-x ray shows various oval masses in the dependent portion of a cystic lesion in the apex of the right lung.

(1) Pesquisador 1c CNPq; Universidade Federal do Rio Grande do Sul, Porto Alegre, RS, Brasil.

(2) Laboratório de Micologia Clínica, Santa Casa - Complexo Hospitalar, Porto Alegre, RS, Brasil.

(3) Pavilhão Pereira Filho, Santa Casa - Complexo Hospitalar, Porto Alegre, RS, Brasil

Correspondence to: Dr. Luiz Carlos Severo. Laboratório de Micologia Clínica, Santa Casa - Complexo Hospitalar, Annes Dias 285, 90020-090 Porto Alegre, RS, Brasil. Fax: (55) 51 3214-8435.

Email:severo@santacasa.tche.br

Aspergillus fumigatus, *A. niger*, *A. flavus* and *Scedosporium apiospermum* antigens.

A lobectomy was performed. At cut section a post necrotic cavity, containing a dull greenish material was seen. Suppurative chronic inflammatory reaction, arterities and a partial coating composed of squamous metaplastic respiratory epithelium lined the cavitation. Suppurative chronic bronchopneumonia, bronchiectasis and interstitial fibrosis were also observed.

Histopathology: The intracavitary mass consisted of a network of hyaline, septate, branched hyphae and some oval conidia.

Mycology (cultures): Colonies of *S. apiospermum* were obtained in Sabouraud dextrose agar and incubated at 25 and 35 °C.

No antifungal therapy was administered. No evidence of recurrence was observed in a follow-up of two years.

Case 2: This patient was a 36 year-old, white, diabetic woman. She complained of chest pain on the right side, fever, cough with purulent expectoration, and dyspnea initiated two years ago. She received penicillin for ten days without improvement. She was non reactor to Mantoux test and had no history of tuberculosis. Linear tomogram showed a nodular mass with meniscus sign, in the right lower lobe (4.5 x 3.5 cm) with undefined border and within an irregular cavitation. The cavity was connected to the axial bronchus without bronchial stenosis.

A subsegmentar resection was performed. At cut section a mass inside a post necrotic cavity was seen. The wall of the cavity was partially composed of respiratory epithelium and presented signs of chronic suppurative reaction.

Histopathology: The mass was composed of intermingled branched septate hyphae and some conidia.

Mycology (cultures): *S. apiospermum* was isolated in Sabouraud dextrose agar and incubated at 25 and 35 °C.

The patient was successfully treated with surgery only.

Case 3: With a past history of tuberculosis, the patient, a 57 year-old white woman was admitted complaining of pain on the right side of the thorax and two bouts of hemoptysis in the previous three months. A chest roentgenogram showed partial fibroatelectasic retraction of the left upper lobe and a thin-walled cavity, which contained rounded opacity in its dependent portion (Fig. 2). Acid-fast bacilli were not detected in sputum examination; no precipitin bands were observed in ID test with aspergillins.

A lobectomy of the left upper lobe was performed. A mass (16 g) was removed from a post necrotic cavitation (9.5 x 7.5 cm). This cavitation was lined with chronic suppurative inflammatory tissue and a palissade of granulomata. The nodules and micronodules were composed of tuberculoid granulomata with caseous necrosis. Some nodules were calcified.

Histopathology: Hyaline, septate, branching hyphae and conidia were seen in microscopic examination of the mass.

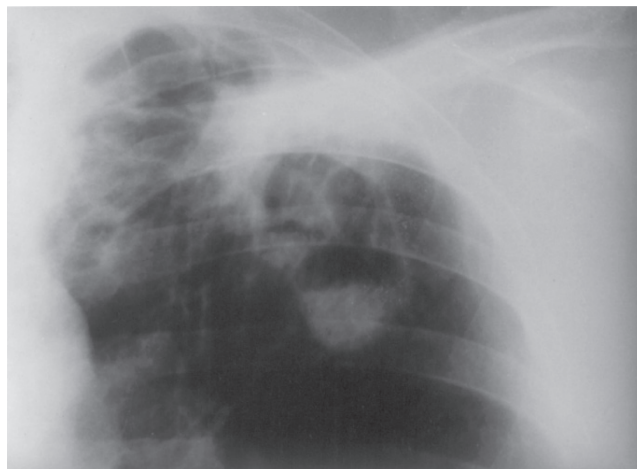


Fig. 2 - Case 3 - A chest roentgenogram shows partial fibroatelectasic retraction of the left upper lobe and a rounded opacity within the dependent portion of a thin-walled cavity.

Mycology (cultures): *S. apiospermum* was isolated in culture in Sabouraud dextrose agar and incubated at 25 and 35 °C, and later on, the appearance of cleistothecia led to the diagnosis of *P. boydii*.

One year after surgical treatment the patient was in good conditions.

Case 4: A 66-year-old, otherwise healthy man presented with chronic cough with purulent expectoration. He had an 8-year history of multiple antibiotic unsuccessful empirically treatments for various lengths of time.

A computed tomographic scan showed partial opacification of the left maxillary sinus along with thickening of the sinus mucosal with irregular soft tissue mass, with anfractuous contours, without calcifications and bone erosion (Fig. 3). The patient underwent to surgery that disclosed soft tissue mass occupying the left maxillary sinus.

Histopathology: The sinus content demonstrated dense conglomerated dichotomously branching septated hyphae with conidia

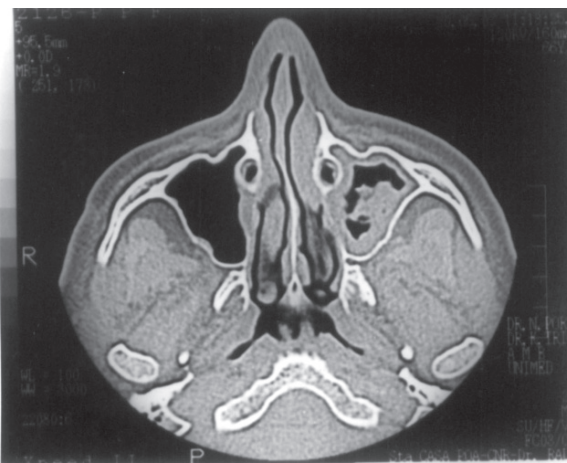

Fig. 3 - A computed tomographic scan shows partial opacification of the left maxillary sinus along with thickening of the sinus mucosal with irregular soft tissue mass, with anfractuous contours.

of *S. apiospermum*. Hematoxylin and eosin-stained tissue showed mucosal chronic inflammation without tissue invasion.

Mycology (cultures): Fragments of the ball were cultured on Sabouraud dextrose agar and incubated at 25 and 35 °C. Cultures were positive within a week, yielding colonies of *P. boydii*.

Surgical treatment resulted in complete recovery of the patient.

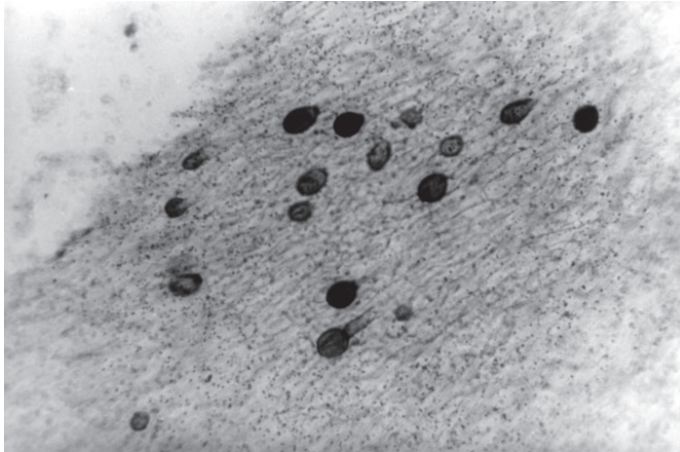


Fig. 4 - The evidence of single terminal anneloconidia is clearly visible. Note short anneloconidiophores.

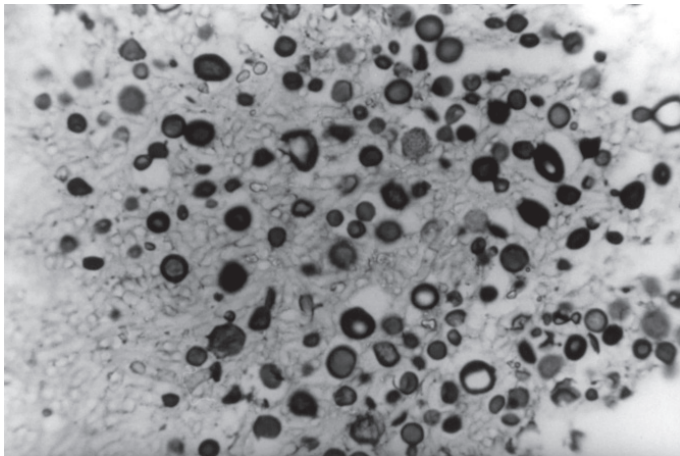


Fig. 5 - Intermediate zone of the fungus ball - both anneloconidia and chlamydospores are seen.

Histopathologic findings of the fungus ball: Tissue sections were prepared with fixation in 10% formalin and stained with hematoxylin-eosin (H&E) and Gomori's methenamine-silver (GMS). The diagnosis of fungal ball was made by the demonstration of mass of fungi consisting of compact hyphae characterized by concentric rings of growth with distorted, aberrant and bulbous central hyphal strands. The conidia produced in the inner part of the fungal growth (Fig. 4) and the chlamydospores in the periphery of the ball (Fig. 5) made the diagnosis of *S. apiospermum* and the cleistothecia observed in culture confirmed *P. boydii* (Fig. 6).

DISCUSSION

The definitive etiologic characterization of *S. apiospermum* respiratory tract intracavitary colonization requires recovery of the organism by culture from the cavity (Table 1). However, serum precipitins may be of aid in diagnosis¹⁰ and can be used as a screening test.

When cultural confirmation is not available, proof of the etiologic agent could be obtained by histopathologic examination. Fungus ball due to *S. apiospermum*, on haematoxylin and eosin stained sections, is primarily composed by tangled septate hyaline hyphae that is distinguished from *Aspergillus* by direct-immunofluorescence⁴.

Other microscopically distinctive features are the production of anneloconidia and chlamydospores in the fungus ball. Anneloconidia represents an actively growing element of the fungus deeply in the

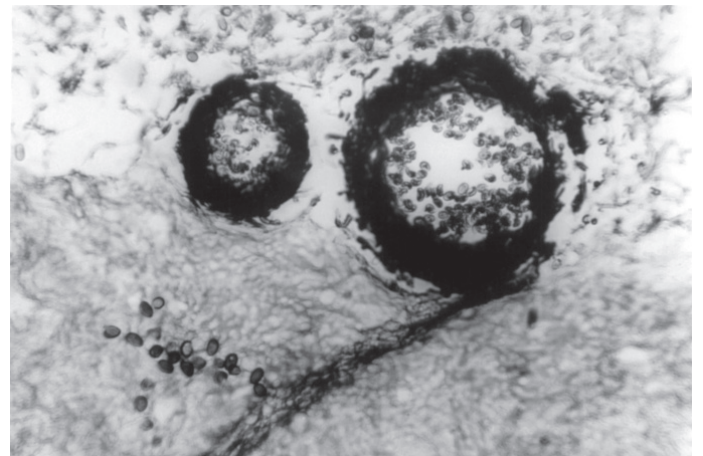


Fig. 6 - Section of colony recovered from the lung cavity shows cleistothecia and ascospores of *P. boydii*.

Table 1
Demographic and clinical manifestations of four patients with *Scedosporium apiospermum* infection

Case	Sex,age	Primary disease; previous treatment	Site	Pathology; culture	Treatment; outcome
1	M,45	Rheumatic arthritis; corticosteroid therapy	Lung: right upper lobe	Conidia; <i>S.a.</i>	Surgery; recovered
2	F, 36	Diabetes mellitus	Lung: right lower lobe	Conidia; <i>S.a.</i>	Surgery; recovered
3	F, 57	Tuberculosis	Lung: left upper lobe	Conidia; <i>S.a. (P.b.)</i>	Surgery; recovered
4	M,66	None	Maxillary sinus	Conidia; <i>S.a. (P.b.)</i>	Surgery; recovered

S.a., *Scedosporium apiospermum*; *P.b.*, *Pseudallescheria boydii*

zation of hyphal growth. The peripheral zone is composed of densely packed aggregation of large, thickwalled chlamydoconidia. Among these, one can observe an intermediate zone with both fungal elements. These findings raise the hypothesis that the chlamydoconidia constitute a phase of the anelloconidia that comes up in contact with an air space.

Finally, surgical removal of the fungus ball is the most successful method of treatment of respiratory tract intracavitary colonization by *S. apiospermum* as observed in our patients.

RESUMO

Colonização intracavitária do trato respiratório por *Scedosporium apiospermum*. Relato de quatro casos

São relatados quatro casos de colonização intracavitária (bola fúngica) do trato respiratório por *Scedosporium apiospermum* (telemorfo, *Pseudallescheria boydii*). É enfatizada a necessidade de cuidadosa busca de aneloconídios, a fim de estabelecer o diagnóstico etiológico no espécime clínico, através da microscopia.

ACKNOWLEDGEMENTS

We wish to thank Dr. Leo Kaufman (CDC, Atlanta, GA, USA) for performing the immunodiffusion tests.

REFERENCES

1. AL REFAI, M.; DUHAMEL, C.; LE ROCHAIS, J.P. & ICARD, P. - Lung scedosporiosis: a differential diagnosis of aspergillosis. **Europ. J. cardio-thorac. Surg.**, 21: 938-939, 2002.
2. CREMER, G. & BOIRON, P. - Epidemiology and biology of *Scedosporium* species. **J. Mycol. Med.**, 6: 165-171, 1996.
3. de HOOG, G.S.; MARVIN-SIKKEMA, F.D.; LAHPOOR, G.A. *et al.* - Ecology and physiology of the emerging opportunistic fungi *Pseudallescheria boydii* and *Scedosporium prolificans*. **Mycoses**, 37: 71-78, 1994.
4. KAUFMAN, L. - Immunohistologic diagnosis of systemic mycoses: an update. **Europ. J. Epidem.**, 8: 377-382, 1992.
5. KATHURIA, S.K. & RIPPON, J. - Non-aspergillus aspergilloma. **Amer. J. clin. Path.**, 78: 870-873, 1982.
6. MELETIADIS, J.; MEIS, F.G.M.; MOUTON, J.W. *et al.* - *In vitro* activities of new and conventional antifungal agents against clinical *Scedosporium* isolates. **Antimicrob. Agents Chemother.**, 46: 62-68, 2002.
7. RIPPON, J.W. & CARMICHAEL, J.W. - Petriellidiosis (Allescheriosis): four unusual cases and review of literature. **Mycopathologia (Den Haag)**, 58: 117-124, 1976.
8. SAITO, Y.; MIKANI, M.; NAKAMURA, S. *et al.* - [Pulmonary pseudallescheriasis in a patient with diabetes mellitus and alcoholic liver cirrhosis]. **Nihon Kokyuki Gakkai Zasshi**, 36: 498-502, 1998.
9. SAWADA, M.; ISOGAI, S.; MIYAKE, S.; KUBOTA, T. & YOSHIZAWA, Y. - Pulmonary pseudallescherioma associated with systemic lupus erythematosus. **Intern. Med.**, 37: 1046-1049, 1998.
10. SEVERO, L.C.; LONDERO, A.T.; PICON, P.D.; RIZZON, C.F. & TARASCONI, J.C. - *Petriellidium boydii* fungus ball in a patient with active tuberculosis. **Mycopathologia (Den Haag)**, 77: 15-17, 1982.
11. SEVERO, L.C.; PORTO, N.S. & LONDERO, A.T. - Pulmonary scedosporiosis. **Rev. Inst. Med. trop. S. Paulo**, 40: 241-243, 1998.
12. SCHWARTZ, D.A. - Organ-specific variation in the morphology of the fungomas (fungus balls) of *Pseudallescheria boydii*: development within necrotic host tissue. **Arch. Path. Lab. Med.**, 113: 476-480, 1989.
13. STANLEY, M.W.; DEIKE, M.; KNOEDLER, J. & IBER, C. - Pulmonary mycetomas in immunocompetent patients: diagnosis by fine-needle aspiration. **Diagn. Cytol.**, 8: 577-579, 1992.
14. TADROS, T.S.; WORKOWSKI, K.A.; SIEGEL, R.J.; HUNTER, S. & SCHWARTZ, D.A. - Pathology of hyalohyphomycosis caused by *Scedosporium apiospermum* (*Pseudallescheria boydii*). An emerging mycosis. **Hum. Path.**, 29: 1266-1272, 1998.
15. ZAAS, D. - Cases from the Osler Medical Service at Johns Hopkins University. *Scedosporium apiospermum* mycetoma of the lung. **Amer. J. Med.**, 113: 760-762, 2002.

Received: 19 August 2003

Accepted: 23 December 2003