

Rev. Inst. Med. trop. S. Paulo
44 (1):49-52, January-February, 2002.

CASE REPORT

PARINAUD'S OCULOGLANDULAR SYNDROME ASSOCIATED WITH PARACOCCIDIOIDOMYCOSIS

Paulo Sérgio Gonçalves da COSTA(1,2,3), Beatriz Vitória Sabbagh HOLLANDA(6), Raimunda Violante Campos de ASSIS(7), Sandra Márcia Carvalho Ribeiro COSTA(7) & Lena Márcia de Carvalho VALLE(4,5)

SUMMARY

The authors report one case of Parinaud's oculoglandular syndrome associated with *Paracoccidioides brasiliensis* infection. No other medical report of this condition was found in the medical literature available at Index Medicus and Medline.

The eye involvement has been rather uncommon in paracoccidioidomycosis and this report emphasizes the possibility of this kind of presentation making it also necessary to include paracoccidioidomycosis among the several known causes of Parinaud's oculoglandular syndrome.

KEYWORDS: Parinaud's oculoglandular syndrome; Conjunctivitis; Paracoccidioidomycosis.

INTRODUCTION

Parinaud's oculoglandular syndrome is a curious medical condition characterized by granulomatous conjunctivitis associated with homolateral cervical and either pre or retro auricular lymph adenopathy¹⁶. It has been associated with several different infectious diseases¹, especially to cat scratch disease (*Bartonella henselae*)^{22,24,27,28,29,32}, but at times it has been reported in granulomatous chronic infectious like tuberculosis and atypical mycobacteria infections¹ and syphilis¹. Fungal infections also have been associated to this syndrome especially sporotrichosis (*Sporothrix schenckii*)¹, blastomycosis (*Blastomyces dermatitidis*)^{1,4}, and at least on one occasion, to coccidioidomycosis (*Coccidioides immitis*)⁷.

Paracoccidioidomycosis is by far the most important endemic mycosis in South America^{9,13,27}. The association between Parinaud's oculoglandular syndrome and paracoccidioidomycosis hasn't been reported so far.

We report here one typical case of Parinaud's oculoglandular syndrome, which had *Paracoccidioides brasiliensis* as its etiological agent. We further overviewed the literature about other possible infectious causes of this syndrome.

CASE REPORT

A 31-year-old black man was admitted to the hospital because of

cervical lymphadenopathy which had started five months earlier, associated with low grade fever, malaise and weight loss. Since the very beginning of his illness he had complained of pain and a purulent discharge in the right eye. His clinical picture evolved in a very indolent way and the patient only received topical therapy for a supposed bacterial conjunctivitis. As his clinical picture deteriorated a cervical lymph node biopsy was performed giving rise to the diagnosis of paracoccidioidomycosis and the patient was transferred to our service for treatment. At the physical examination one could see a thin man with cervical lymphadenopathy (Fig. 1-a), associated with increased right pre and retro auricular lymph nodes. Those lymph nodes were swollen, slightly painful and one located at the right cheek showed sinus drainage. The most prominent lymph node was aspirated (Fig. 1-b) and viscous yellow pus was obtained which was shown to be negative for fungi on direct examination. Another lymph node was further biopsied confirming the diagnosis of paracoccidioidomycosis. No mucosal lesions were seen but his ophthalmologic examination revealed prominent right eye conjunctivitis especially in the bulbar upper inner conjunctiva (Fig. 1-c). This lesion was biopsied and the histological pattern is shown in Fig. 2. Cultures at Sabouraud's medium were negative but serology by double radial immunodiffusion using GP 43 *Paracoccidioides brasiliensis* antigen rich fraction⁸ was positive at a title of 1/32. A chest X-ray showed a diffuse alveolointerstitial infiltrate (Fig. 1-d) and the sputum analysis revealed the presence of *Paracoccidioides brasiliensis* forms. Other blood tests were unremarkable. The patient was given cotrimoxazole and showed continuous improvement, being discharged after 3 weeks.

(1) Post graduate course of Tropical Medicine, Federal University of Minas Gerais, Belo Horizonte, Minas Gerais, Brazil.

(2) Monte Sinai Hospital, Infectious Diseases Unit, Juiz de Fora, Minas Gerais, Brazil.

(3) Barbacena Medical School (UNIPAC), Infectious Diseases Discipline, Barbacena, MG, Brazil.

(4) Post graduate course of Infectious Diseases, University of São Paulo, São Paulo, Brazil.

(5) Hospital João Penido, Juiz de Fora, Minas Gerais, Brazil.

(6) Monte Sinai Hospital, Ophthalmology Department-CECON, Juiz de Fora, Minas Gerais, Brazil.

(7) CIDAP Pathology Laboratory Monte Sinai Hospital, Juiz de Fora, Minas Gerais, Brazil

Correspondence to: Dr. Paulo Sérgio Gonçalves da Costa, Rua Delfim Moreira 181-902, 36010-570 Juiz de Fora, MG, Brasil; E-mail: psgcosta@fusoos.com.br

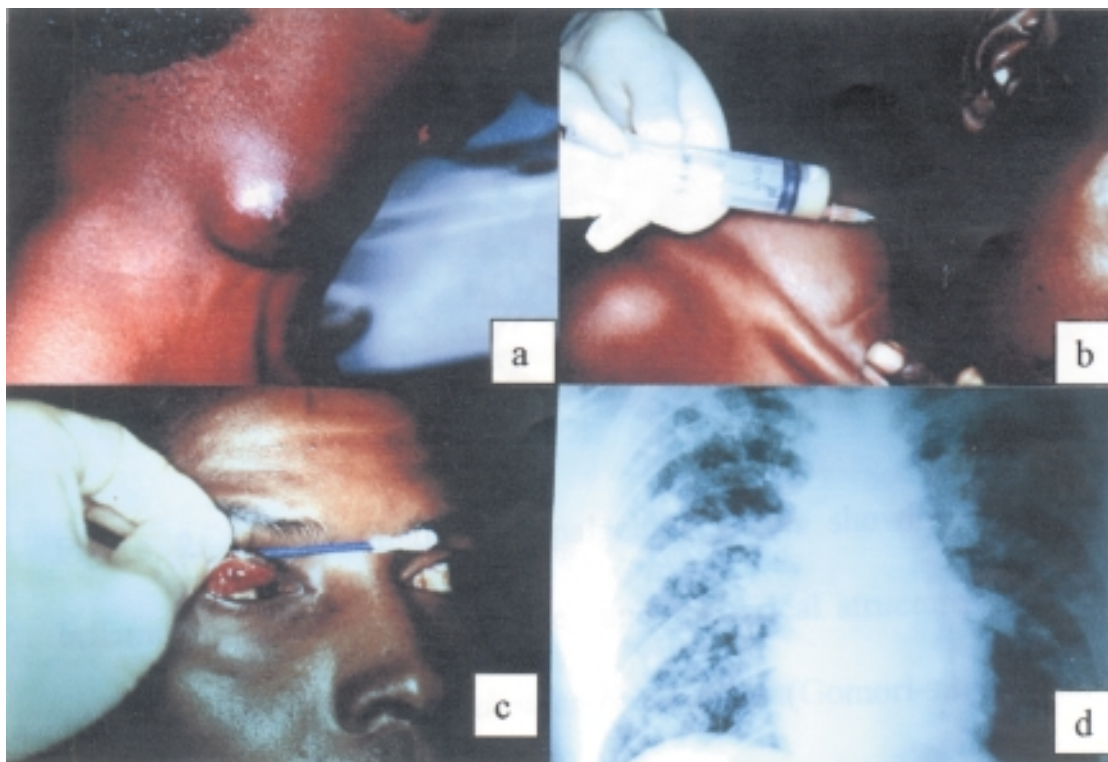


Fig. 1 - a) Cervical lymphadenopathy showing swollen lymph nodes, b) aspiration showing a viscous yellow pus, c) prominent right eye conjunctivitis specially in bulbar upper inner conjunctiva and d) chest X-ray showing a diffuse alveolointerstitial infiltrate.

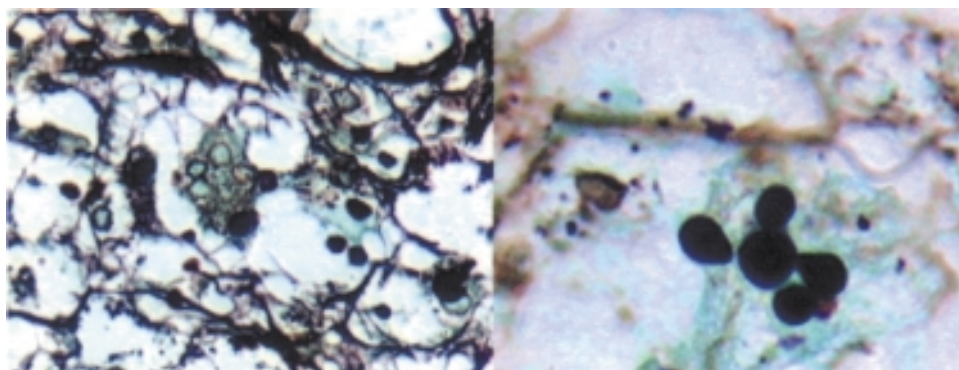


Fig. 2 - Histopathology of palpebral lesion showing granulomatous inflammation of connective tissue and spherical structures with budding compatible with *Paracoccidioides brasiliensis* (Gomori-silver stain X 200 and X 400).

DISCUSSION

The purpose of this paper is to emphasize the peculiar ophthalmologic aspects of this case of paracoccidioidomycosis, which is compatible with Parinaud's oculoglandular syndrome^{1,31}.

Parinaud's oculoglandular syndrome has been characterized by the combination of unilateral granulomatous conjunctivitis and enlarged

regional lymph nodes¹. These lymph nodes usually located at the preauricular, submaxillary, or submandibular areas are often tender^{1,31}. By far the most prevalent cause has been cat scratch disease caused by *Bartonella henselae* infection^{22,24,29,32}, but other infectious agents have also been associated.

Blastomycosis^{1,4}, tularemia¹⁹, tuberculosis and atypical mycobacteria infection¹, actinomycosis¹, syphilis¹, listeriosis¹, chancroid¹ and

lymphogranuloma venereum¹ have been reported as causes of this syndrome. Other associated infections include *Pasteurella multocida*^{1,3}, *Yersinia enterocolitica*^{1,17}, *Yersinia pseudotuberculosis*²³, *Pseudomonas mallei*¹, *Herpes simplex type I*⁵, *Epstein-Barr virus*^{25,26} and *Rickettsia conori* infections^{1,21}.

There is no other previous report of Parinaud's oculoglandular syndrome associated with paracoccidioidomycosis according to a Medline search as well as the medical literature available in Index Medicus.

BELFORT Jr. *et al.*⁶ described a possible case of Parinaud's oculoglandular syndrome caused by *Paracoccidioides brasiliensis* but this report didn't mention it as that, just emphasizing the simultaneous attack of conjunctiva and the draining lymph nodes which by the way have been considered the usually typical characteristics of that syndrome.

BURNIER & SANT'ANNA¹⁴, described two cases of eyelid paracoccidioidomycosis, which were the first sign of the disease. Importantly, in both cases the first clinical diagnosis made was not a fungal infection, but of a neoplastic. According to this report no lymphadenopathy was observed so the diagnosis of Parinaud's oculoglandular syndrome could be ruled out.

SILVA *et al.* in 1988³⁰ reported six cases of ocular paracoccidioidomycosis causing a heterogeneous group of lesions, including two cases of conjunctivitis. These authors also updated what had been published up to that time regarding ocular paracoccidioidomycosis but again no description could fit with Parinaud's oculoglandular syndrome.

Conjunctivitis has been considered the most frequent clinical form of ocular lesion in human paracoccidioidomycosis considering the extreme rarity of eye involvement in this disease^{5,7,27,30}.

Another infrequent but severe ocular form of this disease is coriorretinitis with only four cases described as of 1986².

Several hypotheses have been raised to explain ocular paracoccidioidomycosis. According to experimental models, the severity and frequency of ocular lesions in animals, intracardially inoculated with *P. brasiliensis* cultures, suggest haematogenic dissemination of the fungus during septicemic stages^{12,18} but no one could rule out the possible role of lymphatic dissemination¹⁴, self-inoculation from other fungi-rich lesions¹, contiguous cutaneous spread¹⁴ or even direct inoculation from natural sources³⁰.

The practical importance of a syndromic diagnosis like Parinaud's oculoglandular syndrome lays in the diagnostic track it gives, considering the limited array of diseases associated with that syndrome.

On the other hand, ophthalmologists and pathologists must be aware of its occurrence especially in endemic regions in order to avoid diagnostic pitfalls.

Besides other ophthalmologic syndromes like chorioretinitis², anterior uveitis³⁰, choroidal lesions^{10, 30}, blepharitis³⁰, oculomotor nerve lesions²⁰ and conjunctivitis^{6,11,14,20,30}, *P. brasiliensis* can cause typical Parinaud's oculoglandular syndrome.

RESUMO

Síndrome oculoglandular de Parinaud associada à paracoccidioidomicose

Os autores relatam um caso de síndrome oculoglandular de Parinaud associada à infecção por *Paracoccidioides brasiliensis*.

Nenhum outro relato desta condição foi encontrado na literatura médica disponível pelo Index Medicus e Medline.

O envolvimento ocular é incomum na paracoccidioidomicose e este relato enfatiza a possibilidade deste tipo de apresentação, tornando-se necessário incluir a paracoccidioidomicose entre as várias causas conhecidas de síndrome oculoglandular de Parinaud.

ACKNOWLEDGMENTS

We are thankful to Robert Corley for the English review, to Dr. Zoilo Pires de Camargo for the *P. brasiliensis* antigens and especially to Dr. Carlos da Silva Lacaz for comments and suggestions.

REFERENCES

1. ALBORNOZ, M.B. - Paracoccidioidomycosis. Proceedings of the First Pan-American Symposium. Medellin, 1971. **Pan Amer. Hlth. Org. Scient. publ.**, 254: 142-145, 1972.
2. ARRUDA, W.O.; CANTO, M.A.S.; LODDO, G.; REBUFFI, V.F. & CARDOSO, M.A. - Paracoccidioidomicose ocular relato de um caso com coriorretinite posterior. **Rev. Inst. Med. trop. S. Paulo**, 28: 190-193, 1986.
3. BALSTER, L. & BOPP, S. - Okulo-glandulares Syndrom (Parinaud) durch *Pasteurella multocida* mit Hornhautbeteiligung Ein schwerer klinischer Verlauf. **Fortschr. Ophthalm.**, 84: 554-556, 1987.
4. BARTLEY, G.B. - Blastomycosis of the eyelid. **Ophthalmology**, 102: 2020-2023, 1995.
5. BELFORT, F. - Um caso de "blastomycose conjuntival". **S. Paulo méd.**, 2: 777-786, 1930.
6. BELFORT Jr., R.; FISCHMAN, O.; CAMARGO, Z.P. de & ALMADA, A. - Paracoccidioidomycosis with palpebral and conjunctival involvement. **Mycopathologia (Den Haag)**, 56: 21-24, 1975.
7. BETHLEM, E.P.; CAPONE, D.; MARANHAO, B.; CARVALHO, C.R. & WANKE, B. - Paracoccidioidomycosis. **Curr. Opin. Pulm. Med.**, 5: 319-325, 1999.
8. BLOTTA, M.H. & CAMARGO, Z.P. - Immunological response to cell-free antigens of *Paracoccidioides brasiliensis*: relationship with clinical forms of paracoccidioidomycosis. **J. clin. Microbiol.**, 31: 671-676, 1993.
9. BLOTTA, M.H.; MAMONI, R.L.; OLIVEIRA, S.J. *et al.* - Endemic regions of paracoccidioidomycosis in Brazil: a clinical and epidemiologic study of 584 cases in the southeast region. **Amer. J. trop. Med. Hyg.**, 61: 390-394, 1999.
10. BONOMO, P.P.; BELFORT Jr., R.; TSUNECHIRO, J.Y. & FILHO, O.G. - Choroidal granuloma caused by *Paracoccidioides brasiliensis*. A clinical and angiographic study. **Mycopathologia (Den Haag)**, 77: 37-41, 1982.
11. BRICK, M. - Ocular involvement in lymphatic paracoccidioidomycosis. **Acta ophthalm. (Kbh.)**, 47: 991-997, 1969.
12. BRITO, T. & FAVA NETTO, C. - Disseminated experimental South American blastomycosis of the guinea pig: a pathologic and immunologic study. **Path. et Microbiol. (Basel)**, 26: 29-43, 1963.

13. BRUMMER, E.; CASTANEDA, E. & RESTREPO, A. - Paracoccidioidomycosis: an update. **Clin. microbiol. Rev.**, **6**: 89-117, 1993.
14. BURNIER, S.V. & SANT'ANNA, A.E. - Palpebral paracoccidioidomycosis. **Mycopathologia (Den Haag)**, **140**: 29-33, 1997.
15. CAPUTO, G.M. & BYCK, H. - Concomitant oculoglandular and ulceroglandular fever due to herpes simplex type I. **Amer. J. Med.**, **93**: 577-580, 1992.
16. CHIN, G.N. & HYNDIUK, R.A. - Parinaud ocular conjunctivitis In: DUANE, T.D. & JAEGER, E.A., ed. **Clinical Ophthalmology**. Philadelphia, Harper Publ., 1985. p. 1-8.
17. CHIN, G.N. & NOBLE, R.C. - Ocular involvement in *Yersinia enterocolitica* infection presenting as Parinaud's oculoglandular syndrome. **Amer. J. Ophthalm.**, **83**: 19-23, 1977.
18. CONTI-DIAZ, I.A.; CABOT, P.E.; ARRIGONI, N. & GEZUELLE, E. - Blastomycosis sudamericana diseminada con coriorretinitis nodular posterior. **An. Fac. Med. Montevideo**, **49**: 541-548, 1964.
19. CROSS, T. - Tularemia in the United States. **Infect. Med.**, **14**: 881-890, 1997.
20. DANTAS, A.M.; YAMANE, R. & CAMARA, A.G. - South American blastomycosis: ophthalmic and oculomotor nerve lesions. **Amer. J. trop. Med. Hyg.**, **43**: 386-388, 1990.
21. ESPEJO, E.; BELLA, F.; ESPAULELLA, J. & ROMANILLOS, T. - Mediterranean spotted fever presenting as oculoglandular syndrome. **Trans. roy. Soc. trop. Med. Hyg.**, **82**: 642, 1988.
22. HUANG, M.C. & DREYER, E. - Parinaud's oculoglandular conjunctivitis and cat-scratch disease. **Int. Ophthalm. Clin.**, **36**: 29-36, 1996.
23. KAYSER, F.H.; KNAPP, W. & MARTENET, A. - *Pasteurella pseudotuberculosis* (syn. *Yersinia pseudotuberculosis*) als Ursache der Parinaudschen Conjunctivitis. **Albrecht Von Graefes. Arch. Klin. exp. Ophthalm.**, **173**: 64-70, 1967.
24. MARGILETH, A.M. - Cat-scratch disease: etiology, diagnosis, and therapy. **Infect. Med.**, **10**: 38-43, 1993.
25. MATOBA, A.Y. - Ocular disease associated with Epstein-Barr virus infection. **Surv. Ophthalm.**, **35**: 145-150, 1990.
26. MEISLER, D.M.; BOSWORTH, D.E. & KRACHMER, J.H. - Ocular infectious mononucleosis manifested as Parinaud's oculoglandular syndrome. **Amer. J. Ophthalm.**, **92**: 722-726, 1981.
27. NEGRONI, R. - Paracoccidioidomycosis (South American blastomycosis, Lutz's mycosis). **Int. J. Derm.**, **32**: 847-859, 1993.
28. PIEMONT, Y. & HELLER, R. - Bartonellosis. I. *Bartonella henselae*. **Ann. Biol. clin.**, **56**: 681-692, 1998.
29. REGNER, R. & TAPPERO, J. - Unraveling mysteries associated with cat-scratch disease, bacillary angiomatosis and related syndromes. **Emerg. infect. Dis.**, **1**: 16-21, 1995.
30. SILVA, M.R.; MENDES, R.P.; LASTORIA, J.C. *et al.* - Paracoccidioidomycosis: study of six cases with ocular involvement. **Mycopathologia (Den Haag)**, **102**: 87-96, 1988.
31. WOOD, T.R. - Ocular coccidioidomycosis. Report of a case presenting as Parinaud's oculoglandular syndrome. **Amer. J. Ophthalm.**, **64** (suppl. 3): 587-590, 1967.

Received: 8 May 2001

Accepted: 14 November 2001