

CONTRIBUTION TO THE LABORATORY DIAGNOSIS OF HUMAN CRYPTOSPORIDIOSIS

Isabel MARTINEZ(1) & Francisco Miguel BELDA NETO(2)

SUMMARY

Human cryptosporidiosis is an infection caused by *Cryptosporidium* spp, a coccidial protozoan of emergencial pathogenicity and responsible for severe and prostrating watery diarrhea, mainly in immunocompromised patients. Smears of stools submitted to concentration and staining by carbol fuchsin technique has been used in our laboratory as a diagnostic procedure for cryptosporidiosis. The long time observing the smears in the microscope due to the small size of the forms and the low contrast of the staining led us to introduce some modifications in the original protocol for the acid-fast staining. The smears were treated with the carbol fuchsin solution for 3 minutes as recommended by LENNETTE *et al.*, 1985 and the solution of the ethyl alcohol 70%-chloride acid 0.5% was used instead of the ethyl alcohol-sulfuric acid 5% recommended by HENRIKSEN & POHLENZ, 1981. Smears were treated with the discoloration solution for 2 minutes. These modifications promoted a better washing out of the excess of carbol fuchsin therefore increasing the dye efficiency. In such conditions, the visualization of protozoan oocysts on the slides examined became easier. They were observed by the contrast of their intense pink-reddish pigmentation against the blue background. It's worthwhile to emphasize that these modifications offer advantages when time and accuracy are concerned.

KEYWORDS: *Cryptosporidium* spp; AIDS; diagnosis

INTRODUCTION

Cryptosporidiosis is an infection caused by a protozoan parasite named *Cryptosporidium* spp, that colonizes epithelial cells of the gastrointestinal and respiratory tracts of vertebrates and is related, mainly, to enteric diseases in human beings¹.

The genus *Cryptosporidium* contains several species that were identified in a vast sort of hosts including mammals, birds, fishes, and reptiles¹¹. Although there are nineteen species described¹³ so far only *Cryptosporidium muris* and *Cryptosporidium parvum* are associated with mammals⁶. Nevertheless, considering the difficulties in the specific identification through the use of immunologic tests and molecular biology and the positive confirmation, so far, of existing species, the term *Cryptosporidium* spp has the preference when regarded to those secluded from humans¹⁵.

The first cases of human cryptosporidiosis were diagnosed by intestinal and rectum biopsies^{16,17}. Before 1978, the parasite used to be diagnosed histologically only in tissue sections and observed in the epithelial surface of the intestine by electron microscopy or by staining with hematoxylin and eosin, Giemsa, periodic acid-Schiff, or toluidine blue¹¹. POHLENZ *et al.*, 1978²¹ described the finding of *Cryptosporidium* oocysts in fecal material of young calves, since then the diagnosis of this protozoan has become essentially coprologic, although it shows some limitations.

Diagnostic methods for detection of oocysts in stool were already described by using agglutination techniques of latex particles covered with antibody anti-*Cryptosporidium*²⁰, direct immunofluorescence²⁴ and enzyme-linked immunosorbent assay²³. Although there are several sensitive and specific immunoserologic tests^{8,25,26} they require technical skills and sophisticated equipments. Therefore, these methods are not used routinely in the majority of laboratories. Fecal smears, stained by carbol fuchsin (acid-fast staining)¹⁰ were proposed as an alternative method to detect *Cryptosporidium* spp oocysts in stools.

In this report, the carbol fuchsin method was modified to further improve its performance in the diagnosis of cryptosporidiosis.

MATERIAL AND METHODS

Fecal samples of HIV-positive patients, with and without diarrhea, were analyzed. Patients were followed up regularly by the Special Health Service DST/AIDS program in Araraquara, SP, Brazil.

Samples were preserved in phosphate-buffered saline containing 10% formaldehyde and concentrated by using the formol ether²² or the formalin ethyl acetate²⁷ techniques. Smears were prepared on glass slides, dried and methanol fixed. Stools of young pigs containing oocysts of *Cryptosporidium* spp were used as positive control.

(1) Pos-Graduated in Clinical Analysis, Faculdade Ciências Farmacêuticas-UNESP, Araraquara, SP, Brasil.

(2) Full Professor, Department of Biological Sciences, Parasitology, Faculdade Ciências Farmacêuticas UNESP, Araraquara, SP, Brasil.

Correspondence to: Isabel Martinez, Dep. Ciências Biológicas, Parasitologia, Faculdade Ciências Farmacêuticas, UNESP, 14801-902 Araraquara, SP, Brasil. Tel. (0XX16) 232 0200 R. 294. e-mail: martinez@fcar.unesp.br

Samples were treated with carbol-fuchsin solution for 3 minutes. The discoloration procedure was realized with ethyl alcohol 70%-chloride acid 0.5% for 2 minutes. Smears were washed with running water and counterstained with solution of methylen blue at 1% for 1 minute. After the final wash with water, slides were dried at room temperature. Slides were analyzed by optical microscopy (Jenaval - Carl Zeiss) using 250x and 1000x magnification (immersion).

RESULTS

The acid-fast stain method modified by us in this report confirmed the presence of *Cryptosporidium* spp oocysts in fecal samples of HIV-

positive patients. Oocysts can be seen as an intense pink-reddish body in contrast with the blue background (Fig. 1 and 2).

Results obtained in this study revealed an effective improvement in the oocysts detection when compared to the acid-fast staining method described previously (Fig. 3 and 4).

DISCUSSION

Cryptosporidiosis was initially diagnosed in intestinal biopsy^{16,17}. At present the diagnosis is basically coprologic, although not all routine techniques have been proved effective. The staining methods described

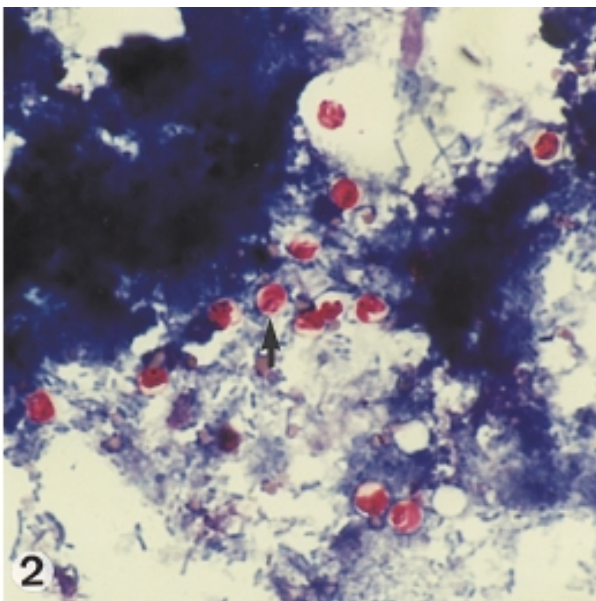
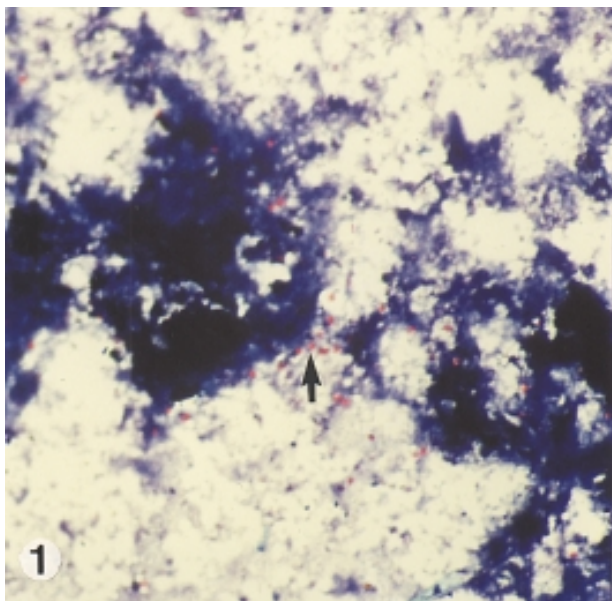


Fig. 1 and 2 - *Cryptosporidium* spp oocysts in fecal smear. Acid-fast staining using alcohol-chloride acid solution (250x and 1000x).

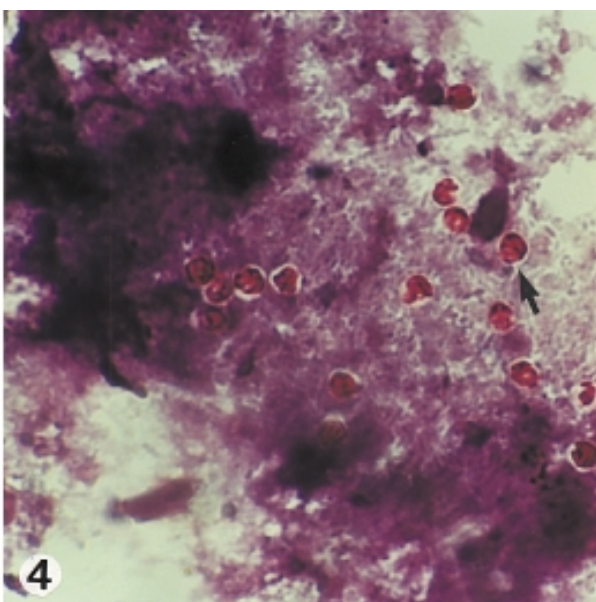
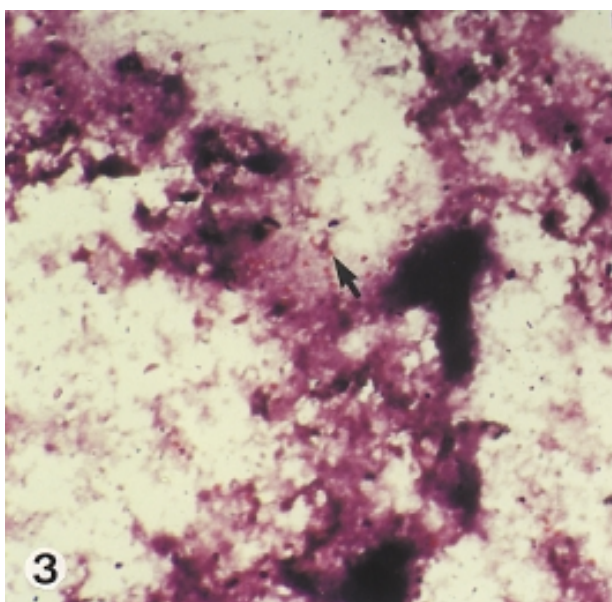


Fig. 3 and 4 - *Cryptosporidium* spp oocysts in fecal smear. Acid-fast staining using alcohol-sulfuric acid solution (250x and 1000x).

so far are based on the alcohol-acid fast property of coccidia oocysts. These methods when used in smears of concentrated stools have been proved to be very efficient in the detection of oocysts, increasing the diagnostic value of coprologic tests¹¹.

In the literature, a large number of coprologic techniques are based on the direct examination of wet smears⁵ or smears treated with lugol¹⁴, phenic fuchsin⁹, methanamine silver¹, nigrosin¹⁸, auramine-rhodamine⁷, acridine orange¹⁴, Giemsa², methylene blue/eosin⁴, safranin-methylene blue and modified periodic acid-Schiff¹¹. These staining techniques are not specific to *Cryptosporidium* and therefore are not used routinely in the coprologic diagnosis of cryptosporidiosis.

The diagnosis of cryptosporidiosis was improved with the discovery of the acid-fast property of *Cryptosporidium* oocysts. There are several staining techniques based on the original Ziehl Neelsen staining^{19,14,10,12}. Also, some modifications were proposed to eliminate the need of heating^{3,10}. In these acid-fast staining, the oocysts of *Cryptosporidium* spp are revealed as intense pink-reddish forms against a green or blue background depending on the dye used in the counterstaining step.

In this report some modifications were introduced in the acid-fast staining to further improve this technique. The treatment with carbol fuchsin was reduced from 30 (HENRIKSEN & POHLENZ, 1981)¹⁰ to 3 minutes (LENNETTE *et al.*, 1985)¹², and the alcohol sulfuric acid solution at 5% (HENRIKSEN & POHLENZ, 1981)¹⁰ used in the discoloration step gave place to the ethyl alcohol 70% - chloride acid 0.5%. Using this proposed procedure, the discoloration became more efficient since the excess of fuchsin was better removed. By counterstaining with methylene blue solution, the pink-reddish color of oocysts became highlighted against the blue background, making them visible even in a magnification of 250x (Fig. 1). The presence of *Cryptosporidium* oocysts was confirmed using a magnification of 1000x (Fig. 2). The modifications described in this report decreased the microscopy utilization time and made the slide analysis quicker and less tiring.

To compare the results obtained with this modification with those generated by using the original technique¹⁰, smears were also submitted to a discoloration with alcohol sulfuric acid solution. Using the original technique¹⁰, the slide analysis needed longer time on the microscope and greater visual accuracy to detect the oocysts of *Cryptosporidium* spp when using a 250x magnification (Fig. 3) or in a 1000x magnification (Fig. 4). The modified acid-fast staining, used in this investigation has shown to be effective, reliable and feasible at any laboratory of clinical analysis, due to the easy execution and low cost.

RESUMO

Contribuição ao diagnóstico laboratorial da criptosporidiose humana

A criptosporidiose humana é uma infecção causada pelo *Cryptosporidium* sp, um protozoário coccídeo de patogenicidade emergente e responsável por severa e prostrante diarreia aquosa em humanos, principalmente em indivíduos imunodeprimidos. O diagnóstico, feito através da utilização de esfregaços de fezes submetidos

a técnicas de concentração e coloração específica pela fucsina-carbólica tem oferecido bons resultados em nosso laboratório. Tendo em vista o longo tempo despendido para a observação dos esfregaços considerando-se a pequenez das formas e o contraste da coloração, realizamos modificações no procedimento técnico da coloração ácido-resistente que resultaram em sensível melhoria das preparações: a fucsina-carbólica passou a ser deixada sobre o esfregaço por período de 3 minutos (LENNETTE *et al.*, 1985) e procedeu-se a substituição da solução de álcool-ácido sulfúrico a 5% (HENRIKSEN & POHLENZ, 1981) por solução de ácido clorídrico a 0,5% em álcool etílico 70%, por cerca de 2 minutos (contribuição original). Estas alterações promoveram melhor remoção do excesso de fucsina-carbólica, aumentando a eficiência da etapa de descoloração e consequentemente otimizando o contraste do processo de coloração. Nestas condições, as lâminas examinadas em microscópio óptico em aumentos de 250x e 1000x tiveram a visualização dos oocistos do protozoário facilitada, sendo os mesmos observados em contraste destacado com pigmentação intensa de cor rosa-avermelhada contra coloração de fundo azulada. Vale destacar que estas modificações oferecem vantagens de rápido processamento do material e facilidade de visualização do protozoário, diminuindo o tempo de microscopia, tornando a análise das lâminas mais rápida e menos cansativa, agilizando o diagnóstico.

ACKNOWLEDGEMENTS

We are grateful to Prof. Dr. Sandro Roberto Valentini for English review of the manuscript.

REFERENCES

1. ANGUS, K.W.; CAMPBELL, I.; GRAY, E.W. & SHERWOOD, D. - Staining faecal yeast and *Cryptosporidium* oocysts. *Vet. Rec.*, **108**: 173, 1981.
2. BLAKEY, J. - *Cryptosporidium* in stools. *Med. J. Aust.*, **141**: 686, 1984.
3. BRONSDON, M.A. - Rapid dimethyl sulfoxide-modified acid-fast stain of *Cryptosporidium* oocysts in stool specimens. *J. clin. Microbiol.*, **19**: 952-953, 1984.
4. CROSS, R.F. & MOORHEAD, P.D. - A rapid staining technic for Cryptosporidia. *Mod. vet. Pract.*, **65**: 307, 1984.
5. DELUOL, A.M.; CENAC, J.; MATHERON, S.; MARCHE, C. & SAVEL, J. - La cryptosporidiose. II. Diagnostic biologique. *Ann. Biol. clin.*, **42**: 399-405, 1984.
6. FAYER, R. & UNGAR, B.L.P. - *Cryptosporidium* spp and Cryptosporidiosis. *Microbiol. Rev.*, **50**: 458-483, 1986.
7. GARCIA, L.S.; BRUCKNER, D.A.; BREWER, T.C. & SHIMIZU, R.Y. - Techniques for the recovery and identification of *Cryptosporidium* oocysts from stool specimens. *J. clin. Microbiol.*, **18**: 185-190, 1983.
8. GRACZYK, T.K.; CRANFIELD, M.R. & FAYER, R. - Evaluation of commercial enzyme immunoassay (EIA) and immunofluorescent antibody (IFA) test kits for detection of *Cryptosporidium* oocysts of species other than *Cryptosporidium parvum*. *Amer. J. trop. Med. Hyg.*, **54**: 274-279, 1996.
9. HEINE, J. - A simple technique for demonstration of Cryptosporidia in faeces. *Zbl. Vet. B.*, **29**: 324-327, 1982.
10. HENRIKSEN, S.A. & POHLENZ, J.F.L. - Staining of cryptosporidia by a modified Ziehl-Neelsen technique. *Acta vet. scand.*, **22**: 594-596, 1981.
11. JANOFF, E.N. & RELLER, L.B. - *Cryptosporidium* species, a protean protozoan. *J. clin. Microbiol.*, **25**: 967-975, 1987.

12. LENNETTE, E.H.; BALOWS, A.; HAUSLER, W.J. & TRUANT, J.P. - **Manual of Clinical Microbiology**, 4. ed. Washington, American Society for Microbiology, 1985.
13. LEVINE, D.N. - Taxonomy and review of the coccidian genus *Cryptosporidium* (Protozoa, Apicomplexa). **J. Protozool.**, 31: 94-98, 1984.
14. MA, P. & SOAVE, R. - Three-step, stool examination for cryptosporidiosis in 10 homosexual men with protracted watery diarrhea. **J. infect. Dis.**, 147: 824-828, 1983.
15. MEINHARDT, P.L.; CASEMORE, D.P. & MILLER, K.B. - Epidemiologic aspects of human cryptosporidiosis and the role of waterborne transmission. **Epidem. Rev.**, 18: 118-136, 1996.
16. MEISEL, J.L.; PERERA, D.R.; MELIGRO, C. & RUBIN, C.E. - Overwhelming watery diarrhea associated with a *Cryptosporidium* in an immunosuppressed patient. **Gastroenterology**, 70: 1156-1160, 1976.
17. NIME, F.A.; BUREK, J.D.; PAGE, D.L.; HOLSCHER, M.A. & YARDLEY, J.H. - Acute enterocolitis in a human being infected with the protozoan *Cryptosporidium*. **Gastroenterology**, 70: 592-598, 1976.
18. POHJOLA, S. - Negative staining method with nigrosin for the detection of cryptosporidial oocysts: a comparative study. **Res. Vet. Sci.**, 36: 217-219, 1984.
19. POHJOLA, S.; JOKIPII, L. & JOKIPII, A.M. - Dimethylsulphoxide-Ziehl-Neelsen staining techniques for detection of cryptosporidial oocysts. **Vet. Rec.**, 116: 442-443, 1985.
20. POHJOLA, S. - Diagnostic and epidemiological aspects of *Cryptosporidium* infection, a protozoan infection of increasing veterinary public health importance. **Acad. Dis. Coll. Vet. Med.**, 1986. Apud: DURÁN, M. L. S. - Avances en Parasitología: Protozoología. Santiago de Compostela, Universidade; Servicio de Publicacions e Intercambio Científico, 1992. p. 168.
21. POHLENZ, J.; MOON, H.W.; CHEVILLE, N.F. & BEMRICK, W.J. - Cryptosporidiosis as a probable factor of neonatal diarrhea in calves. **J. Amer. vet. med. Ass.**, 172: 452-457, 1978.
22. RITCHIE, L.S. - An ether sedimentation technique for routine stool examinations. **Bull. U. S. Army med. Dep.**, 8, 1948.
23. ROBERT, B.; GINTER, A.; ANTOINE, H.; COLLARD, A. & COPPE, P. - Diagnosis of bovine cryptosporidiosis by an enzyme-linked immunosorbent assay. **Vet. Parasit.**, 37: 1-8, 1990.
24. STERLING, C. & ARROWOOD, M. - Detection of *Cryptosporidium* sp. infections using a direct immunofluorescent assay. **Pediat. infect. Dis.**, 5(suppl.): S139-S142, 1986.
25. UNGAR, B.L.; SOAVE, R.; FAYER, R. & NASH, T.E. - Enzyme immunoassay detection immunoglobulin M and G antibodies to *Cryptosporidium*. **J. infect. Dis.**, 3: 570-578, 1986.
26. VILLACORTA, I. - **Diagnostico, incidencia y profilaxia de la cryptosporidiosis. Infecciones experimentales**. Santiago de Compostela, 1989. (Tesis Doctoral). Apud: DURÁN, M. L. S. - Avances en Parasitología: Protozoología. Santiago de Compostela, Universidade; Servicio de Publicacions e Intercambio Científico, 1992. p. 168.
27. YOUNG, K.H.; BULLOCK, S.L.; MELVIN, D.M. & SPRUILL, C.L. - Ethyl acetate as a substitute for diethyl ether in the formalin-ether sedimentation technique. **J. clin. Microbiol.**, 10: 852-853, 1979.

Received: 05 June 2000

Accepted: 08 November 2000