

Rev. Inst. Med. trop. S. Paulo  
42 (6): 299-304, November-December, 2000.

## CLINICAL AND DIAGNOSTIC ASPECTS OF INTESTINAL MICROSPORIDIOSIS IN HIV-INFECTED PATIENTS WITH CHRONIC DIARRHEA IN RIO DE JANEIRO, BRAZIL

Patrícia BRASIL(1), Dirce Bonfim de LIMA(1), Daurita Darci de PAIVA(1), Maria Stella de Castro LOBO(2), Fernando Campos SODRÉ(1), Siudomar Pereira da SILVA(1), Erika Veríssimo VILLELA(1), Edson Jurado da SILVA(3), José Mauro PERALTA(2), Marisa MORGADO(4) & Hercules MOURA(1)

### SUMMARY

The objectives of this study were to determine both the prevalence of microsporidial intestinal infection and the clinical outcome of the disease in a cohort of 40 HIV-infected patients presenting with chronic diarrhea in Rio de Janeiro, Brazil. Each patient, after clinical evaluation, had stools and intestinal fragments examined for viral, bacterial and parasitic pathogens. Microsporidia were found in 11 patients (27.5%) either in stools or in duodenal or ileal biopsies. Microsporidial spores were found more frequently in stools than in biopsy fragments. Samples examined using transmission electron microscopy (n=3) or polymerase chain reaction (n=6) confirmed *Enterocytozoon bienersi* as the causative agent. Microsporidia were the only potential enteric pathogens found in 5 of the 11 patients. Other pathogens were also detected in the intestinal tract of 21 patients, but diarrhea remained unexplained in 8. We concluded that microsporidial infection is frequently found in HIV infected persons in Rio de Janeiro, and it seems to be a marker of advanced stage of AIDS.

**KEYWORDS:** Microsporidia; AIDS; Chronic diarrhea; *Enterocytozoon bienersi*

### INTRODUCTION

Diarrhea is a common clinical manifestation of human immunodeficiency virus (HIV-1) infection both in developing and developed countries<sup>8,20,33</sup>. In temperate and in tropical countries chronic diarrhea associated with significant weight loss is often the presenting illness of HIV-1 infected individuals<sup>25</sup>. Prospective studies of chronic diarrhea in patients with AIDS suggest that identifiable enteric pathogens account for 75-85% of cases<sup>2,8,20,23,33</sup>. Among the emerging and opportunistic enteric agents, microsporidia have gained attention in the past few years. Over 1000 cases of microsporidiosis have been documented all over the world, with the majority attributed to *Enterocytozoon bienersi*<sup>8,38</sup>. Several clinical and epidemiological studies indicated that *E. bienersi* infection is associated with intestinal and biliary illness and it is present in 7 to 60% of persons infected with HIV having CD4 cell counts below 100/mm<sup>3</sup><sup>8,38</sup>. More recently, microsporidiosis has been identified in HIV-infected patients with relatively preserved CD4 levels, as well as in persons with AIDS without diarrhea<sup>8,31,35</sup>. There is only scant information available on the prevalence of microsporidiosis in South America<sup>1,5,36,40</sup>. In Brazil, there are few reports of microsporidial infection and the prevalence of intestinal microsporidiosis in patients with unexplained chronic diarrhea is largely unknown<sup>5,41</sup>. A pilot study conducted in Rio de Janeiro showed that up to 46% of AIDS patients with chronic diarrhea were infected by microsporidia, suggesting that

these parasites may be potentially significant pathogens in Brazil<sup>7</sup>. In the present study, we describe a cross-sectional study of enteric infection in 40 AIDS patients in Rio de Janeiro, to ascertain the prevalence of intestinal infection either in the presence of microsporidia alone, or in the presence of microsporidia associated with other known intestinal pathogens. We have also compared the clinical features of patients with chronic diarrhea infected with microsporidia, with those patients infected with other enteric parasites.

### MATERIALS AND METHODS

**Patients:** Forty HIV-infected patients with chronic diarrhea were recruited from the Infectious Diseases Clinics, Hospital Universitário Pedro Ernesto-HUPE (a large tertiary care facility that belongs to the State University of Rio de Janeiro), on a voluntary basis to participate in the present study, designed to investigate the cause of their diarrhea and possible microorganisms associations with microsporidia. Chronic diarrhea was defined as continuous (at least two episodes of loose to watery bowel movements per day, persisting for at least 1 month) or intermittent (defined as episodes of two or more loose stools per day, alternating with episodes of formed stools, for more than one month)<sup>24</sup>. All patients had symptomatic HIV disease as determined by CDC<sup>11</sup>: C3 (n=32), C2 (n=1), B3 (n=6), and B2 (n=1). The wasting syndrome associated with diarrheal illness was the AIDS-defining illness in eighteen

Part of this work was presented as a poster and an extended abstract at the VI International Workshop of Opportunistic Protists, North Carolina, USA, June, 1999.

(1) Laboratório de Parasitologia do Departamento de Patologia e Serviço de Doenças Infecciosas e Parasitárias do Departamento de Medicina Interna da Faculdade de Ciências Médicas da Universidade do Estado do Rio de Janeiro (UERJ), RJ, Brasil.

(2) Serviço de Saúde Coletiva do Hospital Universitário Clementino Fraga Filho e Instituto de Microbiologia da Universidade Federal do Rio de Janeiro (UFRJ), RJ, Brasil.

(3) Serviço de Endoscopia do Hospital Pedro II, RJ, Brasil.

(4) Laboratório de AIDS do Departamento de Imunologia do Instituto Oswaldo Cruz, Fiocruz, RJ, Brasil.

**Correspondence to:** Dr Patrícia Brasil, Disciplina de Parasitologia, FCM/UERJ, Av. 28 de setembro 87-fundos, 5º Andar, Vila Isabel, 20551-001 Rio de Janeiro, RJ, Brazil. Fax: +55-21-275-3291. E-mail: patbr@ig.com.br

(45%) of the 40 patients. In the remaining 22 (65%) patients, the AIDS defining illness had occurred on average 18 +/- 16 months before the occurrence of the diarrhea (range 0 to 72 months). Patients infected with microsporidia who survived were followed for at least one year after the first visit of the patient to the clinic.

The study protocol was approved by the ethics review board of HUPE. Informed consent was obtained from each patient prior entering the study after detailed information provided.

**Clinical and Laboratory evaluation:** Complete medical histories and physical examinations with regular weight of the patients were conducted for all study participants. Blood samples were processed for whole blood cells and CD4 counts, within one month of recruitment.

**Detection of intestinal pathogens in stools:** Each patient had at least three consecutive stool samples examined by standard culture for detection of bacteria, including *Salmonella*, *Shigella*, *Campylobacter* and *Aeromonas*. At least three other consecutive stool specimens were evaluated for larvae, ova and parasites. Additional methods included either acid-fast or safranin-methylene blue for *Coccidia*<sup>3,7</sup>.

Detection of microsporidia spores was accomplished after processing stool samples in thin smears using the modified chromotrope stain along with the recently described Gram-chromotrope staining method<sup>27,28,37</sup>. The criteria used to define microsporidia-positive patients was the presence of one or more pinkish (chromotrope) or pinkish-violet (Gram-chromotrope) ovoid structures with a spore wall and a belt-like stripe, over an examination of at least 100 field/100x, confirmed by 2 examiners. Patients who tested positive for microsporidial spores in stools were asked to have their stools examined at least every other month during the 24 month follow-up.

**Detection of intestinal pathogens in biopsy specimens:** Thirty-nine out of the enrolled 40 patients underwent fiber-optic upper gastrointestinal endoscopy or colonoscopy. Seven random samples per patient were taken from each area of duodenum, ileum and colon. Each specimen was fixed in 10% formalin and embedded in paraffin. Tissue sections (4µm) were stained using different methods including hematoxylin-eosin, Grocott's methenamine silver, Giemsa, Fite and were examined using light microscopy (LM) (400X and 1000X). The pathologists reading the biopsy specimens were blinded to the results of the stool examination. Additionally, for three microsporidia-positive patients, biopsy specimens were fixed in glutaraldehyde and embedded in epon resin for examination using transmission electron microscopy (TEM).

**Detection of microsporidia by PCR:** DNA was extracted from 6 stool samples out of the 11 that were positive for microsporidia by first disrupting the sample with silanized glass beads in the presence of a digestion buffer containing EDTA and lauryl alcohol polyether and subsequent digestion with proteinase K. The resulting extract was purified on a MicroSpin Ion-Exchange column, available in the RapidPrep Genomic DNA isolation kit for cells and tissues (Pharmacia Biotech)<sup>13</sup>. PCR amplification was performed with primer pairs EBIEF1/EBIER1 and SINTF1/SINTR<sup>14,15</sup>. These amplify diagnostic fragments of 607 bp and 520 bp of *E. bienersi* and *Encephalitozoon intestinalis* SSU-rRNA coding region respectively. Conditions for all PCR reactions were denaturation at 94 °C for 30 s, annealing at 55 °C (45 °C for SINTF1/

SINTR) for 30 s, and extension at 72 °C for 90 s in a GenAmp 2400 PCR machine (Perkin-Elmer Cetus).

PCR of stool was chosen as a confirmatory method of direct stool examination when biopsy was not available.

**Statistical analysis:** Statistical analysis was applied for comparison of clinical and biological features of patients with and without microsporidiosis. It was performed using chi square tests for categorical variables and the nonparametric Kruskal Wallis test, for continuous variables. A  $p < 0.05$  was considered as statistically significant<sup>26</sup>.

## RESULTS

**Prevalence of intestinal pathogens:** Stool examinations and studies of duodenoileal and colonic tissues revealed pathogens in 32 (80%) out of 40 patients. Eleven patients (27.5%; 95% confidence interval, 14-41) had microsporidiosis diagnosed by stool examination and confirmed either by examination of intestinal biopsy or by PCR with DNA extracted from stools. Microsporidia were the second most frequent cause of intestinal infection after *Cryptosporidium* (thirteen cases - 32.5%) and was the only potential enteric pathogen in five patients (13%; 95% confidence interval, 3-23). Cytomegalovirus (CMV) was the third agent found in these cases (n=9 - 22.5%). The cause of diarrhea was not identified in 8 patients (Table 1).

**Endoscopic findings:** No mucosal lesion was observed at esophagogastroduodenoscopy or ileonoscopy of patients infected solely with microsporidia. The mucosa appeared grossly normal in all but 2 patients, who were co-infected with *Cryptosporidium*. Patients presented a hyperemic duodenal mucosa covered by a white thick exsudate.

### Morphologic detection of microsporidia

**Light microscopy of stool samples:** Microsporidial spores were found in the stools of all 11 patients by the Chromotrope and Gram-chromotrope staining methods. The spores were found more easily with the second method, although no measurable difference of sensitivity could be made between them (Fig. 1A, 1B).

**Biopsy Pathology:** Microsporidia were found in eight of the 39 patients for whom biopsy was accomplished (20.5%; 95% confidence interval, 8-33). No microsporidial spore was seen after histopathological examination of two patients who excreted spores in stools; microsporidia was confirmed as the only potential enteric pathogen in five (45%) of 11 infected patients (Table 1). Duodenal or terminal ileum biopsy samples showed the same parasite load.

Biopsies from duodenum and ileum revealed spores inside the cytoplasm of epithelial cells, most of them in a supranuclear location on the luminal side, and some distributed in the cytoplasm of the epithelial cells. Infected enterocytes that were filled with spores appeared degenerated. Clusters of microsporidial spores and sloughed off cells were also seen free in the lamina propria and in the intestinal lumen. Mild to severe villous atrophy were also evident. Expansion of the lamina propria by an infiltrate of lymphocytes, plasma cells, increased apoptotic debris, macrophages and eosinophils were also evident, but neutrophils were rarely seen. There was no evidence of active enteritis, crypt abscesses, or ulceration associated with these cases.

**Microsporidial species identification**

**TEM:** Characteristics of spores were confirmed in three patients by electron microscopy after ultrastructural examination of duodenal biopsy specimens. Spores with an electron-lucent endospore, a thin electron-dense exospore and a polar filament with 6 overlapping coils which appeared in cross-section as a series of three doublets features were compatible with *E. bienewisi*. Septata-like spores and plasmodia were not found in the studied samples.

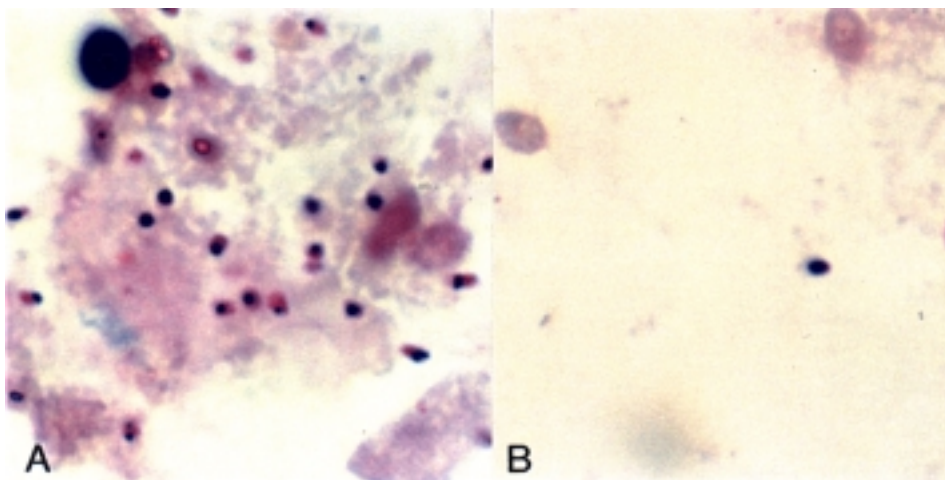
**PCR amplification:** PCR was performed in the stools of six of the eleven patients who tested positive for microsporidia by light microscopy, as PCR for microsporidia was not available in our laboratory in the beginning of the work. All samples tested were confirmed as positive for *E. bienewisi* using the primers EBIEF1/EBIER1. There was no positive reaction with the *E. intestinalis* diagnostic primers (Fig. 2).

**Clinical and biological features of patients with microsporidiosis:** Upon enrollment, the mean age of microsporidian infected patients (9

men and 2 women) was 38 years and median age was 37 +/- 15 years. All of them had acquired HIV infection by sexual contact. Nine patients had AIDS. Two patients had microsporidiosis as the first illness related to AIDS. The wasting syndrome associated with diarrheal illness was the AIDS-defining illness in six (54.5%) of 11 patients. In the remaining five patients (65.5%), the AIDS-defining illness had occurred a mean of 12 +/- 19 months before the diagnosis of microsporidiosis.

The clinical and biological features of patients with intestinal microsporidiosis can be found in Table 1. Cachexia was recorded when the patient lost more than 10% of baseline body weight, associated with muscle atrophy. All patients were receiving antiretroviral therapy, zidovudine (AZT) and dideoxyinosine (ddI), in addition to sulphamethoxazole-trimethoprim. All patients, except one, had intermittent diarrhea and eight of them were followed after initiating specific treatment with albendazole (400 mg twice daily for 4 weeks), which seemed not to alter the frequency of the diarrhea.

Duration of follow-up ranged from 1 to 24 months, with a mean of 6



**Fig. 1** - Microsporidia spores in stool smears stained by the Gram-chromotrope method. 1,250X. At the moment of diagnosis, many spores could be seen (A). During treatment with albendazole a few spores were seen (B).

**Table 1**  
Diagnosis, clinical and biological features of 11 microsporidia infected patients with AIDS in Rio de Janeiro, Brazil

Patient	Stools (LM*)	Stools (PCR)	Intestinal biopsy (LM)	Microsporidia species	Other pathogens in stool or biopsy specimens	Cachexia	CD4 count (cells/mm <sup>3</sup> )	Survival time after diagnosis of microsporidiosis (months)
1	P	ND§	P	U	None detected	No	8	8
2	P	ND	P	<i>E.bienewisi</i> #	None detected	No	22	24
3	P	ND	P	U	None detected	Yes	49	24
4	P	ND	P	U	None detected	Yes	10	<1
5	P	ND	P	U	Cryptosp.	Yes	85	2
6	P	P	P	<i>E.bienewisi</i> #	None detected	No	38	7
7	P	P	ND**	<i>E.bienewisi</i>	U	Yes	6	<1
8	P	P	P	<i>E.bienewisi</i>	CMV+ Cryptosp.	Yes	14	3
9	P	P	N	<i>E.bienewisi</i>	CMV	Yes	15	8
10	P	P	P	<i>E.bienewisi</i> #	Cryptosp.	Yes	12	3
11	P	P	N	<i>E.bienewisi</i>	CMV	Yes	7	3

\*LM: light microscopy; §ND: not done; # identified using transmission electron microscopy (TEM); \*\*Patient died 3 days after microsporidial spores were detected in his stools; P: positive; N: negative; U: unknown; Cryptosp.: *Cryptosporidium*; CMV: Cytomegalovirus

months. Nine patients died after the diagnosis of microsporidia infection, 2 of them died immediately after enrollment, and 1 died two months later. The mean survival time was 4 months (range 1-8 months) after the diagnosis.

A comparison of clinical and biological features of patients with and without microsporidiosis can be found in Table 2. In summary, mean ages were similar for both groups. Weight loss and cachexia were significantly more important in patients with microsporidiosis, either

when microsporidia was the only pathogen or when it was associated with others. The wasting syndrome with chronic diarrhea as the AIDS defining illness was more frequent in the microsporidia infected group. Patients with microsporidiosis had more advanced HIV disease, as demonstrated by a significantly lower CD4 cell count, although this was not evident when the total lymphocyte count were used as a marker. All patients with microsporidiosis had CD4 counts <85/mm<sup>3</sup>. Patients without microsporidiosis had a better prognosis: only 8 of 27 patients from this group died, compared to 9 of 11 patients from the microsporidia-infected group, during the follow-up.

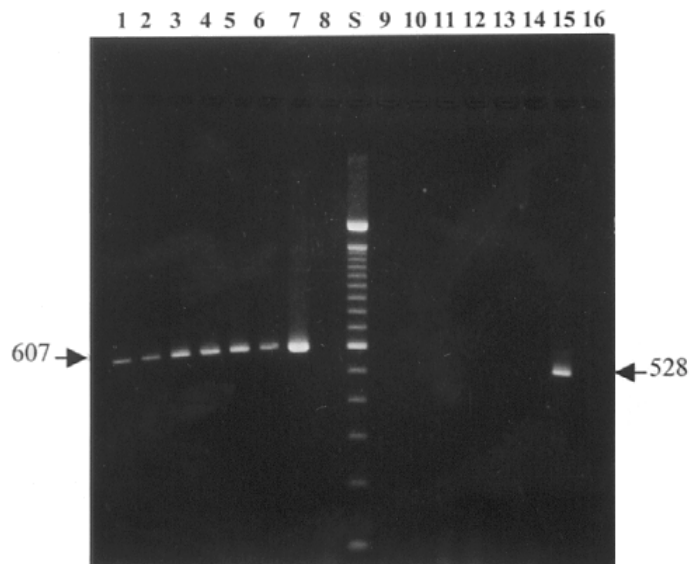
## DISCUSSION

This study examined 40 AIDS patients, over a 24-month period. The total patients studied represented 67% of all patients with chronic diarrhea seen in a specialized center in Rio de Janeiro. We found an 80% prevalence of identifiable enteric pathogens, similar to studies by other investigators in developed countries<sup>20,22,23,34</sup>. *Cryptosporidium* and CMV, accounted together for 55% of the diagnosed causes of chronic diarrhea, in accordance to previous studies<sup>2,33</sup>. An etiologic agent of diarrhea was not found in eight patients, and the finds of others suggest that HIV infection itself may have caused the diarrhea in these patients<sup>19</sup>.

Microsporidia was found in 11 out of 40 (27.5%) patients with chronic diarrhea, prevalence similar to others that documented a rate of infection between 12% to 60% among HIV-infected patients with chronic unexplained diarrhea<sup>7-9,16,17,22,29,30,34,38</sup>.

Of interest, microsporidia was found as the single agent detected in five of 11 cases, thus providing some evidence for a causal relationship between parasitic infection and chronic diarrhea. Also, the progressive damage to the microvilli of infected cells, desquamation of infected enterocytes at rapid rate are strong evidence for a causal relation between this parasite and gastrointestinal disease, as already observed by others<sup>4,16,21,30,32,39</sup>.

LM or TEM examination of tissue has been considered as the gold standard to the diagnosis of microsporidial infection<sup>38</sup>. However, in this study, detection of microsporidia in stools using either chromotrope



**Fig. 2** - Agarose gel analysis of PCR-amplified products using species-specific primers for *Enterocytozoon bienersi* (EBIEF1/EBIER1, lanes 1 to 8) and *Encephalitozoon (sin. Septata) intestinalis* (SINTF1/SINTR, lanes 9 to 16). Lanes 1 to 6: DNA purified from stool samples amplified using primers EBIEF1/EBIER1. Lanes 9 to 14: DNA purified from stool samples, amplified using primers SINTF1/SINTR. Lane 7: *Enterocytozoon bienersi* cloned SSU-rRNA region used as positive control. Lane 15: *Encephalitozoon (sin.Septata) intestinalis* cloned SSU-rRNA region used as positive control. Lanes 8 and 16, DNA extracted from human lung fibroblast cells used as negative control. Lane S contains the 100-bp ladder standard. Numbers to the left of the gel indicate the DNA diagnostic fragment in base pairs for *E. bienersi*, and to the right, for *E. intestinalis*.

**Table 2**

Clinical and biological features of HIV-infected patients with chronic diarrhea with and without microsporidiosis in Rio de Janeiro, R.J., Brazil

	Microsporidia alone# (n=5)	Microsporidia associated (n=5)	Other pathogens (n=21)	Unexplained diarrhea (n=8)	P
Age *	37	35	31	42	0.20
Gender (male/female ratio)	4/1	4/1	21/0	8/0	
Weight loss(kg) <sup>kg</sup>	11	12	7	5.5	0.01*
Cachexia	2	5	6	1	0.009*
AIDS indicator conditions	5	5	20	7	0.63
Diarrhea as AIDS defining syndrome	2	5	6	5	0.02
Survival after one year	2	0	13	6	0.041*
Leucocytes	3950	2600	3250	3150	0.82
Lymphocytes	780	865	784	600	0.84
CD4 cells/mm <sup>3</sup>	22	14	25	80	0.013*

#One patient, who died a few days after *E.bienersi* spores were found in his stools, was excluded from this analysis because he was not fully evaluated; <sup>kg</sup> Median of weight loss during the period of diarrhea; \* Data for the continuous variables are their median values (p<0.05)\*

staining, or the new gram-chromotrope were sufficient to establish a diagnosis<sup>27,37</sup>. Besides reducing the necessity of invasive procedures, it has special interest in developing countries such as Brazil, since the costs of more sophisticated methods like biopsy or PCR were reduced as well.

Microsporidia were found in duodenal as well as in ileal tissue. Colonoscopy with ileal biopsy may remain as an important diagnostic tool because it allows for the detection of cytomegalovirus colitis, which happened to be our third most diagnosed enteric infection. Additionally, the ileal biopsy was useful for the detection of microsporidia, among other small bowel infectious agents that could be susceptible to medical therapy.

Examination of small bowel tissue by LM, using the traditional staining methods (HE, Brown-Brenn, Giemsa) was less sensitive in this study. Our negative findings using these methods in specimens from two patients in whom microsporidia spores were detected in stool samples using either light microscopy or PCR, suggests that tissue examination using LM may also fail to detect microsporidia in small-bowel tissue. The variable sensitivity of LM may be due to the focal distribution of infected enterocytes, the selected biopsy site, the small amount of tissue obtained with biopsies or the lack of utilization of Warthin-Starry or Gram-chromotrope, more specific staining for microsporidia in tissues<sup>17,28,37</sup>.

PCR amplification using diagnostic primers for identification of *E. bieneusi* and *E. intestinalis* designed on the SSU-rRNA coding region, useful for species identification, have important treatment implications, since diarrhea by *E. intestinalis* respond to albendazole therapy. It has been reported that *E. intestinalis* is responsible for 1% to 10% of microsporidial intestinal infections<sup>8,17</sup>. Nevertheless, in our study, *E. bieneusi* was the only species identified among our patients, probably because of the small number of microsporidia-infected patients studied and the limited number of samples analyzed for species determination (seven out of eleven). This result may also explain the lack of effectiveness of albendazole therapy in the outcome of the diarrhea of our patients.

Analysis of the present data obtained for the 40 AIDS patients with chronic diarrhea revealed that the presence of microsporidia parasites might lead to a debilitating diarrhea, with an important weight loss, resulting in cachexia, which may be a significant cause or cofactor in the death of many patients. Whether or not the onset of AIDS with diarrhea is a predictor of microsporidia infection, as suggested by our data, needs further evaluation. Additionally, the decreased survival of microsporidia-infected patients was well correlated with the lowest CD4 cell counts. Intestinal microsporidiosis seems to be a marker of advanced stage of AIDS.

The intermittent characteristic of the diarrhea observed in all but one patient could be related to the partial restoration of immunity to *E. bieneusi* by the combination of nucleoside-analogues utilized by all patients. Complete resolution of diarrhea, as observed with the use of antiretroviral combinations with protease inhibitors, could not be evaluated since these drugs were not available during the current study<sup>5,6,10,12,18,29</sup>.

Improved diagnosis of microsporidia in stool samples might result in an increase in the detection of microsporidial spores in AIDS patients

in Brazil and other developing countries as well. Microsporidia seems to be an important agent of chronic diarrhea among AIDS patients in Brazil and further studies are warranted.

## RESUMO

### Aspectos clínicos e diagnósticos da microsporidiose intestinal em pacientes com infecção pelo HIV e diarreia crônica, no Rio de Janeiro, Brasil

Os objetivos deste estudo foram determinar a prevalência e o prognóstico clínico da infecção por microsporídios em uma coorte de 40 pacientes com infecção pelo HIV e diarreia crônica na cidade do Rio de Janeiro, Brasil. Cada paciente teve suas fezes e fragmentos de intestino examinados para a pesquisa de CMV, bactérias e parasitos.

A prevalência de microsporidiose foi de 27,5% (n=11). Esporos de microsporídios foram encontrados com maior frequência no exame direto das fezes do que em biópsias de intestino delgado. A microscopia eletrônica de transmissão e a reação de polimerase em cadeia (PCR) identificaram *Enterocytozoon bieneusi*, respectivamente, em 3 e 6 amostras examinadas, confirmando a espécie como único agente causal. Nenhum outro microrganismo patogênico, além dos microsporídios, foi detectada em 5 dos pacientes com diarreia. Outros parasitos foram encontrados no trato digestivo de 21 pacientes, enquanto que em 8 a etiologia da diarreia não foi definida. Concluímos que a infecção por microsporídios pode ser frequentemente encontrada em indivíduos infectados pelo HIV no Rio de Janeiro.

## ACKNOWLEDGMENTS

We are indebted to Drs. Govinda S. Visvesvara, David Addis and David A. Schwartz for carefully reviewing the manuscript and for helpful suggestions.

## REFERENCES

1. BANTAR, C.; HERRERA, F.; DIDIER, E.; FALCO, A. & BIANCHINI, H. - Diarrhea por microsporidia en un enfermo con SIDA. *Medicina (B. Aires)*, 55: 685-688, 1995.
2. BARTLETT, J.G.; BELITSOS, P.C. & SEARS, C.L. - AIDS enteropathy. *Clin. infect. Dis.*, 15: 726-735, 1992.
3. BAXBY, D.; BLUNDELL, N. & HART, C.A. - The development and performance of a simple, sensitive method for the detection of *Cryptosporidium* oocysts in faeces. *J. Hyg. (Lond.)*, 93: 317-323, 1984.
4. BLANSHARD, C.; ELLIS, D.S.; DOWELL, S.P.; TOVEY, G. & GAZZARD, B.G. - Electron microscopic changes in *Enterocytozoon bieneusi* following treatment with albendazole. *J. clin. Pathol.*, 46: 898-902, 1993.
5. BRASIL, P.; DE LIMA, D.B.; DE PAIVA, D.D. *et al.* - Emerging and opportunistic intestinal parasites in HIV-infected patients with chronic diarrhea in Rio de Janeiro, Brazil. *J. Euk. Microbiol.*, 46: 40S-41S, 1999.
6. BRASIL, P.; DE PAIVA, D.D.; DE LIMA, D.B. *et al.* - A 3-year follow-up of a Brazilian AIDS patient with protracted diarrhea caused by *Enterocytozoon bieneusi*. *Rev. Inst. Med. trop. S. Paulo*, 40: 215-218, 1998.
7. BRASIL, P.; SODRE, F.C.; CUZZI-MAYA, T. *et al.* - Intestinal microsporidiosis in HIV-positive patients with chronic unexplained diarrhea in Rio de Janeiro, Brazil: diagnosis, clinical presentation and follow-up. *Rev. Inst. Med. trop. S. Paulo*, 38: 97-102, 1996.

8. BRYAN, R.T. & SCHWARTZ, D.A. - Epidemiology of microsporidiosis. In: WITNER, M. & WEISS, L.M., ed. **The microsporidia and microsporidiosis**. Washington, ASM Press, 1999. p. 502-516.
9. CANNING, E.U. & HOLLISTER, W.S. - *Enterocytozoon bieneusi* (Microspora): prevalence and pathogenicity in AIDS patients. **Trans. roy. Soc. trop. Med. Hyg.**, 84: 181-186, 1990.
10. CARR, A.; MARRIOTT, D.; FIELD, A.; VASAK, E. & COOPER, D.A. - Treatment of HIV-1 associated microsporidiosis and cryptosporidiosis with combination antiretroviral therapy. **Lancet**, 351: 256-261, 1998.
11. CDC - 1993 revised classification system for HIV infection and expanded surveillance case definition for AIDS among adolescents and adults. **M.M.W.R.**, 41: 1-19, 1992.
12. CONTEAS, C.N.; BERLIN, O.G.; SPECK, C.E. *et al.* - Modification of the clinical course of intestinal microsporidiosis in acquired immunodeficiency syndrome patients by immune status and anti-human immunodeficiency virus therapy. **Amer. J. trop. Med. Hyg.**, 58: 555-558, 1998.
13. DA SILVA, A.J.; BORNAY-LLINARES, F.J.; DEL AGUILA DE LA PUENTE, C. *et al.* - Diagnosis of *Enterocytozoon bieneusi* (microsporidia) infections by polymerase chain reaction in stool samples using primers based on the region coding for small-subunit ribosomal RNA. **Arch. Path. Lab. Med.**, 121: 874-879, 1997.
14. DA SILVA, A.J.; SCHWARTZ, D.A.; VISVESVARA, G.S. *et al.* - Sensitive PCR diagnosis of infections by *Enterocytozoon bieneusi* (microsporidia) using primers based on the region coding for small-subunit rRNA. **J. clin. Microbiol.**, 34: 986-987, 1996.
15. DA SILVA, A.J.; SLEMENDA, S.B.; VISVESVARA, G.S. *et al.* - Detection of *Septata intestinalis* (Microsporida) Cali *et al.* 1993 using polymerase chain reaction primers targeting the small subunit ribosomal RNA coding region. **Molec. Diagn.**, 2: 47-52, 1997.
16. EEFITINCK-SCHATTENKERK, J.K.; VAN GOOL, T.; VAN KETEL, R.J. *et al.* - Clinical significance of small-intestinal microsporidiosis in HIV-1- infected individuals. **Lancet**, 337: 895-898, 1991.
17. FIELD, A.S.; HING, M.C.; MILLIKEN, S.T. & MARRIOTT, D.J. - Microsporidia in the small intestine of HIV-infected patients. A new diagnostic technique and a new species. **Med. J. Aust.**, 158: 390-394, 1993.
18. FOUORAINE, N.A.; WEVERLING, G.J.; VAN GOOL, T. *et al.* - Improvement of chronic diarrhoea in patients with advanced HIV-1 infection during potent antiretroviral therapy. **Aids**, 12: 35-41, 1998.
19. FOX, C.H.; KOTLER, D.; TIERNEY, A.; WILSON, C.S. & FAUCI, A.S. - Detection of HIV-1 RNA in the lamina propria of patients with AIDS and gastrointestinal disease. **J. infect. Dis.**, 159: 467-471, 1989.
20. GREENSON, J.K.; BELITSOS, P.C.; YARDLEY, J.H. & BARTLETT, J.G. - AIDS enteropathy: occult enteric infections and duodenal mucosal alterations in chronic diarrhea. **Ann. intern. Med.**, 114: 366-372, 1991.
21. JOSTE, N.E.; RICH, J.D.; BUSAM, K.J. & SCHWARTZ, D.A. - Autopsy verification of *Encephalitozoon intestinalis* (microsporidiosis) eradication following albendazole therapy. **Arch. Path. Lab. Med.**, 120: 199-203, 1996.
22. KOTLER, D.P.; FRANCISCO, A.; CLAYTON, F.; SCHOLES, J.V. & ORENSTEIN, J.M. - Small intestinal injury and parasitic diseases in AIDS. **Ann. intern. Med.**, 113: 444-449, 1990.
23. KOTLER, D.P. & ORENSTEIN, J.M. - Clinical syndromes associated with microsporidiosis. In: WITNER, M. & WEISS, L.M., ed. **The microsporidia and microsporidiosis**. Washington, ASM Press, 1999. p. 258-292.
24. KOTLER, D.P.; REKA, S.; CHOW, K. & ORENSTEIN, J.M. - Effects of enteric parasitoses and HIV infection upon small intestinal structure and function in patients with AIDS. **J. clin. Gastroent.**, 16: 10-15, 1993.
25. MACALLAN, D.C.; NOBLE, C.; BALDWIN, C. *et al.* - Prospective analysis of patterns of weight change in stage IV human immunodeficiency virus infection. **Amer. J. clin. Nutr.**, 58: 417-424, 1993.
26. MILTON, J.S. - Some additional procedures and distribution - free alternatives. In: WALLIS, R. & DAMSTRA, D.A., ed. **Statistical methods in the biological and health science**. 2. ed. New York, Mac Graw-Hill, 1992. v.1, p. 413-460.
27. MOURA, H.; DA SILVA, J.L.; SODRÉ, F.C. *et al.* - Gram-chromotrope: a new technique that enhances detection of microsporidial spores in clinical samples. **J. Euk. Microbiol.**, 43: 94S-95S, 1996.
28. MOURA, H.; SCHWARTZ, D.; BORNAY-LLINARES, F. *et al.* - A new and improved "quick-hot Gram-chromotrope" technique that differentially stains microsporidial spores in clinical samples, including paraffin-embedded tissue sections. **Arch. Path. Lab. Med.**, 121: 887-893, 1997.
29. NAVIN, T.R.; WEBER, R.; VUGIA, D.J. *et al.* - Declining CD4+ T-lymphocyte counts are associated with increased risk of enteric parasitosis and chronic diarrhea: results of a 3-year longitudinal study. **J. Acquir. Immun. Defic. Syndr. hum. Retrovirol.**, 20: 154-159, 1999.
30. PEACOCK, C.S.; BLANSHARD, C.; TOVEY, D.G.; ELLIS, D.S. & GAZZARD, B.G. - Histological diagnosis of intestinal microsporidiosis in patients with AIDS. **J. clin. Path.**, 44: 558-563, 1991.
31. RABENECK, L.; GENTA, R.M.; GYORKEY, F. *et al.* - Observations on the pathological spectrum and clinical course of microsporidiosis in men infected with the human immunodeficiency virus: follow-up study. **Clin. infect. Dis.**, 20: 1229-1235, 1995.
32. SCHWARTZ, D.A.; ABOU-ELELLA, A.; WILCOX, C.M. *et al.* - The presence of *Enterocytozoon bieneusi* spores in the lamina propria of small bowel biopsies with no evidence of disseminated microsporidiosis. Enteric opportunistic infections working group. **Arch. Path. Lab. Med.**, 119: 424-428, 1995.
33. SMITH, P.D.; LANE, H.C. & GILL, V.J. - Intestinal infections in patients with acquired immunodeficiency syndrome (AIDS). Etiology and response to therapy. **Ann. intern. Med.**, 108: 328-333, 1988.
34. SOBOTKA, I.; SCHWARTZ, D.A.; SCHOTTELIUS, J. *et al.* - Prevalence and clinical significance of intestinal microsporidiosis in human immunodeficiency virus-infected patients with and without diarrhea in Germany: a prospective coprodiagnostic study. **Clin. infect. Dis.**, 26: 475-480, 1998.
35. SOWERBY, T.M.; CONTEAS, C.N.; BERLIN, O.G. & DONOVAN, J. - Microsporidiosis in patients with relatively preserved CD4 counts. **Aids**, 9: 975, 1995.
36. VELASQUEZ, J.N.; CARNEVALE, S.; GUARNERA, E.A. *et al.* - Detection of the microsporidial parasite *Enterocytozoon bieneusi* in specimens from patients with AIDS by PCR. **J. clin. Microbiol.**, 34: 3230-3232, 1996.
37. WEBER, R.; BRYAN, R.T.; OWEN, R.L. *et al.* - Improved light-microscopical detection of microsporidia spores in stool and duodenal aspirates. The enteric opportunistic infections working group. **New Engl. J. Med.**, 326: 161-166, 1992.
38. WEBER, R.; BRYAN, R.T.; SCHWARTZ, D.A. & OWEN, R.L. - Human microsporidial infections. **Clin. Microbiol. Rev.**, 7: 426-461, 1994.
39. WEISS, L.M. - ...and now microsporidiosis. **Ann. intern. Med.**, 123: 954-956, 1995.
40. WEITZ, J.C.; BOTEHLO, R. & BRYAN, R. - Microsporidiosis en pacientes con diarrhea cronica y Sida, HIV asintomaticos y pacientes con diarrhea aguda. **Rev. med. Chile**, 123: 849-856, 1995.
41. WUHIB, T.; SILVA, T.M.; NEWMAN, R.D. *et al.* - Cryptosporidial and microsporidial infections in human immunodeficiency virus-infected patients in northeastern Brazil. **J. infect. Dis.**, 170: 494-497, 1994.

Received: 22 March 2000

Accepted: 31 July 2000