

Rev. Inst. Med. trop. S. Paulo  
42 (2): 111-113, March-April, 2000.

## ***Chromobacterium violaceum* INFECTION IN BRAZIL. A CASE REPORT**

Roberto MARTINEZ(1), Maria Angeles Sanches L. VELLUDO(2), Vanda Roseli dos SANTOS(3) & Paula Vanessa DINAMARCO(2)

### **SUMMARY**

We report the second case of infection with *Chromobacterium violaceum* that occurred in Brazil. A farm worker living in the State of São Paulo presented fever and severe abdominal pain for four days. At hospitalization the patient was in a toxemic state and had a distended and painful abdomen. Chest X-ray and abdominal ultrasound revealed bilateral pneumonia and hypoechoic areas in the liver. The patient developed failure of multiple organs and died a few hours later. Blood culture led to isolation of *C. violaceum* resistant to ampicillin and cephalosporins and sensitive to chloramphenicol, tetracyclin, aminoglycosides, and ciprofloxacin. Autopsy revealed pulmonary microabscesses and multiple abscesses in the liver. The major features of this case are generally observed in infections by *C. violaceum*: rapid clinical course, multiple visceral abscesses, and high mortality. Because of the antimicrobial resistance profile of this Gram-negative bacillus, for appropriate empirical antibiotic therapy it is important to consider chromobacteriosis in the differential diagnosis of severe community infections in Brazil.

**KEYWORDS:** *Chromobacterium violaceum*; Liver abscess; Septicemia.

### **INTRODUCTION**

Infections with *Chromobacterium violaceum*, although rare, are characterized by rapid dissemination and high mortality. This Gram-negative bacillus is found in the water and soil of tropical and subtropical regions, causing human infection mainly in Southeast Asia and in the Southeastern region of the United States<sup>3,6</sup>. Two reports have been published for South America, respectively involving one case in Brazil<sup>7</sup> and one in Argentina<sup>5</sup>. We report here another Brazilian case with a fulminating course, whose autopsy findings confirmed the pathogenicity of *C. violaceum*.

### **CASE REPORT**

A 30-year old farm worker residing in the State of São Paulo, Brazil, was admitted at the "Hospital das Clínicas", Faculty of Medicine of Ribeirão Preto, on April 3, 1998, presenting fever, anorexia and abdominal pain for 4 days. The pain was intense, continuous and localized in the upper part of the abdomen. The patient denied nausea, vomiting or diarrhea. Physical examination revealed paleness, toxemia and the following values for vital signs: heart rate, 120 bpm, respiratory frequency, 60/minute, blood pressure, 85/55 mmHg, and temperature, 36.8 °C. Chest examination revealed the presence of wheezing. The abdomen was tense and distended, with pain in the epigastrium and right flank upon palpation. No enlarged organs were observed.

Laboratory investigation upon admission showed: hemoglobin, 12.4 g/dL; leukocyte counts, 1,500/mm<sup>3</sup>, with 14% band neutrophils, 20% segmented neutrophils, 54% lymphocytes, and 12% eosinophils; platelet counts, 31,000/mm<sup>3</sup>; serum creatinine, 1.9 mg/dL; blood urea 98.0 mg/dL; arterial gases: pH 7.34, pO<sub>2</sub>, 50 mmHg, pCO<sub>2</sub>, 28 mmHg, and O<sub>2</sub> saturation, 84%. Blood sodium, potassium, calcium and amylase levels were normal.

A chest X-ray revealed bilateral pneumonia. Abdominal ultrasound showed various hypoechoic areas in the liver corresponding to multiple abscesses.

The patient was treated empirically with gentamicin and metronidazole, and intravenous administration of electrolyte fluids. During the subsequent hours he became comatose, with cyanosis of the extremities and circulatory shock. He did not respond to vasoactive drugs or mechanical ventilation and died 12 hours after admission.

A Gram-negative bacillus that formed smooth and violaceous colonies on blood agar was isolated from blood culture collected into a flask of the BactAlert system (Organon/Teknika) (Fig. 1). The bacillus was identified as *C. violaceum* by the Microscan system (Dade-Behring). The isolated strain was sensitive to gentamicin, amikacin, tobramycin, chloramphenicol, tetracyclin, sulfamethoxazole-trimethoprim, ciprofloxacin, imipenem, and cefepime. And showed *in vitro* resistance

(1) Divisão de Doenças Infecciosas e Tropicais, Departamento de Clínica Médica, Faculdade de Medicina de Ribeirão Preto-USP, SP, Brasil.

(2) Departamento de Patologia, Faculdade de Medicina de Ribeirão Preto-USP, SP, Brasil.

(3) Laboratório de Microbiologia, Hospital das Clínicas da Faculdade de Medicina de Ribeirão Preto-USP, SP, Brasil

**Correspondence to:** Roberto Martinez, Departamento de Clínica Médica, Faculdade de Medicina de Ribeirão Preto-USP. Av. Bandeirantes 3900, 14048-900 Ribeirão Preto, SP, Brazil.

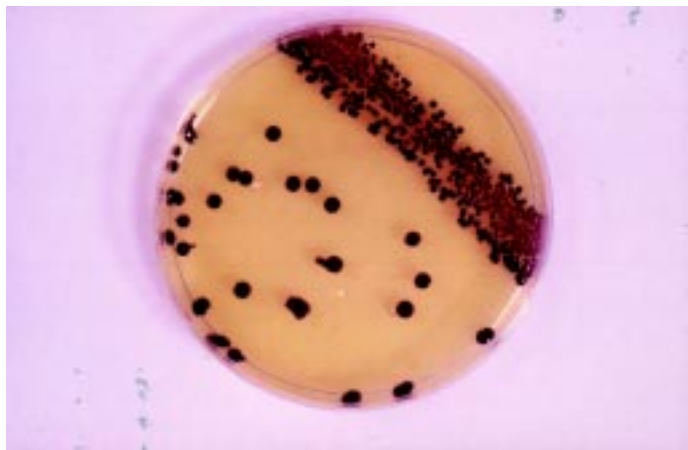

Fig. 1 - Violaceous colonies of *Chromobacterium violaceum* in Müeller-Hinton agar.

to ampicillin, cephalothin, cefoxitin, ceftriaxone, cefotaxime and ceftazidime.

At autopsy, the lungs were found to be edematous and congested, with small yellowish nodules in the parenchyma which were found to be microabscesses when examined under the microscope. The liver was enlarged and contained numerous yellowish nodules and abscessed areas measuring 0.3 to 4.0 cm in diameter and presenting suppurative necrosis (Fig. 2). Other findings were spleen enlargement and congestion, slight cardiac dilatation and lymph node hypertrophy around the pulmonary hili.

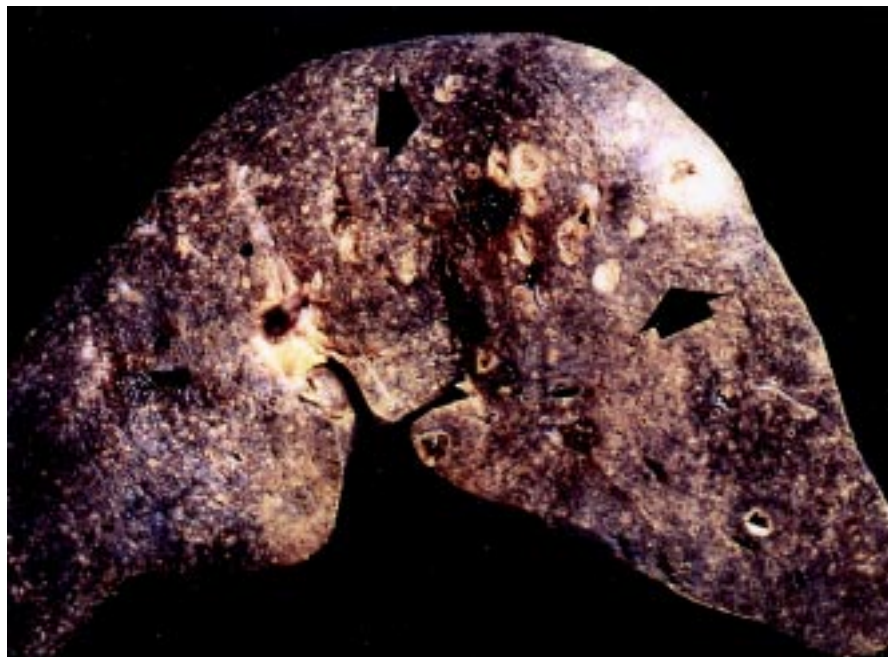


Fig. 2 - Transverse section of the liver showing diffuse yellowish micronodules (microabscesses) and multiple abscesses in the area delimited by arrows.

## DISCUSSION

*C. violaceum* is a common inhabitant of soil and water in tropical and subtropical areas of the world. This Gram-negative bacillus rarely causes invasive disease in humans. Infection occurs after contamination of damaged skin exposed to soil or environmental water. Alternatively, systemic infection can follow the aspiration or ingestion of contaminated water<sup>3</sup>.

The Brazilian territory includes extensive regions of tropical and subtropical climate that create the conditions for cases of chromobacteriosis. A young patient with multiple skin abscesses who had been in contact with river water was the first case observed in Brazil<sup>7</sup>. The patient reported in this paper was in daily contact with the rural environment but did not present skin lesions when admitted to the hospital. His initial symptoms were fever and abdominal pain and rapidly progressed to death, with the presence of toxemia, circulatory shock and respiratory insufficiency. A rapid course, the formation of multiple visceral and subcutaneous abscesses and high mortality are characteristic of infection with *C. violaceum*<sup>9,10</sup>. The fulminant septicemia is usually followed by failure of multiple organs<sup>3</sup>. Leukopenia and platelet depletion as severe as those detected in the present patient have been reported in pediatric cases and disseminated intravascular coagulation was observed in a child<sup>8</sup>. These complications are probably consequences of the lipopolysaccharide and other toxins produced by the large number of bacilli infecting the tissues. Newly formed abscesses in the liver and lungs, tissue necrosis and the presence of Gram-negative bacilli are autopsy findings suggestive of chromobacteriosis<sup>1</sup>. Melioidosis should be included in the differential diagnosis of these cases because of the similarity in the clinical manifestations and pathological changes<sup>10</sup>.

Slower progression and late relapses have been verified in some cases of chromobacteriosis<sup>4,7</sup>.

Although *C. violaceum* is considered nonpathogenic, this bacterium causes systemic infection in domestic animals and previously healthy individuals. Most patients have no underlying disease, but there are case reports of opportunistic infections in deficient phagocytosis diseases. Chronic granulomatous disease of childhood is a predisposing factor to *C. violaceum* infections<sup>8</sup>. The patient reported here had no previous manifestations of abnormality in leukocyte function or of immunosuppressive disease. His brief survival in hospital prevented a laboratory investigation of immunologic function.

As observed for other *C. violaceum* strains<sup>9</sup>, the isolated bacillus was resistant to ampicillin and to various cephalosporins. It was susceptible to chloramphenicol, aminoglycosides, ciprofloxacin, tetracyclin and sulfamethoxazole-trimethoprim, which have been recommended for the treatment of patients with chromobacteriosis. Thus, for an appropriate empirical treatment, *C. violaceum* should be considered in the differential diagnosis of infection, especially in patients exposed to stagnant water or to muddy soil<sup>4,8</sup> and in cases of pneumonia caused by near-drowning<sup>2</sup>.

The case reported here confirms that *C. violaceum*, although rare, is an etiologic agent of severe community infections in Brazil.

## RESUMO

### Infecção por *Chromobacterium violaceum* no Brasil. Relato de caso

Relata-se o segundo caso de infecção por *Chromobacterium violaceum* ocorrido no Brasil. Um trabalhador agrícola, morador do Estado de São Paulo apresentou febre e intensa dor abdominal durante quatro dias. Ao ser hospitalizado estava em estado toxêmico e tinha o abdômen distendido e doloroso. Radiografia de tórax e ultrassonografia abdominal mostraram pneumonia e áreas hipoecóicas no fígado. O paciente desenvolveu falência de múltiplos órgãos e faleceu poucas horas depois. Em cultura de sangue foi isolado *C. violaceum* resistente à ampicilina e a cefalosporinas, mas suscetível a cloranfenicol, tetraciclina, aminoglicosídeos e ciprofloxacina. À autópsia foram encontrados microabscessos pulmonares e múltiplos abscessos hepáticos. As

principais características deste caso são geralmente observadas em infecções por *C. violaceum*: evolução rápida, formação de abscessos viscerais múltiplos e alta mortalidade. Em razão do padrão de resistência antimicrobiana desse bacilo Gram-negativo ambiental, para se obter antibioticoterapia empírica apropriada em casos de graves infecções comunitárias no Brasil é importante incluir no diagnóstico diferencial a cromobacteriose.

## REFERENCES

1. DAUPHINAIS, R.M. & ROBBEN, G.G. - Fatal infection due to *Chromobacterium violaceum*. **Amer. J. clin. Path.**, **50**: 592-597, 1968.
2. ENDER, P.T. & DOLAN, M.J. - Pneumonia associated with near-drowning. **Clin. infect. Dis.**, **25**: 896-907, 1997.
3. GEORGHIOU, P.R.; O'KANE, G.M.; SIU, S. & KEMP, R.J. - Near fatal septicaemia with *Chromobacterium violaceum*. **Med. J. Aust.**, **150**: 720-721, 1989.
4. HUFFAM, S.E.; NOWOTNY, M.J. & CURRIE, B.J. - *Chromobacterium violaceum* in tropical Northern Australia. **Med. J. Aust.**, **168**: 335-337, 1998.
5. KAUFMAN, S.C.; CERASO, D. & SCHUGURENSKY, A. - First case report from Argentina of fatal septicemia caused by *Chromobacterium violaceum*. **J. clin. Microbiol.**, **23**: 956-958, 1986.
6. LEE, J.; KIM, J.S.; NAHAM, C.H. *et al.* - Two cases of *Chromobacterium violaceum* infection after injury in a sub tropical region. **J. clin. Microbiol.**, **37**: 2068-2070, 1999.
7. PETRILLO, V.F.; SEVERO, V.; SANTOS, M.M. & EDELWEISS, E.L. - Recurrent infection with *Chromobacterium violaceum*: first case report from South America. **J. Infect.**, **9**: 167-169, 1984.
8. PONTE, R. & JENKINS, S. - Fatal *Chromobacterium violaceum* infections associated with exposure to stagnant waters. **Pediat. infect. Dis. J.**, **11**: 583-586, 1992.
9. ROBERTS, S.A.; MORRIS, A.J.; MCIVOR, N. & ELLIS-PEGLER, R. - *Chromobacterium violaceum* infection of the deep neck tissues in a traveler to Thailand. **Clin. infect. Dis.**, **25**: 334-335, 1997.
10. TI, T.-Y.; TAN, W.C.; CHONG, A.P.Y. & LEE, E.H. - Nonfatal and fatal infections caused by *Chromobacterium violaceum*. **Clin. infect. Dis.**, **17**: 505-507, 1993.

Received: 30 September 1999

Accepted: 29 February 2000