

## HANTAVIRUS PULMONARY SYNDROME IN BRAZIL: CLINICAL ASPECTS OF THREE NEW CASES

Marcelo S. FERREIRA(1), Sérgio de A. NISHIOKA(1), Thogo L. SANTOS(1), Rubens P. SANTOS(2), Paulo S. SANTOS(2) & Ademir ROCHA(1)

### SUMMARY

Hantavirus pulmonary syndrome (HPS) has been recognized recently in Brazil, where 28 cases have been reported as of September 1999. We report here the clinical and laboratory findings of three cases whose diagnoses were confirmed serologically. All the patients were adults who presented a febrile illness with respiratory symptoms that progressed to respiratory failure that required artificial ventilation in two of them. Laboratory findings were most of the time consistent with those reported in the United States in patients infected with the *Sin Nombre* virus, and included elevated hematocrit and thrombocytopenia; presence of atypical lymphocytes was observed in one patient. The chest radiological findings observed in all the patients were bilateral, diffuse, reticulonodular infiltrates. Two patients died. Histopathological examination of the lungs of these patients revealed interstitial and alveolar edema, alveolar hemorrhage, and mild interstitial pneumonia characterized by infiltrate of immunoblasts and mononuclear cells. In the epidemiologic investigation of one of the cases, serologic (ELISA) tests were positive in 3 (25%) out of 12 individuals who shared the same environmental exposure. HPS should be included in the differential diagnosis of interstitial pneumonia progressing to acute respiratory failure.

**KEYWORDS:** Brazil; Hantaviruses; Hantavirus pulmonary syndrome.

### INTRODUCTION

Hantavirus pulmonary syndrome (HPS) is an emergent disease firstly recognized in southwestern United States causing an outbreak of a respiratory distress syndrome with high case-fatality rate. The disease is caused by novel hantaviruses that have in common the fact of having as reservoirs wild rodents of the subfamily Sigmodontinae. Contact with excreta of these rodents is the usual form of transmission of the disease from usually asymptomatic rodents to human beings. Several species of hantavirus have been recognized in the American continent, some of them associated with HPS. The *Sin Nombre* virus (SNV) is responsible for the large majority of the cases in North America, but in South America other viruses are involved, including the *Andes* virus in Argentina and Chile, *Laguna Negra* in Paraguay, and *Rio Mamore* in Bolivia. In Brazil, 28 cases (including these reported here) have been recognized as of September 1999, from four different states (São Paulo, 16 cases, Rio Grande do Sul, 5 cases, Minas Gerais, 4 cases, and Mato Grosso, Paraná, and Pará, one case each) (Mauro Elkhoury, Fundação Nacional de Saúde, written personal communication); only five of these cases have been published so far<sup>6,12</sup>. All the Brazilian cases were diagnosed serologically; no hantavirus has been isolated from rodents in this country. Recent data obtained from Brazilian patients suggest that there are at least three genetically distinct hantaviruses associated with HPS in Brazil, one of them phylogenetically closer to the *Andes* virus from Argentina<sup>7</sup>. The

case-fatality rate of the Brazilian cases so far is 69% (Mauro Elkhoury, Fundação Nacional de Saúde, written personal communication), whereas in the United States it was 50% in 1993 and has decreased yearly, having reached 20% in 1997<sup>10</sup>, and in Argentina it is 55%<sup>1</sup>.

We report here clinical aspects and laboratory and radiographic findings of two fatal cases of HPS, which were documented with histopathological examination of the lungs, and one additional case that survived.

### CASE REPORTS

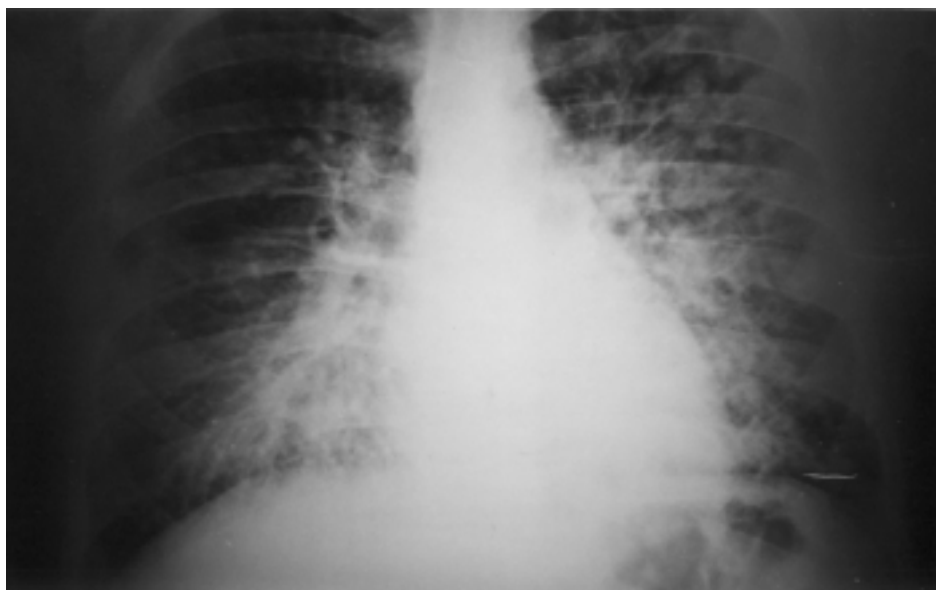
#### Patient 1

In June 1996, a 28-year-old male veterinary from Franca, São Paulo state, complained of fever, myalgias, and non-productive cough, which had started a few days before, and had worsened in the last 72 hours. On physical examination the patient had axillary temperature of 37.5 °C, dyspnea, cyanosis, and rales on both lung bases. The chest X-ray showed bilateral diffuse, mostly perihilar reticulonodular infiltrates (Figure 1). Admitted to the hospital he rapidly deteriorated to severe respiratory failure within 10 hours, notwithstanding the administration of intravenous fluids, bronchodilators and antibiotics. He was transferred to the Intensive Care Unit (ICU) for mechanical ventilation, where he died after 12 hours.

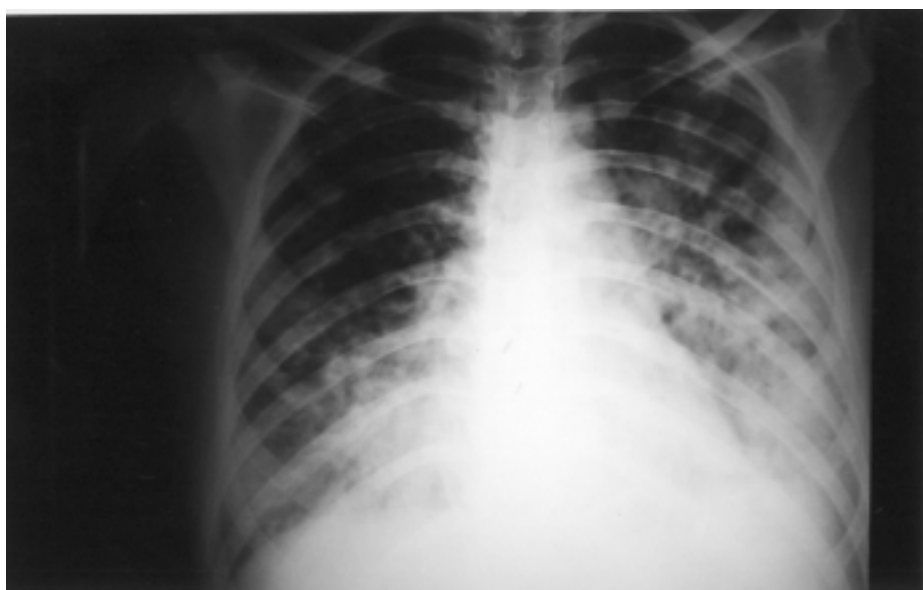(1) Centro de Ciências Biomédicas, Universidade Federal de Uberlândia, Uberlândia, MG, Brazil.

(2) Hospital Regional de Franca, Franca, SP, Brazil.

**Correspondence to:** Dr. Marcelo Simão Ferreira, Rua Goiás 480, Apto. 500, 38400-027 Uberlândia, MG, Brazil; Telephone: +55-34-971 2045; Telefax: +55-34-236 3151



**Fig. 1** - Chest X-ray showing bilateral diffuse, mostly perihilar reticulonodular infiltrates (Patient 1).

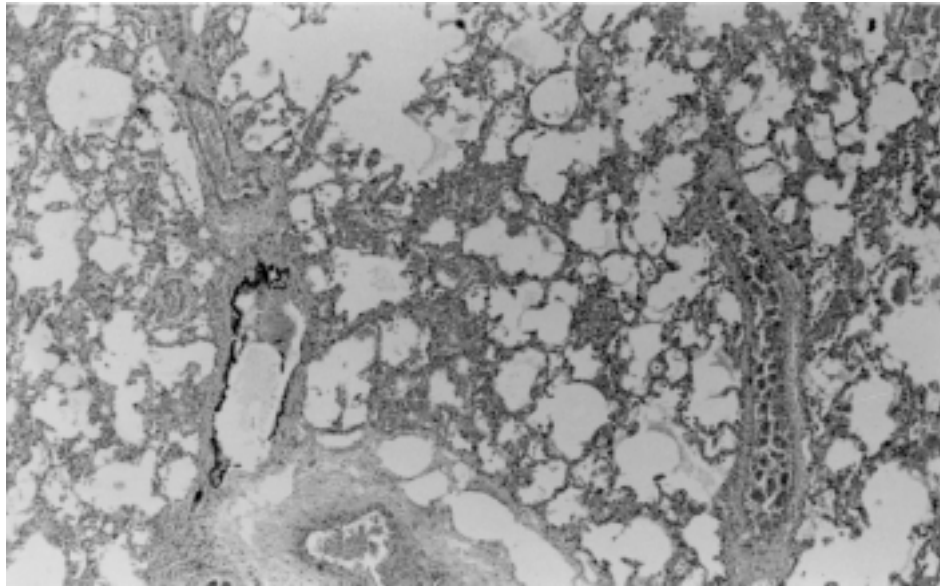


**Fig. 2** - Chest X-ray revealing bilateral diffuse, predominantly bibasilar reticulonodular infiltrates (Patient 2).

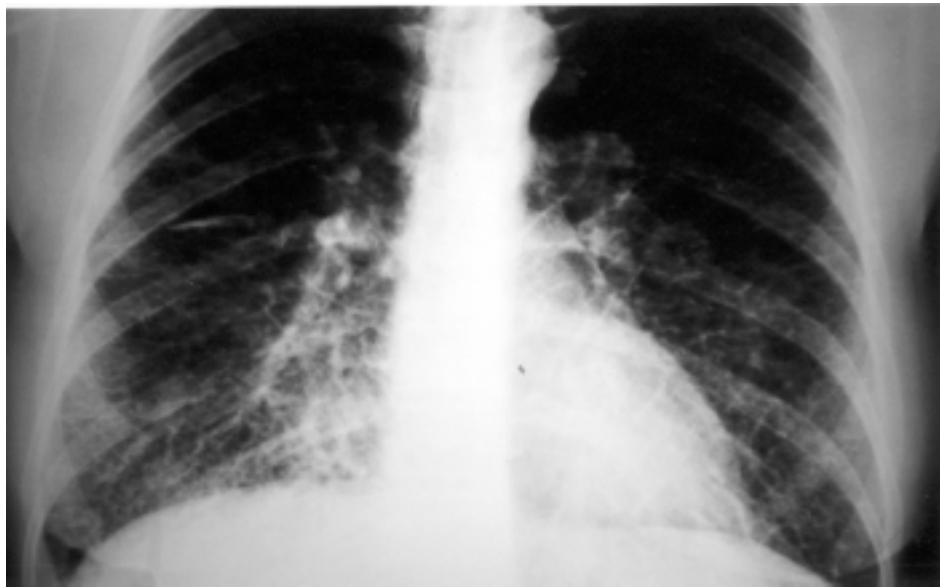
Blood tests revealed hemoglobin of 16.8 g/dl, hematocrit of 52%, and 6500 leukocytes per cubic milliliter (17% band forms). The serum alanine aminotransferase (ALT) was 57 U/l, the serum creatinine was 1.5 mg/dl, and the serum glucose 105 mg/dl. Two blood cultures, direct examination and culture of the sputum for bacteria, acid-fast bacilli and fungi were negative, and so was direct immunofluorescence of the sputum for *Pneumocystis carinii*. Serological tests for legionellosis (indirect immunofluorescence [IF]), HIV infection (enzyme-linked immunosorbent assay [ELISA] and Western-blot), *Chlamydia pneumoniae* infection (IF), paracoccidioidomycosis (immunodiffusion [ID]), histoplasmosis (ID) and rickettsial infections (Weil-Felix test) were all

negative. Serologic test (ELISA) for hantavirus using SNV antigen, performed at the Instituto Adolpho Lutz, São Paulo, was positive for IgM antibodies (titer $\geq$ 1:6400). An autopsy was not authorized, but permission was obtained for an open lung biopsy. The histologic examination of the lung tissue showed interstitial and alveolar edema, interstitial inflammatory infiltrates, presence of immunoblasts and macrophages, and mild intraalveolar deposit of hyaline substance.

The patient worked with horses in exhibition parks, had a small farm where he went to on weekends, and traveled extensively to many farms in the states of São Paulo and Mato Grosso. There is no precise



**Fig. 3** - Lung tissue obtained from Patient 2 showing interstitial and alveolar edema, alveolar hemorrhage, and mild interstitial pneumonia (Hematoxylin-eosin, x400).



**Fig. 4** - Chest X-ray revealing diffuse bilateral interstitial infiltrates (Patient 3).

information as to whether he had contact with urban or wild rodents. Serologic (ELISA) tests carried out in 12 workers of the exhibition park in Franca, and 5 workers of his farm, were positive (IgG) in 3 individuals of the first group.

#### **Patient 2**

In August 1998, a 34-year-old housewife from Uberlândia, Minas Gerais state, was admitted to a private hospital complaining of fever, headache, and generalized myalgia for five days, and cough and dyspnea for two days. She had also had episodes of diarrhea and vomiting during

this period. Physical examination (positive findings only) revealed the presence of conjunctival hyperemia, dyspnea, mild cyanosis, and bilateral pulmonary rales. Chest radiography revealed bilateral diffuse, predominantly basilar reticulonodular infiltrates (Figure 2). Within a few hours she was intubated and put under mechanical ventilation. She developed shock with normal central venous pressure, which was transiently responsive to the infusion of dopamine and dobutamine, but progressed to cardiac arrest within 18 hours. Laboratory tests of interest included hemoglobin of 17.3 g/dl, hematocrit of 53.6%, 5600 leukocytes per cubic milliliter (51% band forms, 22% neutrophils, 20% lymphocytes, 7% monocytes, 7% atypical lymphocytes), 52000 platelets per cubic

milliliter, serum creatinine of 0.5 mg/dl, serum lactic dehydrogenase (LDH) 1489 U/l, serum ALT 81 U/l, aspartate aminotransferase (AST) 141 U/l, gamma glutamyl transpeptidase ( $\gamma$ GT) 123 U/l. The prothrombin time was 13.6 seconds (activity 53.3%), and the partial activated thromboplastin time was 185 seconds. Blood gas tests determined just before the initiation of artificial ventilatory support showed pH 7.41,  $p\text{CO}_2$  28.0 mmHg,  $p\text{O}_2$  44.0 mmHg,  $\text{O}_2$  saturation 81.0%, serum bicarbonate 17 mmol/l, base excess -6.0 mmol/l. Serologic test (ELISA) for hantavirus, using SNV antigen, performed at the Instituto Adolpho Lutz, São Paulo, was positive for IgM antibodies. A postmortem biopsy of the lung but not a complete autopsy was authorized, and revealed interstitial and alveolar edema, alveolar hemorrhage, and mild interstitial pneumonia characterized by infiltrate of immunoblasts and mononuclear cells (Figure 3).

This patient had contact with rodent excreta at home, in a stable in the outskirts of Uberlândia, and in a farm in a neighboring town. Epidemiologic investigation, still in progress, has been so far inconclusive.

### Patient 3

A 42-year-old housewife from Uberlândia was seen by a clinician in June 1999, complaining of fever, myalgia, and dry cough for four days, and dyspnea in the last few hours. Physical examination revealed a temperature of 38.5 °C, respiratory rate 42/minute, heart rate 120 beats/minute, blood pressure 120/80 mmHg, cyanosis, rales on the left lung; and a tender liver palpable 3 cm below the right costal margin. Chest radiography revealed diffuse bilateral interstitial infiltrates (Figure 4). The hemoglobin was 16.4 g/dl, the hematocrit was 47.7%; the white blood cell count was 7100 leukocytes per cubic millimeter (44% band forms, 32% neutrophils, 19% lymphocytes, 5% monocytes), and the platelet count was 74000 per cubic millimeter. The AST was 109 U/L, ALT 44 U/L,  $\gamma$ GT 27 U/L, alkaline phosphatase 105 U/L, LDH 646 U/L, and creatine kinase 455 U/L. Blood gas tests were pH 7.49,  $\text{PO}_2$  62 mmHg,  $\text{PCO}_2$  35.5 mmHg, bicarbonate 27.4 mmol/l, base excess +4.7 mmol/l. Serologic tests for dengue (MAC-ELISA) and leptospirosis (agglutination) were negative. Crioagglutinins were negative. Serologic test for hantavirus (ELISA), performed at the Instituto Adolpho Lutz, São Paulo, was positive for IgM antibodies. Treatment included IV hydration and IV levofloxacin 500mg once daily for 11 days. The patient improved within 72 hours; mechanical ventilation was not required. The epidemiologic investigation revealed no probable source of contamination; the patient denied contact with rodents, and her last trip was four months before to rural Uberlândia.

### DISCUSSION

HPS has been described mostly in young male adults; rare cases have been recognized in children, with the sole exception of Chile<sup>10</sup>. Our cases follow this pattern of age distribution, and have also the high case-fatality rate that has been reported in the literature. It has been documented from seroepidemiological studies that many individuals from areas where cases of HPS have been recognized are seropositive for hantaviruses, suggesting that oligo- or asymptomatic infections occur; in South America this has been observed in Argentina, Paraguay, and Brazil<sup>4,14</sup>. The finding of seropositive individuals in the exhibition park in Franca (case 1) suggest that the virus circulates in that region.

The pathogenesis of HPS is believed to be related to the immune response to the virus, that is responsible for the increased capillary permeability that leads to pulmonary edema. Notwithstanding the fact that virus antigen is found in the microvascular endothelial cells, the disturbance is basically functional, and there is no alveolar damage in the large majority of the patients. Pulmonary edema is a major histological finding, with mild hyaline membrane, and interstitial infiltrate of lymphocytes (immunoblasts) and activated macrophages<sup>10</sup>. Other organs such as the liver and the spleen also show lymphocytic infiltrates. These lymphocytes are CD8+ that probably produce cytokines that act on the endothelial cells and also activate macrophages to produce more cytokines; these are responsible for the increased capillary leak<sup>9</sup>.

The clinical findings of HPS have been relatively constant in the different parts of the American continent where it has been described. The typical patient presents a prodrome of up to a week of fever, myalgia, malaise and, sometimes, nausea, vomiting, abdominal pain and dizziness<sup>4, 5, 10, 12, 13</sup>. Conjunctival injection, observed in patient 2, has been unusual in infections by the SNV, but is a common manifestation in infections with the *Andes* virus<sup>10</sup>. Respiratory symptoms may be mild at the beginning, but tachycardia and tachypnea with absent or mild lung auscultation abnormalities, seen initially, rapidly progress to severe respiratory failure that often requires artificial respiratory support. Cardiovascular depression and shock, of unknown cause, occur in severe cases, such as in our patient 2, and is an indicator of poor prognosis. Death is due to hypoxia and/or circulatory compromise. Two of our cases basically followed the pattern described above for severe cases, whereas patient 3, although presenting similar clinical manifestations at the beginning, had a milder form of the disease. Therefore it is unclear whether any sign or symptom, isolated or in combination, can predict the outcome of individuals with HPS.

Chest radiographic findings are those of interstitial edema, such as peribronchial haze and Kerley B lines, and progress subsequently to alveolar flooding, without the peripheral pattern usually seen in the acute phase of adult respiratory distress syndrome (ARDS)<sup>6</sup>. The radiological findings of patient 3 (Figure 4) is an example of the initial phase of the disease, and this patient did not progress to the late phase of ARDS presented by patients 1 and 2 (Figures 1 and 2). Pleural effusion of variable severity has been commonly described in patients with HPS caused by the SNV<sup>6</sup>; none of our patients had this finding.

Elevated hematocrit (>49%), thrombocytopenia, normal or elevated leukocyte count with left shift, and presence of atypical lymphocytes are the most characteristic laboratory findings, and very suggestive of this syndrome. Most of these findings were present in our patients. Other than thrombocytopenia, abnormal partial thromboplastin time and prolonged prothrombin time are evidence of laboratory coagulopathy, although an hemorrhagic diathesis is unusual. Hypoalbuminemia, metabolic acidosis, elevated aminotransferases and lactic dehydrogenase are other common findings of patients with HPS. Blood urea nitrogen and serum creatinine levels are usually normal, except when there is important circulatory involvement. Abnormal urinary sediment and mild proteinuria are common.

The initial manifestations are flu-like and therefore unspecific. When respiratory failure appears the main differential diagnoses include bacterial pneumonia, influenza, leptospirosis, pneumonic plague, viral

hemorrhagic fevers, and other causes of adult respiratory distress syndrome (ARDS). MOOLENAR *et al.*<sup>8</sup>, comparing patients with proved HPS, bacteremic pneumococcal pneumonia, influenza, and unexplained ARDS, reported that the presence of dizziness, nausea or vomiting and the absence of cough at admission, and low platelet count, low serum bicarbonate level, and elevated hematocrit level identified all patients with HPS and excluded at least 80% of the patients with unexplained ARDS. Patients with HPS who develop shock have low cardiac output and high systemic vascular resistance, which is a very different hemodynamic pattern than septic shock.

Virus isolation is not done in practice. Etiologic diagnosis is made by serological tests and detection of viral genome by reverse transcription and polymerase chain reaction (RT-PCR). ELISA for detection of IgM and IgG antibodies to SNV antigens is the immunological test that has been used in Brazil. The use of a local strain has not been possible, but this is not considered necessary because hantaviruses share a high amino acid identity. The IgM ELISA must be run in the IgM capture format to avoid cross-reactions. Other serological tests available include indirect immunofluorescence, neutralization, passive hemagglutination and western blot. The IgM capture ELISA is considered to be the best because it is virtually always positive in the first sample tested from a patient, with very rare false positives<sup>10</sup>.

There is no specific treatment for HPS. Both the SNV and the Black Creek Canal virus have been shown to be sensitive *in vitro* to ribavirin, a nucleoside analogue, and this drug has been shown to be effective in China for the treatment of hemorrhagic fever with renal syndrome, a disease also caused by hantaviruses. Ribavirin, however, was not effective for the treatment of HPS in an open-label study in the United States<sup>2</sup>. The treatment aims basically at maintaining adequate oxygenation, which usually is achieved by mechanical ventilation, and providing hemodynamic support. Fluid resuscitation must be done carefully to avoid worsening of the pulmonary edema. Administration of inotropic agents is usually necessary. Extracorporeal membrane oxygenation<sup>3</sup> and inhaled nitric oxide<sup>11</sup> have been used in few cases and, where available, are alternatives for the treatment of severe cases. There is no evidence that corticosteroids are beneficial for the treatment of respiratory failure and shock associated with HPS.

Prevention of HPS can be obtained by avoiding contact with wild rodents and their excreta. Measures to exclude the presence of rodents in households include modifications to eliminate rodent access and avoiding leaving exposed food in open dustbins and for feeding pets. HPS can also be acquired when human hosts invade the habitat of wild rodents for leisure activities (e.g. camping) or professional purposes (like do field biologists and archeologists); these individuals should be careful with handling rodents and soil contaminated with their excreta.

## RESUMO

### Síndrome pulmonar por hantavírus no Brasil: aspectos clínicos de três novos casos

Síndrome pulmonar por hantavírus (SPH) tem sido reconhecida recentemente no Brasil, onde 28 casos foram registrados até setembro de 1999. Relatamos aqui os achados clínicos e laboratoriais de três casos confirmados sorologicamente. Os pacientes eram adultos e apresentaram

doença febril com sintomas respiratórios que progrediram para insuficiência respiratória, requerendo ventilação artificial em dois deles. Os achados laboratoriais, na maioria dos casos, foram consistentes com os encontrados em pacientes infectados com o vírus *Sin Nombre* nos Estados Unidos, incluindo hematócrito elevado e trombocitopenia; a presença de linfócitos atípicos foi observada em um paciente. O achado radiológico comum a todos os pacientes foi infiltrado reticulonodular difuso bilateral. Dois pacientes evoluíram para o óbito. Nestes pacientes, o exame histopatológico dos pulmões mostrou a presença de edema intersticial e alveolar, hemorragia alveolar, e pneumonia intersticial leve caracterizada por infiltrado de imunoblastos e células mononucleares. Na investigação epidemiológica de um dos casos, testes sorológicos (ELISA) foram positivos em 3 (25%) de 12 indivíduos que compartilharam a mesma exposição ambiental. A SPH deve ser incluída no diagnóstico diferencial das pneumonias intersticiais que causam insuficiência respiratória aguda.

## REFERENCES

1. CANTONI, G.; LAZARO, M.; RESA, A. *et al.* - Hantavirus pulmonary syndrome in the province of Rio Negro, Argentina, 1993-1996. **Rev. Inst. Med. trop. S. Paulo**, 39: 191-196, 1997.
2. CHAPMAN, L.E.; MERTZ, G.; KHAN, A.S. *et al.* - Open label intravenous ribavirin for hantavirus pulmonary syndrome. In: INTERSCIENCE CONFERENCE ON ANTIMICROBIAL AGENTS AND CHEMOTHERAPY, 34. Washington, American Society of Microbiology, 1994. **Abstracts**. H-111.
3. CROWLEY, M.R.; KATZ, R.W.; KESSLER, R. *et al.* - Successful treatment of adults with severe hantavirus pulmonary syndrome with extracorporeal membrane oxygenation. **Crit. Care Med.**, 26: 409-414, 1998.
4. FERRER, J.F.; JONSSON, C.B.; ESTEBAN, E. *et al.* - High prevalence of hantavirus infection in Indian communities of the Paraguayan and Argentinean Gran Chaco. **Amer. J. trop. Med. Hyg.**, 59: 438-444, 1998.
5. FIGUEIREDO, L.T.; MORELI, M.L.; ALMEIDA, V.S.O. *et al.* - Hantavirus pulmonary syndrome (HPS) in Guariba, SP, Brazil: report of 2 cases. **Rev. Inst. Med. trop. S. Paulo**, 41: 131-137, 1999.
6. KETAI, L.H.; WILLIAMSON, M.R.; TELEPAK, R.J. *et al.* - Hantavirus pulmonary syndrome: radiographic findings in 16 patients. **Radiology**, 191: 665-668, 1994.
7. MONROE, M.C.; MORZUNOV, S.P.; JOHNSON, A.M. *et al.* - Genetic diversity and distribution of *Peromyscus*-borne hantaviruses in North America. **Emerg. infect. Dis.**, 5: 75-86, 1999.
8. MOOLENAR, R.L.; DALTON, C.; LIPMAN, H.B. *et al.* - Clinical features that differentiate hantavirus pulmonary syndrome from three other acute respiratory illnesses. **Clin. infect. Dis.**, 21: 643-649, 1995.
9. MORI, M.; ROTHMAN, A.L.; KURANE, I. *et al.* - High levels of cytokine-producing cells in the lung tissues of patients with fatal hantavirus pulmonary syndrome. **J. infect. Dis.**, 179: 295-302, 1999.
10. PETERS, C.J. - Hantavirus pulmonary syndrome in the Americas. In: SCHELD, W.M.; CRAIG, W.A. & HUGHES, J.M., ed. **Emerging infections 2**. Washington, ASM Press, 1998. p. 17-64.
11. ROSENBERG, R.B.; WAAGNER, D.C.; ROMANO, M. J.; KANASE, H. N. & YOUNG, R.B. - Hantavirus pulmonary syndrome treated with inhaled nitric oxide. **Pediatr. infect. Dis. J.**, 17: 749-752, 1998.
12. SILVA, M.V.; VASCONCELOS, M.J.; HIDALGO, N.T. R. *et al.* - Hantavirus pulmonary syndrome: report of the first three cases in São Paulo, Brazil. **Rev. Inst. Med. trop. S. Paulo**, 39: 231-234, 1997.

13. VASCONCELOS, M.I.; LIMA, V.P.; IVERSSON, L.B. *et al.* - Hantavirus pulmonary syndrome in the rural area of Juquitiba, São Paulo metropolitan area, Brazil. **Rev. Inst. Med. trop. S. Paulo**, 39: 237-238, 1997.

14. ZAPAROLLI, M.A.; IVERSSON, L.B.; ROSA, M.D. *et al.* - Investigation on case-contacts of human disease caused by hantavirus in Juquitiba, state of São Paulo, Brazil. **Amer. J. trop. Med. Hyg.**, 53 (suppl.): 232-233, 1995.

Received: 30 August 1999

Accepted: 29 November 1999