

# TENASCIN AND FIBRONECTIN IN PLEOMORPHIC ADENOMA OF THE SALIVARY GLAND

## TENASCINA E FIBRONECTINA EM ADENOMA PLEOMÓRFICO DE GLÂNDULA SALIVAR

Patrícia Meira BENTO<sup>1</sup>, Roseana de Almeida FREITAS<sup>2</sup>, Leão PEREIRA PINTO<sup>2</sup>, Lélia Batista de SOUZA<sup>2</sup>

1- PhD, Professor of Radiology, Campina Grande Dental School, State University of Paraíba, Campina Grande, PB, Brazil.

2- PhD, Professor of Oral Pathology, Dental School, Federal University of Rio Grande do Norte, Natal, RN, Brazil.

**Corresponding address:** Profa Dra. Lélia B. Souza - Av. Senador Salgado Filho, 1787 - Cep.: 59056-000 - Natal, RN, Brazil  
Tel.:(84)3215-4132; fax: (84)3215-4138 - e-mail:[leliasouza@dod.ufrn.br](mailto:leliasouza@dod.ufrn.br)

**Received: November 07, 2005 - Modification: March 10, 2006 - Accepted: April 19, 2006**

### ABSTRACT

**O**bjectives: To analyze the expression and distribution pattern of extracellular matrix components in pleomorphic adenomas of the major and minor salivary glands and to compare the morphological findings of these tumors with the immunohistochemical expression, considering the different types of stroma predominating in each case. Methods and Results: The expression of tenascin (TN) and fibronectin (FN) was analyzed in 23 cases of pleomorphic adenomas, 11 major and 12 minor salivary gland tumors, by the streptavidin-biotin method using anti-tenascin and anti-fibronectin antibodies. In addition, the immunohistochemical results were correlated with the morphological findings of the lesions. All cases analyzed were immunoreactive for the antibodies used. Fibronectin showed strong labeling in fibrous and chondroid stroma, while labeling was weak in hyaline and myxoid stroma. Tenascin expression was more intense in fibrous and chondroid stroma and moderate in hyaline and myxoid stroma.

Conclusions: No difference in the expression of these proteins was observed between major and minor salivary gland tumors.

**Uniterms:** Extracellular matrix; Fibronectin; Tenascin; Pleomorphic adenoma; Salivary gland neoplasia.

### RESUMO

**O**bjetivo: Analisar a expressão e o padrão de distribuição de componentes da matriz extracelular em adenomas pleomórficos de glândula salivar maior e menor e comparar os achados morfológicos destes tumores com a expressão imuno-histoquímica considerando os diferentes tipos de estromas presentes em cada caso. Métodos e Resultados: A expressão da tenascina (TN) e fibronectina (FN) foi analisada em 23 casos de adenomas pleomórficos, sendo 11 tumores em glândula salivar maior e 12 em glândula salivar menor, utilizando-se o método da estreptoavidina-biotina para os anticorpos anti-tenascina e anti-fibronectina. Os resultados imuno-histoquímicos foram correlacionados com os achados morfológicos das lesões. Todos os casos foram imunorreativos para a fibronectina mostrando forte expressão nos estromas fibrosos e condróides, embora fraca marcação tenha sido evidenciada nos estromas hialinos e mixóides. A expressão da tenascina foi mais intensa nos estromas condróides e fibrosos, sendo moderada nos estromas hialino e mixóide. Conclusões: Não houve diferença na expressão destas proteínas entre os tumores de glândula salivar maior e menor.

**Unitermos:** Matriz extracelular; Fibronectina; Tenascina; Adenoma pleomórfico; Neoplasia de glândula salivar.

## INTRODUCTION

Pleomorphic adenoma is the most common benign neoplasia of the salivary glands and is distinguished by its cytomorphological and architectural diversity. Pleomorphic adenomas consist of two types of cells, i.e., luminal and non-luminal cells, and contain a variable stroma that can be of the hyaline, myxoid, chondroid or fibrous type. Parenchymatous cells are arranged in nests, chains, sheets or in duct-like structures within these different types of stroma<sup>3,6,13</sup>. The marked stromal variety observed in this neoplasia results from factors such as the quantity and distribution of proteins of the matrix produced by epithelial and myoepithelial tumor cells, corresponding to the myxoid, chondroid and hyaline areas<sup>4</sup>.

The extracellular matrix (ECM) plays an important role in the regulation of cell behavior and in embryogenesis, wound healing and tumor growth due to variations in its composition and functioning in different tissues<sup>5</sup>. This matrix acts as a support mechanism and cell anchor, participates in the compartmentalization of the tissue into reservoirs for substances produced by the cells, influences the regulation of gene expression, mediates cell binding, and participates in the filtration of salts and small molecules. Among the matrix components, fibronectin and tenascin represent predominantly adhesive fibrous proteins, which play a fundamental role in the signaling process between cells and in the control of the activity of other secreted proteins such as growth factors, proteases and protease inhibitors<sup>1</sup>.

Several studies have been carried out to analyze the expression of ECM components in different pathological conditions, with emphasis on investigations analyzing fibronectin and tenascin<sup>11,12,14,15,16,17</sup>. Some investigators have emphasized the importance of the interaction between pleomorphic adenoma neoplastic cells and matrix components such as fibronectin and tenascin<sup>14,16</sup>, which led others to suggest that these interactions influence the variable morphological picture observed in this tumor<sup>11</sup>.

Based on the assumption that salivary gland neoplasias tumor cells are able to modify the ECM through the lysis or synthesis of matrix components, or even by promoting desmoplasia, the purposes of this study were to analyze the expression and distribution pattern of tenascin and fibronectin in pleomorphic adenomas of the major and minor salivary glands, and to compare the morphological findings of these lesions to the immunohistochemical expression of tenascin and fibronectin, considering the types of stroma predominating in each case.

## MATERIAL AND METHODS

Twenty-three paraffin-embedded pleomorphic adenoma specimens, 11 major and 12 minor salivary gland tumors, were obtained from the files of the Anatomical Pathology Service of the Department of Oral Pathology, Dental School, Federal University of Rio Grande do Norte (UFRN), and of the Laboratory of Medical Pathology. The study was

approved by UFRN's Research Ethics Committee.

Morphological analysis was performed on hematoxylin/eosin-stained slides stored in the above files. For immunohistochemical analysis, 3- $\mu$ m thick sections were obtained from tissue specimens fixed in 10% formalin and embedded in paraffin. The sections were mounted on glass slides previously treated with organosilane (3-aminopropyltriethoxy-silane; Sigma Chemical Co., St. Louis, MO, USA) adhesive and labeled by the streptavidin-biotin method using anti-tenascin (clone TN2, Dako, A/S Corporation, 1:50, 18 h) and anti-fibronectin (clone, A-245, Dako, A/S Corporation, 1:500, 2 h) antibodies. Antigen was recovered with 0.4% pepsin in an incubator at 37°C for 30 min and with 1% pepsin at 37°C for 1 h, respectively. The sections were then incubated with 0.03% diaminobenzidine (Sigma) chromogen solution and counterstained with Mayer's hematoxylin.

The expression and distribution of tenascin and fibronectin were analyzed in each case under light microscopy using the following parameters: immunoreactivity, location and labeling pattern (intense, moderate, weak, or absent). This analysis was performed by two experienced pathologists.

## RESULTS

Microscopically, the 11 major salivary gland tumors were characterized by the presence of polygonal cells arranged in sheets, chains, nests and duct-like structures whose lumen, in some cases, contained eosinophilic material, with a double cell layer being observed in most cases. Myoepithelial cells, present in smaller numbers, showed mainly a spindle-shaped and plasmocytoid aspect and were characterized by a round morphology, eccentric nucleus and hyalinized eosinophilic cytoplasm. The stroma of these lesions was of the hyaline, myxoid, chondroid and fibrous types, although in some cases a predominance of one stromal type over the others was noted (Table 1).

The 12 cases of pleomorphic adenoma of the minor salivary glands were characterized by epithelial cells arranged in nests, sheets and duct-like structures. The cell type was either epithelial or myoepithelial, with the latter cell type showing a plasmocytoid or spindle-shaped morphology, or even appearing as clear cells. The presence of a double cell layer was sometimes noted in the duct-like structures. The stroma was of the fibrous, hyaline, myxoid and chondroid types (Table 1).

All cases analyzed were positive for fibronectin and tenascin, although the intensity of immunolabeling varied between specimens.

### Tenascin

In the 11 cases of pleomorphic adenoma of the major salivary glands, tenascin labeling was intense in 4 specimens (36.4%), moderate in 6 (54.5%) and weak in 1 (9.1%) (Table 2). The most intense labeling was observed in chondroid and fibrous stromal areas. Labeling was also intense in areas

surrounding parenchymatous epithelial nests (Figure 1A). With respect to the 12 cases of pleomorphic adenoma of the minor salivary glands, tenascin labeling was intense in 5 cases (41.7%), moderate in 3 (25%) and weak in 4 (33.3%). The highest tenascin expression was observed in fibrous and chondroid stromal areas (Table 2; Figure 1B).

**Fibronectin**

Regarding the pleomorphic adenoma of the major salivary glands, fibronectin labeling was intense in 5 specimens (45.4%), moderate in 4 (36.4%) and weak in 2 (18.2%), the highest immunoreactivity being observed in fibrous stroma, in areas adjacent to chondroid stroma, around cell nests in the basement membrane region, and in the fibrous capsule (Table 2; Figure 1C).

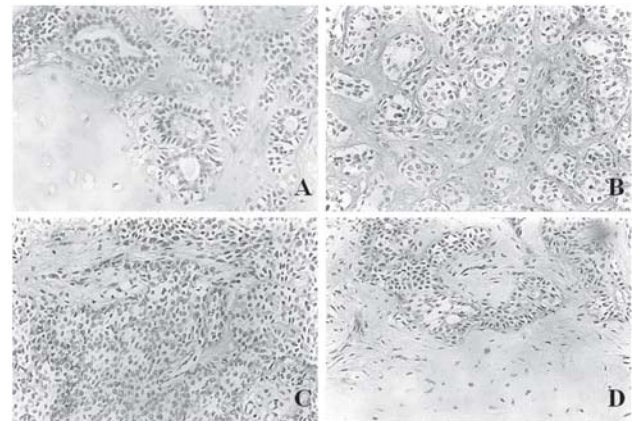
Regarding the pleomorphic adenoma of the minor salivary glands, fibronectin expression was intense in 5 specimens (41.6%), moderate in 4 (33.3%) and weak in 3 (25%). Intense labeling was observed in fibrous stroma, adjacent to chondroid areas, around epithelial nests, and in the fibrous capsule (Table 2; Figure 1D).

**DISCUSSION**

Pleomorphic adenoma is the most frequent neoplasia found in both major and minor salivary glands<sup>3,7,10</sup>, corresponding to 60% of all tumors of these organs. In the present study, microscopic analysis of the lesions showed the classical cytomorphological and architectural characteristics, with some variations according to the affected gland analyzed. In pleomorphic adenomas of the major salivary glands, the myoepithelial cells were mainly of the spindle-shaped type, while a predominance of plasmocytoid cells was observed in minor gland lesions in more than half of the cases, findings that are commonly reported by others<sup>3,13</sup>. Another interesting finding was the

fact that in major gland tumors the stromal component was more abundant, with chondroid areas being observed in a large number of cases, while in minor salivary gland lesions the formation of this stromal type was observed in only one case.

The complex composition that characterizes salivary gland neoplasias is attributed to the myoepithelial components of these tissues. Lam<sup>9</sup>, analyzing pleomorphic adenomas by histochemistry and electron microscopy, showed that the modified myoepithelial cell represents the cellular source of stromal matrix since it develops the ability



**Figure 1(A)**- Pleomorphic adenoma in major salivary gland. Immunostaining for tenascin in the chondroid stroma (streptavidin-biotin complex; original magnification X200); **(B)**. Minor salivary gland. Positive staining for tenascin in the fibrous stroma (streptavidin-biotin complex; original magnification X200); **(C)**. Major salivary gland. Strong expression for fibronectin in the fibrous stroma and around polygonal cells nests (streptavidin-biotin complex; original magnification X200); **(D)**. Minor salivary gland. Strong expression for fibronectin around epithelial cells nests and adjacent to the chondroid area (streptavidin-biotin complex; original magnification X200)

**TABLE 1-** Morphological pattern of the stroma of pleomorphic adenomas of the major and minor salivary glands

	Location	N	Stromal types							
			Hyaline		Fibrous		Mixoid		Chondroid	
			n	%	n	%	n	%	n	%
Major salivary gland	Parotid	9	6	54.5	6	54.5	9	81.8	5	45.5
	Submandibular	2	1	9.1	2	18.2	2	18.2	1	9.1
	Total	11	7	63.3	8	72.7	11	100.0	6	54.5
Minor salivary gland	Palate	7	6	50.0	6	50.0	6	50.0	-	-
	Lip	2	1	8.3	2	16.6	1	8.3	-	-
	Buccal Mucosa	1	1	8.3	-	-	1	8.3	-	-
	Fornix	2	1	8.3	1	8.3	2	16.6	1	8.3
	Total	12	9	75.0	9	75.0	10	83.3	1	8.3

N= number of cases *per* location. n= number of cases *per* stromal type

to synthesize glycosaminoglycans and proteoglycans. As a result, cells separate from each other and rupture the basement membrane that wraps duct-myoe epithelial cell units, thus permitting the migration and dispersal of these cells to the extracellular space. As a consequence of this, the stroma transforms into the myxoid type. Raitz et al.<sup>14</sup>, also stated that myoe epithelial cells lose their immunophenotype and acquire new characteristics.

In the present study, all specimens showed positive labeling, although of variable intensity, for anti-fibronectin and anti-tenascin antibodies. Soini, et al.<sup>16</sup> and Shrestha, et al.<sup>15</sup> suggested that the tenascin expression observed in the stroma of pleomorphic adenomas, mainly in chondroid areas, might be the result of a possible induction of chondrogenic differentiation because this protein plays a role in this differentiation process during embryogenesis. Thus, the fact that tenascin resumes this role in tumor development might explain the immunolabeling observed in the present study around chondroid areas.

Our results are similar to those reported by Sunardhi-Widyaputra and Van Damme<sup>17</sup> who observed a strong fibronectin expression around chondroid stroma, and to those reported by Luo, et al.<sup>11</sup> who detected a strong expression in chondroid, hyaline and myxoid areas. However, these findings are in contrast to those reported by Raitz, et al.<sup>14</sup>, who observed a higher fibronectin expression in hyaline stroma, even though we obtained similar results to theirs regarding fibronectin labeling in myxoid stromal areas in which the expression of this protein was weak.

Analysis of the immunohistochemical results obtained for tenascin showed moderate to intense expression in almost all cases of major salivary gland tumors (90.9%), while weak labeling was observed in only one case (9.1%). The strongest expression was detected in chondroid and fibrous stroma, as well as around neoplastic cell nests.

Tenascin expression in minor salivary gland tumors showed an equal distribution of intense, moderate and weak labeling, being intense in 5 cases, moderate in 3 and weak in 4. The strongest expression of this protein was observed in fibrous and chondroid stroma (because these lesions are

highly cellularized), resembling the embryonic stage of normal salivary glands in which tenascin plays an active role as reported by Alberts, et al.<sup>1</sup>

According to Nakamura, et al.<sup>12</sup>, referring to the chondroid areas of pleomorphic adenoma, tenascin also plays a role in tumor development and remodeling. In contrast, Shrestha, et al.<sup>15</sup> defended the participation of tenascin in embryogenesis, especially in areas of chondrocyte differentiation. These facts perfectly explain the stronger expression of tenascin in chondroid areas as observed in all cases of the present study irrespective of the gland involved, and also confirm the role of neoplastically transformed myoe epithelial cells in the formation of these chondroid areas as a result of glycosaminoglycan synthesis by these cells, as showed in several studies<sup>4,16,17</sup>.

Other authors<sup>16,17</sup> have suggested that the epithelial cells of pleomorphic adenomas release tenascin and secrete glycosaminoglycans, mainly hyaluronic acid and chondroitin sulfate, which accumulate between cells isolating them from the matrix. This fact might explain the labeling observed in the present study in areas around epithelial nests. In addition, glycosaminoglycans organize the ECM due to their ability to interact with chondroitin sulfate, fibronectin and other cells present in the stroma. These glycosaminoglycans have affinity for tenascin which, therefore, might play a role in ECM structural organization, as well as in epithelial-mesenchymal interactions and in the production of myxoid and chondroid stroma.

Some studies have already demonstrated the interaction between cells and ECM components. For example, Jaeger, et al.<sup>8</sup> observed *in vitro* that the most undifferentiated cells of pleomorphic adenomas differentiate into luminal or neoplastic myoe epithelial cells when in contact with the ECM. In this respect, ECM proteins play an important role in the development of neoplasias which, in turn, start to produce their own ECM. Castilho<sup>2</sup>, studying the expression of CD44 and hyaluronic acid in pleomorphic adenomas, reported that the presence of this acid in these lesions might facilitate cell adhesion to ECM components, thus promoting neoplastic

**TABLE 2-** Intensity of expression of tenascin and fibronectin in pleomorphic adenomas of the major and minor salivary glands

	Location	Intensity of expression number of cases (%)			Total
		+++	++	+	
Tenascin	Major salivary gland	4 (36.4)	6 (54.5)	1 (9.1)	11 (100)
	Minor salivary gland	5 (41.7)	3 (25)	4 (33.3)	12 (100)
Fibronectin	Major salivary gland	5 (45.4)	4 (36.4)	2 (18.2)	11 (100)
	Minor salivary gland	5 (41.6)	4 (33.3)	3 (25)	12 (100)

(+++) intense, (++) moderate, (+) weak.

growth.

Based on the above considerations, it should be emphasized the role of tenascin not only in the formation of normal tissues, as demonstrated by many authors, but also in the tumorigenesis process during which tenascin acquires importance in growth and differentiation, in addition to being involved in epithelial-mesenchymal interactions. In pleomorphic adenomas, these interactions play an important role in cell growth and differentiation, particularly in the production of myxoid and chondroid matrix frequently observed in the stroma of these tumors.

## CONCLUSIONS

It may be concluded that fibronectin and tenascin are both expressed in pleomorphic adenomas, although tenascin shows a higher expression in all types of stroma present in pleomorphic adenomas of both major and minor salivary glands.

## ACKNOWLEDGEMENTS:

The authors would like to thank Dr Alexandre de Oliveira Sales (Laboratory of Medical Pathology) for his kind help with the samples used in this study. This study was supported by CNPq (Grant nº 521748/97-6)

## REFERENCES

- 1- Alberts B, Bray D, Lewis J, Raff, M, Roberts, K, Watson, JD . Molecular Biology of Cell. 3rd ed. New York: Garland Publishing;1994.
- 2- Castilho RM. Análise da expressão do CD44 e do ácido hialurônico em adenoma pleomórfico de glândula salivar. São Paulo;2000. [Dissertação de Mestrado- Faculdade de Odontologia, Universidade de São Paulo].
- 3- Dardick I. Salivary gland tumor pathology-text of color atlas. New York Tokyo: Igaku-Shoin Medical Publishe;1996.
- 4- Dardick I., Nostrand P, Phillips J. Histogenesis of salivary gland pleomorphic adenoma (mixed tumor)with an evaluation of the role of the myoepithelial cell. Human Pathol.1982;13:62-75.
- 5- Deryugina EI, Bourdon MA. Tenascin mediates human glioma cell migration and modulates cell migration on fibronectin. J Cell Scien.1996;109:643-52.
- 6- Ellis GL, Auclair PL. Tumor of salivary glands, atlas of tumor pathology. Washington DC: Armed Forces Institute of Pathology; 1996.
- 7- Figueiredo CRLV, Amaral RR, Pinho MMS, Freitas JSA, Rolin MLM, Souza LB. Estudo epidemiológico de tumores benignos e malignos de glândula salivar-análise de 196 casos em Natal(RN) Rev ABO Nac. 2001;8:343-8.
- 8- Jaeger MM., Araujo VC, Kachar B, Jaeger RG Effect of spatial arrangement of basement membrane on cultured pleomorphic adenoma cells. Study by immunocytochemistry and electron and confocal microscopy. Virchows Arch.1997;430: 467-77.

9- Lam RM. An electromicroscopic histochemical study of mature salivary gland pleomorphic adenoma. Ultrastruct Pathol. 1985;8:207-23.

10- Loyola AM, Araujo VC, Sousa SOM, Araujo NS Minor salivary gland tumours. A retrospective study of 164 cases in Brazilian population. Oral Oncol Eur J Cancer. 1995;31b:197-201.

11- Luo M, Takagi H, Tsubone M, Ando C, Ogata K, Sherestha P et al. Fibronectin expresión in salivary gland pleomorphic adenoma Arch Anat Cytol Path. 1993;41:68-74.

12- Nakamura Y, Yamamoto M, Sakamoto K, Otha K, Umeda A, Tsukamotom T et al. Growth factors, extracellular matrix components and cell adhesion molecules in Warthin's tumor. J Oral Pathol Med. 2001;30:290-5.

13- Neville BW, Damm DD, Allen CM, Bouquot JE Oral and Maxillofacial Pathology. Philidelphia: W.B. Saunders; 2002.

14- Raitz R, Martins MD, Araújo VC. A study of the extracellular matrix in salivary gland tumors. J Oral Pathol Med. 2003;32:290-6.

15- Sheresta P, Sumitomo S, Ogata K, Yamada K, Takai Y, Yang L et al. Immunoreactive tenascin in tumours of salivary glands: evidence for enhanced expression in tumours stroma and production by tumour cells. Oral Oncol Eur J Cancer. 1994;30B:393-9.

16- Soini Y, Paakko P, Virtanen I, Veli-Pekka L. Tenascin in salivary gland tumours. Virch Arch Pathol Anat Histopathol. 1992;421:217-22.

17- Sunardhi-Widyaputra S, Van Damme B. Immunohistochemical expression of tenascin in normal human salivary glands and in pleomorphic adenomas Path Res Pract. 1993;189:138-43.