

Is combined therapy more effective than growth hormone or hyperbaric oxygen alone in the healing of left ischemic and non-ischemic colonic anastomoses?

Mine Adas,^I Ozgur Kemik,^{II} Gokhan Adas,^{III} Soykan Arikan,^{IV} Leyla Kuntsal,^V Yersu Kapran,^{VI} Akin Savas Toklu^{VII}

^IOkmeydani Education and Research Hospital, Department of Endocrinology, Istanbul, Turkey. ^{II}Yuzuncu Yil University Medical Faculty, General Surgery, Van, Turkey. ^{III}Bakirkoy Sadi Konuk Training and Research Hospital, Department of Surgery, Istanbul, Turkey. ^{IV}Istanbul Training and Research Hospital, Surgical Department, Istanbul, Turkey. ^VIstanbul University, Istanbul Faculty of Medicine, Department of Histopathology, Istanbul, Turkey. ^{VI}Istanbul University, Istanbul Faculty of Medicine, Department of Pathology, Istanbul, Turkey. ^{VII}Istanbul University, Istanbul Faculty of Medicine, Department of Underwater and Hyperbaric Medicine, Istanbul, Turkey.

OBJECTIVE: Our aim was to investigate the effects of growth hormone (GH), hyperbaric oxygen and combined therapy on normal and ischemic colonic anastomoses in rats.

METHODS: Eighty male Wistar rats were divided into eight groups (n=10). In the first four groups, non-ischemic colonic anastomosis was performed, whereas in the remaining four groups, ischemic colonic anastomosis was performed. In groups 5, 6, 7, and 8, colonic ischemia was established by ligating 2 cm of the mesocolon on either side of the anastomosis. The control groups (1 and 5) received no treatment. Hyperbaric oxygen therapy was initiated immediately after surgery and continued for 4 days in groups 3 and 4. Groups 2 and 6 received recombinant human growth hormone, whereas groups 4 and 8 received GH and hyperbaric oxygen treatment. Relaparotomy was performed on postoperative day 4, and a perianastomotic colon segment 2 cm in length was excised for the detection of biochemical and mechanical parameters of anastomotic healing and histopathological evaluation.

RESULTS: Combined treatment with hyperbaric oxygen and GH increased the mean bursting pressure values in all of the groups, and a statistically significant increase was noted in the ischemic groups compared to the controls ($p < 0.05$). This improvement was more evident in the ischemic and normal groups treated with combined therapy. In addition, a histopathological evaluation of anastomotic neovascularization and collagen deposition showed significant differences among the groups.

CONCLUSIONS: Combined treatment with recombinant human growth hormone and hyperbaric oxygen resulted in a favorable therapeutic effect on the healing of ischemic colonic anastomoses.

KEYWORDS: Colonic Anastomoses; Recombinant Human Growth Hormone; Hyperbaric Oxygen Treatment.

Adas M, Kemik O, Adas G, Arikan S, Kuntsal L, Kapran Y, et al. Is combined therapy more effective than growth hormone or hyperbaric oxygen alone in the healing of left ischemic and non-ischemic colonic anastomoses? *Clinics*. 2013;68(11):1440-1445.

Received for publication on February 17, 2013; First review completed on April 12, 2013; Accepted for publication on May 27, 2013

E-mail: ozgurkemik@hotmail.com

Tel.: 90 5055566969

INTRODUCTION

Currently, operations on the gastrointestinal tract are among the most frequently performed surgical procedures (1). As a major surgical problem following colorectal

surgery, anastomotic dehiscence is a significant cause of morbidity and mortality, and the rate of clinically apparent anastomotic leakage ranges from 3.4 to 8%. In addition, at least one-third of deaths following colorectal surgery have been attributed to anastomotic leakage. The effects of growth hormone (GH) and growth factors on the healing of bowel anastomoses are currently being evaluated in attempts to identify agents that could promote the anastomotic healing process (2).

GH is released from the anterior pituitary gland in response to traumatic injury, burn trauma, surgical operations, infectious disease, and the administration of endotoxins. GH administration produces a positive nitrogen balance

Copyright © 2013 **CLINICS** – This is an Open Access article distributed under the terms of the Creative Commons Attribution Non-Commercial License (<http://creativecommons.org/licenses/by-nc/3.0/>) which permits unrestricted non-commercial use, distribution, and reproduction in any medium, provided the original work is properly cited.

No potential conflict of interest was reported.

DOI: 10.6061/clinics/2013(11)10



at all levels of energy intake (3–6), and previous studies in rats have shown that human GH accelerates wound healing and strengthens colonic anastomoses (7).

In gastrointestinal surgery, many instances of leakage or dehiscence in clinical situations (tension sutures and excessive devascularization of the ends) involve hypoperfusion of the anastomoses. If the degree of hypoxia is sufficiently severe to interfere with tissue viability, the tissue can become necrosed, delaying wound healing (8,9). Because ischemic wounds heal poorly and become infected easily, preventing or reducing ischemic damage is one goal of such surgical procedures. Tissue hypoxia can be reversed through the use of hyperbaric oxygen (HBO), and the beneficial effects of HBO result from increased pressure and hyperoxia. Several studies have shown that increased oxygen tension with HBO not only prevents the adverse effects of ischemia, but it also accelerates healing in different types of wounds (9).

Our aim in the present work was to investigate in rats the roles of GH, HBO, and combined therapy in the early phase of wound healing of left ischemic and non-ischemic colonic anastomoses, by assessing bursting strength and histopathology.

■ MATERIALS AND METHODS

Animals

Eighty male Wistar rats weighing 250–300 g (Istanbul University, Institute of Experimental Medicine and Research, Turkey) were used in this study. All of the animals were housed in wire mesh-bottomed cages on a 12-hour light/dark cycle. The rats were kept in a room at a constant temperature ($22 \pm 2^\circ\text{C}$) and were fed a standard chow diet and water. The study was approved by the ethics committee of the Istanbul Medical School of Istanbul University.

Study design

The rats were divided into eight groups ($n=10$). In the first four groups, non-ischemic colonic anastomosis was performed. In the remaining four groups, ischemic colonic anastomosis was performed.

Group 1: control; normal left colonic anastomoses

Group 2: normal left colonic anastomoses + hGH

Group 3: normal left colonic anastomoses + HBO therapy

Group 4: normal left colonic anastomoses + hGH + HBO therapy

Group 5: control; ischemic left colonic anastomoses

Group 6: ischemic left colonic anastomoses + hGH

Group 7: ischemic left colonic anastomoses + HBO therapy

Group 8: ischemic left colonic anastomosis + hGH + HBO therapy

Surgical procedure

After one night of fasting, the animals were anaesthetized by an intramuscular injection of ketamine hydrochloride (50–100 mg per kg of body weight). Abdominal access was achieved through a midline incision 4 cm long, and the left colon was diverted 3 cm proximally to the peritoneal reflection. After the fecal contents were milked out, a standardized end-to-end anastomosis was created, consisting of eight interrupted, inverting sutures of 6–0 polypropylene. Care was taken to preserve the marginal vessels

of the colon. To establish ischemic colon anastomosis in groups 5–8, entire vessels were ligated in the mesocolon between 2 cm proximal and 2 cm distal from the anastomosis line (8–12). After bleeding was controlled, 2 ccs of 0.9% NaCl were injected intraperitoneally, and the abdomen was closed with 3–0 continuous silk sutures. Water and food were given 12 and 24 hours after the procedure, respectively.

Treatment

HBOT was initiated 3 hours after the surgery and was performed four times for the first 24 hours and then three times per day for the following 3 days. The total number of HBOT sessions was 13. The treatments were conducted in a small research chamber (0.4 m^3), which was flushed with oxygen for 10 minutes to vent the air inside before compression so that the animals could be pressurized with 100% oxygen. The HBOT sessions consisted of 10 minutes of compression to 2.5 absolute atmospheres (ata), 60 minutes at 2.5 ata, and 10 minutes of decompression to the surface pressure.

In groups 2, 4, 6, and 8, the rats were administered hGH (Norditropin 4 IU-1.3 mg, Novo Nordisk-Denmark) subcutaneously at a dose of 2 mg per kilogram of actual body weight per day for 4 days, beginning on the day of surgery (13–16). All of the animals were euthanized 4 days after surgery.

Measurement of colonic bursting pressure

Four days after the procedure, the rats were sacrificed. The abdominal incisions were reopened, and the anastomotic suture lines were noted. The anastomotic segment was resected, preserving the adhesions 2 cm proximal and 2 cm distal to the anastomotic line. The bursting pressure was measured in situ, without detaching the adhesions. The bursting pressure of the anastomotic segment was measured with a mercury manometer and a constant flow pump. Briefly, a 16-gauge silastic catheter was inserted via a colotomy into the proximal colon and was ligated with a 2–0 silk tie. The rectum distal to the anastomosis was ligated with a 2–0 silk tie and was continuously infused through the catheter via a tube pump at a rate of 4 ml/minute. The bursting pressure was recorded (mm Hg) as the peak pressure attained before rupture of the anastomosis, which resulted in an abrupt drop in pressure.

Histological assessment

After bursting, the colon was excised, cleared of surrounding mesentery and fat, and washed with saline. The anastomosis was excised together with 1 cm of the adjacent proximal and distal colon. The segment of bowel was opened longitudinally, was fixed in 10% formalin for approximately 24 hours and was embedded in paraffin. Transverse sections of the embedded tissue 3 μm in thickness were stained with hematoxylin and eosin, and histological assessments were performed by experimenters who were blinded to group identity. Necrosis, epithelialization, inflammation, granulation, collagen deposition, and neovascularization at the anastomotic site were studied and were scored on a scale from 0 to 3 (0: none, 1: slight, 2: moderate, 3: dense).

Electron microscopy techniques

After measuring the bursting pressures, one sample line, $0.5 \times 0.5 \text{ cm}$ in size, from each group was prepared on the



suture. Tissues were fixed in a 2.5% phosphate-buffered glutaraldehyde solution for ultrastructural examination and then were post-fixed in 1% OsO4 for 1 hour. The samples were dehydrated in a graded series of alcohol and were embedded in Epon 812 (Fluka AG, Germany). The blocks were then sectioned with an LKB Ultramicrotome (Stockholm-Sweden). Ultra-thin sections were concentrated with lead citrate and uranyl-acetate and were examined under an electron microscope (Jeol 1011, Tokyo) in the Department of Histopathology, Istanbul Faculty of Medicine.

Statistical analysis

All of the data are expressed as the means ± SDs. The Kruskal-Wallis test and an ANOVA were used for the statistical analysis, and *p*<0.05 was accepted as significant (SPSS, version 11.0 for Windows).

RESULTS

In this study, we investigated two main parameters of wound healing in left ischemic and non-ischemic colonic anastomoses. Bursting pressure measurements provided information on the mechanical strength of the anastomosis, and histopathology was performed to assess the early phases of wound healing in the colonic anastomoses. All of the animals tolerated the surgery well, and there were no deaths during the study.

Bursting pressure assessment

The mean bursting pressures of non-ischemic colonic anastomoses (groups 2, 3, and 4) were higher than those of the control group. Bursting pressures in the untreated control group (group 1) were significantly lower than those in the hGH + HBO group (group 4), which received non-ischemic colonic anastomoses (*p*<0.05 and *p*<0.05, respectively). These results are presented in Table 1. Comparisons between the bursting pressure values of the sixth, seventh, and eighth groups and those of the control group (group 5) revealed that all three groups were significantly different from the control group (*p*<0.01, Table 2).

Table 1 - Bursting pressures in the non-ischemic groups. All of the values are expressed as the means ± SDs; SD: standard deviation. The *p*-value compares group 1 (control) to the other groups.

Bursting Pressure mmHg	Group 1 (control)	Group 2 (hGH)	Group 3 (HBOT)	Group 4 (HBOT+hGH)
Min (mm Hg)	58	64	70	52
Max (mm Hg)	140	150	140	128
Average (mm Hg)	81.4	94.5	93.3	97.3
Percentage increased		11.9%	10.5%	12.9%
SD	20.17	21.34	20.48	19.9
<i>p</i> -value		<i>p</i> <0.05	<i>p</i> <0.05	<i>p</i> <0.05

Table 2 - Bursting pressures in the ischemic groups. All of the values are expressed as the means ± SDs; SD: standard deviation. The *p*-value compares group 1 (control) to the other groups.

Bursting Pressure mmHg	Group 5 (control)	Group 6 (hGH)	Group 7 (HBOT)	Group 8 (hGH+HBOT)
Min (mm Hg)	24	40	56	50
Max (mm Hg)	104	138	150	140
Average (mm Hg)	62	89.3	109.9	96.5
Percentage increased		44%	77%	56%
SD	21.19	24.32	25.30	28.92
<i>p</i> -value		<i>p</i> = 0.01	<i>p</i> = 0.01	<i>p</i> = 0.01

Histological assessment

At necropsy, all of the anastomoses were covered with either omentum or small bowel loops, and they lacked any evidence of leakage or peritonitis. Upon investigating the early period of wound healing, groups 3–4 showed lower levels of tissue necrosis (0.3) than the non-ischemic groups (*p*<0.05). When tissue collagen levels were compared among the groups, groups 3–4 differed significantly from the control group (*p*<0.01) (Figure 1). In addition, the second and third groups did not differ significantly from the controls in terms of the level of tissue granulation (*p*>0.05), although significant differences were detected when the levels of the fourth group were compared to those of second and third groups (*p*<0.01). In addition, neovascularization was also compared, and we found statistically significant differences between group 4 and the other groups (*p*<0.05). These results are presented in Table 3.

In the ischemic groups, the necrosis observed in groups 7 and 8 differed significantly from that in the control group (group 5) (*p*<0.05). In contrast, the levels of epithelialization and inflammation did not differ significantly among the groups (*p*>0.05). We also investigated tissue collagen and neovascularization, and we detected significant differences between groups 7 and 8 and the control group (*p*<0.05) (Figure 2). Moreover, significant differences were observed between the eighth group and the sixth and seventh groups (*p*<0.05). These results are presented in Table 4.

Electron microscopy

Greater collagen deposition was observed between cells present in the connective tissue from groups 4 and 8 and those in the control groups. The electron microscopy results are presented in Figures 1 and 2.

DISCUSSION

Injury triggers an organized and complex cascade of cellular and biochemical events that result in wound healing. Anastomotic healing in the gastrointestinal tract differs from the healing of other injuries in that a controlled, full-thickness injury of limited duration is created. This full-thickness injury elicits a fibrotic response, in which

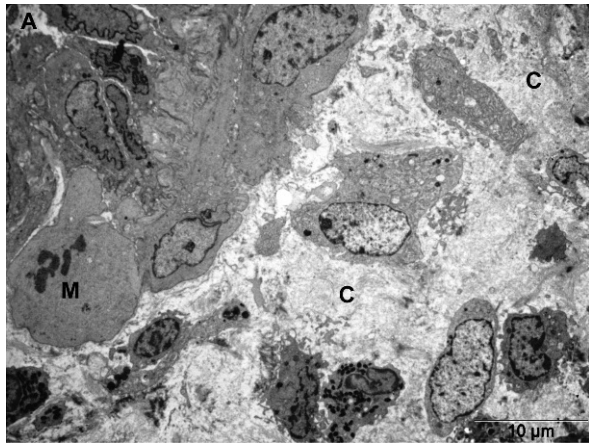


Figure 1 - Dense collagen deposition (c) is shown in the anastomotic area. M: mitosis and new vessel in group 4.

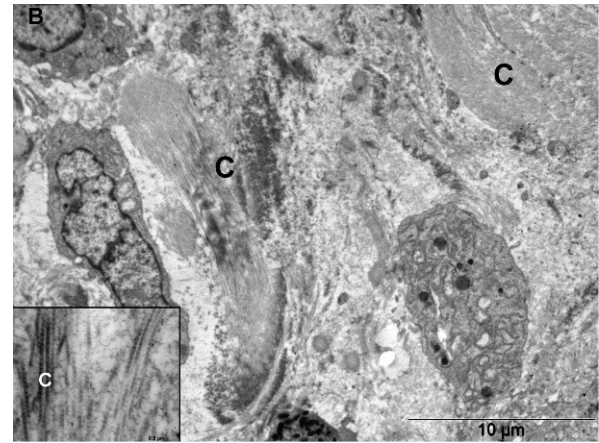


Figure 2 - Dense and bunch collagen in group 8.

inflammation, proliferation, and connective tissue deposition all contribute to generating a fibrotic scar at the site of repair (15–18). Failure of healing results in dehiscence, leaks, and fistulas, which carry significant risks of morbidity and mortality (19–22).

Major surgery is characterized by a hypermetabolic state, accompanied by increased oxygen consumption, a negative nitrogen balance, and a loss of body weight (3,6,16). In addition, catabolism and protein depletion inhibit normal wound healing, and recombinant GH has shown promise as an anabolic treatment in post-operative and burn therapy by increasing protein synthesis and attenuating protein catabolism. Furthermore, systemic GH treatment stimulates granular tissue formation and increases collagen deposition and incisional breaking strength (23). The anabolic effects of hGH have received increasing interest during the early postoperative period, when the strength of an anastomosis is lowest (24). The beneficial effects of hGH on colonic anastomosis and skin wound healing have also been previously demonstrated (17). In elective colorectal surgery, 9 days of perioperative hGH injections (4 and 8 U/day = 1.3 and 2.6 mg/day) improved nitrogen balances and lean body mass, even when patients received low-calorie diets; however, this treatment was associated with an average retention of 4 liters of fluid (6). In addition, in patients with sepsis, 7 days of hGH treatment improved net protein synthesis (6), and 5 days of hGH treatment was shown to stimulate muscle protein synthesis and increase glutamine stores in critically ill patients (24). GH also has direct wound healing effects, and the skin is a target tissue for hGH, both directly through hGH receptors on the surface of epidermal cells and indirectly through the action of IGH-1 (25). In the gastrointestinal tracts of normal rats, hGH administration

stimulates mucosal growth, and a previous study by Tei and Christensen showed that GH treatment increased transmural colonic growth in rats (25). Silver also demonstrated that GH increased the breaking strength of colonic anastomoses and stimulated the collagen deposition rate of the anastomotic segment, while having no effects on hydroxyproline concentrations; in addition, this author later reported that GH caused a significant increase in the connective tissue thickness of bowel anastomoses (26).

The results of the present study demonstrated that systemic administration of GH and HBO (groups 4–8) significantly accelerated two parameters of healing in left-sided colonic anastomoses. We observed angiogenesis in the fourth and eighth groups, which were administered hGH, and the angiogenesis rates differed significantly between these groups and the control group ($p < 0.01$). Another finding in our study was that bursting pressure was increased in all of the treatment groups that received non-ischemic and ischemic colonic anastomoses. In addition, when we evaluated the groups as ischemic or non-ischemic, two situations were observed. First, the bursting pressure in both groups was statistically different compared to the control groups (groups 1 and 5). Second, no statistical comparisons were made between the treatment groups, as this parameter fell outside of the research parameters and was not of interest in our study. Our sole aim was to determine whether GH and HBOT would exert positive effects on the healing process relative to the control groups (groups 1 and 5). The mean bursting pressure in group 7 was measured as 110 mm Hg, which was the highest mean value observed among all of the groups. Generally, we observed that groups 7 and 8, which were classified as ischemic and which received HBOT, demonstrated more strict adhesions in the anastomotic areas, and this finding

Table 3 - Histological assessments in the non-ischemic groups (all parameters scored from 0 to 3). The p -value compares group 1 to the other groups.

Histological Assessment	Necrosis	Epithelialization	Inflammation	Granulation	Collagen Deposition	Neovascularization
Group 1 (control)	0.7	0.3	2.3	1	0.5	0.8
Group 2 (hGH)	0.6 ($p > 0.05$)	0.3 ($p > 0.05$)	2.4 ($p > 0.05$)	1.5 ($p > 0.05$)	0.7 ($p > 0.05$)	1.9 ($p < 0.01$)
Group 3 (HBO)	0.3 ($p > 0.05$)	0.3 ($p > 0.05$)	2.2 ($p > 0.05$)	1.5 ($p > 0.05$)	1.1 ($p < 0.01$)	1.9 ($p < 0.01$)
Group 4 (hGH+HBO)	0.6 ($p > 0.05$)	0.2 ($p > 0.05$)	1.9 ($p > 0.05$)	2.6 ($p < 0.01$)	2.7 ($p < 0.01$)	2.4 ($p < 0.01$)



Table 4 - Histological assessment in the non-ischemic groups (all parameters scored from 0 to 3). The *p*-value compares group 1 to the other groups. All of the values are expressed as the means ± SDs.

Histological Assessment	Necrosis	Epithelialization	Inflammation	Granulation	Collagen Deposition	Neovascularization
Group 5 (control)	2.6	0.2	2.8	0.5	0.2	0.3
Group 6 (hGH)	1.5 (<i>p</i> >0.01)	0.8 (<i>p</i> <0.05)	2.7 (<i>p</i> >0.05)	1 (<i>p</i> <0.05)	0.7 (<i>p</i> <0.05)	1.5 (<i>p</i> <0.05)
Group 7 (HBOT)	1.4 (<i>p</i> <0.01)	0.5 (<i>p</i> <0.05)	2.4 (<i>p</i> >0.05)	1.2 (<i>p</i> <0.05)	0.8 (<i>p</i> <0.05)	1.5 (<i>p</i> <0.05)
Group 8 (hGH+HBOT)	1.3 (<i>p</i> <0.01)	1.2 (<i>p</i> <0.05)	2.9 (<i>p</i> >0.05)	2.8 (<i>p</i> <0.01)	1.6 (<i>p</i> <0.01)	1.7 (<i>p</i> <0.05)

could be one explanation for the higher bursting pressures observed in the ischemic treatment groups. However, this possibility was not examined because it was beyond the parameters of the study.

Wound healing in the gastrointestinal system involves processes related to hemostasis/inflammation, proliferation/fibroplasia, and maturation/remodeling, and delays or problems during any of these stages can delay healing (27). Numerous local and systemic factors have been shown to affect anastomotic healing, and the most important local factors are the perfusion and oxygenation of the site of anastomosis. To achieve safe anastomosis, the intestinal blood flow should exceed 30%. Oxygen is an essential material for cell metabolism, and it is in especially high demand during reparative processes, such as cell proliferation and collagen synthesis. Furthermore, evidence from animal and cell line studies has shown that hyperbaric oxygen therapy increases growth factor production and accelerates wound healing (28). HBO treatment was also shown to improve distal microvascular perfusion, as measured by laser Doppler flowmetry of ischemic skin flaps in rats; this effect was observed for HBO treatment administered either during ischemia or following 8 hours of ischemia (29,30). The tensile strength of wounds, collagen deposition, and the rate at which the wound closes around a dead space are affected by the amount of available oxygen. Fibroblasts cannot synthesize collagen without a reasonable amount of oxygen, but the presence of molecular oxygen is critical for the post-translational hydroxylation of prolyl and lysyl residues, which are required for triple helix formation and the cross-linking of collagen fibrils (29–32). Fibroblasts are the primary producers of collagen in the repair response, and hypoxia affects fibroblasts by decreasing IGF-1 production, increasing TGF-β production, and increasing procollagen mRNA levels. Numerous studies have shown, however, that wound collagen deposition is greatly increased in well-oxygenated wounds (33,34). The administration of HBO therapy in wound healing increases the production of growth factors, such as platelet-related growth factor, transforming growth factor-β1, and vascular endothelial growth factor (29). Therefore, HBO has been administered preoperatively to patients with inadequately vascularized recipient sites, to stimulate sufficient angiogenesis and to support skin grafts. The mechanism by which HBO exerts its effect centers on increasing the oxygen gradient between the underlying blood vessels and the recipient site, thereby stimulating vessel proliferation (34–38).

In light of these data in the literature, an important focus of discussion and consequently the basis of our study regard whether the synergistic effects of combined HBO and GH therapy are applicable in colonic anastomosis. In this study, we showed that combined HBO and GH therapy

significantly accelerated parameters of healing in left-sided ischemic colonic anastomoses.

In summary, the use of GH, HBO, and the combination of these two treatments positively affected early wound healing by increasing granulation, collagen deposition, and neovascularization. Therefore, HBO, together with the use of GH to enhance the healing of anastomosis, could be adopted in clinical practice. Although our findings warrant further clinical investigation, this study might have clinical relevance for patients with ischemic and non-ischemic colonic anastomoses.

AUTHOR CONTRIBUTIONS

Adas M and Adas G conceived the study and participated in its design and organization. Kemik O, Adas G and Arikian S designed and executed the experimental study, especially the surgical procedures. Adas M, Ozgur K and Adas G collected the data and participated in its analysis and interpretation; drafted and revised the article critically for important intellectual content; and approved the final manuscript. Kuntsal L and Kapran Y performed the evaluation and scoring of the histological assessments. Toklu AS executed the HBOT.

REFERENCES

- Thorton FS, Barbal A. Healing in the gastrointestinal tract. *Surg Clin of North Am.* 1997;77(3):549-73, [http://dx.doi.org/10.1016/S0039-6109\(05\)70568-5](http://dx.doi.org/10.1016/S0039-6109(05)70568-5).
- Egger B, Inglin R, Zeek J, Dirsch O, Huang Y, Büchler WM. Insulin like growth factor I and truncated keratinocyte growth factor accelerate healing of left sided colonic anastomoses. *Brit J of Surg.* 2001;88(1):90-8, <http://dx.doi.org/10.1046/j.1365-2168.2001.01617.x>.
- Brunicaudi FC. Systemic response to injury and metabolic support in: Edward L, Schwartz's Principles of Surgery, eighth ed, McGraw-Hill Co, Newyork, 2005, p:3-42.
- Townsend CM. The pituitary and adrenal glands in: Brunt LM, Sabiston Text of Surgery, 17th ed, Elsevier Saunders Co, Philadelphia, 2004, p:1023-70.
- Bengtsson BA, Monson JP. Future directions of growth hormone research in: John MP, GH Replacement in Adults, Oxford PharmaGenesis Ltd, London, 2000, p:202-8.
- Abs R, Rasmussen UF. The catabolic syndrome of prolonged critical illness in: Weekers F, Growth Hormone Deficiency in Adults, Oxford PharmaGenesis Ltd, Oxford, 2004, p:299-13.
- Karahasanoglu T, Altinli E, Hamzaoglu I, Paksoy M, Yesildere T, Alemdaroglu K. Effects of growth hormone treatment on the healing of left colonic anastomoses in protein malnourished rats. *Brit J of Surg.* 1998;85(7):931-3, <http://dx.doi.org/10.1046/j.1365-2168.1998.00696.x>.
- Garcia JG, Criado G. Healing of colonic ischemic anastomoses in the rat: role of superoxide radicals. *Dis Colon Rectum.* 1998;41(7):892-5, <http://dx.doi.org/10.1007/BF02235374>.
- Hamzaoglu I, Karahasanoglu T, Aydın S, Dursun AS, Carkman S, Sariyar M, et al. The effects of hyperbaric oxygen on normal and ischemic colon anastomoses. *Am J Surg.* 1998;76(5):458-61.
- Adas G, Percem A, Adas M, Kemik O, Arikian S, Ustek D, et al. VEGF-A and FGF gene therapy accelerate healing of ischemic colonic anastomoses (experimental study). *Int J Surg.* 2011;9(6):467-71.
- Adas G, Arikian S, Karatepe O, Kemik O, Ayhan S, Karaoz E, et al. Mesenchymal stem cells improve the healing of ischemic colonic anastomoses (experimental study). *Langenbecks Arch Surg.* 2011;396(1):115-26, <http://dx.doi.org/10.1007/s00423-010-0717-z>.
- Yarimkaya A, Apaydin B, Unal E, Karabacak I, Aydogan F, Uslu E, et al. Effects of recombinant human growth hormone and nandrolone phenylpropionate on the healing of ischemic colon anastomosis in rats. *Dis Colon Rectum.* 2003;46(12):1690-7, <http://dx.doi.org/10.1007/BF02660777>.



13. Caglikulekci M, Ozcay N, Orug T, Aydog G, Renda N, Atalay F. The effect of recombinant growth hormone on intestinal anastomotic wound healing in rats with obstructive jaundice. *Turk J Gastroenterol.* 2002;13(1):17-23.
14. Seyer-Hansen M, Andreassen TT, Christensen H, Oxlund H. Effect of experimental diabetes and growth hormone administration on the strength of colonic anastomoses in rats. *Eur Surg Res.* 1999;31(5):419-28, <http://dx.doi.org/10.1159/000008721>.
15. Christensen H, Chemnitz J, Christensen BC, Oxlund H. Collagen structural organization of healing colonic anastomoses and the effect of growth hormone treatment. *Dis. Colon Rectum.* 1995;38(11):1200-5, <http://dx.doi.org/10.1007/BF02048337>.
16. Christensen H, Oxlund H. Growth hormone increases the collagen deposition rate and breaking strength of left colonic anastomoses in rats. *Surgery.* 1994;116(3):550-6.
17. Ozcay N, Orug T, Caglikulekci M, Turhan N, Atalay F, Akoglu M. The effect of growth hormone therapy on the healing of small bowel anastomosis after reperfusion injury in the rat. *Transplant Proc.* 2002;34(3):1015-6, [http://dx.doi.org/10.1016/S0041-1345\(02\)02695-7](http://dx.doi.org/10.1016/S0041-1345(02)02695-7).
18. Mast AB. Healing in other tissues. *Surg Clin North Am.* 1997;77(3):529-47, [http://dx.doi.org/10.1016/S0039-6109\(05\)70567-3](http://dx.doi.org/10.1016/S0039-6109(05)70567-3).
19. Verhofstad HJ, Lomme ML, Hendriks MT. Intestinal anastomoses from diabetic rats contain supranormal levels of gelatinase activity. *Dis Colon Rectum.* 2002;45(4):554-61, <http://dx.doi.org/10.1007/s10350-004-6238-5>.
20. Kiyema T, Onda M, Tokunaga A, Yoshiyuki T, Barbul A. Effect of early postoperative feeding on the healing of colonic anastomoses in the presence of intra-abdominal sepsis in rats. *Dis Colon Rectum.* 2000 Oct;43(10 Suppl):S54-8, <http://dx.doi.org/10.1007/BF02237227>.
21. Syk I, Agren MS, Adawi D, Jeppsson B. Inhibition of matrix metalloproteinases enhances breaking strength of colonic anastomoses in an experimental model. *Br J Surg.* 2001;88(2):228-34.
22. Dubay DA, Franz MG. Acute wound healing: the biology of acute wound failure. *Surg Clin North Am.* 2003;83(3):463-81, [http://dx.doi.org/10.1016/S0039-6109\(02\)00196-2](http://dx.doi.org/10.1016/S0039-6109(02)00196-2).
23. Dunaiski V, Belford DA. Contribution of circulating IGF-1 to wound repair in GH-treated rats. *Growth Horm IGF Res.* 2002;12(6):381-7, [http://dx.doi.org/10.1016/S1096-6374\(02\)00080-1](http://dx.doi.org/10.1016/S1096-6374(02)00080-1).
24. Gamrin L, Essen P, Hultman E, McNurlan MA, Garlick PJ, Wernerman J. Protein-sparing effect in skeletal muscle of growth hormone treatment in critically ill patients. *Ann Surg.* 2000;231(4):577-86, <http://dx.doi.org/10.1097/0000658-200004000-00018>.
25. Tei TM, Nielsen K, Christensen H, Flyvbjerg A. Growth hormone treatment increases transmural colonic growth in GH-deficient dwarf rats. *Growth Horm IGF Res.* 2000;10(2):85-92, <http://dx.doi.org/10.1054/ghir.2000.0144>.
26. Silver DF, Simon A, Dubin NH, Wheelless CR. Recombinant growth hormone's effects on the strength and thickness of radiation injured ileal anastomosis. *J Surg Res.* 1999;85(1):66-70, <http://dx.doi.org/10.1006/jrsr.1999.5611>.
27. Chen SJ, Thung C, Cheng YL, Yu SY, Lo HC. Effects of hyperbaric oxygen therapy on circulating interleukin-8, nitric oxide, and insulin-like growth factors in patients with type 2 diabetes mellitus. *Clin Biochem.* 2007;40(1-2):30-6, <http://dx.doi.org/10.1016/j.clinbiochem.2006.07.007>.
28. Hammarlund C. The physiologic effects of hyperbaric oxygenation in: Kindwall EP, Whelan HT, *Hyperbaric Medicine Practice*, second edition, Best Publishing Company, Flagstaff 1999, p:37-65.
29. Grim PS, Gottlieb LJ, Boddie A, Batson E. Hyperbaric oxygen therapy. *JAMA* 1990;263(16):2216-20.
30. Aktas S, Toklu AS, Olgac V. Hyperbaric oxygen therapy in adriamycin extravasation: an experimental animal study. *Ann Plast Surg.* 2000;45(2):167-71, <http://dx.doi.org/10.1097/0000637-200045020-00012>.
31. Hunt TK. The physiology of wound healing. *Ann Emerg Med.* 1988;17(12):1265-73, [http://dx.doi.org/10.1016/S0196-0644\(88\)80351-2](http://dx.doi.org/10.1016/S0196-0644(88)80351-2).
32. Kang TS, Gorti GK, Quan SY, Ho M, Koch RJ. Effect of hyperbaric oxygen on the growth factor profile of fibroblasts. *Arc Facial Plast Surg* 2004;6(1):31-5, <http://dx.doi.org/10.1001/archfaci.6.1.31>.
33. Friedman HF, Fitzmaurice MD, Lefavre JF, Vecchiolla TS, Clarke D. An evidence-based appraisal of the use of hyperbaric oxygen on flaps and grafts. *Plast Reconstr Surg.* 2006;117(7 Suppl):175S-190S; discussion 191S-25.
34. Méchine A, Rohr S, Toti F, Aysoy C, Schneider F, Meyer C, et al. Wound healing with hyperbaric oxygen: Experimental study of the angiogenesis phase in the rat. *Ann Chir.* 1999;53(4):307-11.
35. Falanga V, Martin TA, Takagi H, Kirsner RS, Helfman T, Pardes J, et al. Low oxygen tension increases mRNA levels of alpha 1 procollagen in human dermal fibroblasts. *J Cell Physiol.* 1993;157(2):408-12, <http://dx.doi.org/10.1002/jcp.1041570225>.
36. Gimbel M, Hunt T. Wound healing and hyperbaric oxygenation in: Kindwall EP, Whelan HT. *Hyperbaric Medicine Practice*, second edition, Best Publishing Company, Flagstaff, 1999, p:169-204.
37. Demling RH. The role of anabolic hormones for wound healing in catabolic states. *J Burns Wounds.* 2005;4:e2.
38. Li Y, Bao Y, Jiang T, Tan L, Liu F, Li J. Combination of fibrin glue with growth hormone augments healing of incomplete intestinal anastomoses in a rat model of intra abdominal sepsis: a dynamic study. *J Invest Surg.* 2007;20(5):301-6, <http://dx.doi.org/10.1080/08941930701598826>.