

CLINICAL SCIENCE

Pleural tuberculosis: is radiological evidence of pulmonary-associated disease related to the exacerbation of the inflammatory response?

Leila Antonangelo,^{I,II} Francisco S. Vargas,^I Juliana Puka,^I Márcia Seiscento,^I Milena M. P. Acencio,^I Lisete R. Teixeira,^I Ricardo M. Terra,^{III} Roberta K. B. Sales^I

^IHospital das Clínicas da Faculdade de Medicina da Universidade de São Paulo, Heart Institute (InCor), Pulmonary Division, Pleural Laboratory, São Paulo/SP, Brazil. ^{II}Hospital das Clínicas da Faculdade de Medicina da Universidade de São Paulo, Department of Pathology, Clinical Laboratory and LIM III, São Paulo/SP, Brazil. ^{III}Hospital das Clínicas da Faculdade de Medicina da Universidade de São Paulo, Heart Institute (InCor), Thoracic Surgery Division, São Paulo/SP, Brazil.

OBJECTIVE: Pleural tuberculosis is the most frequently occurring form of extra pulmonary disease in adults. In up to 40% of cases, the lung parenchyma is concomitantly involved, which can have an epidemiological impact. This study aims to evaluate the pleural and systemic inflammatory response of patients with pleural or pleuropulmonary tuberculosis.

METHODS: A prospective study of 39 patients with confirmed pleural tuberculosis. After thoracentesis, a high resolution chest tomography was performed to evaluate the pulmonary involvement. Of the 39 patients, 20 exhibited only pleural effusion, and high resolution chest tomography revealed active associated-pulmonary disease in 19 patients. The total protein, lactic dehydrogenase, adenosine deaminase, vascular endothelial growth factor, interleukin-8, tumor necrosis factor- α , and transforming growth factor- β_1 levels were quantified in the patient serum and pleural fluid.

RESULTS: All of the effusions were exudates with high levels of adenosine deaminase. The levels of vascular endothelial growth factor and transforming growth factor- β_1 were increased in the blood and pleural fluid of all of the patients with pleural tuberculosis, with no differences between the two forms of tuberculosis. The tumor necrosis factor- α levels were significantly higher in the pleural fluid of the patients with the pleuropulmonary form of tuberculosis. The interleukin-8 levels were high in the pleural fluid of all of the patients, without any differences between the forms of tuberculosis.

CONCLUSION: Tumor necrosis factor- α was the single cytokine that significantly increased in the pleural fluid of the patients with pulmonary involvement. However, an overlap in the results does not permit us to suggest that cytokine is a biological marker of concomitant parenchymal involvement. Although high resolution chest tomography can be useful in identifying these patients, the investigation of fast acid bacilli and cultures for *M. tuberculosis* in the sputum is recommended for all patients who are diagnosed with pleural tuberculosis.

KEYWORDS: Cytokines; Inflammation; Pleural Diseases; Tuberculosis.

Antonangelo L, Vargas FS, Puka J, Seiscento M, Acencio MM, Teixeira LR, Terra RM, Sales RK. Pleural tuberculosis: is radiological evidence of pulmonary-associated disease related to the exacerbation of the inflammatory response? *Clinics*. 2012;67(11):1259-1263.

Received for publication on April 25, 2012; First review completed on May 13, 2012; Accepted for publication on July 12, 2012

E-mail: roberta.sales@uol.com.br

Tel.: 55 11 2661-5695

INTRODUCTION

Pleural tuberculosis is the most common extra pulmonary form of tuberculosis in adults, particularly in countries where the prevalence of the disease is high or moderate (1-3). Although pulmonary tuberculosis can be a manifestation of primary infection, it is most commonly associated with the reactivation of pre-existing foci (1,2,4). It is generally

accepted that pleural tuberculosis results from a late hypersensitive reaction to the antigens of *M. tuberculosis* subsequent to the rupture of a subpleural caseous focus (1,2,4). The release of even a small number of bacilli from the lungs to the pleural space triggers a series of immune reactions that are mediated by T lymphocytes, which produce cytokines and stimulate macrophages to form a granuloma (4-7). These events trigger an inflammatory process in the pleural cavity: vascular permeability increases and an influx of leukocytes enter the pleural space, resulting in the accumulation of fluid and cells, which is a characteristic of the pleural exudates (1,2,6).

Cytokines are a group of polypeptides with multiple biological functions that act with other inflammatory mediators to coordinate the interaction between sensitized

Copyright © 2012 **CLINICS** – This is an Open Access article distributed under the terms of the Creative Commons Attribution Non-Commercial License (<http://creativecommons.org/licenses/by-nc/3.0/>) which permits unrestricted non-commercial use, distribution, and reproduction in any medium, provided the original work is properly cited.

No potential conflict of interest was reported.

lymphocytes and macrophages to form granulomas (5-11). Among the involved mediators, we highlight the importance of interleukin-8 (IL-8) (8-15), vascular endothelium growth factor (VEGF) (8,9,16-18), tumor necrosis factor- α (TNF- α) (8,9,11,17-20), and transforming growth factor- β_1 (TGF- β_1) (7,9,20,21), all of which are considered to be key effectors in the inflammatory response of the pleural space (4-6).

Although pleural and pulmonary lesions were previously considered to be independent events, the advent of computed tomography has demonstrated concomitant lesions in more than 40% of cases (1,21-24). This concomitance may have an epidemiological impact, given that many patients with pleural tuberculosis are not adequately evaluated for intrathoracic involvement. This finding enables us to speculate whether serum or pleural fluid inflammatory markers in pleural tuberculosis could suggest associated active pulmonary disease. The answer to this question is particularly relevant if we consider the potential risk of *Mycobacterium tuberculosis* transmission from these patients to contacts.

Therefore, this study compares the serum and pleural fluid expression of inflammatory mediators in pleural tuberculosis patients to evaluate whether pulmonary-associated involvement influences the magnitude of the inflammatory response. We hypothesized that the more extensive the injury, the greater the inflammatory response. If this hypothesis is true, the inflammatory cytokines could be increased both locally (pleural fluid) and in the serum as a result of the pulmonary involvement.

METHODS

After approval by the local ethics committee, informed consent was obtained from 39 pleural tuberculosis patients. The patients were prospectively selected from the outpatient clinic of Pulmonary Diseases (InCor/FMUSP), São Paulo, Brazil.

The diagnosis of pleural tuberculosis was based on the presence of a granuloma (upon pleural biopsy) associated with exudative effusion with increased adenosine deaminase (ADA > 40 IU/L) and/or a culture of the pleural fluid or fragment positive for *Mycobacterium tuberculosis* (1,2,25). After thoracentesis, the patients underwent high resolution chest tomography (HRCT) and were subdivided into two groups based on the HRCT findings: pleuropulmonary (n=19) or only pleural involvement (n=20). The tomographic abnormalities that were suggestive of active pulmonary disease included the following: multi-segmental consolidation over the upper lung zones (homogenous opacity that reflected granulomatous inflammation of the parenchyma), thick-walled cavities (resulting from the coalescence of multiple inflammatory foci that necrotized and drained into the airways), centrilobular or confluent nodules, and the presence of the tree-in-bud pattern, which reflects the endobronchial dissemination of caseous necrosis and the granulomatous inflammation that fills and surrounds the alveolar ducts and respiratory bronchioli. Patients who had nonspecific tomographic findings or images of residual scarring were not included in this series (23-25). HIV patients, patients previously treated for tuberculosis, and patients undergoing immunosuppressant therapy were also excluded.

Concomitant with thoracentesis, all of the patients underwent peripheral venous puncture and tuberculin skin tests. Pleural fluid samples were processed for cytology,

bacilloscopy, *M. tuberculosis* cultures, and to determine the adenosine deaminase levels (Giusti modified method) (26). Proteins (Biuret method) and lactic dehydrogenase (enzymatic method) were also quantified in the blood and pleural fluid. Aliquots from both samples (serum and pleural fluid) were immediately centrifuged (1,500 rpm for 10 minutes at 4°C), and the supernatant was stored at -80°C for posterior cytokine analyses.

VEGF, IL-8, TNF- α , and TGF- β_1 were quantified using an immunoenzymatic method (enzyme-linked immunosorbent assay, ELISA) according to the manufacturer's instructions (R&D Systems Inc., Minneapolis, USA). The assays were performed in triplicate, and the results are expressed as means. The results were quantified by comparing the optic density (450 nm filter) in the ELISA reader (Powerwave, Biotek, USA) against a pre-established standard curve. The minimal detection values for IL-8, VEGF, and TGF- β_1 were 31 pg/mL, and the minimum detection value for TNF- α was 16 pg/mL. To evaluate the pleural inflammatory response, the results were compared with those obtained from the serum and pleural fluid of the patients with transudates that were caused by heart failure (27).

Statistical analysis

The results of the inflammatory marker analysis were compared using Student's T-test or the Mann Whitney U-test according to the distribution of the variables. The SigmaStat 3.5 (SSI 2006, California, USA) program was used for the statistical analyses, and the results are presented as medians (IQ 25th - 75th); $p \leq 0.05$ was considered to be statistically significant.

RESULTS

Thirty-nine patients (35 ± 15 years) presented with pleural effusions caused by tuberculosis, and 19 patients exhibited concomitant parenchyma involvement. In the patients with pleural effusion (n=20), the detection of fast acid bacilli in the sputum was negative. In the pleuropulmonary group (n=19), three patients exhibited positive fast acid bacilli in sputum. In two patients in the pleural group and six patients in the pleuropulmonary group, the response to the skin test exhibited indurations that were greater than 5 mm. Thus, the microbiological detection and the skin test contributed little toward diagnosing active pulmonary tuberculosis. The patients were not submitted to bronchoalveolar lavage because they had previously been diagnosed with pleural tuberculosis.

The HRCT findings that were considered to be suggestive of active pulmonary disease met the following criteria: the presence of centrilobular nodules (n=14), confluent nodules (n=11), tree-in-bud pattern (n=15), pulmonary consolidation in the upper lung zones (n=8), and thick-walled cavities (n=3). Some patients exhibited more than one of these radiological changes.

Tuberculous pleural effusions were exudates with high ADA levels according to Light's criteria. Comparing with transudates, the levels of all inflammatory markers were higher in the pleural fluid of the tuberculosis patients (data not shown). VEGF and TGF- β_1 were increased to similar levels in the blood and pleural fluid of the patients with both forms of the disease. The TNF- α levels were significantly higher in the pleural fluid of the patients with the pleuropulmonary form of the disease; this difference

Table 1 - Results obtained in the patients with pleural effusion secondary to tuberculosis (n = 39). The data are expressed as medians (25th and 75th percentiles).

	Pleural fluid	Blood	p-value
Biochemical Analysis			
Total proteins (g/dL)	5.3 (4.7-5.7)	7.8 (7.2-8.5)	<0.001
Lactic dehydrogenase (UI/L)	877 (572-1182)	503 (442-591)	<0.001
Adenosine deaminase (U/L)	115 (78.1-145.3)		
	Pleural fluid/Blood		
Total proteins	0.6 (0.6-0.7)		
Lactic dehydrogenase	1.8 (1.2-2.2)		
Cytokine Analysis			
Vascular endothelium growth factor (VEGF)	1364 (927-2120)	896 (288-1781)	0.014
Interleukin-8 (IL-8)	1583 (1239-1886)	31 (31-125)	<0.001
Tumor necrosis factor- α (TNF- α)	209 (37-498)	16 (16-475)	0.007
Transforming growth factor- β_1 (TGF- β_1)	647 (377-1027)	751 (486-1135)	0.439

represented the single parameter that was capable of differentiating between the two forms. IL-8 was increased in the pleural fluid of all the TB patients, and no differences in the levels of IL-8 were observed between the two forms. As expected, the protein and lactic dehydrogenase levels were higher in the serum and pleural fluid, respectively (Table 1; Figures 1 and 2).

DISCUSSION

The high expression of inflammatory mediators in the pleural fluid of pleural tuberculosis patients allows us to recognize the exudative inflammatory response at the site of active disease. The increased levels of VEGF and TGF- β in the serum of these patients reflect the systemic response

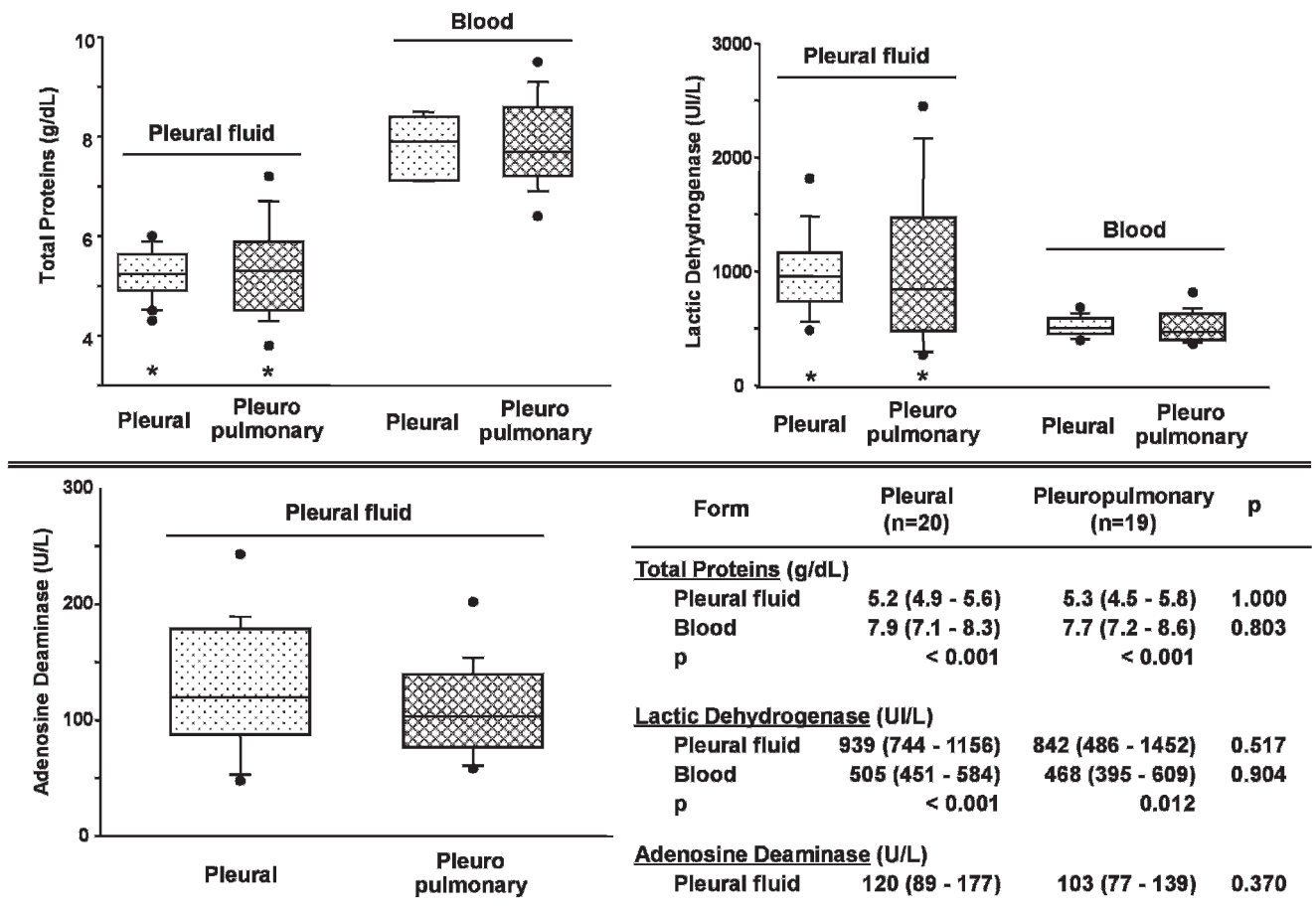


Figure 1 - Biochemical analysis of the fluid and blood of the patients with tuberculous pleural effusions. The data are expressed as medians; 25th and 75th percentiles (*p<0.05: fluid x blood).

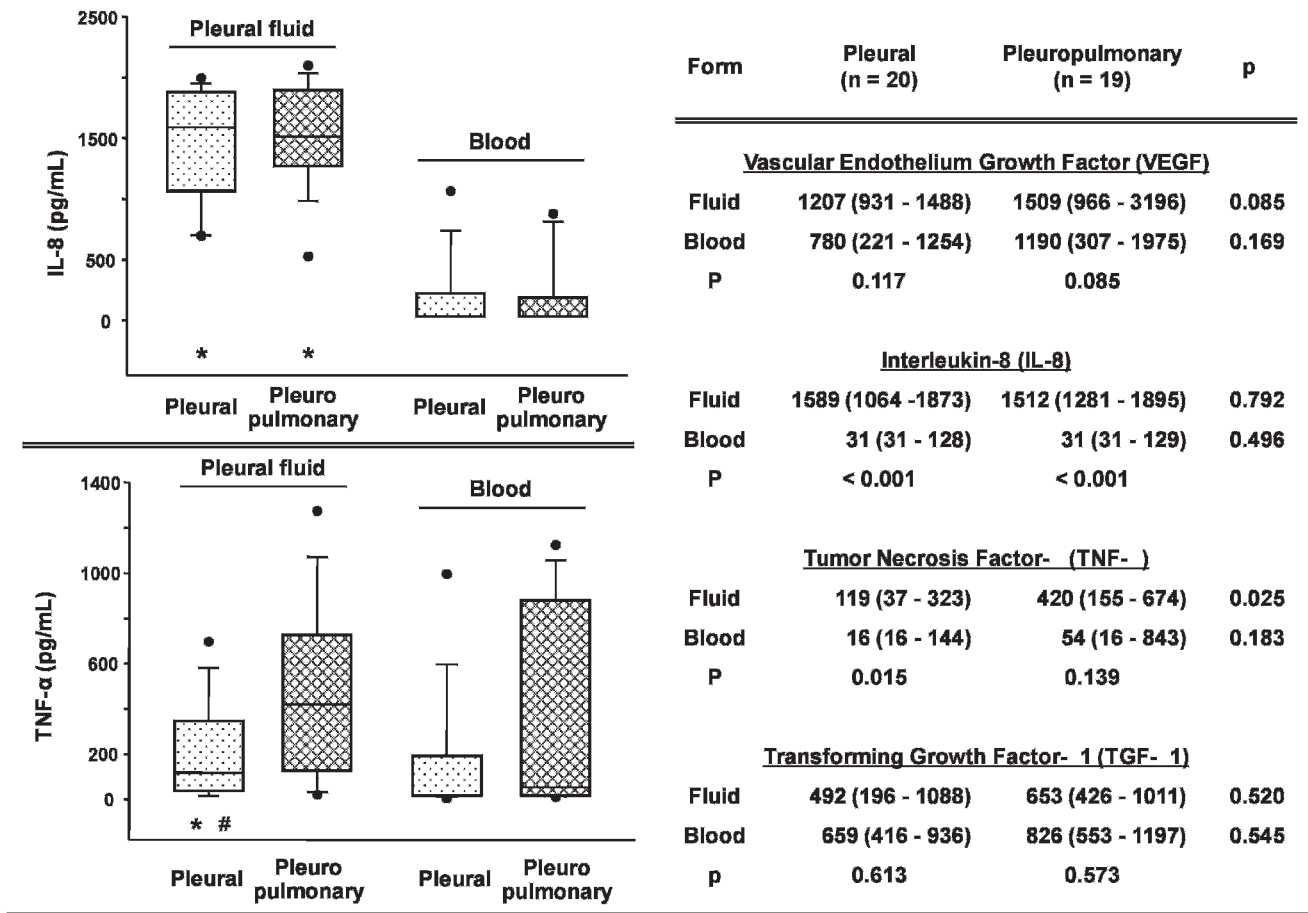


Figure 2 - Cytokines in the fluid and blood of the patients with tuberculous pleural effusions. The data are expressed as medians: 25th and 75th percentiles (*p<0.05: pleural fluid x blood; #p<0.05: pleural x pleuropulmonary).

observed in cases of pleural tuberculosis. Although elevated TNF-α levels in the pleural fluid was the single parameter that was capable of differentiating between the two forms of the disease, the overlapping results do not suggest that this cytokine is a marker of pulmonary involvement.

Tuberculosis pleurisy is an acute and symptomatic disease that invariably evolves with exudative pleural effusions that are rich in cells and inflammatory mediators (1,2,4,7-10). Although tuberculosis pleurisy can indicate a manifestation of primary infection, it is most commonly associated with the reactivation of preexisting foci (1,2,4). Currently available laboratory methods frequently fail to demonstrate a possible concomitance with active pulmonary disease (1). In this regard, high resolution chest tomography has been helpful in identifying pulmonary lesions that are consistent with active disease in approximately 40% of pleural tuberculosis patients (20-24). This finding has epidemiological implications, particularly if we consider that these patients are potential sources of infection and that their contacts are often not clinically or radiologically evaluated. Therefore, we hypothesized that the patients with the pleuropulmonary form of tuberculosis could exhibit a greater inflammatory response because of the involvement of more than one anatomic site. This fact presumably determines systemic repercussions that could be detected by evaluating the serum and pleural inflammatory mediators.

Our findings corroborate previously described reports of increased inflammatory mediators in the pleural fluid of patients with pleural tuberculosis, thereby providing evidence of the compartmentalization of the inflammatory response at the active disease site (10,13,20,27). During the early phases of infection, after antigenic stimulation is triggered by the mycobacteria, cytokines such as VEGF, TNF-α, and IL-8 are transiently produced *in vivo* and alter the pleura permeability; this event precedes the exudative phase (20,28). However, the elevated serum levels of TNF-α and TGF-β are thought to be related to prolonged antigenic stimulation, similar to observations in patients with pulmonary tuberculosis or late-diagnosed pleural tuberculosis (28-30).

In pleural tuberculosis, many cytokines are produced intracavitarily and modulate the inflammatory response that is triggered by the mycobacteria or its antigens to limit or aggravate the disease (7,19). Previous studies have related the findings of high serum or PF levels of TNF-α, TGF-β, and IL-8 to residual pleural thickening (19,20). TGF-β is a mediator that is expressed in active infection and plays a fundamental role in the fibrotic scarring process. TGF-β is a key mediator in the immunopathogenesis of tuberculosis because it is able to modify the production and function of other cytokines, such as IL-1β and TNF-α, in addition to modulating the functions of T lymphocytes and macrophages (7,20,29,30). In pleural tuberculosis, the excessive

production of TGF- β is believed to be related to the clinical progression of the disease, particularly in the physiopathology of pleural thickening (29). TGF- β possesses proinflammatory activity in low concentrations (pleural tuberculosis and healthy contacts of tuberculosis carries) and anti-inflammatory activity in high concentrations (pulmonary tuberculosis). We observed increased levels of TGF- β in the pleural fluid and blood of tuberculosis patients. Although higher TGF- β levels were observed in the pleuropulmonary form, there was no statistical significance when compared to the levels in patients with pleural disease.

Siawaya et al. (8) studied the cytokine and chemokine profiles of patients with different forms of tuberculosis to better understand the immunopathology of the disease and identify the biological markers that differentiate the various clinical forms of the disease. The authors concluded that systemic inflammatory markers, such as IL-8, TNF- α , and VEGF, are associated with pleural tuberculosis, whereas elevated levels of the factors involved in cell-mediated immunity, such as IL-12p40 and sCD40L, characterize pulmonary tuberculosis.

In conclusion, the present study demonstrates an intense intracavitary inflammatory response in the patients with pleural tuberculosis independent of parenchymal involvement. Although all of the cytokines were overexpressed in the pleural fluid, only TNF- α was significantly increased in the pleuropulmonary tuberculosis patients. This finding could suggest a more pronounced inflammatory response because of the concomitance of the anatomic sites involved. However, TNF- α should not be considered to be a biological marker of pulmonary-associated disease. Although HRCT can be useful in identifying these patients, the identification of fast acid bacilli and/or the culture for *M. tuberculosis* in the sputum is recommended for all pleural tuberculosis patients.

ACKNOWLEDGMENTS

The study was supported by grants from the Fundação de Amparo à Pesquisa do Estado de São Paulo (FAPESP).

AUTHOR CONTRIBUTIONS

Antonangelo L, Vargas FS, Seiscento M, and Sales RK participated in the study design and conduction. Puka J, Acencio MM analyzed the patient files. Teixeira LR and Terra RM performed the statistical analysis. Antonangelo L, Vargas FS, Puka J, and Sales RK drafted and reviewed the manuscript. All of the authors reviewed and approved the manuscript.

REFERENCES

- Light RW. Update on tuberculous pleural effusion. *Respirology*. 2010;15(3):451-8, <http://dx.doi.org/10.1111/j.1440-1843.2010.01723.x>.
- Porcel JM. Tuberculous pleural effusion. *Lung*. 2009;187(5):263-70, <http://dx.doi.org/10.1007/s00408-009-9165-3>.
- Baumann MH, Nolan R, Petrini M, Lee YC, Light RW, Schneider E. Pleural tuberculosis in the United States: incidence and drug resistance. *Chest*. 2007;131(4):1125-32, <http://dx.doi.org/10.1378/chest.06-2352>.
- Valdes L, Pose A, San Jose E, Martinez Vazquez JM. Tuberculous pleural effusions. *European journal of internal medicine*. 2003;14(2):77-88, [http://dx.doi.org/10.1016/S0953-6205\(03\)00018-9](http://dx.doi.org/10.1016/S0953-6205(03)00018-9).
- Cooper AM, Khader SA. The role of cytokines in the initiation, expansion, and control of cellular immunity to tuberculosis. *Immunol Rev* 2008;226:191-204, <http://dx.doi.org/10.1111/j.1600-065X.2008.00702.x>.
- Jantz MA, Antony VB. Pathophysiology of the pleura. *Respiration*. 2008;75(2):121-33, <http://dx.doi.org/10.1159/000113629>.
- Antony VB. Immunological mechanisms in pleural disease. *Eur Respir J*. 2003;21(3):539-44, <http://dx.doi.org/10.1183/09031936.03.00403902>.
- Siawaya JFD, Chegou NN, van den Heuvel MM, Diacon AH, Beyers N, van Helden P, et al. Differential cytokine/chemokines and KL-6 profiles in patients with different forms of tuberculosis. *Cytokine*. 2009;47(2):132-6, <http://dx.doi.org/10.1016/j.cyto.2009.05.016>.
- Seiscento M, Vargas FS, Acencio MM, Teixeira LR, Capelozzi VL, Sales RK, et al. Pleural fluid cytokines correlate with tissue inflammatory expression in tuberculosis. *Int J Tuberc Lung Dis*. 2010;14(9):1153-8.
- Akarsu S, Kurt ANC, Dogan Y, Yilmaz E, Godekmerdan A, Aygun AD. The differential diagnostic values of cytokine levels in pleural effusions. *Mediators Inflamm*. 2005;2005(1):2-8, <http://dx.doi.org/10.1155/MI.2005.2>.
- Pokkali S, Das SD, Logamurthy R. Expression of CXC and CC type of chemokines and its receptors in tuberculous and non-tuberculous effusions. *Cytokine*. 2008;(3):307-14, <http://dx.doi.org/10.1016/j.cyto.2007.12.009>.
- Yang CS, Lee JS, Lee HM, Shim TS, Son JW, Jung SS, et al. Differential cytokine levels and immunoreactivities against *Mycobacterium tuberculosis* antigens between tuberculous and malignant effusions. *Respir Med*. 2008;102(6):280-6, <http://dx.doi.org/10.1016/j.rmed.2007.08.016>.
- Hoheisel G, Izbicki G, Roth M, Chan CHS, Leung JCK, Reichenberger F, et al. Compartmentalization of pro-inflammatory cytokines in tuberculous pleurisy. *Respir Med*. 1998;92(1):14-7, [http://dx.doi.org/10.1016/S0954-6111\(98\)90025-7](http://dx.doi.org/10.1016/S0954-6111(98)90025-7).
- Saunders BM, Britton WJ. Life and death in the granuloma: immunopathology of tuberculosis. *Immunology and cell biology*. 2007;85(2):103-11, <http://dx.doi.org/10.1038/sj.icb.7100027>.
- Park JS, Kim YS, Jee YK, Myong NH, Lee KY. Interleukin-8 production in tuberculous pleurisy: role of mesothelial cells stimulated by cytokine network involving tumour necrosis factor-alpha and interleukin-1 beta. *Scandinavian journal of immunology*. 2003;57(5):463-9, <http://dx.doi.org/10.1046/j.1365-3083.2003.01201.x>.
- Lim SC, Jung SI, Kim YC, Park KO. Vascular endothelial growth factor in malignant and tuberculous pleural effusions. *J Korean Med Sci*. 2000;15(3):279-83.
- Momi H, Matsuyama W, Inoue K, Kawabata M, Arimura K, Fukunaga H, et al. Vascular endothelial growth factor and proinflammatory cytokines in pleural effusions. *Respir Med*. 2002;96(10):817-22, <http://dx.doi.org/10.1053/rmed.2002.1364>.
- Hamed EA, El-Noweihl AM, Mohamed AZ, Mahmoud A. Vasoactive mediators (VEGF and TNF- α) in patients with malignant and tuberculous pleural effusions. *Respirology*. 2004;9(1):81-6, <http://dx.doi.org/10.1111/j.1440-1843.2003.00529.x>.
- Hua CC, Chang LC, Chen YC, Chang SC. Proinflammatory cytokines and fibrinolytic enzymes in tuberculous and malignant pleural effusions. *Chest*. 1999;116(5):1292-6, <http://dx.doi.org/10.1378/chest.116.5.1292>.
- Olobo JO, Geletu M, Demissie A, Eguale T, Hiwot K, Aderaye G, et al. Circulating TNF- α , TGF- β , and IL-10 in tuberculosis patients and healthy contacts. *Scandinavian journal of immunology*. 2001;53(1):85-91, <http://dx.doi.org/10.1046/j.1365-3083.2001.00844.x>.
- Valdés L, Alvarez D, San José E, Penela P, Valle JM, García-Pazos JM, et al. Tuberculous pleurisy: a study of 254 patients. *Arch Intern Med*. 1998;158(18):2017-21, <http://dx.doi.org/10.1001/archinte.158.18.2017>.
- Kim HJ, Lee HJ, Kwon SY, Yoon HI, Chung HS, Lee CT, et al. The prevalence of pulmonary parenchymal tuberculosis in patients with tuberculous pleuritis. *Chest*. 2006;129(5):1253-8, <http://dx.doi.org/10.1378/chest.129.5.1253>.
- Nakanishi M, Demura Y, Ameshima S, Kosaka N, Chiba Y, Nishikawa S, et al. Utility of high-resolution computed tomography for predicting risk of sputum smear-negative pulmonary tuberculosis. *Eur J Radiol*. 2010;73(3):545-50, <http://dx.doi.org/10.1016/j.ejrad.2008.12.009>.
- Seiscento M, Vargas FS, Bombarda S, Sales RK, Terra RM, Uezumi K, et al. Pulmonary involvement in pleural tuberculosis: how often does it mean disease activity? *Respir Med*. 2011;105(7):1079-83, <http://dx.doi.org/10.1016/j.rmed.2011.02.014>.
- Chung KP, Chen JY, Lee CH, Wu HD, Wang JY, Lee LN, Yu CJ, Yang PC; TAMI Group. Trends and predictors of changes in pulmonary function after treatment for pulmonary tuberculosis. *Clinics*. 2011;66(4):549-56, <http://dx.doi.org/10.1590/S1807-59322011000400005>.
- Giusti G. Adenosine deaminase. In: Bergmeyer HU, editor. *Methods of Enzymatic Analysis*. 1th ed. New York: Academic Press 1974;p.1092-9.
- Marchi E, Acencio M, Antonangelo L, Sales RK, Vargas FS, Teixeira LR. Cytokines in pleural effusions. *Am J Respir and Critical Care Medicine*. 2002;v.168:p.A605.
- Ruiz E, Alemán C, Alegre J, Monasterio J, Segura RM, Armadans L, et al. Angiogenic Factors and angiogenesis inhibitors in exudative pleural effusions. *Lung*. 2005;183(3):185-95, <http://dx.doi.org/10.1007/s00408-004-2533-0>.
- Ceyhan BB, Demiralp E, Karakurt ZL, Karakurt S, Sungur M. Transforming growth factor beta-1 level in pleural effusion. *Respirology*. 2003;8(3):321-5, <http://dx.doi.org/10.1046/j.1440-1843.2003.00474.x>.
- Marino S, Myers A, Flynn JL, Kirschner DE. TNF and IL-10 are major factors in modulation of the phagocytic cell environment in lung and lymph node in tuberculosis: a next-generation two-compartmental model. *J Theor Biol*. 2010;265(4):586-98, <http://dx.doi.org/10.1016/j.jtbi.2010.05.012>.