

TECHNICAL NOTE

An innovative model of autologous anorectal transplantation with pudendal nerve reconstruction

Flavio Henrique Ferreira Galvao, Victor Edmund Seid, Daniel Reis Waisberg, Ruy Jorge Cruz-Jr, Hugo Hirano, Sergio Catanozi, Eleazar Chaib, Luiz Augusto Carneiro D’Albuquerque

Faculdade de Medicina da Universidade de São Paulo, Department of Gastroenterology, Division of Transplantation, Laboratories of Medical Investigation (LIM37 and LIM10), São Paulo/SP, Brazil.

Email: fgalvao@usp.br
Tel.: 55 11 3061 8319

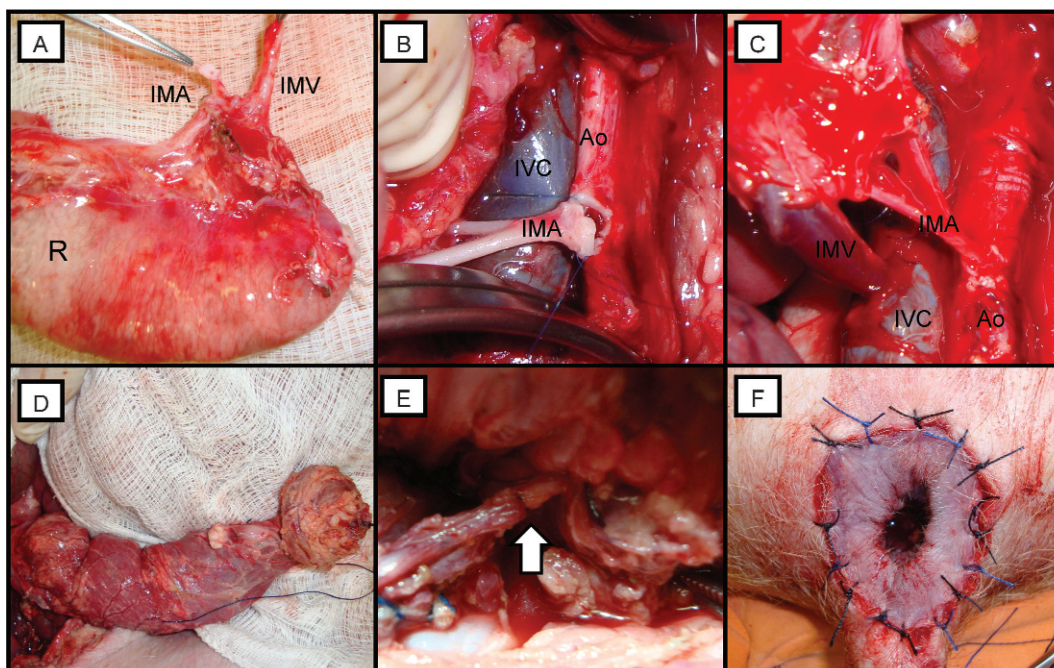


Figure 1 - (A) An anorectal graft showing the inferior mesenteric artery (IMA) and vein (IMV) and the rectum (R). (B) The infrarenal aorta (Ao) and vena cava (IVC) were cross-clamped at the site of anastomosis. (C) The anastomoses between the Ao and IMA and between the IVC and IMV. (D) The anorectal graft following reperfusion. (E) Pudendal nerve anastomosis (arrow head). (F) Anal anastomosis in the perineum.

Fecal incontinence is an important public health problem that has a significant impact on the quality of life of individual patients. The prevalence of fecal incontinence in the United States ranges from 2 to 17%, but this may be an underestimation (1). The current treatments for severe fecal incontinence are often complex and have disappointing results (1). Anorectal transplantation may be a definitive method for restoring normal sphincter function in these patients. We and others have previously investigated anorectal transplantation in rats with promising results (2-4).

However, there is a lack of pre-clinical large animal models to study the potential benefits of this procedure. In this paper, we describe an innovative surgical technique of anorectal auto-transplantation, which allows for physiological studies without the immunologic effects related to allotransplantation.

The technique was initially performed in three swine weighing 25-35 Kg. After general anesthesia, an abdominal and perineal incision was performed in which the rectum, anal sphincter, and skin surrounding the anus were procured en bloc. The graft’s vascular pedicle contained the inferior mesenteric artery (IMA) with a patch of the aorta and inferior mesenteric vein (IMV), which was divided near the splenic vein (Figure 1A). The pudendal nerve was carefully isolated and transected. The graft was removed and immediately flushed with 250 ml of cold heparinized preservation solution through a catheter inserted in the IMA. The graft was then placed in a cooler with cold solution without heparin for a total of 20 minutes.

Copyright © 2012 CLINICS – This is an Open Access article distributed under the terms of the Creative Commons Attribution Non-Commercial License (<http://creativecommons.org/licenses/by-nc/3.0/>) which permits unrestricted non-commercial use, distribution, and reproduction in any medium, provided the original work is properly cited.

No potential conflict of interest was reported.

The infrarenal aorta and vena cava were isolated and cross-clamped, and the graft was implanted by arterial and venous anastomoses between the IMA and the aorta (Figure 1B) and the IMV and vena cava (Figure 1C). After reperfusion (Figure 1D), the entire graft was placed inside the abdominal cavity, and the pudendal nerve was reconstructed (Figure 1E). Finally, the anus was placed in its original position, and the perineum was closed (Figure 1F). Digestive tract continuity was reestablished by an end-to-end colorectal anastomosis. The abdominal cavity was closed, and the animals were observed for an additional two hours. At the end of the experiment, the graft was removed for histological analysis. The average times for graft recovery and implantation (including vascular, nervous and GI reconstruction) were 57 and 99 minutes, respectively. No problems regarding graft perfusion were observed at the end of the experiment. Histological graft assessment showed normal aspects in one graft and mild ischemia-reperfusion injury in two.

To the best of our knowledge, there is only one report of a pre-clinical model of anorectal transplantation (5). Those authors described the donor and recipient surgical technique in four swine allotransplantations, with a 25% rate of technical failure after a 24-hour observation period. The experimental model described in this paper mimics the surgical stress and potential effects of graft denervation of allotransplantation but precludes, for obvious reasons, the antigen-mediated immune response. In addition, the technical modifications were associated with a significant reduction in the surgical time and cost. Therefore, anorectal autotransplantation in swine is a feasible and relatively simple procedure that may be a relevant technique to study regeneration, anorectal physiology, and the potential benefits of this unique type of transplantation without the interference of immune-mediated effects.

ACKNOWLEDGMENTS

This study was supported by Laboratory of Medical Investigation (LIM37), University of São Paulo School of Medicine.

AUTHOR CONTRIBUTIONS

Galvao FH conceived and designed the study, provided the hypothesis, performed the operative procedure, was responsible for the data analysis and interpretation, manuscript writing and approval of the manuscript final version. Seid VE conceived and designed the study, provided technical help with the operative procedure, was responsible for the data analysis, interpretation of results and approval of the manuscript final version. Waisberg DR conceived and designed the study, provided technical help with the operative procedure, was responsible for the data analysis and interpretation of results. Cruz Jr RJ conceived and designed the study, provided advice and consultation, was responsible for the manuscript writing, critical review and approval of the manuscript final version. Hirano H and Catanozi S provided technical help with the operative procedure, were responsible for the data analysis and interpretation of results. Chaib E and D'Albuquerque LA provided advice and consultation, were responsible for the manuscript writing and approval of the manuscript final version.

REFERENCES

1. Wald A. Fecal incontinence in adults. *New Engl J Med.* 2007;356(16):1648-55, <http://dx.doi.org/10.1056/NEJMcp067041>.
2. Galvao FHF, Seid VE, dos Santos RMN, Kitamura M, Galvao RD, Pinto RA, et al. Anorectal transplantation. *Tech Coloproctol.* 2009;13(1):55-9, <http://dx.doi.org/10.1007/s10151-009-0459-5>.
3. Galvao FHF, Waisberg DR, Vianna RMD, Galvao RD, Seid VE, Andraus W, et al. Intestinal transplantation including anorectal segment in the rat. *Microsurg.* 2012;32(1):77-9, <http://dx.doi.org/10.1002/micr.20958>.
4. Araki J, Mihara M, Narushima M, Iida T, Sato T, Koshima I. Vascularized Anal Autotransplantation Model in Rats: Preliminary Report. *Transplant P.* 2011;43(9):3552-6, <http://dx.doi.org/10.1016/j.transproceed.2011.08.042>.
5. O'Bichere A, Shurey S, Sibbons P, Green C, Phillips RKS. Experimental model of anorectal transplantation. *Brit J Surg.* 2000;87(11):1534-9, <http://dx.doi.org/10.1046/j.1365-2168.2000.01557.x>.