

BASIC RESEARCH

Protective effect of sildenafil citrate on contralateral testis injury after unilateral testicular torsion/detorsion

Hamit Yıldız,^I Ali Said Durmus,^{II} Halil Şimşek,^{III} Mine Yaman^{IV}

^IDepartment of Obstetrics and Gynecology, Faculty of Veterinary Medicine, Firat University, 23119 Elazığ, Turkey. ^{II}Department of Surgery, Faculty of Veterinary Medicine, University of Firat, 23119, Elazığ-Turkey. ^{III}Sanitary Services Vocational School of Higher Education, University of Bingöl, 12000 Bingöl, Turkey. ^{IV}Department of Histology, Faculty of Veterinary Medicine, University of Firat, 23119, Elazığ-Turkey.

OBJECTIVES: This study was designed to investigate prevention of contralateral testicular injury with sildenafil citrate after unilateral testicular torsion/detorsion.

METHODS: Thirty-seven adult male rats were divided into four groups: sham operated (group 1, n = 7), torsion/detorsion + saline (group 2, n = 10), torsion/detorsion + 0.7 mg of sildenafil citrate (group 3, n = 10) and torsion/detorsion + 1.4 mg of sildenafil citrate (group 4, n = 10). Unilateral testicular torsion was created by rotating the right testis 720° in a clockwise direction for 2 h in other groups, except for group 1, which was served as sham group. After torsion (2 h) and detorsion (2 h) periods, rats were killed.

RESULTS: The level of reduced glutathion (GSH) ($p < 0.05$) and the activities of catalase ($p < 0.01$) and glutathione peroxidase ($p < 0.05$) in the contralateral testis from group 2 were significantly lower and nitric oxide (NO) ($p < 0.05$) level in the contralateral testis were significantly higher than those of group 1. Administration of low-dose sildenafil citrate (group 3) prevented the increases in malondialdehyde and NO levels and decreases in glutathione peroxidase activities and GSH values induced by testicular torsion. However, administration of high-dose sildenafil citrate (group 4) had no effect on these testicular parameters ($p > 0.05$). Histopathological changes were detected in groups 2, 3 and 4.

CONCLUSION: These results suggest that biochemically and histologically torsion/detorsion injury occurs in the contralateral testis following 2-h torsion and 2-h detorsion and that administration of low-dose sildenafil citrate before detorsion prevents ischemia/reperfusion cellular damage in testicular tissue.

KEYWORDS: Testicular torsion; Ischemia-reperfusion damage; Sildenafil citrate; Rat.

Yıldız H, Durmus AS, Şimşek H, Yaman M. Protective effect of sildenafil citrate on contralateral testis injury after unilateral testicular torsion/detorsion. Clinics. 2011;66(1):137-142.

Received for publication on August 12, 2010; First review completed on September 29, 2010; Accepted for publication on October 10, 2010

E-mail: hamityildiz@firat.edu.tr

Tel.: 90 424 237 00 00 / 3854

INTRODUCTION

Testicular torsion is the most common cause of testicle loss in newborns, children and adolescent boys.¹ Although experimental and clinical studies have demonstrated that the contralateral (nontorted) testis is injured after unilateral testicular torsion (UTT),^{2,3} some studies have shown that this phenomenon is not always observed.^{4,5} The period of ischemia and reperfusion is an important factor for detrimental effects on the contralateral testis. Several studies have shown that testicular tissue damage is related to the degree of rotation of the testicle, reperfusion time and the duration of torsion.⁶ Testicular ischemia induces germ cell

death, which is attributed mainly to a reduction in oxygen supply relative to metabolic demands, depletion of the stored cellular energy and accumulation of toxic metabolites. The reperfusion phase may significantly exacerbate ischemia-induced germ cell injury via the formation of reactive oxygen and nitrogen species.⁷ Germ cell apoptosis in the contralateral testis increased significantly after 2, 3 and 24 h of ischemia and showed direct, time-related correlation with the duration of ischemia.⁸ On the whole, at least 4 h of 720° unilateral testicular torsion causes enough testicular tissue injury in both testis in rats.² Yazihan et al.³ reported that 2 h of 720° unilateral testicular torsion and 4 h of detorsion time caused significant biochemical and histological changes in both ipsilateral and contralateral testes. However, some studies previously^{9,10} showed that 2-h torsion and 2-h detorsion had an adverse effect on the contralateral testis.

Although sildenafil citrate has been developed for erectile dysfunction, it now has other medical indications (disease

such as pulmonary hypertension, cardiovascular, spinal cord injury and type II diabetes).⁷ Several studies have indicated that sildenafil may exert a powerful protective effect against ischemia and reperfusion (I/R) injury in the testis in rat models.^{11,12} Furthermore, it has been shown that administration of sildenafil may also be useful against ischemic injury in other organs such as the liver, colon and brain.¹³⁻¹⁵

In the present study, we investigated the protective effect of sildenafil citrate on the contralateral testis after testicular I/R injury, and we discuss the mechanisms underlying the effects of sildenafil on these processes.

MATERIAL AND METHODS

The experimental protocols were approved by the local Animal Use Committees of Firat University (Elazığ, Turkey) (No: 13/62 (03/09/2008)). Animal care and experimental protocols complied with the NIH Guide for the Care and Use of Laboratory Animals (NIH publication no. 85-23, revised 1985). This study was carried out at the Firat University Experimental Medical Research Center. During the study period, rats were fed with a standard laboratory diet and allowed water. A total of 37 male Wistar Albino rats, weighing between 220 and 250 g were housed in a climate-controlled (relative humidity of 40–60% and temperature of 21–24°C) animal care facility, with a 12-h light/dark cycle. Before surgical procedures, the animals were provided with standard rat chow and water *ad libitum*. The rats were anesthetized with intramuscular ketamine (Ketalar; Eczacıbaşı, İstanbul, Turkey) at 85 mg/kg body weight and xylazine (Rompun Vet; Bayer AG, İstanbul, Turkey) at 6 mg/kg body weight). Following anesthesia, the skin of the scrotal area was shaved and antisepsis was obtained using 10% povidone iodine solution.

The rats were divided into four groups. A midline incision was made in the scrotum. In all the groups except for the sham-operated group, torsions were created by rotating the right testis 720° clockwise for 2 h. The torsion was maintained by fixing the testis in the scrotum with a 4-0 silk suture, and the incision was closed. After a 2-h torsion period, the suture was removed, and the right testis was then detorted and replaced in the scrotum for 2 h.

In group 1 (sham-operated group, n = 7), the testes were taken out through the incision lines then replaced, and a silk suture was placed through the tunica albuginea. The rats were maintained in an ambient temperature of 24°C.

Group 2 (torsion/detorsion (T/D) + saline, n = 10) was used as the control group. Saline (2 ml of 0.9% NaCl) was injected intraperitoneally 1 h before the detorsion.

In group 3 (T/D + 0.7 mg/kg sildenafil citrate group, low dose, n = 10), the treatment with intraperitoneal sildenafil citrate (Deva Holding A.S., Degra 50 mg), 2 ml from 0.7 mg/kg dissolved in 0.9% NaCl, was carried out 1 h before the detorsion.

In group 4 (T/D + 1.4 mg/kg sildenafil citrate group, high dose, n = 10), treatment with intraperitoneal sildenafil citrate, 2 ml from 1.4 mg/kg dissolved in 0.9% NaCl, was carried out 1 h before detorsion. The torsion lasted for 2 h followed by a detorsion period of 2 h, after which the rats were killed and bilateral orchietomy performed. Contralateral testis in all groups were evaluated for the biochemical assay and histopathological examinations.

Homogenate preparation

Tissues were washed twice with cold saline solution, placed in glass bottles, labeled and stored in a deep freeze (–30°) until processing (maximum 10 h). After weighing, the tissue (1 g) was placed on dry ice, cut into small pieces with scissors, and homogenized (2 min at 3000 × g) in five volumes (1:5, w/v) of ice-cold Tris-HCl buffer (50 mM, pH 7.4), using a glass Teflon homogenizer (Çaliskan Cam Teknik, Ankara, Turkey). All the procedures for preparation were performed at 4°C. After addition of butylhydroxytoluol (4 µl per ml), the tissue homogenate samples were used for immediate NO, malondialdehyde (MDA), glutathione peroxidase (GPx), catalase (CAT) and GSH measurement.

Biochemical assay

Lipid peroxidation (as malondialdehyde) levels in tissue homogenate were measured with the thiobarbituric acid reaction by the method of Placer et al.¹⁶ The quantification of thiobarbituric acid-reactive substances was determined by comparing the absorption to the standard curve of malondialdehyde equivalents generated by acid-catalyzed hydrolysis of 1,1,3,3 tetramethoxypropane. The values of MDA were expressed as µmol/g protein. The GSH content of the tissue homogenate was measured at 412 nm using the method of Sedlak and Lindsay.¹⁷ The solution was kept at room temperature for 5 min, and then read at 412 nm on the spectrophotometer. Results were expressed as µmol/g protein. GSH-Px activities of the tissue were spectrophotometrically measured at 37°C and 412 nm according to Lawrence and Burk.¹⁸ Results were expressed as µmol/g protein. The protein content in the tissue was measured by the method of Lowry et al.¹⁹ with bovine serum albumin as the standard. CAT activity was assayed in tissue homogenate by the Aebi²⁰ method. The principle of the assay is based on the determination of the rate constant (s – 1, k) for H₂O₂ decomposition at 240 nm using a spectrophotometer. Results were expressed as unit/g protein. The NO content of the tissue was determined according to method of Green et al.²¹ Results were expressed as µmol per gr protein.

Histopathologic evaluation

The testicular tissues from rats for histopathological examination were collected. The tissue samples were fixed in 10% neutral buffered formalin embedded in paraffin wax and cut into 5-µm sections and stained with hematoxylin and eosin. The tissues were examined under a light microscope and the microscopic scoring was graded on a scale of mild (+), moderate (++) and severe (+++). Spermatogenesis was assessed histopathologically using Johnsen's mean testicular biopsy score (MTBS) criteria.²² All cross-sectioned tubules were evaluated systematically, and a score between 1 (very poor) and 10 (excellent) was given to each tubule according to Johnsen's criteria. Light microscopy with an ocular micrometer was used to measure mean values of seminiferous tubule diameter (MSTD) and germinal cell layer thicknesses (GCLT) and to evaluate the damage to testicular tissue. Twenty-five tubules were evaluated for each animal.

Statistical analysis

Differences between group means were estimated using a one-way analysis of variance (ANOVA) and the Duncan test was carried out for multiple comparisons using 11.0 for

Table 1 - CAT and GPx activities, GSH, MDA and NO levels in the contralateral testis in all groups.

Tissue parameters	Group 1 (n = 7)	Group 2 (n = 10)	Group 3 (n = 10)	Group 4 (n = 10)
CAT(k/g tissue)	14.38 ± 1.16*	11.41 ± 1.16 [†]	13.97 ± 1.13* [†]	12.22 ± 3.31 [†]
GSH (μmol/g protein)	1.59 ± 0.03 [‡]	1.50 ± 0.15 [§]	1.94 ± 0.25 [¶]	1.58 ± 0.34 ^{‡§}
GPx (μmol/g protein)	23.07 ± 1.20 [‡]	19.69 ± 2.20 [§]	23.43 ± 5.19 [‡]	20.57 ± 4.03 ^{‡§}
MDA (μmol/g protein)	0.60 ± 0.02 ^{‡§}	0.73 ± 0.03 [‡]	0.51 ± 0.07 [§]	0.58 ± 0.08 ^{‡§}
NO (μmol/g tissue)	31.11 ± 0.49 [§]	33.10 ± 0.22 [‡]	31.93 ± 0.74 ^{§¶}	32.27 ± 0.64 ^{‡§}

*[‡]Within rows: means with different superscript letters differ significantly (p<0.01).

^{‡§¶}Within rows: means with different superscript letters differ significantly (p<0.05).

Data are expressed as mean ± SEM.

Windows. Results were considered statistically significant at p<0.05.

RESULTS

Biochemical analysis

The results of testicular CAT and GPx activities and GSH, MDA and NO levels in contralateral testis in all groups are shown in Table 1. Contralateral testicular tissue GSH (p<0.05) level, CAT (p<0.01) and GPx (p<0.05) activities in group 2 were lower, whereas the NO level was higher (p<0.05) than in the group 1. The level of MDA in group 2 was increased, although the change was not statistically significant. GSH (p<0.05) level and GPx (p<0.05) activity were significantly higher and MDA level was significantly lower (p<0.05) in the contralateral testis of group 3 than in those of group 2. In group 3, contralateral testicular CAT and GPx activities and GSH, MDA and NO levels were

similar to those of group (sham) 1. The testicular GPx and CAT activities and GSH, MDA and NO levels in the contralateral testis in group 4 were not significantly different from those of group 2 (p>0.05).

Histopathologic evaluation

When the structure of the testis was histopathologically examined, it was observed that the histological appearance of testicular tissues of group 1 was normal (Figure 1a). There were some histopathological changes such as degeneration, desquamation, disorganization in germinal cells, interstitial oedema and capillary congestion and hemorrhage in the contralateral testis of rats in group 2 (Figure 1b). These histopathological changes were also present to a similar extent in contralateral testis of rats from group 4 (Figure 1d). However, these histopathological changes were not significantly obvious in group 3 (Table 2, Figure 1c).

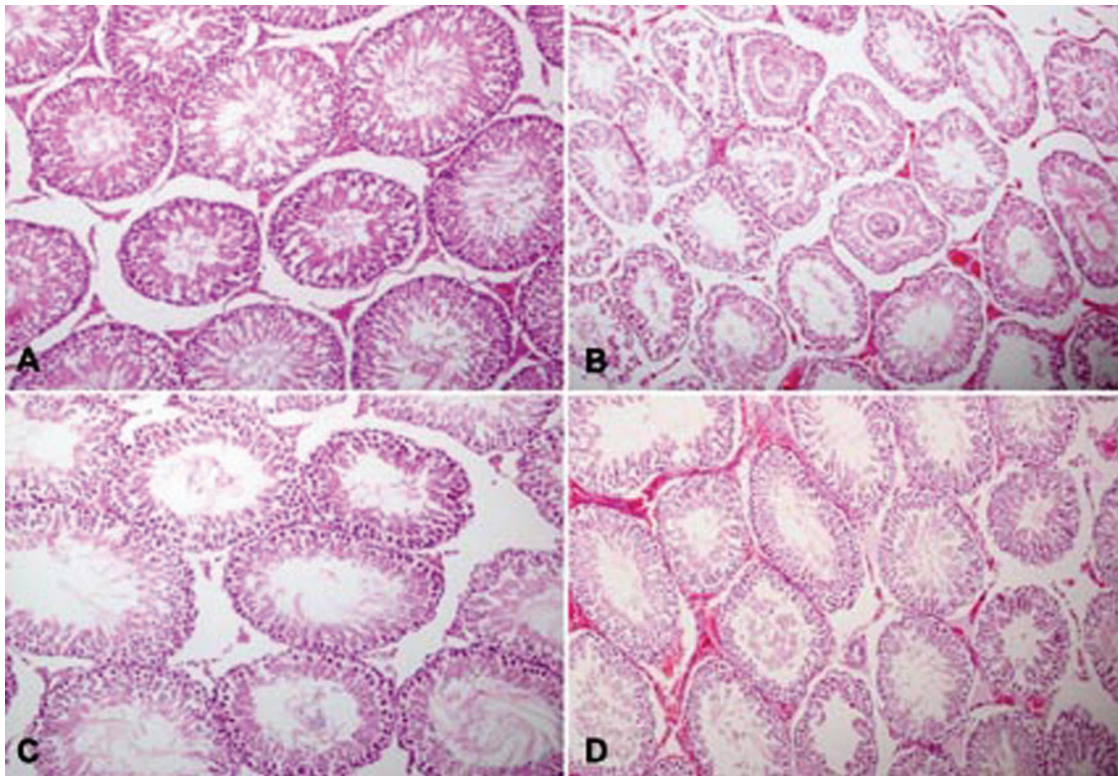


Figure 1 - (a) Normal morphological appearance seminiferous tubule in contralateral testis of group 1 (H&E, 200×). (b) Degeneration, desquamation and disorganization in germinal cell along with interstitial oedema, capillary congestion and hemorrhage in group 2 (H&E, 200×). (c) Normal morphological appearance seminiferous tubule in group 3 (H&E, 200×). (d) Degeneration, desquamation and reduction in germinal cell along with interstitial oedema, capillary congestion and hemorrhage in group 4 (H&E, 200×).

Table 2 - Degrees of some histopathological lesions of testicular sections of rats in all groups [mild (+), moderate (++), severe (+++)].

Parameters	Group 1	Group 2	Group 3	Group 4
Degeneration in germinal cells	ND	+	-	+
Desquamation in germinal cells	ND	+	-	+
Reduction in germinal cell counts	ND	-	-	+
Disorganization in germinal cells	ND	+	-	+
Interstitial oedema and capillary congestion	ND	+	-	++
Hemorrhage	ND	+	-	++

ND = not detected.

Significant decreases in MSTD and GCLT ($p < 0.01$) were observed in the testis of group 2 compared with group 1 (Table 3). MTBS value in the group 2 was decreased, although the changes were not statistically significant. Histological parameters such as MSTD and GCLT in the contralateral testis of group 3 were significantly more than the values in group 2. There were no differences between groups 2 and 4. In other words, the administration of low-dose sildenafil to rats resulted in an improvement in these histopathological parameters, whereas high-dose sildenafil did not yield an improvement, as confirmed by histopathological findings in groups 2 and 4.

DISCUSSION

The mechanisms of contralateral testis injury after UTT has not yet been identified. Different hypotheses have been put forward to explain this phenomenon. For example, contralateral testicular damage leads to subclinical attacks of contralateral testicular torsion, reduced contralateral testicular blood flow, a reflex activating the sympathetic system, underlying congenital defects, release of acrosomal enzymes, immunological mechanism, free oxygen radical formation after detorsion, and overproduction of NO by activated inducible nitric oxide synthase (NOS), and alterations in the blood flow.^{7,23-25} In contrast, Akgur et al.² suggested that UTT causes a decrease in the perfusion of the contralateral testis, and levels of lactic acid, hypoxanthine and lipid peroxidation were increased significantly in the contralateral testis after UTT. Pampal et al.⁹ said that testicular I/R injury after 2-h torsion and 2-h detorsion affects the contralateral testis, epididymis and the adjacent vas deferens. They suggested that UTT leads to infertility due to the damage on the contralateral side; this infertility can be the consequence of testicular and epididymal injury, and also of altered vas motility due to vas deferens injury after testicular I/R. In addition, Aktas et al.¹⁰ found significant increases in MDA levels and decreases in the mean seminiferous tubular diameter and germinal epithelial cell thickness after 2-h torsion and 2-h detorsion. In contrast, Unsal et al.²⁶ did not find any harmful effects in the

contralateral testis after 2-h torsion or detorsion in terms of biochemical or histological parameters. In our study, 2 h of 720° unilateral testicular T/D leads to significant changes in enzymatic antioxidants, lipid peroxidation and histological parameters in the contralateral testis. According to our results, in the contralateral testis of group 2, there were significant decreases in CAT and GPx activities, GSH levels, MSTD and GCLT, and an increase in NO level compared with group 1. These changes in the contralateral testis after unilateral testicular T/D were in agreement with the findings obtained by other researchers.^{2,9,26}

In the present study, T/D caused a significant increase in disorganization, degeneration and desquamation in germinal cells, interstitial edema and capillary congestion, hemorrhage in the contralateral testis and also reduced the histological parameters such as MSTD and GCLT. Similar studies demonstrated that T/D creates increased capillary edema, congestion, interstitial hemorrhage and hemorrhagic infarcts in the injured testis and reduced seminiferous tubule diameter, GCLT and Johnsen's testicular score.^{27,28} Some studies reported that administration of sildenafil and vardenafil during reperfusion reduced apoptotic cells and testicular necrosis.^{11,12} In contrast, Üstün et al.²⁹ reported that oral sildenafil and vardenafil (0.5 mg/kg) had no protective effect on testicular apoptotic cell. However, in our study, we administered sildenafil intraperitoneally. Consistently, intraperitoneal administration of sildenafil¹¹ and vardenafil¹² results in significantly higher sildenafil and vardenafil concentrations in the testicular tissue than when administered orally. In several studies, it has been observed that administration of sildenafil and vardenafil during reperfusion after ischemia decreased the myocardial infarct size by opening mitochondrial K_{ATP} channels in the heart.^{30,31} Mitochondrial K_{ATP} channel opening may prevent apoptosis, presumably by inhibiting the mitochondrial Ca²⁺ accumulation during ischemia.³² We propose that low-dose sildenafil administration caused a pivotal amelioration in the testicular histological view after T/D-induced I/R damage via a similar mechanism as suggested by some researchers.^{30,31} Also, administration of low-dose sildenafil citrate improved the T/D-induced

Table 3 - Mean values of seminiferous tubules diameters (MSTD), germinal cell layer thickness (GCLT) and mean testicular biopsy score (MTBS) in testis of all groups.

Parameters	Group 1 (n = 7)	Group 2 (n = 10)	Group 3 (n = 10)	Group 4 (n = 10)
MSTD (µm)	294.00 ± 6.79*	256.00 ± 4.31 [†]	283.83 ± 5.44*	267.50 ± 6.32 [†]
GCLT (µm)	6.13 ± 0.12*	5.50 ± 0.15 [†]	6.18 ± 0.16*	4.87 ± 0.34 [‡]
MTBS	10.00 ± 0.00*	9.50 ± 0.22* [†]	9.66 ± 0.21*	9.00 ± 0.25 [†]

*†‡Within rows: means with different superscript letters differ significantly ($p < 0.01$).

Data are expressed as mean ± SEM.

decrease in the diameters of seminiferous tubules, GCLT and Johnsen's testicular score (not statistically significant). However, administration of high-dose sildenafil citrate to rats in group 4 imposes a protective effect on testicular I/R injury when compared with group 2. Similarly, in a study by Kolettis et al.,³³ beneficial actions on left ventricular function were evident after a low-dose of sildenafil (0.7 mg/kg) administration to rats 30 min before myocardial ischemia, but were lost after doubling the dose (1.4 mg/kg), and compared with controls post-ischaemic recovery was higher after low dose and unchanged after high dose. In addition, low concentrations of sildenafil improved recovery of reperfusion aortic output and infarct size, while high concentrations worsened aortic output recovery.³⁴ Findings obtained in group 4 were in agreement with the results of other researchers.^{33,34}

Since increasing level of NOS expression leads to excessive NO production, high concentrations of NO, which is an important free radical, may cause DNA damage and cell death in testis. NO increases the level of cyclic guanosine monophosphate, which results in relaxation of the smooth muscle, creating increased blood flow. Also, NO is a potent inhibitor of nicotinamide adenine dinucleotide phosphate oxidase expression in vascular tissue.³⁵ The increased expressions of endothelial NOS and inducible NOS in I/R damage of testis has been reported previously.³² In the present study, tissue NO levels in contralateral testis were higher in group 2 than in group 1. Contralateral testis injury after UTT may be due to increased tissue NO levels. Similarly, Ustün et al.²⁹ found significant elevations in endothelial NOS and inducible NOS levels in testicular tissues after I/R damage. These authors showed that oral administration of sildenafil and vardenafil (0.5 mg/day) significantly increased endothelial NOS and inducible NOS expressions in ipsilateral testis, and they had no protective effect on testicular I/R injury. In contrast, Erol et al.¹² reported that vardenafil treatment significantly reduced endothelial NOS and inducible NOS levels in testicular tissues after I/R injury. This effect of vardenafil was shown to be mediated by increased intracellular cyclic guanosine monophosphate levels and activation of mitochondrial K_{ATP} channels either directly or through a variety of signaling pathways, such as activation of protein kinase C.³⁶ In the present study, the tissue NO level in the contralateral testis in group 3 was significantly lower than in groups 2 and 4. In other words, the level of NO in group 1 was similar to those of group 3. These results indicate the beneficial effects of intraperitoneal low-dose sildenafil administration on I/R damage after UTT. Therefore, our findings are consistent with those of Erol et al.¹² However, our results contradict those reported by Ustün et al.²⁹ The differences may be due to oral administration of phosphodiesterase type 5 inhibitors. Sildenafil acts by inhibiting phosphodiesterase type 5 activity, which by preventing the hydrolysis of cyclic guanosine monophosphate increases the nucleotide, thus amplifying the effect of diminished NO.³⁷

A possible cause of the testicular damage due to T/D is I/R injury attributed to neutrophil infiltration and reactive oxygen species.³⁸ Peroxidation of the lipids in membranes changes membrane permeability or disrupts membrane integrity and thus inflicts significant injury on cellular organisms.³⁹ However, the protective role of antioxidant enzymes such as CAT, GSH and GPx against free radical attack is in balance under normal conditions. In our study,

we observed that the level of tissue MDA was increased (not statistically significant) and GPx and CAT activities and GSH level were significantly decreased in group 2. Previous studies have shown similar findings that I/R injury leads to increased MDA and inactivation of antioxidant enzymes in rat testis.^{11,12,15} Intraperitoneal treatment with sildenafil or vardenafil prevented a further increase in MDA levels and significantly increased GSH levels and the GPx and CAT activities after testicular T/D.^{11,12,15} The increase in CAT values of red blood cells after sildenafil treatments has been attributed to the inhibition of free radicals and lipid peroxidation.^{37,40} In the current study, the treatment of low-dose sildenafil before detorsion increased GSH levels and GPx and CAT activities (not statistically significant) and decreased the MDA level in the contralateral testis when compared with group 2, but administration of high-dose sildenafil did not cause significant improvement in these parameters. The protective effect of sildenafil citrate on oxidative stress has previously been shown in many investigations related to I/R injury in other tissues, for example in the liver, colon and brain.¹³⁻¹⁵ This effect of sildenafil could be associated with its inhibiting effect on the production of lipid peroxidation via the activity and expression of nicotinamide adenine dinucleotide phosphate-oxidase.^{37,40}

CONCLUSIONS

I/R injury may occur in the contralateral testis following the 2-h T/D procedure. Intraperitoneal treatment of low-dose sildenafil citrate decreased free radical formation and increased antioxidant enzyme values and attenuated histopathological damage in the testis after T/D. Whereas, high-dose sildenafil treatment had no effect. From these results, we suggest that low-dose sildenafil, which is safe in humans, could be used to prevent lesion on the contralateral testis before surgery.

REFERENCES

1. Visser AJ, Heyns CF. Testicular function after torsion of the spermatic cord. *BJU Int.* 2003;92:200-3, doi: 10.1046/j.1464-410X.2003.04307.x.
2. Akgur FM, Kilinc K, Tanyel FC, Buyukpamukcu N, Hicsonmez A. Ipsilateral and contralateral testicular biochemical acute changes after unilateral testicular torsion and detorsion. *Urology.* 1994;44:413-8, doi: 10.1016/S0090-4295(94)80105-3.
3. Yazihan N, Ataoglu H, Koku N, Erdemli E, Sargin AK. Protective role of erythropoietin during testicular torsion of the rats. *World J Urol.* 2007;25:531-6.
4. Turner TT. Acute experimental testicular torsion. No effect on the contralateral testis. *J Androl.* 1985;6:65-72.
5. Stern JA, Lui RC, LaRegina MC, Herbold DR, Tolman KC, Johnson FE. Long-term outcome following testicular ischemia in the rat. *J Androl.* 1990;11:390-5.
6. Costabile RA, Choyke PL, Frank JA, Girton ME, Diggs R, Billups KL, Desjardins C. Variability of ischemia during spermatic cord torsion in rat. *J Urol.* 1994;151:1070-2.
7. Filho DW, Torres MA, Bordin AL, Crezcynski-Pasa TB, Boveris A. Spermatic cord torsion, reactive oxygen and nitrogen species and ischemia-reperfusion injury. *Mol Aspect Med.* 2004;25:199-210, doi: 10.1016/j.mam.2004.02.020.
8. Sukhotnik I, Miselevich I, Lurie M, Nativ O, Coran AG, Mogilner G. The time relationship between ipsilateral testicular ischemia-reperfusion and germ cell apoptosis in the contralateral testis in rat. *Pediatr Surg Int.* 2005;15:1-5.
9. Pampal A, Ozen IO, Ekingen G, Demirogullari B, Helvacioğlu F, Take G. The morphological evaluation of ipsilateral and contralateral vasa deferentia in a rat model of unilateral spermatic cord torsion. *Pediatr Surg Int.* 2010;26:287-92, doi: 10.1007/s00383-009-2533-5.
10. Aktas BÇ, Bulut S, Bulut S, Baykam MM, Ozden C, Senes M, et al. The effects of N-acetylcysteine on testicular damage in experimental testicular

ischemia/reperfusion injury. *Pediatr Surg Int.* 2010;26:293–8, doi: 10.1007/s00383-009-2538-0.

11. Beheshtian A, Salmasi AH, Payabvash S, Kiumehr S, Ghazinezami B, Rahimpour S, et al. Protective effects of sildenafil administration on testicular torsion/detorsion damage in rats. *World J Urol.* 2008;26:197–202.
12. Erol B, Tokgoz H, Hanci V, Bektas S, Akduman B, Yencilek F, et al. Vardenafil reduces testicular damage following ischemia/reperfusion injury in rats. *Kaohsiung J Med Sci.* 2009;25:374–380, doi: 10.1016/S1607-551X(09)70530-3.
13. Li J, Fu P, Deleon M, French BA, French SW. The effect of Viagra (sildenafil citrate) on liver injury caused by chronic ethanol intragastric feeding in rats. *Exp Mol Pathol.* 2005;78:101–8, doi: 10.1016/j.yemp.2004.09.004.
14. Zhang RL, Zhang Z, Zhang L, Wang Y, Zhang C, Chopp M. Delayed treatment with sildenafil enhances neurogenesis and improves functional recovery in aged rats after focal cerebral ischemia. *J Neurosci Res.* 2006; 1:1213–9, doi: 10.1002/jnr.20813.
15. Uzun H, Konukoglu D, Nuri MK, Ersoy EY, Özçevik S, Yavuz N. The effects of sildenafil citrate on ischemic colonic anastomotic healing in rats: its relationship between nitric oxide and oxidative stress. *World J Surg.* 2008;32:2107–13.
16. Placer ZA, Cushman L, Johnson BC. Estimation of products of lipid peroxidation (malonyl dialdehyde) in biological fluids. *Anal. Biochem.* 1966;16:359–64, doi: 10.1016/0003-2697(66)90167-9.
17. Sedlak J, Lindsay RHC. Estimation of total, protein bound and non-protein sulfhydryl groups in tissue with Ellmann's reagent. *Anal. Biochem.* 1968;25:192–205, doi: 10.1016/0003-2697(68)90092-4.
18. Lawrence RA, Burk RF. Glutathione peroxidase activity in selenium-deficient rat liver. *Biochem. Biophys. Res. Commun.* 1976;71:952–8, doi: 10.1016/0006-291X(76)90747-6.
19. Lowry OH, Rosebrough NJ, Farr AL, Randall RJ. Protein measurement with the Folin-Phenol reagent. *J. Biol. Chem.* 1951;193: 265–75.
20. Aebi H. Catalase in vitro. *Methods Enzymol.* 1984;105:121–6, doi: 10.1016/S0076-6879(84)05016-3.
21. Green LC, Wagner DA, Glogowski J, Skippner PL, Wishnok JS, Tannenbaum SR. Analysis of nitrate, nitrite, and [15N] nitrite in biological fluids. *Anal. Biochem.* 1982;126:131–8, doi: 10.1016/0003-2697(82)90118-X.
22. Johnsen SG. Testicular biopsy score count a method for registration of spermatogenesis in human normal values and results in 335 hypogonadal males. *Hormones.* 1970;1:2–25, doi: 10.1159/000178170.
23. Andiran F, Okur DH, Kilinc A, Gedikoglu G, Kilinc K, Tanyel FC. Do experimentally induced ipsilateral testicular torsion, vas deferens obstruction, intra-abdominal testis or venous obstruction damage the contralateral testis through a common mechanism? *Br J Urol Int.* 2000; 85:330–5.
24. Karagüzel G, Tanyel FC, Kilinç K, Büyükpamukçu N, Hiçsönmez A. The preventive role of chemical sympathectomy on contralateral testicular hypoxic parameters encountered during unilateral testicular torsion. *Br J Urol.* 1994;74:507–10.
25. York JP, Drago JR. Torsion and the contralateral testicle. *J Urol.* 1985;133:294–7.
26. Unsal A, Devrim E, Guven C, Eroglu M, Durak I, A Bozoklu A, et al. Propofol attenuates reperfusion injury after testicular torsion and detorsion. *World J Urol.* 2004;22:461–5.
27. Somuncu S, Cakmak M, Erdogan S, Caglayan O, Akman H, Kaya M. Protective effects of trapidil in ischemia-reperfusion injury due to testicular torsion and detorsion: an experimental study. *Int J Urol.* 2006; 13:601–5.
28. Bozlu M, Acar D, Cayan S, Aktas S, Tunckiran A. Protective effect of trapidil on long-term histologic damage in a rat model of testicular ischemia-reperfusion injury. *World J Urol.* 2009;27:117–22.
29. Ustün H, Akgül KT, Ayyıldız A, Yagmurdur H, Nuhoglu B, Ersagun Karaguzel, et al. Effect of phosphodiesterase 5 inhibitors on apoptosis and nitric oxide synthases in testis torsion: an experimental study. *Pediatr Surg Int.* 2008;24:205–11, doi: 10.1007/s00383-007-2058-8.
30. Salloum FN, Ockaili RA, Wittkamp M, Marwaha VR, Kukreja RC. Vardenafil: A novel type 5 phosphodiesterase inhibitor reduces myocardial infarct size following ischemia/reperfusion Vardenafil reduces testicular damage injury via opening of mitochondrial KATP channels in rabbits. *J Mol Cell Cardiol.* 2006;40:405–411, doi: 10.1016/j.yjmcc.2005.10.002.
31. Ockaili R, Salloum F, Hawkins J, Kukreja RC. Sildenafil (Viagra) induces powerful cardioprotective effect via opening of mitochondrial KATP channels in rabbits. *Am J Physiol Heart Circ Physiol.* 2002;283: 1263–9.
32. Taneli F, Vatanserver S, Ulman C, Yilmaz O, Giray G, Genc A, Taneli C. The effect of spermatic vessel ligation on testicular nitric oxide levels and germ cell-specific apoptosis in rat testis. *Acta Histochem.* 2005; 106:459–66, doi: 10.1016/j.acthis.2004.11.001.
33. Kolettis TM, Kontaras K, Spartinos I, Maniotis C, Varnavas V, Koutouzis M, et al. Dose-dependent effects of sildenafil on post-ischaemic left ventricular function in the rat isolated heart. *J Pharm Pharmacol.* 2010;62:346–51.
34. du Toit EF, Rossouw E, Salie R, Opie LH, Lochner A. Effect of sildenafil on reperfusion function, infarct size, and cyclic nucleotide levels in the isolated rat heart model. *Cardiovasc Drugs Ther.* 2005;19:23–31, doi: 10.1007/s10557-005-6894-2.
35. Das A, Xi L, Kukreja RC. Phosphodiesterase-5 inhibitor, sildenafil preconditions adult cardiac myocytes against necrosis and apoptosis: essential role of NO signaling. *J. Biol. Chem.* 2005;280:12944–55, doi: 10.1074/jbc.M404706200.
36. Ardehali H, O'Rourke B. Mitochondrial K(ATP) channels in cell survival and death. *J Mol Cell Cardiol.* 2005;39:7–16, doi: 10.1016/j.yjmcc.2004.12.003.
37. Koupparis AJ, Jeremy JY, Muzaffar S, Persad R, Shukla N. Sildenafil inhibits the formation of superoxide and the expression of gp47^{phos} NAD(P)H oxidase induced by the thromboxane A2 mimetic, U46619, in corpus cavernosal smooth muscle cells. *British Journal of Urology International.* 2005;96:423–7.
38. Prillman HM, Turner TT. Rescue of testicular function after acute experimental torsion. *J Urol.* 1997;157:340–5.
39. Carden DL, Granger DN. Pathophysiology of ischemia reperfusion injury. *J Pathol.* 2000;190:255–66.
40. Jeremy JY, Shukla N, Muzaffar S, Angelini GD. Reactive oxygen species, vascular disease and cardiovascular surgery. *Current Vascular Pharmacology.* 2004;3:229–36, doi: 10.2174/1570161043385691.