

CASE REPORT

Paroxysmal atrial fibrillation and intermittent left bundle branch block: an unusual electrocardiographic presentation of mad honey poisoning

Ayhan Saritas,¹ Hayati Kandis,¹ Davut Baltaci,¹¹ Ismail Erdem¹¹¹

¹Duzce University School of Medicine, Department of Emergency Medicine, Duzce, Turkey. ¹¹Duzce University School of Medicine, Department of Family Medicine, Duzce, Turkey. ¹¹¹Duzce University School of Medicine, Department of Cardiology, Duzce, Turkey.

Email: a_saritas@hotmail.com

Tel.: 0 380 5421390/5820

INTRODUCTION

Mad honey poisoning occurs through the intake of honey made from the nectar of *Rhododendron* species containing grayanotoxins, a family of lipid-soluble toxins responsible for the clinical manifestations of mad honey intoxication syndrome. These plants grow in the eastern parts of the Black Sea region of Turkey and in various other parts of the world (e.g., South America, Europe, and Japan).¹ Previous reports concerning mad honey poisoning have generally described various degrees of atrioventricular (AV) block, sinus bradycardia, asystole, nodal rhythm with ventricular parasystole, and even acute myocardial infarction.^{2,3} The diagnosis is often made based on a history of honey intake. We report a unique case of a patient who presented paroxysmal atrial fibrillation and intermittent left bundle branch block related to mad honey poisoning.

CASE REPORT

A 70-year-old man was admitted to our emergency department with weakness, palpitation, nausea and vomiting that arose from eating a few teaspoons of mad honey. He did not have any cardiovascular or systemic disease and was not taking any medication. On physical examination, he was confused, his blood pressure was 60/20 mmHg, and his heart rate was 105 beats/min. The neurological examination was normal. Upon admission, his electrocardiography revealed paroxysmal atrial fibrillation and intermittent left bundle branch block (Figure 1). There was no structural cardiac abnormality found from transthoracic echocardiography. His hypotension improved rapidly after saline infusion. During observation, his rhythm returned to a normal sinus rhythm six hours after admission (Figure 2), and he was discharged on the second day of his hospital stay.

DISCUSSION

Grayanotoxins are responsible for the clinical manifestations of mad honey poisoning. These toxins bind to sodium channels in the cell membrane, increasing the permeability of these channels and are thus responsible for inotropy. The signs and symptoms generally may occur within minutes and to up to two hours or more after ingestion.^{1,4,5} Well-known clinical manifestations of mad honey poisoning include hypotension, bradycardia, arrhythmia, loss of consciousness, weakness, nausea, and vomiting. To the best of our knowledge, no case of paroxysmal atrial fibrillation and intermittent left bundle branch block associated with mad honey poisoning has previously been reported.

CONCLUSION

We report a case of a 70-year-old man with severe hemodynamic instability following the ingestion of mad honey and his unusual electrocardiographic manifestations: paroxysmal atrial fibrillation and intermittent left bundle branch block.

REFERENCES

1. Gunduz A, Bostan H, Turedi S, Nuhuğlu I, Patan T. Wild flowers and mad honey. *Wilderness Environ Med.* 2007;18:69–71, doi: 10.1580/06-WEME-LE-042R.1.
2. Aliyev F, Türkoğlu C, Celiker C. Nodal rhythm and ventricular parasystole: an unusual electrocardiographic presentation of mad honey poisoning. *Clin Cardiol.* 2009;32:52–54, doi: 10.1002/clc.20438.
3. Akinci S, Arslan U, Karakurt K, Cengel A. An unusual presentation of mad honey poisoning: acute myocardial infarction. *Int J Cardiol.* 2008;129:56–8, doi: 10.1016/j.ijcard.2007.06.129.
4. Gunduz A, Turedi S, Uzun H, Topbas M. Mad honey poisoning. *Am J Emerg Med.* 2006;24:595–8, doi: 10.1016/j.ajem.2006.01.022.
5. Yilmaz O, Eser M, Sahiner A, Altintop L, Yesildag O. Hypotension, bradycardia and syncope caused by honey poisoning. *Resuscitation.* 2006;68:405–8, doi: 10.1016/j.resuscitation.2005.07.014.

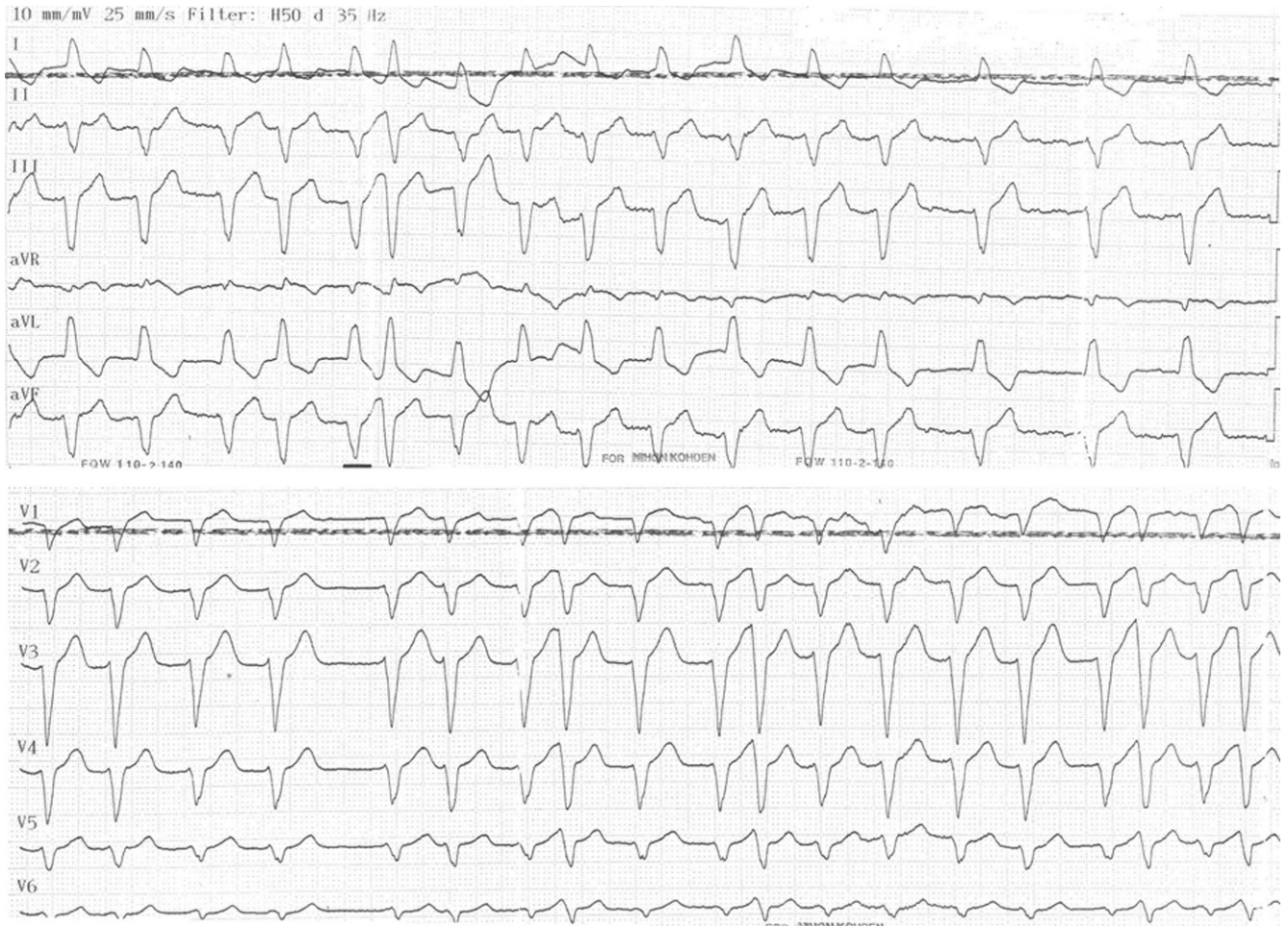

Figure 1 - Paroxysmal atrial fibrillation and intermittent left bundle branch block upon admission.

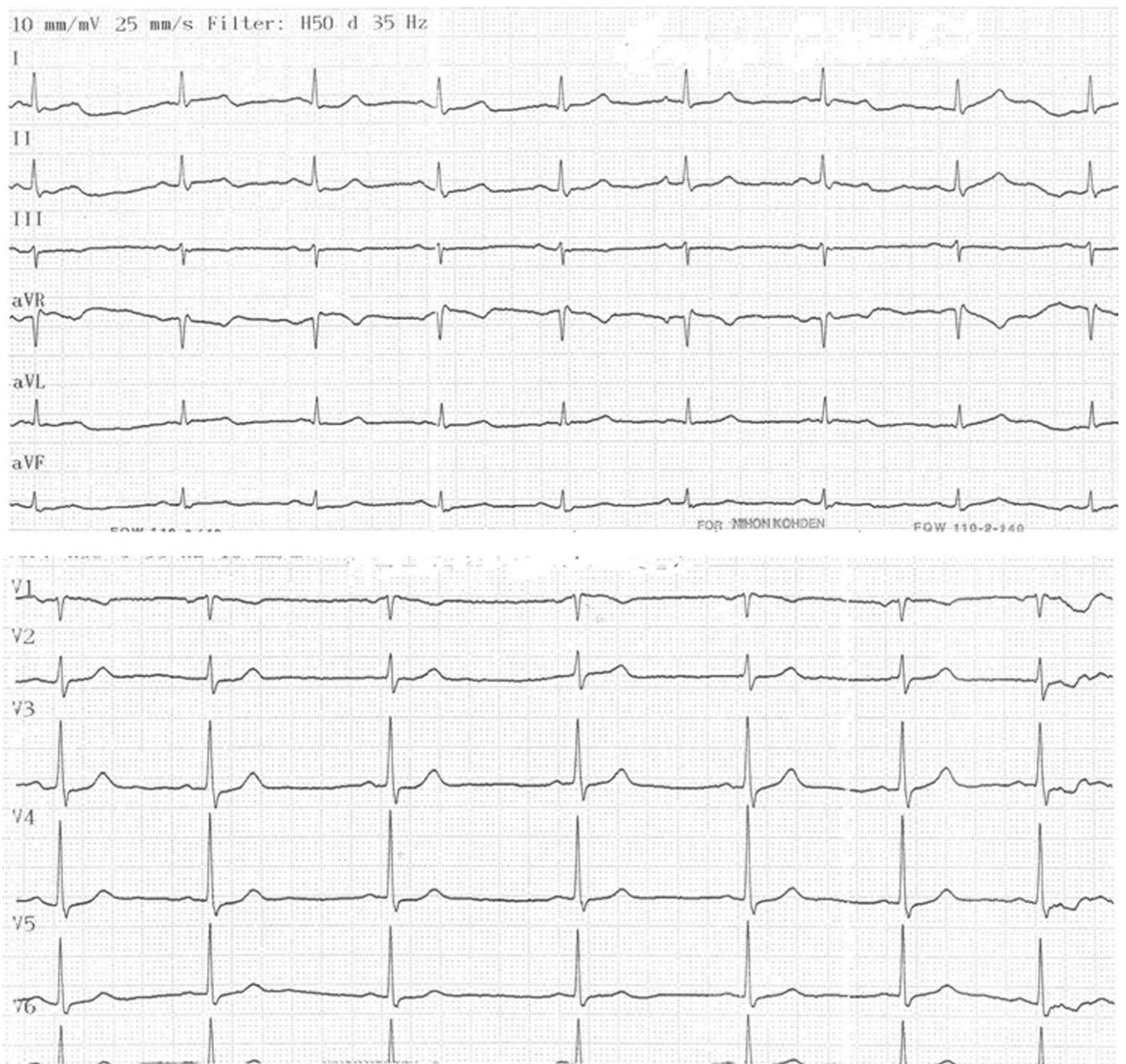


Figure 2 - Normal sinus rhythm 6 hours after admission.