

LETTER TO THE EDITOR

RAPUNZEL SYNDROME OF A COTTON BEZOAR IN A MULTIMORBID PATIENT

Ali Ugur Emre, Oge Tascilar, Guldeniz Karadeniz, Oktay Irkorucu, Kemal Karakaya, Mustafa Comert

INTRODUCTION

Bezoars are foreign bodies that form masses in the gastric or intestinal lumen, particularly in mentally retarded or psychiatric patients.¹ Classifications of bezoars are made according to the content of the bezoar, such as trichobezoars (of hairs), phytobezoars (of vegetable fibers), lactobezoars (of milk products), and others containing medications or other foreign materials.² Whatever the etiology, the usual location of bezoar formation is the stomach; the addition of new materials to this nidus increases the size of the bezoar. On very rare occasions, part of the parent mass extends as a tail into the intestine. Due to the similarity of the tail of the bezoar to the hair of the female prisoner in a fairy tale by the Grimm brothers, this condition has been named the Rapunzel Syndrome.³

CASE DESCRIPTION

An 18 year old male patient with mental and motor retardation was admitted to the emergency department with nausea, vomiting and abdominal pain, followed by loss of consciousness, and was hospitalized in the gastroenterology clinic. He had a fever of over 38.4°C, and an infiltration zone in the chest radiogram diagnosed as aspiration pneumonia. In the history of the patient, there was an episode of esophageal variceal bleeding and hypersplenism ten years previous and generalized tonic-clonic seizures partially controlled with medication. Liver function tests were all normal, but ammonia levels were elevated to as high as 319 µg/dl (normal range: 70-102 µg/dl) on admission. Abdominal ultrasonographic examination revealed a spleen of 155 mm in cranio-caudal length, with a tortoise splenic artery and splenorenal shunt and portal vein thrombosis. A cachectic appearance and hepatosplenomegaly were noted in the physical examination. The laboratory results revealed pancytopenia. Other routine laboratory parameters were normal. Levels of Factor V and VII were low, and a heterozygotic Factor V Leiden mutation was reported.

The patient was admitted to the critical care unit, and

appropriate antibiotic therapy was started. Normal liver function tests other than ammonia levels decreased the probability of chronic liver failure, and an enteral feeding low in protein content was begun as the patient was severely malnourished, with a body mass index of 16.4. The patient's serum albumin level was 2.1 g/dl, and the number of lymphocytes was 800/ml. A nasojejunal tube was inserted, but it was impossible to pass the tube into the jejunum. Intra-gastric feeding was attempted, but was terminated as reflux was observed. On the third day of the hospitalization period, gastric bleeding and melena were observed, and an upper gastrointestinal endoscopy was performed. The feeding tube could not be removed. A giant bezoar filling the stomach and eroding the wall of the stomach was observed. The feeding tube was found to be trapped in the bezoar, which was formed of strings. Grade 1 esophageal varices without bleeding, diffuse erosive gastritis and a deep ulcer at the incisura angularis were noted. The bezoar was observed to continue through the duodenum, and although 35-40 cm of it was retracted, it was not possible to remove the entire length.

The gastric bezoar and the tail, which traveled through the intestine, caused erosions and bleeding of the gastric wall, gastric outlet obstruction, pneumonia due to aspiration of gastric contents and an inability to feed the patient enterally. As the bezoar could not be removed endoscopically, surgery was necessary. The patient was consulted by the surgery department and required serious preparation for comorbidities (pancytopenia, hypersplenism, portal vein thrombosis and factor V deficiency). The possibility of splenectomy was abandoned as the condition could deteriorate due to portal thrombosis. Any intervention to the portal vein thrombosis was avoided, as the general condition of the patient, who exhibited pulmonary sepsis, made this procedure unsuitable.

A gastrotomy was performed with a midline incision to remove the cotton bezoar and the tail (Figure 1, 2). The entire intestinal system was monitored for the presence of other bezoar particles. The cotton bezoar filled the stomach, and the tail was 86 cm long (Figure 3). The clew of cotton forming the bezoar contained some hair and food particles

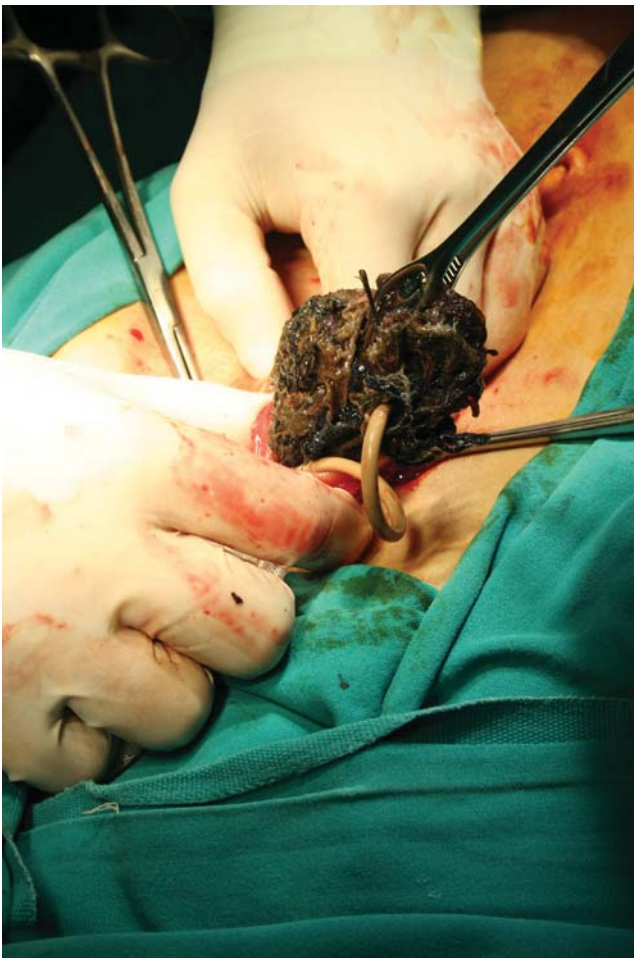

Figure 1 - Cotton bezoar with trapped feeding tube

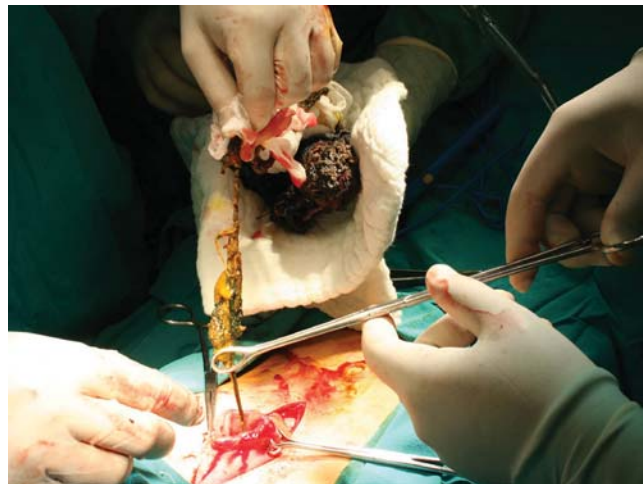


Figure 2 - The tail of the bezoar pulled back from the intestine

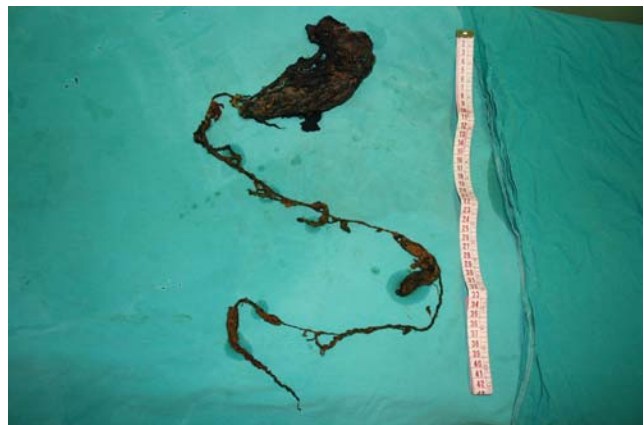

Figure 3 - 86 cm long cotton bezoar

and had a very bad odor. A jejunal catheter was placed for further feeding, and the gastrotomy was closed. A liver biopsy was performed before the closure of the abdomen. Pathological examination of the liver yielded focal steatohepatitis with minimal inflammation. The patient died on the 36th postoperative day due to multiorgan failure after pulmonary sepsis.

DISCUSSION

The term bezoar comes from the Arabic “badzehr”, meaning antidote. Although there are not many articles in the literature concerning bezoars, many are presumed to go unreported. The etiology of bezoar formation is usually the ingestion of indigestible materials, especially by mentally retarded or psychiatric patients. Gastric dysmotility may be another factor.⁴ Most cases involve trichobezoars in young females with trichotillomania, reported in India. Other rare forms include phytobezoars (vegetable fibers), lactobezoars (milk products), pharmacobezoars (drugs) or diospyrobezo-

ars (persimmon fibers). Cotton bezoars are also rare, resulting from the ingestion of strings unraveled from clothes, especially by mentally retarded patients. The strings coil up and mix with mucus and food particles to form a gastric bezoar, and the long strings extend down to the duodenum and intestines, leading to Rapunzel syndrome.

Patients are usually asymptomatic, except if an obstruction or erosion is caused by the mass. On physical examination, a palpable non-tender mass can be found in the epigastric region. Soft cotton strings forming a bezoar can be missed during a physical examination. The mass of a bezoar can lead to epigastric pain due to distention and ulceration, early satiety and loss of weight. In cases of Rapunzel syndrome, a tail present in the intestines can trigger peristaltic movements, resulting in colicky abdominal pain. Gastrointestinal obstruction, bleeding and perforation are rare complications.⁵ Any suspicion of the above symptoms, especially in mentally retarded or psychiatric patients, should

alert physicians to perform an endoscopy, as complications can be life-threatening. Low platelet counts, high bleeding parameters and the masking of comorbidities were the factors leading to the endoscopy on the third day of hospitalization in this patient.

The hyperammonemic coma state in the patient was due to portal vein thrombosis in a non-cirrhotic condition, and episodic type B hepatic encephalopathy has been described in portal-systemic shunts.⁶ Predisposition to thrombosis in deficiencies of factors V and VII of the coagulation cascade was the underlying problem in portal vein thrombosis of the patient.

Treatment of bezoars is their removal, either by enterotomy or by endoscopy, if possible. Large bezoars can be difficult to remove in a one session endoscopy, so fragmentations and removal may be attempted. Enzymatic fragmentation with acetylcysteine may be helpful during endoscopic removal.⁷ Phytobezoars are more sensitive to

pharmacological degradation than trichobezoars. Cellulase, papain, acetylcysteine and carbonated beverages are reported pharmacotherapies for bezoars.⁸⁻¹⁰ However, the main threat arising from attempts to degrade bezoars is the migration of fragments of bezoar to the intestines, which may cause intestinal obstruction or an overlooked intestinal bezoar. The literature recommends multiple enterotomies of the gastrointestinal system in Rapunzel syndrome if gastrotomy is not sufficient to remove all the bezoar.¹¹ Morbidities from surgical intervention are the main disadvantage of this treatment, but the problems due to bezoar mentioned previously can be solved in one surgical session. It is mandatory to explore the whole intestinal system for retained bezoars. Psychiatric treatment of the patients should be instituted in order to avoid recurrent conditions.

The presence of a cotton bezoar extending into the intestinal system is a rare form of Rapunzel syndrome and may be a real problem in patients with multiple pathologies.

REFERENCES

1. Bouwer C, Stein DJ. Trichobezoars in trichotillomania: case report and literature overview. *Psychosom Med.* 1998;60:658-60.
2. Andrus CH, Ponsky JL. Bezoars: classification, pathophysiology, and treatment. *Am J Gastroenterol.* 1988;83:476-8.
3. Vaughan ED Jr, Sawyers JL, Scott HW Jr. The Rapunzel syndrome. An unusual complication of intestinal bezoar. *Surgery.* 1968;63:339-43.
4. Chintamani, Durkhure R, Singh JP, Singhal V. Cotton Bezoar--a rare cause of intestinal obstruction: case report. *BMC Surg.* 2003;4:3-5.
5. Goldstein SS, Lewis JH, Rothstein R. Intestinal obstruction due to bezoars. *Am J Gastroenterol.* 1984;79:313-8.

6. Ferenci P, Lockwood AH, Mullen KD, Tarter RE, Weissenborn K, Blei AT et al. Hepatic encephalopathy— definition, nomenclature, diagnosis, and quantification: final report of the working party at the 11th World Congress of Gastroenterology, Vienna, 1998. *Hepatology*. 2002;35:716-21.
7. Silva FG, Gonçalves C, Vasconcelos H, Cotrim I. Endoscopic and enzymatic treatment of gastric bezoar with acetylcysteine. *Endoscopy*. 2002;34:845.
8. Lee SP, Holloway WD, Nicholson GI. The medical dissolution of phytobezoars using cellulase. *Br J Surg*. 1977;64:403-5.
9. Walker-Renard P. Update on the medicinal management of phytobezoars. *Am J Gastroenterol*. 1993;88:1663-6.
10. Sechopoulos P, Robotis JF, Rokkas T. Gastric bezoar treated endoscopically with a carbonated beverage: case report. *Gastrointest Endosc*. 2004;60:662-4.
11. Duncan ND, Aitken R, Venugopal S, West W, Carpenter R. The Rapunzel syndrome. Report of a case and review of the literature. *West Indian Med J*. 1994;43:63-5.