

## BASIC RESEARCH

---

### NASAL TOLERANCE WITH COLLAGEN V PROTEIN REVERTS BRONCHOVASCULAR AXIS REMODELING IN EXPERIMENTAL BRONCHIOLITIS OBLITERANS

Ana Garippo<sup>1</sup>, Edwin Parra<sup>1</sup>, Walcy Teodoro<sup>2</sup>, Dolores Rivero<sup>1</sup>, Francisca Souza<sup>2</sup>, Natalino Yoshinari<sup>2</sup>, Vera Capelozzi<sup>1</sup>

---

Garippo A; Parra E; Teodoro W; Rivero D; Souza F; Yoshinari N; Capelozzi V. Nasal tolerance with collagen v protein reverts bronchovascular axis remodeling in experimental bronchiolitis obliterans. CLINICS. 2077;62(4):499-506.

**INTRODUCTION:** The precise role of the remodeling process and possible therapies for bronchiolitis obliterans remain to be established.

**OBJECTIVE:** In the present study, we sought to validate the importance of nasal collagen V tolerance to verify whether bronchovascular axis remodeling could be reverted by this therapeutic approach when compared to steroid treatment.

**METHODS:** Mice were randomly divided into 4 groups: control, bronchiolitis obliterans, collagen V tolerance, and prednisone groups. Morphometry was employed to evaluate bronchovascular axis dimensions, collagen density, and immune cell response. Collagen V nasal tolerance and steroid-treated mice showed significantly lower values of terminal bronchiole wall thickness and reduction in peribronchovascular cells; bronchioalveolar lymphoid tissue; and CD3<sup>+</sup>, CD4<sup>+</sup>, CD8<sup>+</sup>, and CD20<sup>+</sup> lymphocytes. A significant decrease in CD68<sup>+</sup> macrophage density was found in prednisone-treated mice. In addition, a strong quantitative relationship was found between collagen V tolerance, and reduction in density of immune cells and collagen.

**RESULTS:** Our results indicate that bronchovascular axis remodeling in bronchiolitis obliterans can be reverted by collagen V nasal tolerance, possibly as the result of T-cell suppression.

**CONCLUSION:** We concluded that the tolerance effects in this model were strongly related to the improvement in bronchovascular remodeling, and these may be an appropriate targets for further prospective studies on nasal collagen V tolerance.

**KEYWORDS:** Bronchiolitis obliterans. Chemical injury. Nasal immunization. Collagen V. Morphometry.

---

## INTRODUCTION

Only a few patients with bronchovascular axis remodeling process following bronchiolitis obliterans respond to treatment.<sup>1</sup> The recognition of possible pathological mechanisms involved in the manifestation of bronchiolitis obliterans might help establish the adequate treatment or definitively block

lung remodeling. Thus, the understanding of the mechanisms in bronchiolitis obliterans remodeling and the treatment effects aiming at preventing irreversible damage and decreased survival are of great interest. Although the exact mechanism of the steroid treatment effect remains unknown, steroid treatment seems to diminish the affluence of immune inflammatory cells and their mediators in animal models of bronchiolitis obliterans, thus affecting collagen synthesis and degradation, interfering with the remodeling of the extracellular matrix. Because active remodeling of the extracellular matrix has been thought to be important in prompting bronchovascular axis restoration, a group of collagens have also been targeted as potentially useful indicators.<sup>2</sup>

Collagen V is a component of the extracellular matrix located in the bronchovascular interstitium, septal

---

<sup>1</sup> Department of Pathology, São Paulo University Medical School- São Paulo/ SP, Brazil

<sup>2</sup> Department of Medicine, Rheumatology, São Paulo University Medical School - São Paulo/SP, Brazil

EMAIL: [vcapelozzi@lim05.fm.usp.br](mailto:vcapelozzi@lim05.fm.usp.br)

Received for publication on March 29, 2007

Accepted for publication on April 26, 2007

---

interstitium, and capillary basement membranes and is surrounded by vascular smooth cells.<sup>3,4</sup> It is a very preserved protein found in many different animal species, and it maintains the NH<sub>2</sub> terminal end, making this molecule more immunogenic.<sup>5</sup> Normally, this protein is not found exposed in the extracellular matrix, as it is hidden among collagen types I and III, composing heterotypic fibers.<sup>4,5</sup> Collagen V tolerance has shown promising results in experimental lung allograft rejection, preventing bronchovascular axis remodeling.<sup>6,7</sup> Other clinical studies have also shown that oral tolerance induced by collagen I, II, and IV has meaningful clinical efficacy in rheumatoid arthritis,<sup>8-10</sup> systemic sclerosis,<sup>11</sup> and glomerulonephritis.<sup>12</sup>

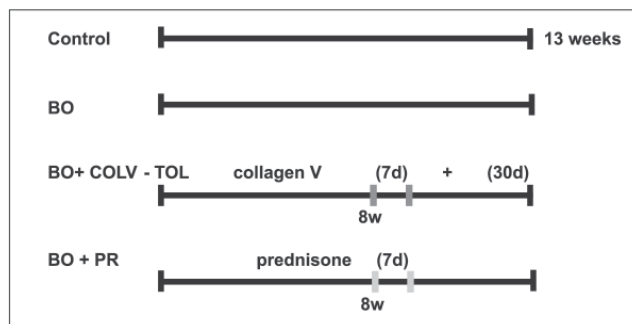
Recently, we have shown an important inflammatory response in bronchiolitis obliterans produced by chemical injury, followed by remodeling of the bronchovascular axis.<sup>13</sup>

The aim of promoting mucosal tolerance is to suppress specific immune reactivity without affecting the entire immunological system by deleting or inactivating specific antigen-driven T-cell clones. We have recently reported immune cell infiltration and broncovascular axis remodeling after nasal instillation of nitric acid in a mouse model of bronchiolitis obliterans.<sup>13</sup> In the present study, we proposed to establish nasal tolerance with collagen V protein in an attempt to ascertain whether the main aspects of bronchiolitis obliterans, including bronchovascular axis remodeling, could be reverted by this therapeutic approach. To evaluate the significance of the effect of nasal tolerance with collagen V protein in bronchiolitis obliterans, we also assessed the effect of steroid treatment on bronchovascular axis remodeling.

## MATERIALS AND METHODS

### Experimental groups

Forty normal female BALB/c mice (4-6 weeks old and 17-26 g) were randomly divided into 4 groups: (i) in the control group, animals did not undergo any procedures (CTRL, n = 10); (ii) in the bronchiolitis obliterans group (BO, n = 10), mice received a single nasal instillation of a solution of 4.8 mmol/mL of HNO<sub>3</sub> 2%, pH 0.1, as previously described;<sup>13</sup> (iii) nasal tolerance was induced in the animals with 8 weeks of bronchiolitis obliterans by daily nasal administrations of 20 ml (0.5 mg/mL/animal/day) collagen V for 7 days and, subsequently, after 30 days on alternate days<sup>7</sup> (BO + COLV-TOL group; n = 10); (iv) animals with 8 weeks of bronchiolitis obliterans were treated with 0.002 mg/animal/day of prednisone for 7 days (BO+PR group; n = 10). Figure 1 shows the experimental design.



**Figure 1** - Experimental Design: (i) group (CTRL): no procedures; (ii) bronchiolitis obliterans group (BO): single nasal HNO<sub>3</sub> solution instillation; (iii) nasal tolerance group (BO+COLV-TOL): induced after 8 weeks of bronchiolitis obliterans by daily nasal administrations of collagen V (7 days) and, subsequently, after 30 days on alternate days; (iv) bronchiolitis obliterans + prednisone group (BO+PR): after 8 weeks of bronchiolitis obliterans, treated with 0.002 mg/animal/day of prednisone for 7 days. At the end of experiments, (13 weeks), lungs were removed and histologically processed.

### Animal preparation

At the end of the experiments, animals were anaesthetized with an intraperitoneal injection of ketamine 1 mL, xylazine 0.25 µl suspended in 3.75 mL saline solution at a concentration of 0.015 mL/g body weight. The animals were exsanguinated, and the thoracic and abdominal cavities were opened and the lungs removed in bloc.

All mice received humane care in compliance with the "Guide for care and use of laboratory animals" (NIH publication 85-23, revised 1985). The study was approved by the institutional review board of our institution, the Council for Research of the School of Medicine, University of São Paulo (CAPPesq).

### Lung histology

Sections representing peripheral areas of the lung were cut and subsequently fixed with 10% formaldehyde for 24 h. After fixation, tissues were paraffin-embedded. Histological sections (3 mm in thickness) were cut and stained with hematoxylin and eosin (H&E) and were evaluated by researchers blinded to the protocol design. As previously described,<sup>10</sup> bronchiolitis obliterans was histologically characterized by bronchovascular axis remodeling that resulted in reduction or total obliteration of the terminal bronchiole lumen, increased wall thickness, deposition of collagen fibers at the peribronchovascular extracellular matrix, and immune cell infiltration.

To evaluate the deposition of collagen fibers at the peribronchovascular axis, collagen was stained in a 0.2% solution of Sirius red (Direct Red 80, C.I. 35780, Aldrich, Milwaukee, WI) dissolved in a saturated aqueous solution

of picric acid, and observed under polarized light microscopy.

Immunohistochemistry analysis was used to evaluate immune cell airway infiltration of the bronchovascular axis as previously described.<sup>13</sup> For the immune cell infiltration markers, we used the following antibodies: CD20, B-Cell (Clone L26, Dako Corporation Carpinteria, USA, 1:600); CD3 (Leu-4, T<sub>3</sub>, 1:600), T-Cell CD4 (CD45RO, clone OPD4, 1:400); CD8 T-Cell (Clone C8/144B, 1:100); Macrophage, CD68 (Clone KP1, 1:3200), Neutrophil Elastase (Clone NP57, 1:800) from Dako A/S Denmark. A secondary procedure using the VECTASTAIN<sup>®</sup> ABC kit (Vector Technologies, Burlingame, CA), which produces a streptavidin-biotin complex, was then performed.

The area of the terminal bronchiole and artery lumen was expressed in  $\mu\text{m}^2$  and comprised the area of wall thickness, including the internal border lumen, epithelial cell height, and basement membrane extending to the outer smooth muscle border. The wall thickness of the terminal bronchiole and artery was determined by the difference between the total area and the lumen area in  $\mu\text{m}^2$ . Immune cell infiltration was evaluated by determining the presence of bronchiole-associated lymphoid tissue (BALT); CD3<sup>+</sup>, CD4<sup>+</sup>, CD8<sup>+</sup>, and CD20<sup>+</sup> lymphocytes; CD68<sup>+</sup> macrophages; neutrophils; and total cells. Collagen density and immune cell infiltration were expressed as percentages.

Morphometric analysis was performed to evaluate the extent and distribution of histological changes that resulted in bronchiolitis obliterans after bronchovascular axis remodeling. The bronchovascular axis includes the terminal bronchiole, terminal artery, and correspondent extracellular matrix. These were measured regarding diameter, wall thickness, collagen, and immune cell densities using an image analysis system (LEICA Qwin Imaging Systems Ltd., Cambridge, England).

The terminal bronchiole and artery diameter present in each sample at (x100) and (x400) magnification, respectively, were measured in 10 random noncoincident microscopic fields using the lengths of the total and transversal areas when the minimum and maximum diameter ratio was greater than 0.6. The wall thickness of the terminal bronchiole and artery was determined by the difference between the total area and the lumen area in  $\text{mm}^2$ . Immune cell infiltration was evaluated for the presence of bronchiole-associated lymphoid tissue (BALT); CD3<sup>+</sup>, CD4<sup>+</sup>, CD8<sup>+</sup>, and CD20<sup>+</sup> lymphocytes; CD68<sup>+</sup> macrophages; neutrophils; and total cells. Collagen density and immune cell infiltration were expressed as percentages.

### Statistical analysis

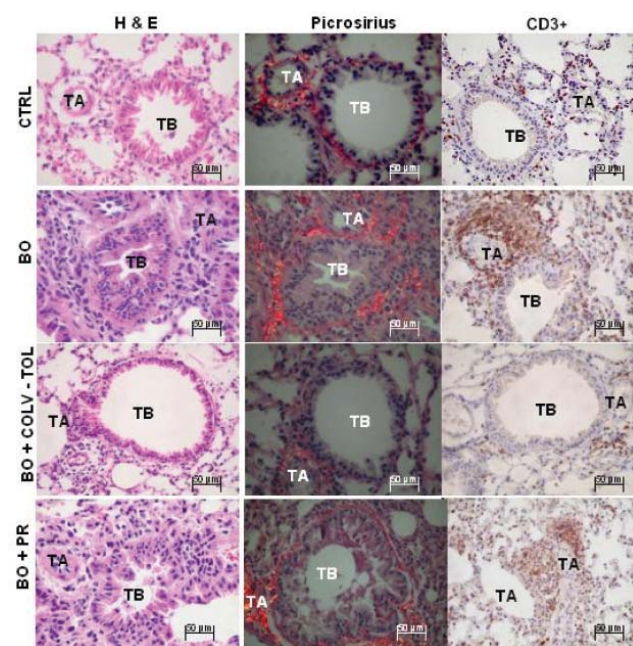
Measurements were expressed as mean  $\pm$  standard de-

viation. All statistical procedures were performed using SPSS software v.13.0 (SPSS, Inc., Chicago, IL 2004). Data were assessed by *t* test and ANOVA with Tukey-HSD or Dunnett-T3 post-hoc tests for multiple comparisons. A *P* value less than .05 was considered statistically significant.

## RESULTS

### Lung histology

Figure 2 shows the bronchovascular axis (terminal bronchiole and matched artery) in the control (CTRL), bronchiolitis obliterans (BO), nasal tolerance with collagen V (BO + COLV-TOL), and prednisone-treated (BO+PR) animals. Tissue is shown treated with H&E stain, picrosirius red under polarized light microscopy, and an immunohistochemical reagent (CD3). In control mice, the bronchovascular axis architecture is preserved, and there is a weak red-orange birefringence of bronchovascular axis tissue sections, coincident with the maintenance of the peribronchovascular extracellular matrix density. In con-



**Figure 2** - Lung histology from the CTRL, BO, BO+COL-TOL, BO+PR groups respectively, stained with H&E and picrosirius, observed under polarized light microscopy, with immunohistochemistry for CD3<sup>+</sup>. CTRL lungs showed reddish birefringence of bronchovascular extracellular matrix, maintenance of lumen and histoarchitecture of terminal bronchiole in H&E preparations. BO lungs showed obliteration or distortion of terminal bronchiole lumen, major immune cell infiltration, and wall distortion, with diffuse increase of birefringence around the periadventitial extracellular matrix. Note intensity of histoarchitecture modification, lumen and immune cell infiltration, with decreased birefringence around periadventitial extracellular membrane in terminal bronchiole of BO+PR and BO+COL-TOL lungs. TB- terminal bronchiole and TA- terminal artery, 400x.

trast, bronchiolitis obliterans animals show a distortion of the bronchovascular axis, with reduction or total obliteration of the lumen, diffuse increase of birefringence, and intense immune cell infiltration in the peribronchovascular extracellular matrix, shown in H&E preparations. Prednisone and collagen V treatments induce a remarkable restoration of the bronchovascular axis architecture and decrease collagen deposition and immune cell infiltration around the bronchovascular axis, which is more intense in animals induced to nasal tolerance with collagen V.

The extension and distribution of the lesions along the bronchovascular axis differed in quantitative terms according to the animal group.

Measurements of the terminal bronchiole, terminal artery, peribronchovascular collagen, and immune cells are shown in Table 1 and illustrated in Figures 3A-C and 4A-C.

Both collagen V and prednisone treatments affect the wall thickness of the bronchovascular axis (terminal bronchiole and artery) (Figure 3A). Reductions were found in the following parameters in the COLV-TOL group compared with the BO group: terminal bronchiole wall thickness ( $P = .002$ ); collagen density in the terminal bronchiole ( $P = .01$ , Figure 3B); density of peribronchovascular cells ( $P = .002$ ); density of BALT in both the terminal bronchiole and the matched artery when compared to bronchiolitis obliterans animals ( $P = 0.002$  and  $P = .01$ , respectively, Figure 3C); density of CD3<sup>+</sup> cells ( $P = .03$ , Figure 4A); density of CD20<sup>+</sup> cells ( $P = .005$ , Figure 4A); and density of CD4<sup>+</sup> cells ( $P = .001$ , Figure 4B). Notable was the

increase in density of CD8<sup>+</sup> cells after collagen V and prednisone treatments when compared with control animals ( $P = .004$  and  $P = .01$ , respectively, Figure 4B). Densities of CD68<sup>+</sup> cells and neutrophils, which were increased in the BO group, did not differ between the collagen V nasal tolerance and prednisone groups (Figure 4C). The total cell density decreased along the bronchovascular axis after collagen V nasal treatment ( $P = .003$ ).

Inter- and intra-observer comparisons were performed in 20% of the slides by 2 observers (ALG and ERP) or by doubling the time of the same observer. The coefficient of variation for the inter- and intra-observer was less than 5%.error

## DISCUSSION

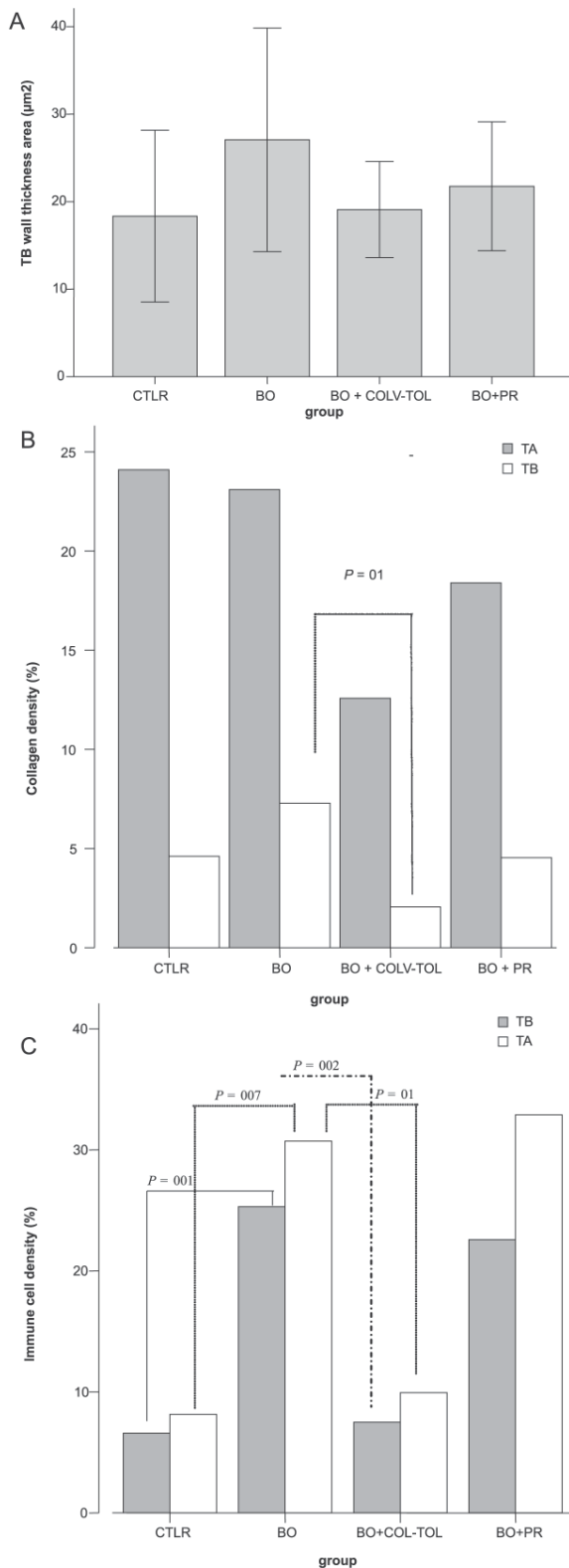
Systemic steroids have been widely employed for infants with acute viral bronchiolitis and young children with acute viral bronchiolitis or adults with bronchiolitis obliterans after transplantation, but the actual benefit of this intervention requires clarification.<sup>14,15</sup> In 13 studies involving 1,198 affected children, no benefits were found for duration of hospital stay, clinical score, or other outcomes.

Patel et al<sup>16</sup> demonstrated that no benefits were found in either bronchiolitis or clinical score in infants and young children treated with systemic steroids as compared with placebo. In addition, marked study heterogeneity and occasionally, conflicting direction of benefit between trials suggest that these results should be interpreted with cau-

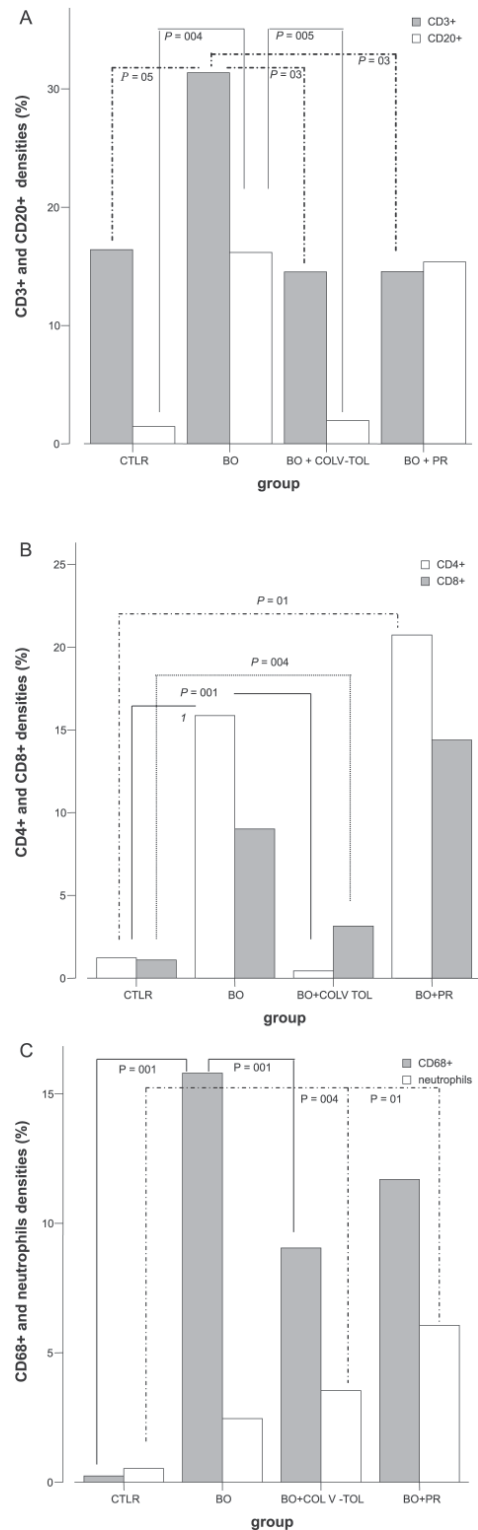
**Table 1** - Measurements of terminal bronchioles, terminal arteries, peribronchovascular collagen, and immune cells in the 4 experimental groups of animals (mean ± SD).

	CTRL	BO	BO + COLV-TOL	BO + PR
TB diameter (µm)	0.83 ± 0.05	0.79 ± 0.07	0.83 ± 0.06	0.77 ± 0.06
TB wall thickness (µm <sup>2</sup> )	18.35 ± 4.90**	27.06 ± 6.39**	19.09 ± 2.75#	21.76 ± 3.68#
TA diameter (µm)	0.86 ± 0.05	0.84 ± 0.06	0.83 ± 0.08	0.80 ± 0.03
TA wall thickness (µm <sup>2</sup> )	3.39 ± 0.82	3.90 ± 0.97	3.16 ± 1.18	6.87 ± 4.29
TB collagen (%)	4.61 ± 0.73	7.28 ± 4.25#	2.05 ± 1.31#	4.54 ± 1.83
TA collagen (%)	24.09 ± 6.91	23.11 ± 9.08	12.57 ± 4.57	18.39 ± 7.16
TB cells (%)	6.60 ± 1.97*	25.30 ± 7.04**	7.50 ± 3.92#	22.58 ± 9.53
TA cells (%)	8.14 ± 1.65#	30.72 ± 11.89#	9.93 ± 4.15#	32.89 ± 13.64
BALT cells (%)	6.23 ± 3.64*	34.65 ± 4.41**	15.24 ± 7.54#	27.32 ± 16.68*
CD3 <sup>+</sup> lymphocytes (%)	16.40 ± 4.38	31.37 ± 10.91#	14.52 ± 11.13#	14.55 ± 4.70#
CD4 <sup>+</sup> lymphocytes (%)	1.23 ± 1.05*	15.87 ± 6.89*	0.44 ± 0.48*	20.74 ± 6.70
CD8 <sup>+</sup> lymphocytes (%)	1.11 ± 1.07#	9.01 ± 5.97	3.15 ± 3.68#	14.39 ± 7.37#
CD20 <sup>+</sup> lymphocytes (%)	1.46 ± 1.89#	16.17 ± 5.35#	1.98 ± 1.87#	15.36 ± 9.74
CD68 <sup>+</sup> macrophage (%)	0.24 ± 0.28*	15.80 ± 4.33*	9.05 ± 5.96*	11.70 ± 13.52
Neutrophils (%)	0.52 ± 0.84#	2.46 ± 1.32	3.54 ± 2.33#	6.06 ± 4.26*
Total cells (%)	20.97 ± 2.92*	90.68 ± 20.24**	32.68 ± 13.55#	82.80 ± 34.49

**Abbreviations:** BALT- bronchiolar associated lymphoid tissue; BO- bronchiolitis obliterans; BO + COLV-TOL- bronchiolitis obliterans + nasal tolerance with type V collagen; BO+PR- bronchiolitis obliterans + prednisone treatment; BV- bronchovascular axis; CTRL- control; TA- terminal artery; TB- terminal bronchiole; Statistical comparisons- ANOVA with Tukey-HSD or Dunnett-T3 post hoc test were compared bronchiolitis obliterans with other groups: \* $P = .001$  and # $P < .05$



**Figure 3-** Quantitative data of TB wall thickness (A), expressed in µm<sup>2</sup>. Collagen density (B) and bronchovascular axis immune cells (C), expressed in (%). Decreased TB area and wall thickness seen in BO+COLV-TOL animals compared to the BO group. Collagen density (B) in TB decreased in the BO+COLV-TOL group compared to BO. Peribronchovascular cell density (D) in TB and matched artery reduced in BO+COLV-TOL animals compared to BO. TB- terminal bronchiole; TA- terminal artery.



**Figure 4 -** Quantitative data of densities (%) of CD3<sup>+</sup> and CD20<sup>+</sup> (A), CD4<sup>+</sup> and CD8<sup>+</sup> (B), and CD68<sup>+</sup> and macrophage (C) immune cells in CTRL, BO, BO+COLV-TOL and BO+PR lungs. Compare CD3<sup>+</sup> cells for TB (A) from BO+COLV-TOL and BO+PR to BO animals. CD20<sup>+</sup> (A) and CD4<sup>+</sup> (B) cells reduced after BO+COLV-TOL, when compared to BO. Note increase in CD8<sup>+</sup> cells (B) in animals receiving the BO+COLV-TOL and BO+PR treatments, vs. CTRL. Density of CD68<sup>+</sup> cells and neutrophils, increased in BO lungs, did not differ between the BO+COLV-TOL and BO+PR (C). TB- terminal bronchiole, TA- terminal artery; BO- (bronchiolitis obliterans).

tion. The variable response to anti-inflammatory treatment could be attributed to the heterogeneous biochemical and molecular mechanisms activated in response to different initial insults.<sup>17,18</sup> Moreover, the inflammatory mechanisms are continuous and cyclic, sometimes causing deterioration or improvement in lung function. Other major continuing problems include determining when to administer prednisone, monitoring its use, and determining what other therapy it should be compared with.<sup>16</sup> Hence, the aim of the present study was to compare collagen V nasal tolerance with a traditional therapeutic approach, such as prednisone, in an experimental bronchiolitis obliterans model.

Clearly, the likely reason for failure of treatment to cure some patients with bronchiolitis obliterans is due to the irreversible scarring of the bronchovascular axis, which is not detected by either routine imaging or routine pathological analysis.

The question of interest is whether additional, more technological information obtained from histopathological assessment can help us identify patients with bronchiolitis obliterans who are likely to present scarring of the bronchovascular axis and, consequently, poor response to treatment, thus helping improve long-term function and prevent the cumulative morbidity.<sup>19</sup>

The inflammation/repair processes that occur in bronchiolitis obliterans undoubtedly comprise a series of complex, sequential steps; however, among these, the immune system is thought to be especially important, due to its interaction with the extracellular matrix remodeling.<sup>15</sup>

Type V collagen fulfills all the criteria of a fibrillar collagen: both N- and C-termini are processed, and it consists of an approximately 1000-amino acid chain, thus controlling fibrillogenesis and making it more immunogenic.<sup>20</sup>

Despite being a quantitatively minor collagen, collagen V is fundamental not only for regulation of fibril diameter of other collagen types, but also for the integrity of connective tissues.<sup>21</sup> Whereas prior studies<sup>4-7</sup> were able to show a significant relationship between lung transplantation and collagen V tolerance, our results suggested that nasal collagen V tolerance could be used to interrupt the bronchiolitis obliterans process, reducing collagen deposition and T- and B-cell reactivity.

Although the precise mechanisms for daily sampled antigens in the bronchial epithelia induction are still unclear, collagen V treatment of lung diseases that develop with fibrosis may be promising. Presumably, when collagen V immunization is carried out by the nasal route, it may reach the lymphoid tissue associated with the nasal mucosa, where it is processed and then locally presented to T cells so they can induce pro-inflammatory as well as suppressive immune responses<sup>4-7</sup> in the pre-acinar axis.

In a variety of situations, oral and nasal induction to collagen may stabilize experimental,<sup>8,22</sup> and human arthritis,<sup>10</sup> systemic sclerosis,<sup>23</sup> and osteoarthritis.<sup>24</sup>

Our data are both interesting and important and continue the studies of Dr. David Wilkes' group, which have previously documented that collagen V-induced oral tolerance prevents bronchiolitis obliterans after rat lung allografts.<sup>4-7</sup>

Considering these facts, we were not surprised to learn that collagen V nasal tolerance could revert the bronchovascular axis remodeling in bronchiolitis obliterans, and our results have now confirmed the importance of this therapeutic approach.

A beneficial effect of low doses of orally or nasally administered collagen types I and II has also been demonstrated as an immunotherapeutic intervention for arthritic joints.<sup>8-10</sup>

We have also observed that collagen V and prednisone treatments reduced peribronchovascular cells and BALT in both the terminal bronchiole and matched artery when compared to control animals.

Regarding collagen fibers in the terminal bronchiole, we observed that collagen V treatment resulted in a decrease in this response compared with control animals. Most interesting was the strong, quantitative relationship observed between tolerance and reduction in density of immune cells and collagen. Although a variety of associations between prednisone and lung remodeling have been described recently,<sup>15,25</sup> we observed that its relationship with immune cells and collagen density was not as strong as that observed for collagen V tolerance.

In fact, we found that collagen V treatment reduced densities of CD3<sup>+</sup>, CD4<sup>+</sup>, CD20<sup>+</sup>, and CD68<sup>+</sup> cells. Not only has tolerance been thought to dramatically reduce immune cell response and thus protect the host from deleterious cytokine effects, but it has also been thought to regulate extracellular matrix synthesis and degradation.<sup>8</sup>

Of interest was our finding of an increase in density of CD8<sup>+</sup> lymphocytes in animals with untreated bronchiolitis obliterans when compared with control animals and a decrease after collagen V treatment, suggesting that collagen V nasal tolerance induces significant, prompt restoration of the bronchovascular axis, possibly as the result of T-cell suppression. It has been postulated that CD8<sup>+</sup> T suppressor cells can be induced by exposure to an antigen.

When stimulated, CD8<sup>+</sup> T suppressor cells also suppress immune system responses. The B-cell population is "tolerated" through clonal deletion, anergy and/or sequestering of antigens within an organ.<sup>26</sup> Where T-cell help is required to activate B cells exposed to thymus-dependant antigens, suppression of the T helper CD4<sup>+</sup> cell population will pre-

vent possible autoantibody production.<sup>27,28</sup> It is well known that a decrease in B- and T-cell reactivity induced by collagen V tolerance can prevent bronchiolitis obliterans in lung transplantation.<sup>4,29</sup>

At present, we have demonstrated that there is an association between tolerance and reduction in immune cell infiltration and restoration of the bronchiole dimension in bronchiolitis obliterans caused by chemical injury. Thus, decreased immune cell infiltration may be more of a primary event, and bronchovascular axis remodeling, more of a secondary event. Regardless of the mechanism, immune cell infiltration and collagen density provide important morphological information in experimental bronchiolitis obliterans.

Finally, randomized and prospective trials will be required, since we believe it is important to validate our therapeutic assessment of collagen V nasal tolerance as well as to extend it to other lung diseases by studying additional

patients. We conclude that the effects of collagen V nasal tolerance in bronchiolitis obliterans induced by chemical injury were strongly related to the improvement in bronchovascular axis remodeling. Lungs with increased immune cell and collagen density around the peribronchovascular axis comprise a subset with a high risk of irreversible scarring and may be an appropriate target for prospective studies of collagen V tolerance. The collagen V therapeutic approach may be especially important in patients who are resistant to steroids.

#### ACKNOWLEDGMENTS

The authors would like to thank the Laboratory Animal Facility, Lim-51, and Maria Cristina Medeiros for expert assistance in the histological preparation and the Department of Pathology of the University of São Paulo School of Medicine for excellent technical assistance.

#### RESUMO

Garippo A; Parra E; Teodoro W; Rivero D; Souza F; Yoshinari N; Capelozzi V. Tolerância nasal com a proteína colágeno V reverte o remodelamento no eixo broncovascular na bronquiolite obliterante experimental. CLINICS. 2007;62(4):499-506.

**INTRODUÇÃO:** A participação precisa do processo de remodelamento e possíveis implicações no tratamento da bronquiolite obliterante ainda não está estabelecida.

**OBJETIVOS:** Estabelecer a importância da tolerância nasal induzida pelo colágeno do tipo V e verificar se o processo de remodelamento do eixo broncovascular pode ser revertido com esta estratégia terapêutica comparada ao efeito do tratamento com esteróides.

**MATERIAL E MÉTODO:** Camundongos foram divididos em quatro grupos: controle, bronquiolite obliterante, tolerância nasal com colágeno do tipo V e prednisona. Morfometria foi realizada para avaliar as dimensões do eixo broncovascular, densidade de colágeno e resposta imunocelular. Camundongos submetidos à tolerância nasal com colágeno do tipo V e tratados com prednisona exibiram significativas re-

duções da espessura da parede de bronquíolos terminais, da densidade de células inflamatórias ao redor do eixo peribroncovascular e da resposta imunocelular às custas de linfócitos CD3, CD4, CD8 e CD20. Houve também significativa redução da densidade de macrófagos CD68 nos camundongos tratados com prednisona. Adicionalmente, houve uma forte associação entre tolerância nasal induzida pelo colágeno do tipo V, resposta imunocelular e redução do conteúdo de colágeno peribroncovascular.

**RESULTADOS:** O remodelamento do eixo broncovascular na bronquiolite obliterante pode ser revertido pela indução de tolerância nasal com o colágeno do tipo V, possivelmente como resultado de supressão de linfócitos T.

**CONCLUSÃO:** Os efeitos da tolerância nasal no presente modelo estiveram fortemente relacionados à melhora no remodelamento do eixo broncovascular, despontando como um alvo promissor para estudos prospectivos.

**UNITERMOS:** Bronquiolite obliterante. Lesão química. Imunização nasal. Colágeno V. Morfometria.

## REFERENCES

1. King VJ, Viswanathan M, Bordley WC, Jackman AM, Sutton SF, Carey TS. Pharmacologic treatment of bronchiolitis in infants and children: a systematic review. *Arch Pediatr Adolesc Méd.* 2004;158:127-37.
2. Niyibizi C, Fietzek, Rest M. Human placenta type V collagens. Evidence for existence of a  $\alpha 1(V)$ ,  $\alpha 2(V)$ ,  $\alpha 3(V)$ . *J Biol Chem.* 1984;259:14170-4.
3. Madri J A and Furthmayr H. Collagen polymorphism in the lung. An immunochemical study of pulmonary fibrosis. *Hum Pathol.* 1980;11:353-66.
4. Yoshida S, Haque A, Mizobuchi T, Iwata T, Chiyo M, Webb TJ, et al. Anti-type V collagen lymphocytes that express IL-17 and IL-23 induce rejection pathology in fresh and well-healed lung transplants. *Am J Transplant.* 2006; 6:724-35.
5. Mares DC, Heidler KM, Smith Jr GN, Cummings OW, Harris ER, Foresman BH, et al. Type V collagen modulates alloantigen-induced pathology and immunology in the lung. *Am J Respir Cell Mol Biol.* 2000;23:62-70.
6. Haque MA, Mizobuchi T, Yasufuku K, Fujisawa T, Brutkiewicz R, Zheng Y, et al. Evidence for immune responses to a self-antigen in lung transplantation: role of type V collagen-specific T cells in the pathogenesis of lung allograft rejection. *J Immunol.* 2002;169:1542-9.
7. Yasufuku K, Heidler KM, Woods KA, Smith Jr GN, Cummings OW, Fujisawa T, et al. Prevention of bronchiolitis obliterans in rat lung allograft by type V collagen-induced oral tolerance. *Transplantation.* 2002;73:500-5.
8. Garcia G, Komagata K, Slavin AJ, Maron Ruth, Weiner, HL. Suppression of collagen-induced arthritis by oral or nasal administration of type II collagen. *J Autoimmun.* 1999;13:15-24.
9. Meyer O. Oral immunomodulation therapy in rheumatoid arthritis. *Joint Bone Spine* 2000;67:384-92.
10. Myers LK, Higgins GC, Findel TH, Reed AM, Thompson JW, Walton RC, et al. Juvenile arthritis and autoimmunity to type II collagen. *Arthritis Rheum.* 2001;44:1775-81.
11. Mckown KM, Carbone LD, Bustillo J, Seyer JM, Kang AH & Postlethwaite AE. Induction of immune tolerance to human type I collagen in patients with systemic sclerosis by oral administration of bovine type I collagen. *Arthritis Rheum* 2000;43:1054-61.
12. Reynolds J, Prodromidi EI, Juggapah JK, Abbott DS, Holthaus KA, Kalluri R, et al. Nasal administration of recombinant rat  $\alpha 3(IV)$  NC1 prevents the development of experimental autoimmune glomerulonephritis in the WKY rat. *J Am Soc Nephrol.* 2005 May;16:1350-9.
13. Garippo AL, Parra ER, Teodoro WR, Veloza AP, Yoshinari NH, Capelozzi VL. Immune cell infiltration and bronchovascular remodeling after nitric acid nasal instillation in a mouse bronchiolitis obliterans model. *Lung.* 2006;184:229-38.
14. Daniels CE, Myers JL, Utz JP, Markovic SN, Ryu JH. Organizing pneumonia in patients with hematologic malignancies: A steroid-responsive lesion. *Respir Med. Respir Med.* [published online ahead of print May 15, 2006] 2007;101:162-8.
15. Fernandes ABS, Zin WA, Rocco PMR. Corticosteroids in acute respiratory distress syndrome. *Braz J Med Biol Res.* 2005;38:147-159 . Review.
16. Patel H, Platt R, Lozano JM, Wang EE. Glucocorticoids for acute viral bronchiolitis in infants and young children. *Cochrane Database of Systematic Reviews* 2004, Issue 3. Art. No.: CD004878. DOI: 10.1002/14651858.CD004878.
17. Halna M, Leblond P, Aissi E, Dumonceaux A, Delepouille F, El Kohen R, Hue V, Martinot A. Impact of the consensus conference on the ambulatory treatment of bronchiolitis in infants. *Presse Med.* 2005;34:277-81.
18. Scarfone RJ. Controversies in the treatment of bronchiolitis. *Curr Opin Pediatr.* 2005;17:62-6.
19. Smyth RL and Openshaw PJ. Bronchiolitis. *Lancet.* 2006;368:312-22.
20. Wenstrup RJ, Florer JB, Brunskill EW, Bell SM, Chervonevai I, Birk DE. Type V collagen control the initiation collagen fibril assembly. *J Biol Chem.* 2004;279:53331-7.
21. Kelley J. Collagen. *Lung Cell Biology.* New York: Marcel Dekker Inc; 1991. Cap 17, p. 821-58.
22. Higuchi K, Kweon MN, Fujihashi K, McGhee JR, Kiyono H. Comparison of nasal and oral tolerance for the prevention of collagen induced murine arthritis. *J Rheumatol.* 2000;27:1039-44.
23. Wan-Uk K, Woo-Kyoung L, Jae-Woong R, Seung-Hoon K, Ho-Youn K. Suppression of collagen-induced arthritis by single administration of poly(lactin-co-glycolic acid) nanoparticles entrapping type II collagen. *Arthritis Rheum.* 2002;46:119-20.
24. Stancikova M, Stancik R, Gubzova Z, Rovensky J. Collagen in the treatment of rheumatic diseases-oral tolerance. *Bratisl Lek Listy.* 1999;100:567-71.
25. Kurland G and Michelson P. Bronchiolitis in children. *Pediatr Pulmonol.* 2005;39:193-208.
26. Faria AMC and Weiner HL. Oral tolerance: mechanisms and therapeutic applications. In: Dixon, FG, editor. *Advances in Immunology*, 73. Elsevier; Amsterdam: 1999. p. 153-264.
27. Hoyne GF. Immunological tolerance to inhaled antigen. *Am J Respir Crit Care Med.* 2000;162(4 Pt 2):S169-74.
28. Novak N, Allam JP, Betten H, Haberstok J, Bieber T. The role of antigen presenting cells at distinct anatomic sites: they accelerate and they slow down allergies. *Allergy.* 2004;59:5-14.
29. Bharat A, Fields RC, Steward N, Trulock EP, Patterson GA, Mohanakumar T. CD4+25+ regulatory T cells limit Th1-autoimmunity by inducing IL-10 producing T cells following human lung transplantation. *Am J Transplant.* 2006;6:1799-808.