

---

**LETTER TO THE EDITORS**

---

**PEMPHIGUS VEGETANS ASSOCIATED WITH  
VERRUCOUS LESIONS - EXPANDING A PHENOTYPE**

---

Hiram Larangeira de Almeida Jr., Maria Gertrudes Pereira Neugebauer, Isabelle Maffei Guarenti, and Valéria Aoki

---

Pemphigus vegetans (PV), a variant of pemphigus vulgaris, is the rarest form of pemphigus, accounting for 2% of patients with this class of disease in Sicily,<sup>1</sup> 3.3% in Mali,<sup>2</sup> and 5.7% in Tunisia.<sup>3</sup> It is an autoimmune disease, characterized by flaccid bullae or pustules that erode to form hypertrophic papillated plaques involving predominantly skin folds, scalp, face, and mucous membranes.<sup>4</sup> Nail involvement is seldom described. We report a case of pemphigus vegetans with typical skin fold involvement, nail dystrophy with verrucous paronychia, and acral verrucous lesions.

A 65-year-old white woman, in treatment for diabetes mellitus and hyperthyroidism for years, complained of flare-ups of erosions on the oral mucosa, explained by the use of dentures. Biopsy of the oral mucosa was performed and evaluated as inconclusive. After some weeks, additional erosions in the genital mucosa and perianal region were observed. Since the probable initial diagnosis was of Stevens-Johnson's syndrome, she was placed on steroid therapy, antibiotics, and volume and electrolytic replacement, which controlled her condition. After reduction and withdrawal of the steroids, she presented a worsening of her skin disease with vegetations in inframammary, axillary, and inguinal folds (Figure 1). The patient's vermillion of the lips had a verrucous appearance (Figure 2). She also had hyperkeratotic plaques on the borders of both feet (Figure 2), as well as verrucous paronychia of the 20 nails (Figure 3) with pachyonychia and onychorrhexis.

Laboratory tests were normal. Some flaccid blisters or blister traces could be also seen (Figures 1 and 3).

Histology of a vegetating lesion from a skin fold revealed a suprabasal cleft with acantholytic cells; from a verrucous acral lesion, epithelial hyperplasia with microabscesses composed of eosinophils, neutrophils, and some acantholytic cells (Figure 4). The first histologic ex-

amination of the oral lesion was reviewed, and a suprabasal cleft was found (Figure 4).

Indirect immunofluorescence was performed as follows: Sera samples in serial dilutions were incubated for 30 minutes with tissue cryosections on albuminized slides. Two 20-minute-washes with trisma base solution, calcium-enhanced, pH 7.5 (TBS-Ca<sup>++</sup>) were performed, followed by incubation for 30 minutes with conjugates (fluorescein-antihuman immunoglobulins G, A, M, and C3 fractions, SIGMA, USA), at a 1:20 dilution in TBS-Ca<sup>++</sup>. Two final washes with TBS-Ca<sup>++</sup> were performed, and an epiluminescence microscope HBO50W (CB12 filter) (Zeiss, Germany) was used for the reading. Indirect immunofluorescence showed intercellular deposition of IgG4 and IgG1 antibodies at a titer of 1:2560 and 1:20, respectively.

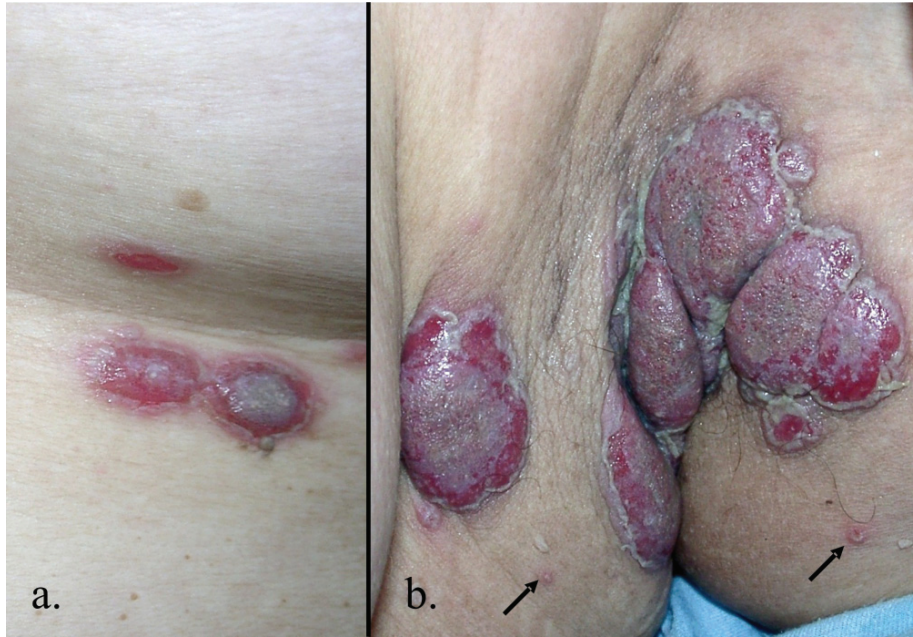Systemic corticosteroid (prednisone 80 mg/day) therapy was reintroduced associated with dapsone (100 mg/day), with a good response.

Historically, cases of pemphigus vegetans have been divided into 2 clinical subclasses: the Hallopeau type and the Neumann type. The first starts with circumscribed pustules and has a relatively benign course; in contrast, the Neumann type has vesicles and bullae as primary lesions, is usually more frequently seen and develops extensive lesions that are often refractory to therapy.<sup>5</sup> The diagnosis of pemphigus vegetans is based on clinical manifestations and confirmed by histology. Involvement of the vermillion border of the lips is the clinical hallmark of oral involvement. Proliferative growth begins at the sites of pustules or bullae that erode, and it gradually becomes vegetative and hypertrophic.<sup>6</sup> These verrucous lesions can be clinically similar to common warts<sup>7</sup> or they may evolve into vegetating masses up to several centimeters in diameter, with fresh vesicles or pustules at the periphery of the lesion.<sup>6</sup> Both circumstances were present this case. Nail involvement in pemphigus is rare; it has been described in pemphigus vulgaris in a variety of manifestations: chronic paronychia, onychomadesis, onycholysis, Beau's lines, trachyonychia, subungual hemorrhage, nail dystrophy, and vegetative lesions over paronychia.<sup>7,8</sup>

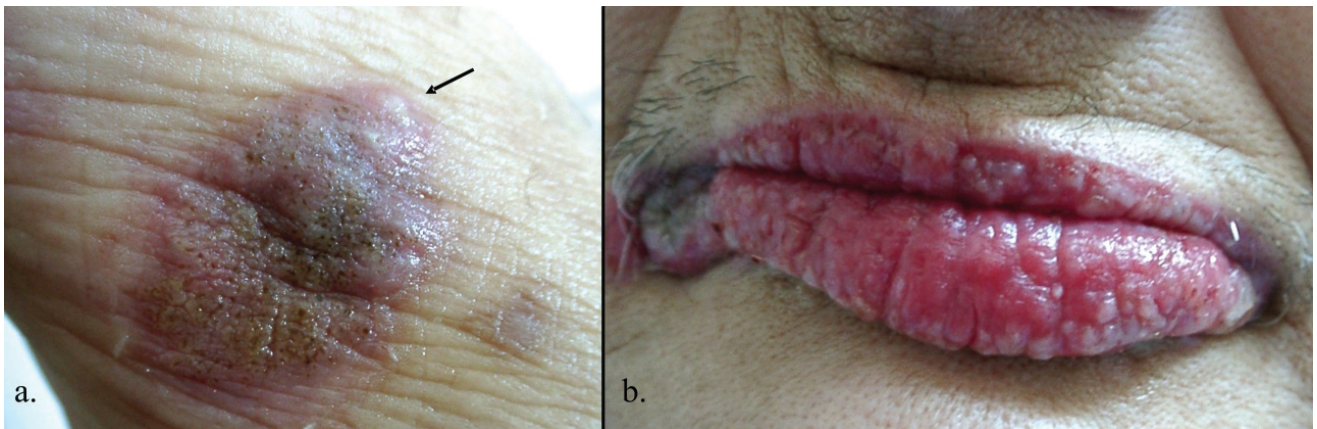
---

Federal University of Pelotas - Pelotas/RS, Brazil.  
Catholic University of Pelotas - Pelotas/RS, Brazil.  
São Paulo University Medical School - São Paulo/SP, Brazil.  
Email: hiramalmeidajr@hotmail.com

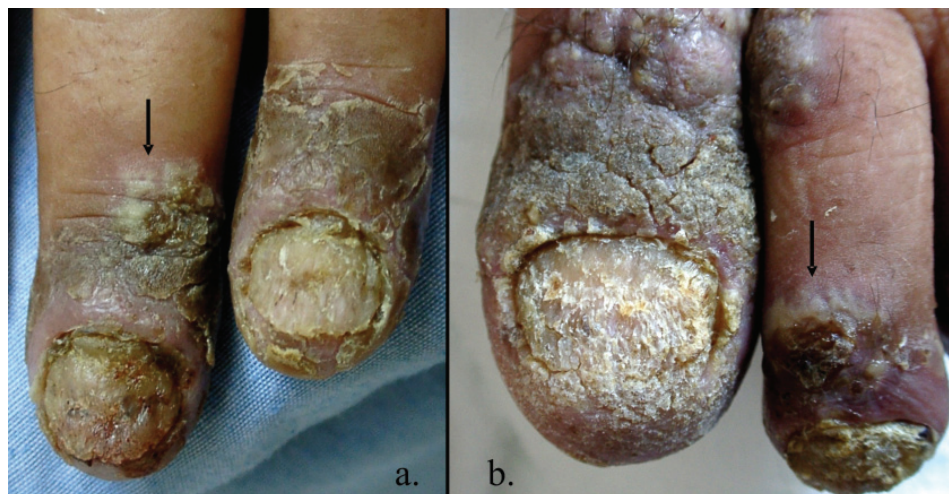---



**Figure 1** - a. vegetating plaques on the inframammary fold. b. similar lesions in the axillary fold with two small blisters (arrows)

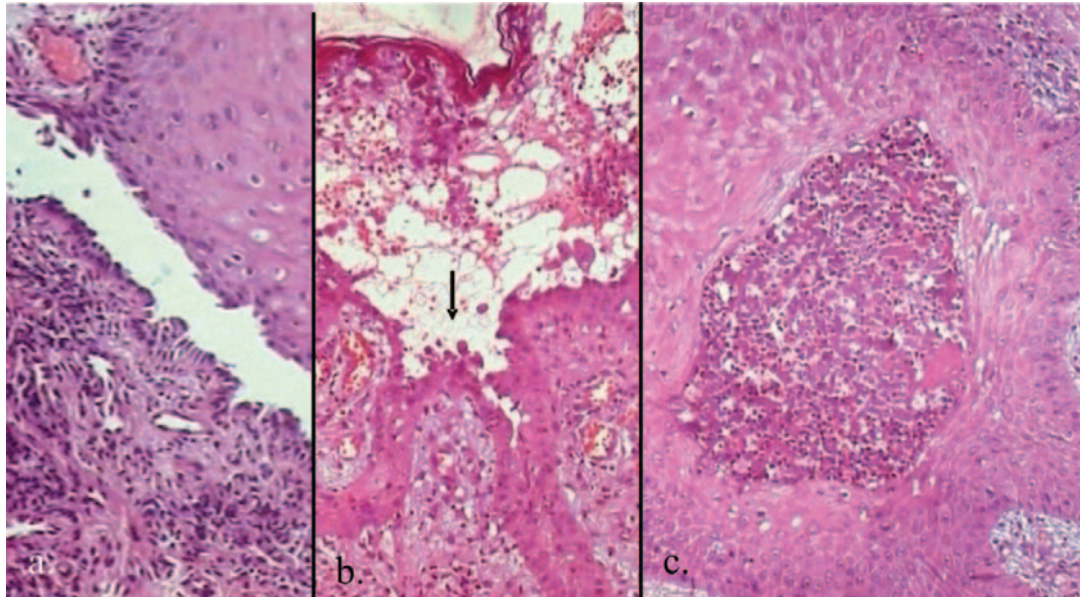


**Figure 2** - a. verrucous plaque on the right foot, note the pustule on the periphery (arrow) b. verrucous aspect of the lips



**Figure 3** - a. verrucous paronychia with dystrophic finger nail b. similar aspect of the hallux. Note the rest of some flaccid bullae (arrows)





**Figure 4** - Light microscopy a. suprabasal cleft in the oral mucosa. b. suprabasal cleft and acantholytic cells (arrow) from a vegetant lesion. c. epithelial hyperplasia with neutrophil abscess from a verrucous acral lesion

Histological findings, such as epithelial hyperplasia, suprabasal cleft and acantholytic cells, as well as microabscesses composed of eosinophils and neutrophils, are the main characteristics, as seen in this patient.<sup>6,9</sup>

Immunofluorescence techniques have proved to be important in the differential diagnosis of bullous disorders and the pemphigus group has the classical intercellular pattern.

The most important differential diagnosis is the Pyodermitis-pyostomatitis vegetans, which has similar clinical and histological manifestations, but has negative immunofluorescence results.<sup>10</sup>

Because of the mucosal involvement, the first clinical diagnosis made was of Stevens-Johnson's syndrome, a severe expression of erythema multiforme that involves the skin and the mucous membranes, which is an important differential diagnosis of bullous disorders. The association of PV with lung neoplasia has already been reported.<sup>11</sup>

Treatment of PV often involves the use of immunosup-

pressive agents, and steroids have been the mainstay of clinical management. However, oral administration of corticosteroids alone does not always induce disease remission.<sup>12</sup> In the literature reviewed, the association of systemic steroid therapy with azathioprine, dapsone, cyclophosphamide, and cyclosporine as effective treatment has been described. When it comes to persistent, verrucous vegetations, the combination of corticosteroid and etretinate resulted in healing of the lesions.<sup>12</sup> Moreover, the association of methotrexate, dicloxacillin, oral steroids, and periodic intralesional corticosteroid injections were effective in a relatively resistant scalp disease.<sup>13</sup>

The vermilion and nail involvement, as well as the verrucous, hyperkeratotic acral plaques seen in this patient were also described in other cases of pemphigus vulgaris/vegetans,<sup>6-8</sup> and these should be considered, together with the classical vegetant lesions in the skin folds, characteristic of the verrucous variant of this condition.

## REFERENCES

- Micali G, Musumeci ML, Nasca MR. Epidemiologic analysis and clinical course of 84 consecutive cases of pemphigus in eastern Sicily. *Int J Dermatol.* 1998;37:197-200.
- Mahé A, Flageul B, Cissé I, Kéita S, Bobin P. Pemphigus in Mali: a study of 30 cases. *Br J Dermatol.* 1996;134:114-9.
- Haouet H, Ben Hamida A, Haouet S, Chaffai M, Ben Osman A. Le Pemphigus Tunisien-A propos de 70 cas. *Ann Dermatol Venereol.* 1996;123:9-11.
- Downie JB, Dicostanzo DP, Cohen SR. Pemphigus vegetans-Neumann variant associated with intranasal heroin abuse. *J Am Acad Dermatol.* 1998;39:872-5.
- Ohata Y, Komiya H, Kawahara Y, Watanabe K, Nishikawa T, Hashimoto T. A case of Neumann type pemphigus vegetans showing reactivity with the 130 kD pemphigus vulgaris antigen. *Acta Derm Venereol.* 1995;76:169-70.

6. Woo TY, Solomon AR, Fairley JA. Pemphigus vegetans limited to the lips and oral mucosa. *Arch Dermatol.* 1985;121:271-2.
7. Mascarenhas R, Fernandes B, Reis JP, Tellechea O, Figueiredo A. Pemphigus vulgaris with nail involvement presenting with vegetating and verrucous lesions. *Dermatol Online J.* 2003;9:14.
8. Cahali JB, Kakuda EYS, Santi CG, Maruta CW. Nail manifestations in pemphigus vulgaris. *Rev Hosp Clín Fac Med S Paulo.* 2002;57:229-34.
9. Jansen T, Messer G, Meurer M, Plewig G. Pemphigus vegetans. A historical perspective. *Hautarzt.* 2001;52:504-9.
10. Mehravaran M, Kemény L, Husz S, Korom I, Kiss M, Dobozy A. Pyodermatitis-pyostomatitis vegetans. *Br J Dermatol.* 1997;137:266-9.
11. Serwin AB, Bokinić E, Chodyncka B. Pemphigus vegetans in a patient with lung cancer *Dermatology Online Journal.* 2005; 11:13.
12. Ichimiya M, Yamamoto K, Muto M. Successful treatment of pemphigus vegetans by addition of etretinate to systemic steroids. *Clin Experim Derm.* 1998;23:178-80.
13. Rackett SC, Rothe MJ, Hoss DM, Grin-Jorgensen CM, Grant-Kels JM. Treatment-resistant pemphigus vegetans of the scalp. *Int J Dermatol.* 1995;34:865-6.