

Biomarker responses (serum biochemistry) in pregnant female wistar rats and histopathology of their neonates exposed prenatally to pesticides

Jyoti Upadhyay¹, Mahendra Rana^{1*}, Satpal Singh Bisht², Amita Rana¹,
Sumit Durgopal¹, Vijay Juyal¹

¹Department of Pharmaceutical Sciences, Kumaun University, Campus Bhimtal, Nainital Uttarakhand, India, ²Department of Zoology, D. S. B. Campus, Kumaun University, Nainital, Uttarakhand

Experiments were conducted to investigate the effects on health of pregnant female rats exposed to pesticides glyphosate and carbendazim. Glyphosate is used as herbicide and carbendazim as a fungicide; all are commercially available readily for various agricultural and domestic purposes. The hypothesis tested in this investigation is that pesticide exposure during pregnancy causes changes in biomarker responses like serum glucose level, total protein, total cholesterol, triglycerides, SGOT, SGPT, and bilirubin level. Significant changes were observed in all above biomarker responses, when compared with the reference. Histopathology of skin and kidney of rat neonates showed marked damage. Degenerative changes and vacuolization with eroded capsule were observed in kidney sample and thinning of epidermis in skin sample was seen in pesticides exposed neonates of rats. The serum biochemistry and histopathological findings are valuable markers for observing the changes caused by pesticide exposure.

Keywords: Glyphosate, Carbendazim. Biomarker responses. Biomarkers/ analysis. Pesticide exposure/ histopathology. Newborn/ histopathology. Herbicides/ toxicity.

INTRODUCTION

Pesticides are ubiquitous substances which are highly lipid soluble, resistant to metabolism and get accumulated in the human body. It covers a wide range of compounds like insecticides, herbicides, fungicides and other plant growth regulators (Cope *et al.*, 2004). The exposure to pesticides is a major public health issue globally, but they have played a vital role in controlling agricultural, home, industrial pest worldwide (Rabideau, 2001; Bjørling-Poulsen *et al.*, 2008). Pesticides are widespread in the environment thereby polluting water, soil, and ecosystem and finally affecting human health. As they are persistent and non-biodegradable, they have tendency to accumulate and cause harmful effects in living organism (Akpor *et al.*, 2014). According to World Health Organization (WHO), more than 250,000 deaths occur due to pesticides poisoning every year (Yang and Deng,

2007). In spite of this alarming situation there is no global network to track the poisoning or harmful health effects associated with the use of pesticides. Poisoning due to pesticides is increasing due to lack of knowledge about pesticides and their use by farmers, preventive measures against pesticides exposure, minimal understanding of health risks and inadequate safety labels/warnings on the packages by manufacturers (Gbarukoet *et al.*, 2009). During the last three decades there has been a sequential rise in the production and consumption of pesticides in India. Glyphosate, (N-(phosphonomethyl)-glycine) is a non-selective, broad spectrum organophosphate herbicide. Serious ill effects of glyphosate like teratogenicity have been well reported in some literature (Sparling *et al.*, 2006; Cavalcante *et al.*, 2008; Quassinti *et al.*, 2009; George *et al.*, 2010). Carbendazim is a benzimidazole fungicide. Methyl benzimidazole-2-yl carbamates (MBC). It is a broad spectrum, systemic fungicide used to control a range of pests affecting fruits, vegetables and cereals (Lewandowska and Walorczyk, 2010). Carbendazim shows its aneugenic effects by binding with the tubulin proteins, disrupting the microtubular assembly and the

*Correspondence: M. Rana. Department of Pharmaceutical Sciences, Kumaun University, Campus Bhimtal, Nainital Uttarakhand, India, PIN: 263136. Telephone No. 05942-247030. E-mail: pharma214dops@gmail.com

spindle formation at cell division (JMPR, 2005). It was found to cause serious effects on health in several mammalian systems especially male reproduction such as inhibition of germ cell division, sloughing of germ cells, and atrophy of seminiferous tubules (Gray *et al.*, 1990). It was also found that carbendazim treatment affects the functional capacity of Leydig cells which secrete testosterone (Rehnberget *al.*, 1989). It is important to understand the mechanism of action of pesticide and their toxicity, as domesticated animals and humans encounter these pesticides through a variety of applications. There is an increasing concern about reproductive toxicity and teratogenicity caused by these pesticides. Long term exposure of these pesticides affects the normal functioning of various organ systems and has produced several clinical effects (Azmi *et al.*, 2006; Jain *et al.*, 2009; Sharma *et al.*, 2009; Joshi and Sharma, 2012). Serum content of these biomarker responses reflects the total health status of animals when they have been subjected to environmental pollutants like pesticides. The aim of the present study is to investigate the effect of pesticides using pregnant female rats' serum as a reporter system and histopathology of their neonates exposed prenatally.

MATERIAL AND METHODS

In the present study virgin wistar female rats served as experimental animals. Methods used in this study were according to the Organization for Economic Co-operation and Development (OECD) study guidelines for testing of chemicals and prenatal growth and development (OECD, 1987; 2001).

Experimental Animals

Healthy wistar female rats, eighteen in number weighing between 200 to 250 gm were taken for the study.

Ethical approval for animal experimentation

Animal experimentation protocol of rats was preapproved by the Institutional Animal Ethical Committee (IAEC), Department of Pharmaceutical Sciences, Kumaun University, Nainital, India. The registration number was KUDOPS/42, issued by Committee for the Purpose of Control and Supervision of Experiments on Animals (CPCSEA). All methods were performed with relevant guidelines and regulations accordingly. The rats were given standard rat chaw and clean drinking water ad libitum, kept in propylene cages (three per cage) in a well ventilated room with 12 hour light/dark cycles.

Chemicals: Pesticides

S.N	Pesticides Used	Brand	Company
1	Herbicide Glyphosate	Topper 77	Crystal Crop Protection Pvt. Ltd. India
2	Fungicide Carbendazim	Bavistin	BASF India Ltd.

Diagnostic Kits

S.N	Diagnostic Kits	Company and methodology
1	Cholesterol	Erba ® + Modified Roeschlau's method
2	Triglycerides	Erba ® + GPO-TOPS method
3	SGOT	Erba ® + IFCC
4	SGPT	Erba ® + IFCC
5	Total Protein	Erba ® + Modified biuret, End Point Assay
6	Billirubin	Erba ® + Diazo, End Point

Blood glucose level was analyzed with the help of glucometer using glucose strips.

Experimental Design

The animals were randomly selected into three groups, 6 rats in each group. Proestrous females were placed individually for breeding with male overnight and those with sperm positive vaginal smear or with copulatory plug were considered to be at gestational day zero (0) (Abd El-Nasser *et al.*, 2009). After confirmation of their gestational day (0), the first and second group were administered 10 mg/kg of glyphosate and carbendazim orally throughout their gestation period the animals in the third group served as control and were given distilled water only. All animals of control group and exposed group were observed daily for any signs of mortality and toxicity. Body weight and gestation period were monitored and recorded (Upadhyay *et al.*, 2017).

Serum Analysis

During the gestation period, blood samples were collected on day 0, 7, 14, and 21 days, of all the groups of animals through retro orbital sinus under anesthetic condition (diethyl ether used for anesthesia). Serum

separation was done by centrifugation at 10,000× g for 10 min and analyzed for serum glucose and cholesterol level, total protein, triglycerides, bilirubin, SGOT and SGPT by using commercially available diagnostic kits.

Histopathological Analysis

The rat neonates were observed and 5 neonates were selected from each group. They were euthanized under anesthesia diethyl ether. The kidneys of the foetuses were removed and tissues of kidney and skin were fixed in 10% buffered formalin. Tissues were embedded in paraffin and the sections were stained with Hematoxylin and eosin (H and E). After staining they were examined under light microscope. Alterations from the normal were analyzed and histopathological changes between control neonates and experimental neonates of rats were observed (Javed *et al.*, 2017).

Statistical analysis

The results are represented as mean±SEM for each group. The differences among groups were analyzed by using ANOVA. Data analysis was performed using Graph Pad Prism Version 5 and the levels of significance were considered at P<0.05.

RESULTS

Determination of early pregnancy

The presence of sperm in vaginal smear of female rats after mating was considered as gestational day zero (0), as can be seen in Figure 1.

Body weight and gestation period observation

In case of pesticides exposed group, the mean body weight of female rats was found to be lower when compared with the control group throughout their gestation period (Table I). It was also observed in exposed group

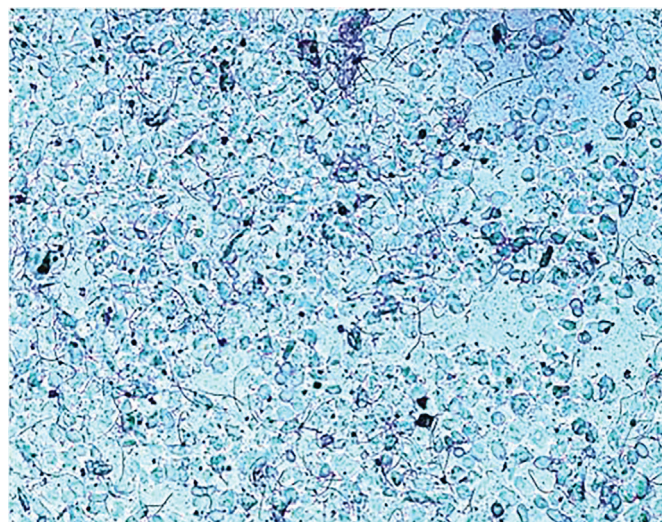


FIGURE 1 - Vaginal smear of female rats after copulation, presence of sperm in the smear

that their gestation duration was greater when compared with the control group as shown in Table II.

Serum biochemistry of female rats (Biomarker responses)

The data on blood glucose, cholesterol, total protein, triglycerides in the serum is given in Table III. It was observed that in pesticides exposed group (both glyphosate and carbendazim) there was not any significant change in the blood glucose level throughout the gestation period of female rats, when compared with control group. Significant increase in the blood cholesterol level of glyphosate exposed group was observed when compared with the control group but in case of carbendazim exposed group the blood cholesterol level got decreased on the day 21 when compared with control group. Triglycerides level in both the pesticides exposed group was found significantly greater on the day 14 and 21 of gestation duration, in comparison with the control group. The Total Protein value in pesticides exposed group was found to have increased in pesticides exposed group (both glyphosate and carbendazim). Total bilirubin level was found to be higher in pesticides exposed group on day

TABLE I - Body weight gain in female rats during pregnancy

S. N.	GROUP	Mean Body weight/days			
		0	7	14	21
I	Glyphosate-exposed (10mg/kg)	204.6	219.16	236.83	265.83
II	Carbendazim-exposed (10mg/kg)	202.50	224.16	243.50	261.00
III	Control (Distilled Water)	206.70	250.00	260.00	283.30

TABLE II - Gestation duration of female rats

S.N.	GROUP	Gestation length (days)	
		X±Sx	S.D
I	Glyphosate-exposed (10mg/kg)	26.33±0.21	0.51
II	Carbendazim-exposed (10mg/kg)	26.83±0.30	0.75
III	Control (Distilled Water)	22.33±0.33	0.57

14 and 21 of gestation period. The elevated level of SGOT (Serum glutamic oxaloacetic transaminase) and SGPT (Serum glutamic pyruvate transaminase) was observed in pesticide exposed group. The levels of these enzymes were found to be the highest in carbendazim exposed group when compared with control and glyphosate exposed group. The estimation of serum bilirubin, SGOT and SGPT enzyme level helped in the detection of any injury to hepatocytes.

Histopathological study

Histopathologically, examination of neonatal kidney section in pesticides exposed group (both glyphosate and carbendazim) showed marked degenerative changes and vacuolization within the eroded capsules. Thinning of epidermis of skin was found in pesticide exposed group. The histopathological examination was shown in Figure 2 (A, B, C, D, E, F, G, H, I, and J). No histological changes

TABLE III - Serum biochemistry of pregnant female rats

S.N.	GROUP	Variables	No. of Days (Gestation Duration)			
			0	7	14	21
I	Glyphosate-exposed (10 mg/kg)	Glucose(mg/dL)	99.6±0.84	97.6±3.22	86.66±0.88	91.33±0.88
		Cholesterol (mg/dL)	108.83± 4.43	144.66± 5.34**	154.00± 3.01**	179.16± 4.56**
		Total Protein (g/dL)	7.36± 0.46	7.94± 0.46	10.96± 0.31**	13.84± 0.74**
		Triglycerides(mg/dL)	71.66± 3.34	103.66±2.41*	136.16± 3.38**	175.00± 4.04**
		Billirubin (mg/dL)	0.341± 0.13	0.643± 0.24*	1.31± 0.54**	2.1± 0.86**
		SGOT(IU/L)	9.68± 0.89	13.2± 0.35	17.56± 0.41*	19.83± 0.87*
		SGPT (IU/L)	11.8± 0.50	15.6± 0.76*	18.83± 0.60**	19.5± 0.84**
II	Carbendazim-exposed (10 mg/kg)	Glucose (mg/dL)	93.83± 1.40	85.33± 1.17	79.66± 2.01	94.33± 2.12
		Cholesterol (mg/dL)	105.5± 2.49	93.50± 2.48**	83.66± 2.10**	65.83± 0.99**
		Total Protein (g/dL)	7.48± 0.08	7.86± 0.04	9.92± 0.29**	10.08± 0.30**
		Triglycerides(mg/dL)	69.66± 2.52	94.33± 2.16	127.83± 2.11**	170.66± 3.20**
		Billirubin (mg/dL)	0.328± 0.005	0.537± 0.01*	0.832±0.07**	1.705±0.19**
		SGOT(IU/L)	9.23±0.84	16.61±0.20*	20.48±0.96**	43.16±3.22**
		SGPT (IU/L)	11.58±0.26	19.66±1.11**	25±1.46**	45.83±2.85**
III	Control (Distilled Water)	Glucose (mg/dL)	102.5±2.04	99.0±1.33	87.16±1.85	92.83±1.49
		Cholesterol (mg/dL)	104.66± 3.42	137.50± 4.97	142.5± 3.83	159.00± 1.33
		Total Protein (g/dL)	7.38± 0.10	7.43± 0.07	7.78± 0.04	7.76± 0.04
		Triglycerides(mg/dL)	68.33±5.29	94.16±2.19	113.00±1.99	153.66± 3.30
		Billirubin (mg/dL)	0.356±0.03	0.355±0.04	0.411±0.04	0.362±0.04
		SGOT(IU/L)	8.33±0.90	12.4±0.49	15.55±0.58	16.18±0.26
		SGPT (IU/L)	11.16±0.26	11.8±0.38	12.18±0.20	12.56±0.20

Data represent mean± SE. Significant difference (**p<0.01) between control and exposed group.

were observed in the kidney section of neonate of pregnant rat of control group (Figure 2 A and B). Histological examination of kidney of neonate of pregnant rat exposed to pesticide glyphosate showed marked degenerative changes and vacuolization. Few shrunken glomeruli, glomerular hypertrophy and spaces between Bowman's capsule and glomeruli were observed in glyphosate exposed group (Figure 2 C and D). Slight thinning of epidermis, dilated and congested blood vessels were also observed in skin section of neonate of glyphosate exposed pregnant rats (Figure 2 G and H). The kidney of neonate

of pregnant rat exposed to pesticide carbendazim showed degenerative changes and vacuolization with eroded capsule (Figure 2E). Tubules showed severe degeneration, capsule was eroded at places. Epithelial lining became undistinguished. Many renal tubular cells appeared foamy due to epithelial vacuolization (Figure 2F). The skin of neonates of carbendazim exposed group showed thinning of epidermis (Figure 2I) and normal sized blood vessel without congestion was observed in this carbendazim exposed group (Figure 2J).

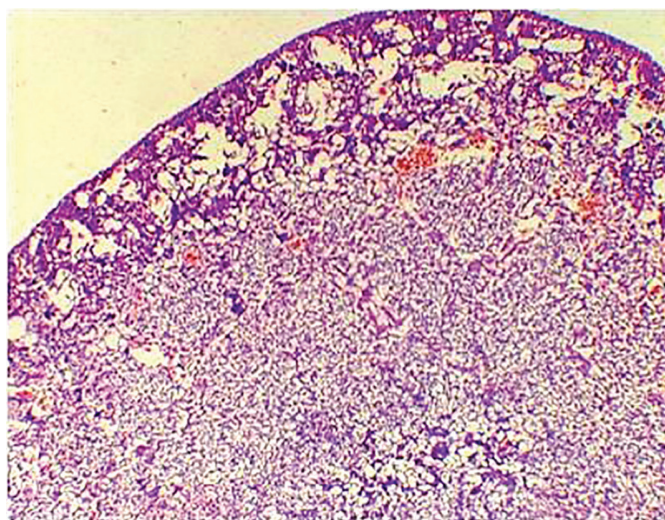


FIGURE 2(A) - Photomicrograph of section of kidney of neonate of pregnant rat (control) showing normal structure. (H & E 40X).

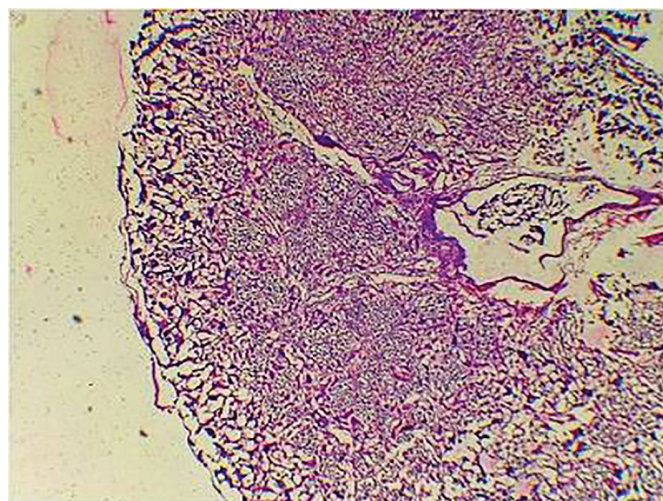


FIGURE 2(C) - Photomicrograph of section of kidney of neonate of pregnant rat exposed to pesticide glyphosate shows degenerative changes and vacuolization. (H & E 40X).

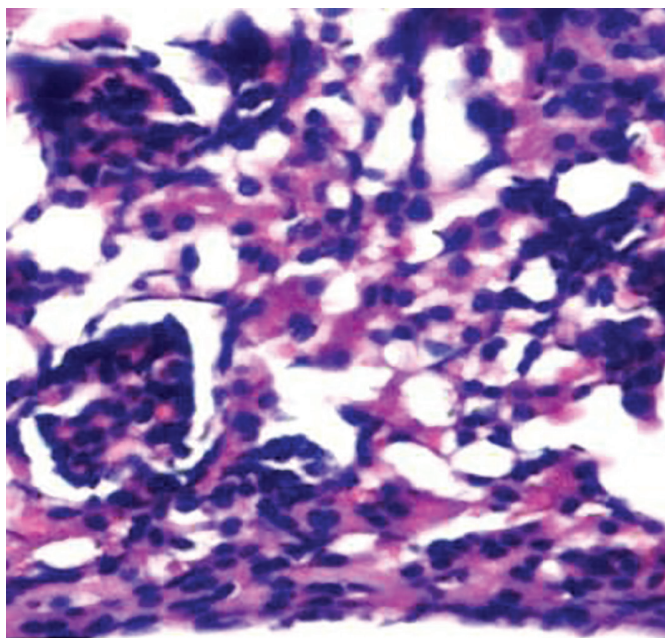


FIGURE 2(B) - Photomicrograph of section of kidney of neonate of pregnant rat (control) showing normal structure. (H & E 400X).

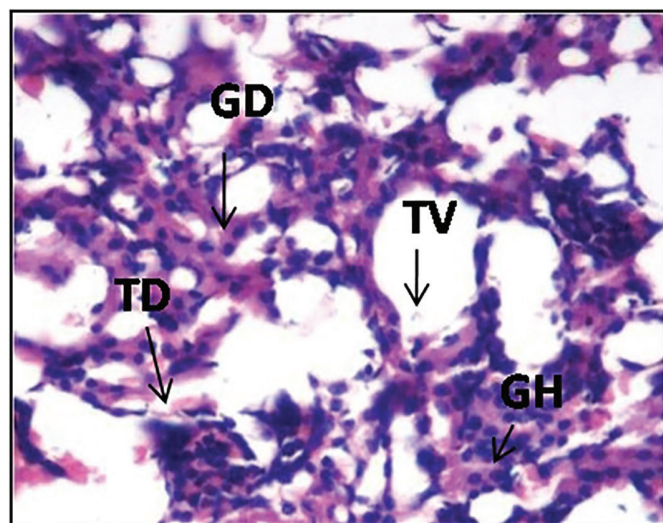


FIGURE 2(D) - Photomicrograph of section of kidney of neonate of pregnant rat exposed to pesticide glyphosate shows marked degenerative changes (TD) and vacuolization within tubules (TV). Some glomeruli appear hypercellular (GH) and some show degeneration and shrinkage (GD). Focal lymphocytic infiltration noted in the interstitium. (H & E 400 X).

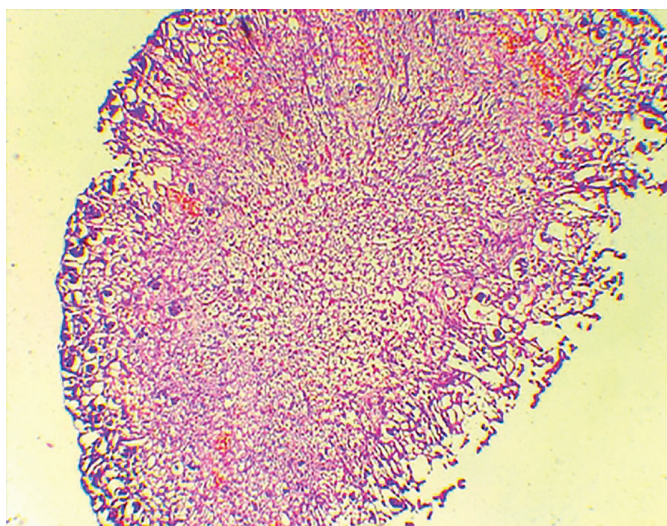


FIGURE 2(E) - Photomicrograph of section of kidney of neonate of pregnant rat exposed to pesticide carbendazim shows marked degenerative changes and vacuolization with eroded capsule. (H&E 40X).

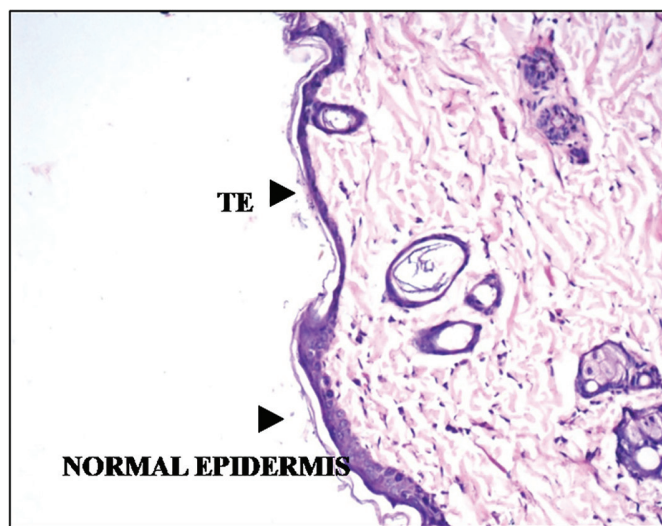

FIGURE 2(G) - Photomicrograph of section of skin of neonate of pregnant rat exposed to pesticide glyphosate shows slight thinning of epidermis (TE) (H & E 100X).

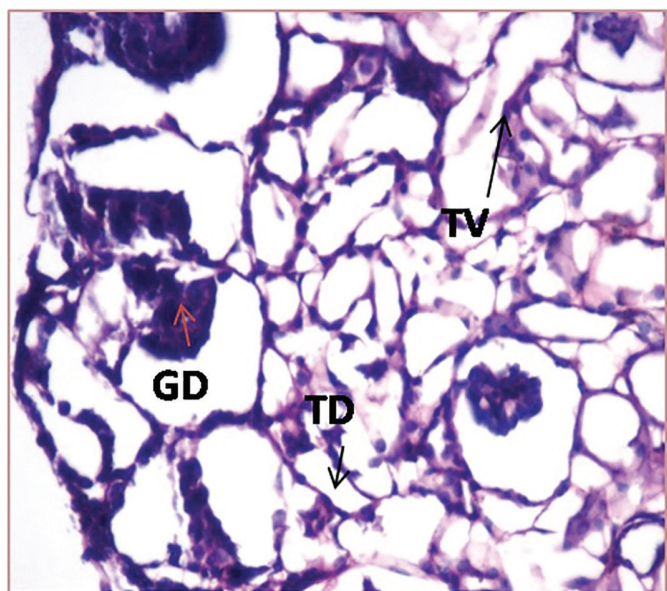


FIGURE 2 (F) - Photomicrograph of section of kidney of neonate of pregnant rat exposed to pesticide carbendazim shows marked degenerative changes (TD) and vacuolization within tubules (TV). The glomerulus appears shrunken and shows degenerative changes (GD). (H&E 400x).

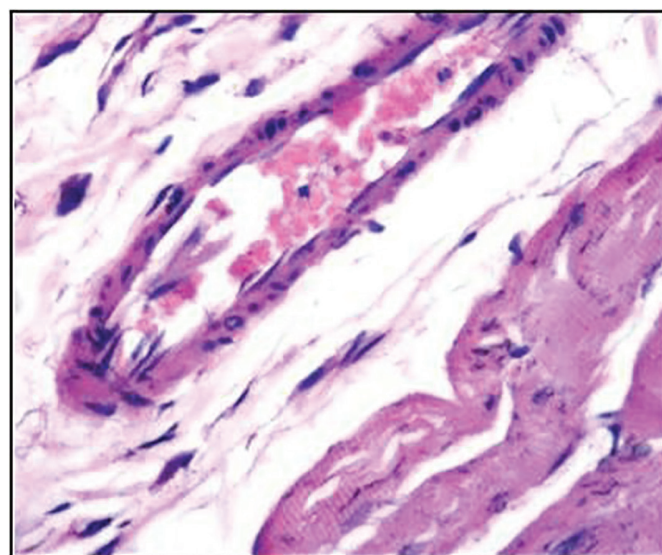


FIGURE 2 (H) - Photomicrograph of section of skin of neonate of pregnant rat exposed to pesticide glyphosate shows dilated and congested blood vessels. (H & E 400X).

DISCUSSION

Pesticides have been considered as the most effective weapon which protects agricultural products. Glyphosate and carbendazim are widely used herbicide and fungicide. These pesticides are persistent, non-biodegradable, get accumulated and produce deleterious effects in living

organisms. Biomarker responses like SGOT, SGPT, and serum total protein, cholesterol, glucose, triglycerides, and bilirubin represent the functional status of homeostasis. In this study, effects of the pesticides exposure on the biomarker responses were analyzed in pregnant rats and histopathological study of kidney of their neonates were analyzed. In serum biochemistry analysis, no significant changes were observed in the serum glucose level of both the pesticides exposed group. Increase in the blood glucose level in rats during pregnancy is called

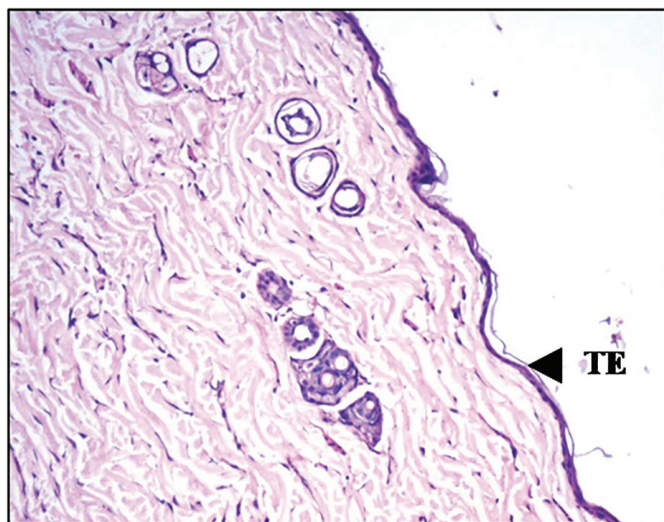


FIGURE 2 (I) - Photomicrograph of section of skin of neonate of pregnant rat exposed to pesticide carbendazim shows slight thinning of epidermis (TE) (H & E 100X).

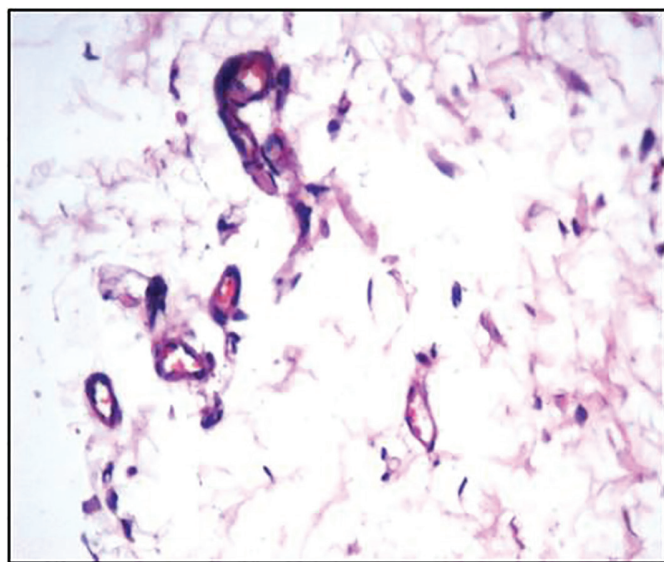


FIGURE 2 (J) - Photomicrograph of section of skin of neonate of pregnant rat exposed to pesticide carbendazim shows normal sized vessels with no congested blood vessels (H & E 400X).

gestational diabetes caused by insulin resistance. When the body is not able to produce extra insulin gestational diabetes may develop (Rosenn and Miodovnik, 2000; ter Braak *et al.*, 2002; Evers *et al.*, 2002). Cholesterol and triglyceride levels are important constituents of lipid which is an important component of cell membrane and also plays a major role as messenger in various signal transduction pathways. Increase in cholesterol level is due to hepatic adipose metabolism and synthesis of sex steroid hormones during pregnancy. Some studies show that excessive rise in cholesterol level during pregnancy is associated with high risk of atherosclerosis in both

mother and infant, preeclampsia and gestational diabetes in mothers (Bartels and O'Donoghue, 2011). Decrease in the level of cholesterol in carbendazim exposed group may be due to its utilization in membrane biogenesis. It may also be due to low feed intake, less absorption from the gut because of the gut damage caused by carbendazim and also due to improper cholesterol synthesis in the liver. Low cholesterol level prior to conception or during pregnancy may have an increased risk of premature labor and other complications as cholesterol is necessary for the proper development of placenta and sex steroid hormones. The increase in the level of total protein might be due to the increased production of vital proteins which combat pesticide toxicity. There is a need of protein synthesis to meet the demand for the repair of damaged tissue as well as for the growth and development of the foetus. The elevated level of serum plasma was observed in pre-eclampsia (Hughes *et al.*, 1980). Pre-eclamptic pregnant females have high blood pressure and proteinuria (Eiland *et al.*, 2012). SGPT and SGOT are the most reliable biomarkers of hepatotoxicity. It plays an important role in amino acid metabolism and gluconeogenesis. Elevated level of this enzyme was observed during liver damage. Total Billirubin is another biomarker of hepatobiliary injury. The increased level of bilirubin indicates septicemias, parenchymal disease and renal failure (Bacq *et al.*, 1996).

Exposure to these pesticides causes marked structural damage of the kidney. Increased susceptibility of mammalian kidney to the toxic effects of these chemicals can be attributed in relation to the unique anatomy and physiology of this organ. Kidney receives about 20-25% resting cardiac output and constitutes only 0.5% of total body mass. As a result any chemical or drug in the blood circulation will be delivered directly to these organs in higher amounts. Progressive accumulation of these toxicants in the nephron results in intraluminal precipitation of insoluble compounds which finally causes tubular obstruction and acute renal failure (Javed *et al.*, 2017).

CONCLUSION

Our results indicated that pesticides exposure has toxic effect on the serum biochemistry of pregnant female rats and it causes structural damage to the kidney and skin of neonates. This study concluded that both the glyphosate and carbendazim are toxic to females during their gestation period and also the growth of the embryo might be affected during this period. Further research is needed to explore the causes of birth defects after the maternal exposure to pesticides.

REFERENCES

- Abd El-Nasser, MA, Abdel-mohsen MA, Shaaban AA, Ahmed DY. Teratogenic and genotoxic effects of Perfluoroalkyl acids on embryonic and neonate mice. *Ass Univ Bull Environ Res.* 2009;12(2):39-53.
- Akpor OB, Ohiobor, GO, Olaolu TD. Heavy metal pollutants in waste water effluents: sources, effects and remediation. *Adv Biosci Bioeng.* 2014;2(4):37-43.
- Azmi MA, Naqvi SHN, Azmi MA, Aslam M. Effect of pesticide residues on health and different enzyme levels in the blood of farm workers from Gadap (rural area) Karachi—Pakistan. *Chemosphere.* 2006;64(10):1739-44.
- Bacq Y, Zarka O, Brechot JF, Mariotte N, Vol S, Tichet J, Weill J. Liver function tests in normal pregnancy: a prospective study of 103 pregnant women and 103 matched controls. *Hepatology.* 1996;23(5):1030-4.
- Bartels A, O'Donoghue K. Cholesterol in pregnancy: a review of knowns and unknowns. *Obstet Med.* 2011;4(4):147-51.
- Bjørning-Poulsen M, Andersen HR, Grandjean P. Potential developmental neurotoxicity of pesticides used in Europe. *Environ Health.* 2008;7(50):1-23.
- Cavalcante DG, Martinez CBR, Sofia SH. Genotoxic effects of Roundup on the fish (*Prochilodus lineatus*). *Mutat Res.* 2008;655(1/2):41-6.
- Cope WG, Leidy RB, Hodgson E. Classes of toxicants: use classes. In: Hodgson E, editor. *Textbook of modern toxicology*, 3rd edition. Hoboken: John Wiley; 2004. p.58-70.
- Eiland E, Nzerue C, Faulkner M. Preeclampsia 2012. *J Pregn.* 2012; 2012(586578):1-7.
- Evers IM, de Valk HW, Mol BW, ter Braak EW, Visser GH. Macrosomia despite good glycemic control in Type I diabetic pregnancy; results of a nationwide study in the Netherlands. *Diabetologia.* 2002; 45(11):1484-9.
- Gray Jr. LE, Ostby J, Linder R, Goldman J, Rehnberg G, Cooper R. Carbendazim-induced alterations of reproductive development and function in the rat and hamster. *Fundam Appl Toxicol.* 1990;15(2):281-97.
- Gbaruko BC, Ogwo EI, Igwe JC, Yu H. Organophosphate induced chronic neurotoxicity: health, environmental and risk exposure issues in developing nations of the world. *Afr J Biotech.* 2009;8(20):5137-41.
- George J, Prasad S, Mahmood Z, Shukla Y. Studies on glyphosate-induced carcinogenicity in mouse skin: a proteomic approach. *J Proteomics.* 2010;73:951-64.
- Hughes G, Bischof P, Wilson G, Smith R, Klopper A. Tests of fetal wellbeing in the third trimester of pregnancy. *Br J Obstet Gynaecol.* 1980;87:650-6.
- Jain N, Sharma N, Sharma P, Joshi SC. Haemato-biochemical profile following sub acute toxicity of malathion in male albino rats. *Pharmacologyonline.* 2009;2:500-6.
- Javed M, Ahmad MI, Usmani N, Ahmad M. Multiple biomarker responses (serum biochemistry, oxidative stress, genotoxicity and histopathology) in *Channa punctuatus* exposed to heavy metal loaded waste water. *Scientific Reports* 2017;7(1675):1-11.
- JMPR. Pesticide residues in food – 2005, JMPR evaluations 2005, Part II, Carbendazim, 87-106. Accessed 2018 Mar. Available from: <http://www.inchem.org/documents/jmpr/jmpmono/v2005pr05.pdf>.
- Joshi SC, Sharma P. Effect of acephate on sex hormones, sperm dynamics and fertility in male albino rats. *Int J Res Pharm Biomed Sci.* 2012;3(1):286-92.
- Lewandowska A, Walorczyk S. Carbendazim residues in the soil and their bioavailability to plants in four successive harvests. polish. *J Environ Stud.* 2010;19 (4):757-61.
- OECD. Organization for Economic Cooperation and Development. OECD guidelines for testing chemicals. Washington: OECD Publication and Information Center; 1987. p.492-7.
- OECD. Organization for Economic Cooperation and Development. Prenatal development toxicity study guideline for the testing of chemical proposal for updating Guideline 414. Washington: OECD Publication and Information Center; 2001.
- Quassinti L, Maccari E, Murri O, Bramucci M. Effects of paraquat and glyphosate on steroidogenesis in gonads of the frog *Rana esculenta* in vitro. *Pestic Biochem Physiol.* 2009;93(2):91-5.

Rabideau CL. Pesticide mixtures induce immunotoxicity: potentiation of apoptosis and oxidative stress. Blackburg. Thesis [Masters of Science] - Virginia Polytechnic and State University; 2001. 170p.

Rehnberg GL, Cooper RL, Goldman JM, Gray LE, Hein JF, McElroy WK. Serum and testicular testosterone and androgen binding protein profiles following subchronic treatment with carbendazim. *Toxicol Appl Pharmacol* 1989;101(1):55-61.

Rosenn BM, Miodovnik M. Glycemic control in the diabetic pregnancy: Is tighter always better? *J Matern Fetal Med.* 2000;9(1):29-34.

Sharma P, Sharma N, Joshi SC. Effects of copper oxychloride on reproductive functions of male albino rats. *J Life Sci.* 2009;6(2):157-61.

Sparling DW, Matson C, Bickham J, Doelling-Brown P. Toxicity of glyphosate as glypro and LI 700 to red-eared slider (*trachemys Scripta elegans*) embryos and early hatchings. *Environ Toxicol Chem.* 2006;25:2768-74.

ter Braak EW, Evers IM, Willem Erkelens D, Visser GH. Maternal hypoglycemia during pregnancy in type 1 diabetes: maternal and fetal consequences. *Diabetes/Metab Res Rev.* 2002;18(2):96-105.

Upadhyay J, Rana M, Juyal V, Rana A, Bisht SS. Effect of pesticide exposure on the female rats and their pups throughout their gestation period. *Res J Pharm Technol.* 2017;10(8):2535-7.

Yang C, Deng J. Intermediate syndrome following organophosphate insecticide poisoning. *J Chin Med Assoc.* 2007;70(11):467-72.

Received for publication on 13th March 2018

Accepted for publication on 02nd May 2018