


# Persistence of congenital penile frenulum in male cat: case report

## *Persistência de frênulo peniano congênito em gato macho: relato de caso*

Juliana Chieco Jeronymo Garcia<sup>1</sup>; Matheus Felipe da Silva<sup>2</sup>; Daniel de Souza Ramos Angrimani<sup>2\*</sup> 

<sup>1</sup> Universidade Anhembi Morumbi, São Paulo - SP, Brazil

<sup>2</sup> Universidade Estadual Paulista “Júlio de Mesquita Filho”, Faculdade de Medicina Veterinária e Zootecnia, Departamento de Reprodução Animal e Radiologia Veterinária, Botucatu - SP, Brazil

### ABSTRACT

The penile frenulum is a thin strip of connective tissue that connects the penis glans to the foreskin. Due to the few number of reports of this condition, this work reports the occurrence of persistent penile frenulum in a mixed breed domestic cat, of seven months old and 5.2 kg. In this particular case, penile frenulum was an incidental finding during clinical examination. The animal was in puberty, characterizing the penile frenulum. The resolution of the case occurred spontaneously prior to elective orchiectomy. Thus, the changes observed in the penis due to congenital alteration in cats are described in this report.

**Keywords:** Penile frenulum. Animal reproduction. Feline.

### RESUMO

O frênulo peniano é uma fina faixa de tecido conectivo que une a glânde ao prepúcio que pode se romper sob a ação da testosterona quando o animal inicia a puberdade. Devido a escassez de relatos desta afecção o presente trabalho relata a ocorrência de frênulo peniano persistente em um gato doméstico, sem raça definida, de sete meses de idade e 5,2 kg. O frênulo peniano foi um achado incidental durante o exame clínico do animal. O animal já apresentava-se em puberdade, caracterizando o quadro de frênulo peniano. A resolução do caso ocorreu de maneira espontânea previamente a orquiectomia eletiva. Dessa forma, as alterações observadas no pênis devido a alteração congênita em gatos são descritas neste relato.

**Palavras-chave:** Frênulo peniano. Reprodução animal. Felino.

#### Correspondence to:

Daniel de Souza Ramos Angrimani  
Universidade Estadual Paulista “Júlio de Mesquita Filho”,  
Faculdade de Medicina Veterinária e Zootecnia, Departamento  
de Reprodução Animal e Radiologia Veterinária  
Rua Prof. Dr. Walter Mauricio Correra, Rubião Junior  
CEP: 18618-970, Botucatu - SP, Brazil  
e-mail: [angrimani@gmail.com](mailto:angrimani@gmail.com)

Received: November 21, 2018

Approved: May 09, 2019

**How to cite:** Garcia JCJ, Silva MF, Angrimani DSR. Persistence of congenital penile frenulum in male cat: case report. *Braz J Vet Res Anim Sci.* 2019;56(2):e151959. <https://doi.org/10.11606/issn.1678-4456.bjvras.2019.151959>.

### Case Report

Penile frenulum is a thin layer of connective tissue that connects the penis to the foreskin, which may be present or not in newborns (Papazoglou & Kazakos, 2002; Wolfe &

Rodning, 2009). The rupture of the penile frenulum tends to occur spontaneously, and since it is an androgen-dependent condition, usually occurs during the pubertal period in males (Boothe, 2008; Papazoglou & Kazakos, 2002). In cats, Carranza et al. (2014) described that the onset of early puberty in felines can be identified by the presence of penile spicules and complete balano-preputial separation, which occurs at the age of 13 weeks. Thus, after this age, the connection between gland and foreskin can be classified as penile frenulum.

The clinical diagnosis of this condition is visual, performed through the observation of a thin transparent layer of connective tissue. When natural rupture does not occur, treatment is surgical, where a simple excision is performed. In fact, penile frenulum is avascular, and the prognosis is favorable (Volpato et al., 2010). In dogs and ruminants, the penile frenulum is often asymptomatic; however, the animal can develop dysuria and inability to perform copulation (Volpato et al., 2010). In cats, there are

few studies about penile frenulum, but penis deviation and inability to reproduce were observed (Axner et al., 1996; Baran et al., 2014). Therefore, in general, the most common clinical signs are inability to expose the penis, deviation of urine direction and local inflammation. Thus, since there are only few descriptions in cats, the aim of this study was to report a case of persistence of congenital penile frenulum in male domestic cat.

A seven-month-old male cat weighing 5.2 kg of undefined breed was referred to the Department of Animal Reproduction in the School of Veterinary Medicine and Animal Science of the São Paulo State University at Botucatu. The owner wanted to submit the animal to an elective orchiectomy. During clinical examination, we observed that the animal was in good general condition, without changes in urine and feces. The animal presented with a heart rate of 192 beats per minute, 32 respiratory movements per minute, and rectal temperature of 38.2°C. However, during the penis exposure, it was noted that the animal presented a thin layer of connective tissue connecting the penile glans to the foreskin (Figure 1). Thus, the animal was diagnosed with persistent congenital penile frenulum, and since there was no interest in animal reproduction, the surgical correction of the penile frenulum during the elective orchiectomy was scheduled. One week after the previous exams, and after preoperative tests, the animal was referred to elective surgery, and pre-anesthetic medication consisted of xylazine (3mg/kg, IM) and pethidine (3mg/kg, IM). Anesthetic inducers were midazolam (0.2 mg/kg, IV) and ketamine (5mg/kg, IV). Orchiectomy was performed as described by Macphail (2015). During the surgical procedure, it was observed that the penile frenulum had already ruptured, apparently spontaneously, and no intervention was necessary (Figure 2). Dipyron (25mg/kg) was used for pain control after surgery.

Only few reports have described penile frenulum in cats, suggesting that this abnormality is uncommon in this species. Moreover, is possible that the factors that may contribute to the low incidence of this reproductive disorder in cats may be related to the lack of attention by owners to observe the disease. Axner et al. (1996) reported a case of dorsal deviation of the penis due to the persistence of penile frenulum in a cat. Similarly, Baran et al. (2014) described a case of an 18-month-old male cat exhibiting penile frenulum associated with phimosis. Both cases were diagnosed during andrological examination and were corrected without complications in outpatient procedures. Furthermore, in this case, the penile frenulum was an incidental finding during andrological examination of cats, such as in the present report. It should be highlighted that the surgical

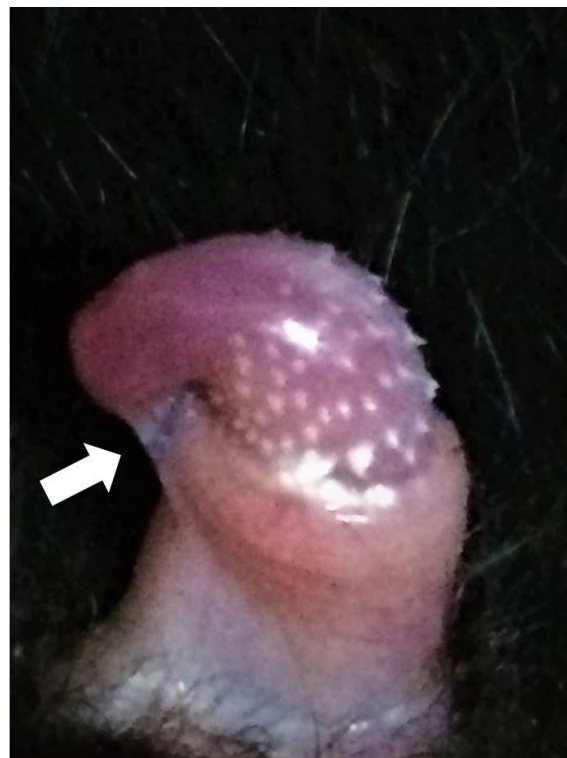

Figure 1 - Macroscopic exam of the penis. Connective tissue attached from the penis to the foreskin along the ventral region of the glans (white arrow).

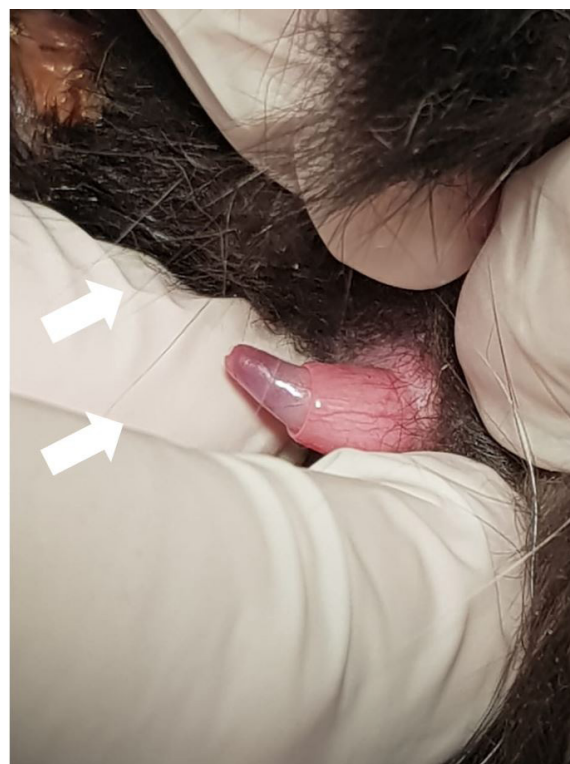


Figure 2 - Penis three months after the rupture of the penile frenulum.

procedure was performed in this case, because there was no interest in animal reproduction, unlike Axner et al. (1996) and Baran et al. (2014).

Regarding the etiopathogeny of penile frenulum, Carranza et al. (2014) described that the balano-preputial

separation is the first sign of puberty, which occurs from the age of 13 weeks in normal cats. In fact, Gaytan et al. (1988) verified relationship between balano-preputial separation and androgen production during sexual maturation in rats, since this fact does not occur when animals are castrated or when substances with antiandrogenic effects are administered (Yoshimura et al., 2005). Therefore, although the expected interval for a definitive diagnosis of this condition in cats is not described in literature, it is assumed that the animal in the present report was already at the age for the initial development of sexual maturity, since the presence of androgen-dependent penile spicules was observed (Carranza et al, 2014; Schäfer-Somi et al., 2014). Thus, it could be inferred that the present report is a case of persistence of penile frenulum.

In conclusion, cases of persistence of penile frenulum in felines are still poorly explored in literature, which is

an incidental finding observed in clinical practice. Thus, we expect that this report can contribute for the diagnosis and prognosis of penile frenulum and may assist clinical veterinarians when the reproductive status of these animals must be maintained.

### Conflict of Interest

The authors state they have no conflicts of interest to declare.

### Ethics Statement

Since this manuscript is a clinical case report and all the therapeutic approach described is based on the literature, it was not necessary the approve of the animal ethics committee. In addition, a document declaring the authorization for publication of this case was signed by the owner of the animal during admission.

## References

- Axnér E, Ström B, Linde-Forsberg C, Gustavsson I, Lindblad K, Wallgren M. Reproductive disorders in 10 domestic male cats. *J Small Anim Pract.* 1996;37(8):394-401. <http://dx.doi.org/10.1111/j.1748-5827.1996.tb02427.x>. PMID:8872943.
- Baran A, Gursoy M, Gulcubuk A, Ozdas OB. Congenital penile frenulum and phimosis in a male cat. In: *Proceedings of XVIII The Annual Conference of the European Society for Domestic Animal Reproduction; 2014; Helsinki, Finland. Utrecht: ESDAR; 2014.*
- Boothe HW. Diseases of the external male genitalia. In: Morgan RV, editor. *Handbook of small animal practice.* 5th ed. Philadelphia: Saunders; 2008. p. 587-92. <http://dx.doi.org/10.1016/B978-1-4160-3949-5.50063-7>.
- Carranza A, Faya M, Merlo ML, Batista P, Gobello C. Effect of GnRH analogs in postnatal domestic cats. *Theriogenology.* 2014;82(1):138-43. <http://dx.doi.org/10.1016/j.theriogenology.2014.03.012>. PMID:24725419.
- Gaytan F, Bellido C, Aguilar R, Aguilar E. Balano-preputial separation as an external sign of puberty in the rat: correlation with histologic testicular data. *Andrologia.* 1988;20(5):450-3. <http://dx.doi.org/10.1111/j.1439-0272.1988.tb00724.x>. PMID:3207205.
- Macphail CM. Cirurgia dos sistemas reprodutivo e genital. In: Fossum TW, editor. *Cirurgia de pequenos animais.* 4. ed. Rio de Janeiro: Elsevier; 2015. p. 780-855.
- Papazoglou LC, Kazakos GM. Surgical conditions of the canine penis and prepuce. *Compend Contin Educ Pract Vet.* 2002;24(3):204-19.
- Schäfer-Somi S, Kaya D, Gültiken N, Aslan S. Suppression of fertility in pre-pubertal dogs and cats. *Reprod Domest Anim.* 2014;49(2, Suppl 2):21-7. <http://dx.doi.org/10.1111/rda.12330>. PMID:24947857.
- Volpato R, Ramos RS, Magalhães LCO, Lopes MD, Souza DB. Review on disorders of the penis and prepuce in dogs. *Vet Zootec.* 2010;17(3):312-23.
- Wolfe D, Rodning SP. Diagnosis and management of juvenile anomalies of the penis and prepuce. In: Anderson DE, Rings DM, editor. *Food animal practice.* 5th ed. Saint Louis: Saunders; 2009. p. 340-42. <http://dx.doi.org/10.1016/B978-141603591-6.10073-9>.
- Yoshimura S, Yamaguchi H, Konno K, Ohsawa N, Noguchi S, Chisaka A. Observation of preputial separation is a useful tool for evaluating endocrine active chemicals. *J Toxicol Pathol.* 2005;18(3):141-57. <http://dx.doi.org/10.1293/tox.18.141>.

**Financial support:** There was no financial support for this study.

**Authors Contributions:** All authors participated in the writing of the article, considering the reading and review stages.