

Feline chronic gingivostomatitis with calicivirus infection: case report

Gingivostomatite crônica felina com infecção por calicivírus: relato de caso

Aline Silvestrini da SILVA¹; Fernanda Campos HERTEL¹; Mayara Pereira LOTÉRIO¹; Jéssica Miranda COTA¹; Bruna Giannakopoulos RODRIGUES²; Marcus Rebouças SANTOS¹; Emily Correna Carlo REIS³

¹ Universidade Federal de Viçosa, Programa de Pós-Graduação em Medicina Veterinária, Viçosa – MG, Brazil

² Universidade Federal de Viçosa, Programa de Residência em Medicina Veterinária, Viçosa – MG, Brazil

³ Universidade Federal de Viçosa, Departamento de Medicina Veterinária, Viçosa – MG, Brazil

Abstract

Feline chronic gingivostomatitis (FCGS) is an oral inflammatory condition that frequently affects felines. Its etiology is not well defined, but several viral agents are thought to be involved. Several therapeutic protocols have been described, yet treatment response is often variable, and the therapeutic success is transient with an unpredictable duration. Therefore, the therapeutic strategy needs to be tailored for each patient. This work relates a case characterized by viral involvement in its etiopathogenesis providing an alternative to the most widely-used methods that so often frustrate both veterinary doctors and pet owners.

Keywords: Feline chronic gingivostomatitis. Feline. Interferon. Calicivirus.

Resumo

A gingivostomatite crônica felina (FCGS) é uma condição inflamatória oral que frequentemente afeta felinos. A sua etiologia não está bem definida, mas acredita-se que vários agentes virais possam estar envolvidos. Muitos protocolos terapêuticos têm sido descritos, no entanto, a resposta ao tratamento é frequentemente variável e o sucesso terapêutico é transitório com uma duração imprevisível. Portanto, a estratégia terapêutica precisa ser adaptada para cada paciente. O presente trabalho propõe a caracterização do envolvimento viral na etiopatogenia da doença como uma alternativa aos métodos mais amplamente utilizados, que muitas vezes frustram médicos veterinários e os donos de animais de estimação.

Palavras-chave: Gingivostomatite crônica felina. Felinos. Interferon. Calicivírus.

Correspondence to:

Aline Silvestrini da Silva
Universidade Federal de Viçosa, Departamento de Medicina Veterinária
Avenida Peter Henry Rolfs, s/n
CEP 36570-900, Viçosa, MG, Brazil
e-mail: aline.silvestrini1804@gmail.com

Received: 11/12/2017

Approved: 07/08/2018

Feline chronic gingivostomatitis (FCGS) is a chronic oral inflammatory condition that frequently affects felines (LYON, 2005). Its etiology is not well defined, but the immune system is thought to be involved in its pathogenesis (VEIR et al., 2002; LYON, 2005). Several therapeutic protocols are described with medical and/or surgical approaches.

Clinical studies point to the involvement of several viral agents in FCGS etiopathogenesis, including feline calicivirus (FCV) (LYON, 2005).

A 12-year-old female domestic shorthair cat had a history of weight loss, hyporexia and tooth loss two months before presenting to our practice. Physical examination revealed the presence of ulcers in the oral cavity (Figure 1), mostly localized on the swollen gums and tonsils, in addition to pain upon palpation and mouth opening. The cat also presented dental calculus on all teeth. Complementary tests were performed, hyperproteinemia was driven by hyperglobulinemia, and the FIV/FeLV immune-

assay was negative for both viruses. Antibiotic therapy with amoxicillin and potassium clavulanate (20 mg/kg, twice per day for 21 days) was prescribed along with prednisolone (1 mg/kg, twice per day for seven days, followed by a gradual dose reduction) for initial reduction of swollen tonsils, combined with periodontal therapy. The treatment temporarily improved the clinical symptoms. Due to the recurrent relapses after treatment with antibiotics and corticosteroid was discontinued, premolar and molar teeth extraction and oral cavity biopsy procedures were performed, and the animal was prescribed ketoprofen (1 mg/kg, once per day for 5 days) for pain management as well as the antibiotic therapy as previously prescribed.

The histopathological findings revealed the presence of dense lymphoplasmacytic and polymorphonuclear inflammatory infiltrate in the gingival mucosa. Therefore, based on clinical signs and treatment response, the presumptive diagnosis of FCGS was confirmed.

Although a follow-up appointment after one week was recommended, the patient returned two months after exodontia, presenting hyporexia and recurrence of the lesions (Figure 2), combined with dysphagia and sialorrhea. A sample was collected by sterile gingival swab of the injured areas of oral cavity. Viral isolation was performed through inoculation in cell culture, considered the gold standard in virological diagnosis (Laboratory of Immunobiological and Animal Virology, Department of Veterinary - UFV). After multiplication in cultured cells, the virus was identified by the cytopathic characteristics of feline calicivirus present in the sample (Figure 3), which were compatible with FCV isolation. The patient returned with complaints of sialorrhea, hyporexia and dehydration. Upon examination of the oral cavity, the recurrence of lesions in the gingiva and in the region of the palatoglossal arch was observed.

Treatment with amoxicillin and clavulanate was prescribed, and the patient was requested to return for a follow-up assessment. After four days, the patient returned with general improvement of the clinical symptoms and return to normorexia. Interferon alfa 2A (30 IU/animal, once daily for 7 days) was prescribed with a seven-day interval without medication until further recommendations. At submission of this case report, the patient had been successfully treated with interferon alfa 2A with an improvement in general condition, and no subsequent lesions have been observed.

The mucosa of the oral cavity is always exposed to antigens (VEIR et al., 2002). The immune system produces antibodies against the antigens, leading to the activation of the complement system, attracting phagocytic cells that damage the membranes of gingival cells (WHITE et al., 1992).

It is common for periodontal disease to occur concomitant with FCGS lesions. Studies suggest an association between FCGS and the bacteria involved in periodontal disease because many affected animals respond to antibiotic therapy (WHITE et al., 1992). The patient was initially treated with antibiotics and corticosteroids, together with the removal of dental calculi to treat the concomitant periodontal disease. This resulted in improvement of clinical signs and symptoms for a short period of time (NIZA et al., 2004). As the clinical treatment was not sufficient to keep the animal asymptomatic, the option was surgical treatment (BELLEI et al., 2008). Even with extraction of premolar and molar teeth, the patient returned due to recurrence of the lesions, an occurrence that is not uncommon. This fact is reported by Jennings et al. (2015) in a retrospective study of feline stomatitis, where 67% of the patients improved with dental extraction, but most required medical management with antimicrobial, anti-inflammatory, or analgesic medications following tooth extraction. Other

authors also report that extraction of teeth showed better results, and clinical cure could reach 50-60% of the cases. About 20% of the patients presented persistent caudal discrete stomatitis, but benefited from the fact that symptoms almost disappeared,

culminating in a better quality of life. Initially, extraction of premolar and molar teeth is chosen, but if there is no satisfactory answer, all teeth are extracted (BELLEI et al., 2008; HOFMANN-APPOLLO et al., 2010; HUNG et al., 2014).

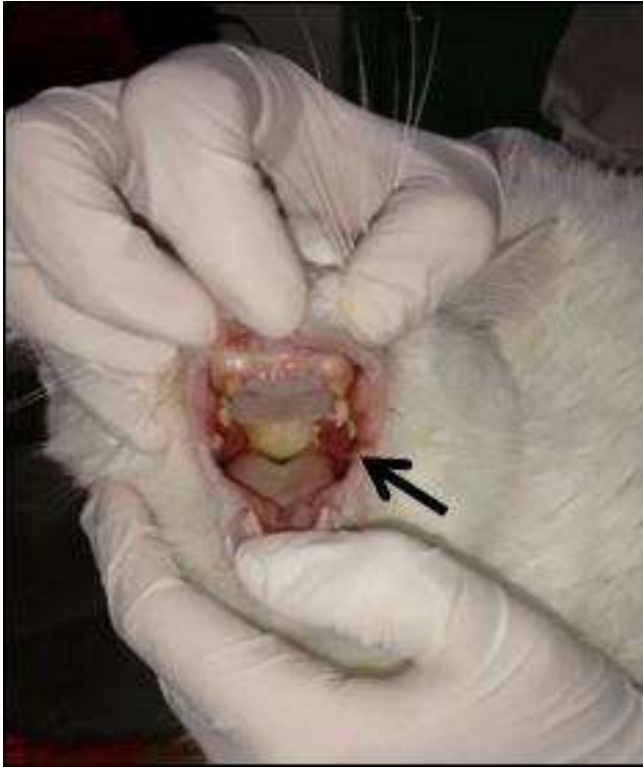

Figure 1 – Presence of ulcers in the oral cavity of a cat with Feline chronic gingivostomatitis

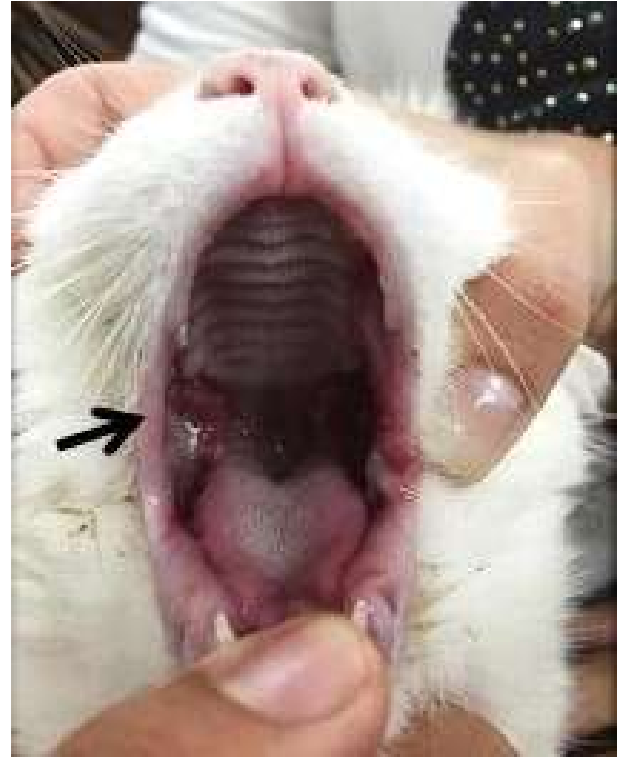

Figure 2 – Recurrence of the lesions in cat with Feline chronic gingivostomatitis

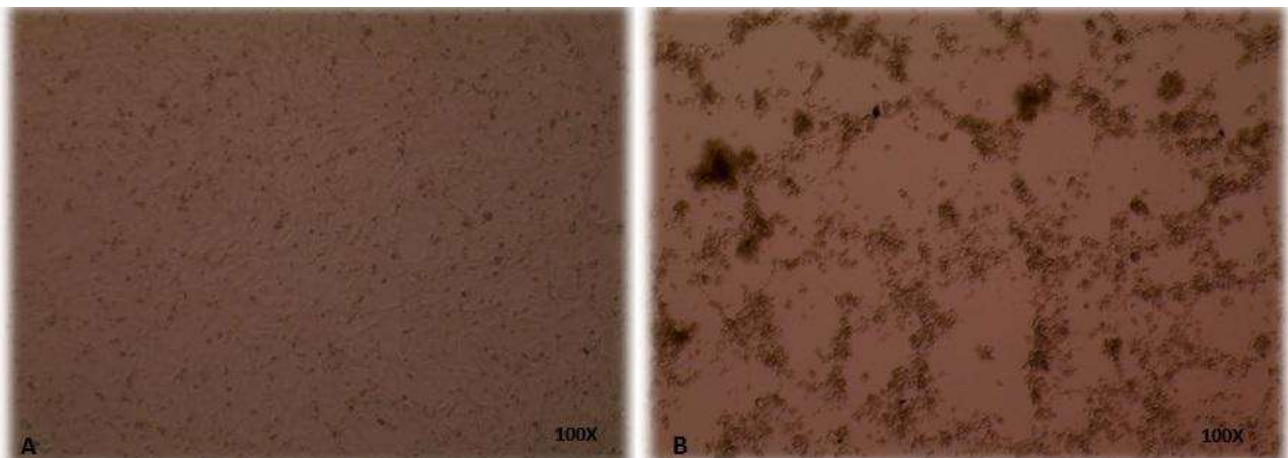


Figure 3 – A) Normal cell culture; B) Cytopathic characteristics of feline calicivirus present in the sample collected from a cat with Feline chronic gingivostomatitis

Corticosteroids are widely used in the treatment of FCGS, but controversy exists related to their use. In cases with viral involvement, administration of corticosteroids may contribute to the development and progression of the disease, and their therapeutic efficacy decreases over time (NIZA et al., 2004).

Diagnosis is based on patient history, including progression of the condition, duration of symptoms and results obtained with previously established therapy. Physical examination with inspection of the oral cavity is crucial, but laboratory findings may also be used, often indicating persistent neutropenia and hyperglobulinemia (HENNET, 2005; LYON, 2005). Histopathological examination is the gold standard (LYON, 2005).

Currently, the disease can be treated with different therapeutic protocols associated or not with the surgical treatment. Several drugs have already been used in treatment and responses differ for each animal. Until now, no treatment has been shown to be totally effective in promoting disease cure, only the control of clinical signs (HOFMANN-APPOLLO et al., 2010).

Considering disease recurrence, refractory response to treatment and findings of complementary examinations, total exodontia combined with immunomodulatory medication and antibiotic therapy was recommended to prolong the patient's life. As interferon has antiviral, antiproliferative and immunomodulatory effects that regulate inflammatory processes (NIZA et

al., 2004), a different approach was chosen using interferon alfa 2A together with periodic control of plaque accumulation on incisive and canine teeth with successful results and no subsequent recurrence of lesions. This is in agreement with a previously reported case that describes clinical improvement and reduction of lesions using immunomodulatory therapy in two cats with FCGS (LEAL et al., 2013). This treatment has several advantages, including: (i) decreased number of surgical procedures, (ii) maintenance of canine teeth that are important for feline behavior, (iii) avoiding continuous use of antibiotics in line with worldwide recommendations for the control of bacterial resistance and the effect on normal microbiota in the animal's gastrointestinal tract and, (iv) promising results of better life-long symptom control.

The animal was treated several times with antibiotics and immunosuppressive therapy as it presented recurrence of the disease even after extraction of premolar and molar teeth. The owner made treatment decisions more difficult by failing to return to the clinic for follow-up appointments on the dates required to adjust the treatment and selection of drugs. This case reports successful immunomodulatory therapy with interferon alfa 2A after extraction of all premolar and molar teeth, established based on the inflammatory nature of the disease and its association with a viral infection.

References

BELLEI, E.; DALLA, F.; MASETTI, L.; PISONI, L.; JOECHLER, M. Surgical therapy in chronic feline gingivostomatitis (FCGS). **Veterinary Research Communications**, v. 32, p. 231-234, 2008. Supplement 1. doi: 10.1007/s11259-008-9153-8.

HENNET, P. Relationship between oral calicivirus and herpesvirus carriage and "palatoglossitis" lesions. In: ANNUAL VETERINARY DENTAL FORUM & WORLD

VETERINARY DENTAL CONGRESS, 9, 2005, Orlando. **Proceedings...** Orlando: Academy of Veterinary Dentistry, American Veterinary Dental College, American Veterinary Dental Society, p. 503, 2005.

HOFMANN-APPOLLO, F.; CARVALHO, V. G. G.; GIOSO, M. A. Complexo gengivite estomatite-faringite dos felinos. **Clínica Veterinária**, v. 15, n. 84, p. 44-52, 2010.

HUNG, Y. P.; YANG, Y. P.; WANG, H. C.; LIAO, J. W.; HSU, W. L.; CHANG, C. C.; CHANG, S. G. Bovine lactoferrin and piroxicam as an adjunct treatment for lymphocytic plasmacytic gingivitis stomatitis in cats. **Veterinary Journal**, v. 202, n. 1, p. 76-82, 2014. doi: 10.1016/j.tvjl.2014.06.006.

JENNINGS, M. W.; LEWIS, J. R.; SOLTERO-RIVERA, M. M.; BROWN, D. C.; REITE, A. M. Effect of tooth extraction on stomatitis in cats: 95 cases (2000-2013). **Journal of the American Veterinary Medical Association**, v. 246, n. 6, p. 654-660, 2015. doi: 10.2460/javma.246.6.654.

LEAL, R. O.; GIL, S.; BRITO, M. T. V.; MCGAHIE, D.; NIZA, M. M. R. E.; TAVARES, L. The use of oral recombinant feline interferon omega in two cats with type II diabetes mellitus and concurrent feline chronic gingivostomatitis syndrome. **Irish Veterinary Journal**, v. 66, n. 19, p. 1-4, 2013. doi: 10.1186/2046-0481-66-19.

LYON, K. F. Gingivostomatitis. **Veterinary Clinics of North America: Small Animal Practice**, v. 35, n. 4, p. 891-911, 2005. doi: 10.1016/j.cvsm.2005.02.001.

NIZA, M. M. R. E.; MESTRINHO, L. A.; VILELA, C. L. Gengivo-estomatite crónica felina – um desafio clínico. **Revista Portuguesa de Ciências Veterinárias**, v. 99, n. 551, p. 127-135, 2004.

VEIR, J. K.; LAPPIN, M. R.; FOLEY, J. E.; GETZY, D. M. Feline inflammatory polyps: historical, clinical, and PCR findings for feline calicivirus and feline herpes virus-1 in 28 cases. **Journal of Feline Medicine and Surgery**, v. 4, n. 4, p. 195-199, 2002. doi: 10.1053/jfms.2002.0172.

WHITE, S. D.; ROSYCHUK, R. A. W.; JANIK, T. A.; DENEROLLE, P.; SCHULTHEISS, P. Plasma cell stomatitis-pharyngitis in cats: 40 cases (1973-1991). **Journal of the American Veterinary Medical Association**, v. 200, n. 9, p. 1377-1380, 1992.