

# Ultrasound diagnosis and monitoring of canine scleritis

## *Diagnóstico ultrassonográfico e monitoramento da esclerite em cães*

Michelle Barboza Pereira BRAGA-SÁ<sup>1</sup>; Eduardo PERLMANN<sup>1</sup>;  
Ana Carolina Almeida de GÓES<sup>1</sup>; Renata SQUARZONI<sup>1</sup>; Angélica Mendonça Vaz SAFATLE<sup>1</sup>;  
Paulo Sergio de Moraes BARROS<sup>1</sup>; Aline Adriana BOLZAN<sup>1</sup>

<sup>1</sup> Universidade de São Paulo, Faculdade de Medicina Veterinária e Zootecnia, São Paulo – SP, Brazil

---

### Abstract

Scleritis is a severe painful inflammatory and vision-threatening disease. The purpose of this paper is to describe two cases of scleritis in dogs treated with immunosuppressors and monitored by ocular ultrasound. In both cases the ocular wall presented marked thickening and the ultrasonic exams were repeated for weeks showing progressive improvement allowing adjusting the dosage of the medications. In conclusion, ocular ultrasound is a useful tool in the diagnosis and management of scleritis in dogs.

**Keywords:** Scleritis. Ultrasound. Dogs.

---

### Resumo

A esclerite é uma doença inflamatória extremamente dolorosa e pode afetar seriamente a visão. O presente trabalho descreve dois casos de esclerite em cães tratados com imunossuppressores e monitorados pela ultrassonografia ocular. Em ambos os casos, a parede ocular apresentava acentuado espessamento e as avaliações ultrassonográficas foram repetidas por semanas, revelando melhoria progressiva e permitindo ajustes na dosagem das medicações. Em conclusão, a ultrassonografia ocular é um instrumento útil no diagnóstico e tratamento da esclerite em cães.

**Palavras-chave:** Esclerite. Ultrassom. Cães.

---

### Introduction

Scleritis is a severe, painful inflammation of the sclera, and is considered a vision-threatening disease (JABS et al., 2000; OKHRAVI et al., 2005). It may involve the anterior sclera, posterior sclera, or both, and it may also involve adjacent structures such as the cornea, episclera, and uvea (OKHRAVI et al., 2005). The posterior scleritis may be an extension of the anterior process (GRAHN; SANDMEYER, 2008). The disease is classified as primary (idiopathic immune-mediated disease) or secondary (traumas and infectious diseases), focal or diffuse, and necrotizing or non-necrotizing (GRAHN; SANDMEYER, 2008; OKHRAVI et al., 2005; RAHMAN; BISWAS, 2008; URBANO et al., 2002).

In humans, anterior scleritis accounts for 90% of cases, and diffuse anterior scleritis is the most frequently occurring form (GRAHN; SANDMEYER, 2008). Association with a systemic autoimmune disease is common (GRAHN; SANDMEYER,

2008; JABS et al., 2000; RAHMAN; BISWAS, 2008; RAMSEY, 2002), with rheumatoid arthritis, a connective tissue disorder, being the most prevalent, followed by Wegener's granulomatosis, a vasculitis (GRAHN; SANDMEYER, 2008; RAHMAN; BISWAS, 2008; RIONO; HIDAYAT; RAO, 1999; SMITH; MACKENSEN; ROSENBAUM, 2007). Bilateral scleritis occurs in 40% to 80% of cases, mainly in patients with concomitant systemic disease (BENSON et al., 1979).

Scleritis in dogs is categorized as idiopathic non-necrotizing, necrotizing, and is secondary to

---

#### Correspondence to:

Michelle Barboza Pereira Braga-Sá  
Universidade de São Paulo, Faculdade de Medicina Veterinária e Zootecnia  
Av. Professor Doutor Orlando Marques de Paiva, 87  
CEP 05508-270, São Paulo, SP, Brazil  
e-mail: michellebarbosa@usp.br

Received: 20/06/2014

Approved: 17/11/2014

trauma, infectious organisms, and surgery (GRAHN; SANDMEYER, 2008). The disease is considered immune-mediated and organ-specific, and there is no evidence for underlying systemic connective tissue disturbance (DAY; MOULD; CARTER, 2008).

Non-necrotizing scleritis is uncommon in dogs. Its manifestation can be unilateral or bilateral, characterized by a diffuse thickening of sclera and conjunctival and episcleral hyperemia. If it is chronic or very extensive, it may lead to choroiditis with retinal detachment and degeneration. Clinical presentation is very similar to diffuse episcleritis, with the exception of posterior scleritis and more severe inflammation. It is also similar to necrotizing scleritis, but collagen necrosis is not observed. The pathogenesis of non-necrotizing scleritis is not completely understood and is assumed to be immune-mediated (GRAHN; SANDMEYER, 2008).

Scleral inflammation is usually suspected from the clinical history, and it is confirmed by observation of characteristic ocular signs (OKHRAVI et al., 2005; RAHMAN; BISWAS, 2008). Scleritis is characterized by edema in the episcleral and scleral tissues with injection of superficial and deep episcleral vessels (JABS et al., 2000). Clinical signs include intense ocular pain, decreased vision, proptosis and fundus abnormalities such as choroidal folds and detachment, cystoids macular edema, retinal detachment, optic neuritis (GRAHN; SANDMEYER, 2008; RAHMAN; BISWAS, 2008), and vitreitis (URBANO et al., 2002). Clinical signs can be less obvious if involvement is posterior (OKHRAVI et al., 2005).

Complementary exams such as ocular ultrasound and others are useful in establishing the diagnosis of cases of posterior disease (OKHRAVI et al., 2005; RAHMAN; BISWAS, 2008). B-mode ultrasound is the most useful method in diagnosing posterior scleritis in humans (BENSON et al., 1979; BISWAS et al., 1998; McCLUSKEY et al., 1999; NANDI et al., 2009; OKHRAVI et al., 2005; PERRI et al., 1998), with computed tomography scanning demonstrating it has

no advantages to ultrasound for the diagnosis of this condition (McCLUSKEY et al., 1999; NANDI et al., 2009).

Ocular complications are frequent in posterior scleritis' therefore, it is very important to establish early diagnosis and treatment. The management consists in treating the cause, controlling inflammation, and reducing damage to the eye (RAHMAN; BISWAS, 2008). Topical anti-inflammatory therapy is used to improve comfort (GRAHN; SANDMEYER, 2008); however, its routine use is insufficient to control the disease (GRAHN; SANDMEYER, 2008; JABS et al., 2000; RAHMAN; BISWAS, 2008). Systemic medications such as nonsteroidal anti-inflammatory drugs, corticosteroids, and immunomodulatory agents are required in the majority of the cases (JABS et al., 2000; RAHMAN; BISWAS, 2008).

The purpose of this paper is to describe the importance of ocular ultrasound as a tool for diagnosis and management in two cases of scleritis in dogs with favorable outcomes.

## Material and Method

### *Animal 1*

A 10-year-old female Dalmatian referred to the Ophthalmology Service of the Veterinary Hospital at College of Veterinary Medicine, Sao Paulo University, Brazil, was presented with a history of blindness for three days. Ophthalmic examination revealed bilateral ocular hyperemia and episcleral injection. The patient demonstrated impaired visual acuity with absence of the menace reflex in both eyes; however, direct and consensual pupillary light were present. Ocular discharge, pain, pruritis, and buphthalmia were not observed. Tear production (Schirmer tear test<sup>®</sup>, Ophthalmos, Sao Paulo, Brazil) and intraocular pressure (Tono-Pen XL<sup>®</sup>, Bio-Rad X, Berkeley, California, USA) measurements were within normal values. Retinal folds were noted in the left eye during the fundoscopic exam (Binocular indirect ophthalmoscope IO-H<sup>®</sup>, Neitz Instruments, Tokyo, Japan), which was suggestive of retinal detachment.

Ultrasound examination was performed using a B-mode ocular ultrasound unit (Accutome Ultrasound Advent A/B System; Accutome, Malvern, Pennsylvania, USA) with a small and round surface 12 MHz transducer. The patient was treated with anesthetic eye drops (Anestalcon® 0,5%, Alcon Labs, Sao Paulo, Brazil). Acoustic gel was applied to the transducer, which was then gently placed to the cornea.

The ultrasound findings (Figure 1) revealed an intense degree of thickening of the posterior ocular wall compression of the vitreous chamber an anechoic area behind the posterior wall, considered as sub-tenon fluid; and partial retinal detachment in the left eye (Figure 1a). These findings were suggestive of scleritis with retinal detachment. Axial length was 18.6 mm in the right eye (OD) and 18.0 mm in the left eye (OS).

The patient was treated with oral prednisone (1 mg/kg/day) and topical prednisolone acetate drops 1% (Pred Fort®, Allergan, Sao Paulo, Brazil), in both eyes (OU), three times a day. Vision improved in one week after initial treatment, and ocular ultrasound revealed only a mild thickening, an improvement of

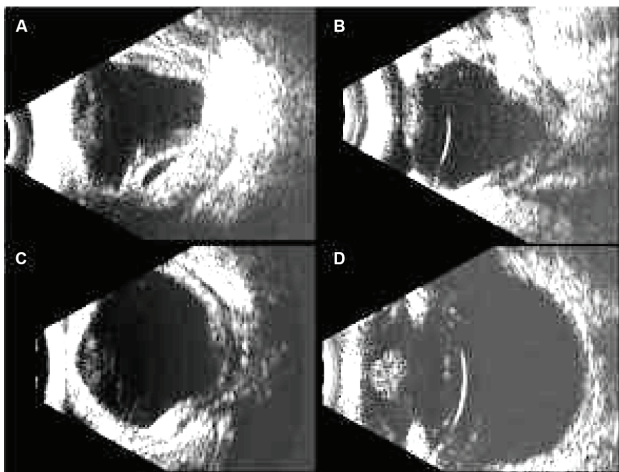


Figure 1 – B-mode ocular ultrasound of patient 1. A. Scleral thickening with retinal detachment (first day). Edema in the retrobulbar space represented by fluid in the tenon capsule at 7 days (B) and 14 days follow-up (C). D. Resolution posterior wall thickness and curvature corresponding to improvement of the ultrasound findings (1 year follow-up)

Source: (VETERINARY HOSPITAL-USP, 2014)

the posterior ocular wall, and no evidence of retinal detachment. Monthly ocular ultrasound evaluations monitored gradual improvement of posterior ocular wall thickness and normal curvature (Figure 1c), and vision was normal at this point. After treatment, axial length was approximately 20.0 mm in OU.

Systemic steroid therapy was slowly reduced and discontinued after 3 months; oral azathioprine (1 mg/kg/day) was initiated at this time. Topical prednisolone acetate drops were applied twice daily and maintained for six months.

The azathioprine dose was gradually reduced (1mg/kg, q48h), and maintained until the last visit (one year after initial presentation). Topical prednisolone acetate drops 1%, were used once daily for two years. Patient follow-up visits showed no recurrence for four years. Periodic ultrasound evaluations have not indicated ocular changes; however, episcleral vessels remain mildly dilated.

#### Animal 2

A 7-year-old female mixed breed dog was referred to the Ophthalmology Service of the Veterinary Hospital at the College of Veterinary Medicine, Sao Paulo University, Brazil, presenting with buphthalmia and redness OU. The patient had suffered from blindness for fifteen days. Pruritis, sanguineous discharge, and blefarospasm were observed by the owners. Ophthalmic examination revealed lagophthalmos and exophthalmos in both eyes, buphthalmia in the right eye, and bilateral subconjunctival hemorrhage. There was dense neovascularization in the right eye. Due to severe pain, tonometry was carried out at the time of presentation, and the anterior chamber was not visible because of deep corneal edema (Figure 2).

Ocular ultrasound revealed increase thickness of the posterior ocular wall, with marked compression of the vitreous chamber, resulting in complete abnormality of posterior wall curvature (Figure 3a and 4a). An echographic diagnosis of scleritis was performed. There were mobile, point-like echoes in the vitreous



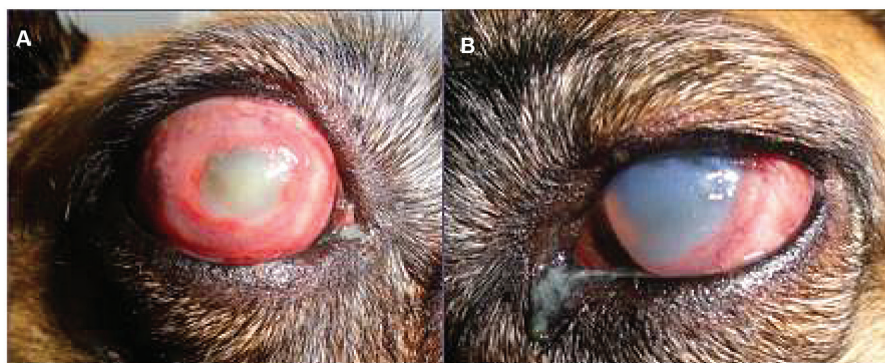

Figure 2 – Photograph of OD (A) and OS (B) of patient 2. First day exhibiting lagophthalmos and exophthalmos OU, buphthalmia OD; deep corneal edema OS; bilateral subconjunctival hemorrhage

Source: (VETERINARY HOSPITAL-USP, 2014)

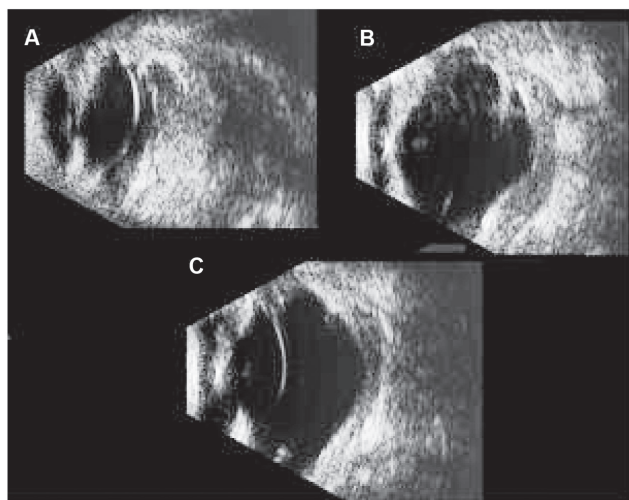


Figure 3 – B-mode ocular ultrasound patient 2 (OD). A. Point-like echos in vitreous corresponding to inflammatory cells and/or intraocular hemorrhage (1 day). B. Marked thickening of the posterior wall associated with fluid in the tenon space. Note the irregular posterior wall curvature. The vitreous became anechoic (7 days follow-up). C. Normal curvature and decrease of the thickening of the posterior ocular wall (30 days follow-up)

Source: (VETERINARY HOSPITAL-USP, 2014)

of the right eye (Figure 3a), which are compatible with inflammatory cells and/or intraocular hemorrhage. The initial measurements of axial length were 18.0 mm OD and 19.7 mm OS.

Initial treatment consisted of topical 1% prednisolone (Pred Fort<sup>®</sup>, Allergan, Sao Paulo, Brazil) six times daily, topical tobramycin four times daily,

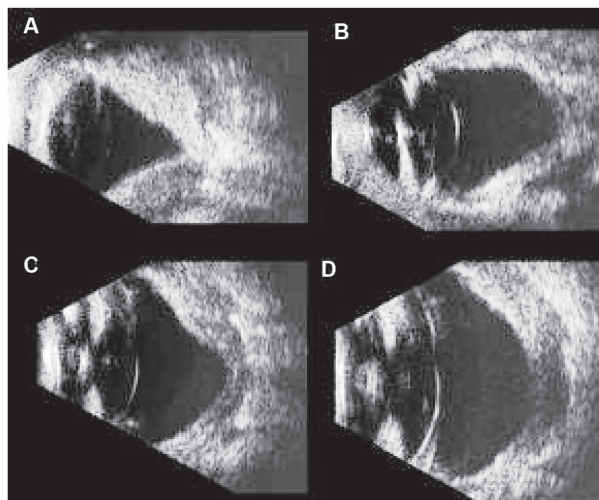


Figure 4 – B-mode ocular ultrasound of patient 2 (OS). A. Marked thickening and irregular curvature of the posterior wall (first day). B. Improvement of the posterior ocular aspect (7 days follow-up). C. Posterior wall associated with fluid in the tenon space (7 days follow-up). D. Improvement in ultrasound findings (1 year follow-up)

Source: (VETERINARY HOSPITAL-USP, 2014)

and artificial tears (Vidisic<sup>®</sup> gel, Bausch & Lomb, Sao Paulo, Brazil) three times daily. The patient received oral prednisone (2 mg/kg/day) and enrofloxacin (5 mg/kg/q12h). After 17 days, clinical improvement of ocular signs was observed; however, vision did not return. The right eye developed hypotension.

Ocular ultrasound examination repeated every two

weeks revealed gradual improvement of the posterior wall thickness and normal curvature OU. Vitreous was completely anechoic OD (Figure 3c).

Vision was restored in the left eye after three weeks of the initial treatment. The ophthalmic signs remained favorable, with only scleral edema and corneal degeneration OD. The dose of prednisone was reduced to (40mg/day), and azathioprine was added (1 mg/kg/day). Topical prednisolone acetate drops 1% were maintained once daily. After five weeks, prednisone was decreased (10 mg/day), and azathioprine was maintained (30 mg/day). Vision has been maintained until the last visit, seven weeks after the onset of symptoms.

No ultrasound and clinical recurrence of the scleritis was noted and the vision remained after follow-up of two months with azathioprine therapy.

## Discussion

Ocular ultrasound has become an essential technique for exploring the globe and orbit. In most patients, clinical examination of the eye usually provides enough information to reach an ophthalmic diagnosis (GONZALEZ; RODRIGUEZ; GARCIA, 2001). Ultrasound has great value in identification and differentiation of ocular changes and also in the measurement of the eye and its tissues or structures (STERNLICHT; ALLERMANN; MUCCIOLI, 2001), providing additional information which allows the clinician to establish treatment and prognosis of many diseases (GONZALEZ; RODRIGUEZ; GARCIA, 2001).

In dogs, scleritis is considered an immune-mediated, organ-specific process in which there is no evidence for underlying systemic connective tissue disease (DAY; MOULD; CARTER, 2008). Neither of the two patients in this report presented systemic alterations. Because of the limited cases reported in veterinary literature, it is necessary to compare this disease to those described in humans (DENK et al., 2012).

Differential diagnosis may include posterior and anterior uveitis, Vogt-Koyanagi-Harada syndrome, glaucoma, intraocular tumors, and inflammatory orbital disorders, all of which can affect the sclera (BISWAS, 1998; PERRI et al., 1998). It has been stated that is important to distinguish nodular posterior scleritis from choroidal melanoma (PÉREZ-CAMPAGNE et al., 2007).

Diffuse thickening of the sclera, severe ocular pain, visual impairment, proptosis and fundus abnormalities such as retinal detachment as reported, as observed in both cases 1 and 2. Also, patient 2 presented with severe sclera and corneal involvement, which corroborate cases previously described (DENK et al., 2012).

In the right eye of case 2, excessive point-like echoes in the vitreous were observed. This is probably an intraocular extension of scleral inflammation. After treatment, the vitreous became completely anechoic, but clinically the eye was hypotense and blind.

Thickening of the posterior ocular wall and retinal detachment were observed in the ocular ultrasound. These findings are in agreement with previous studies which showed the same signs in cases of posterior scleritis in humans (BISWAS, 1998; MACHADO et al., 2009; PERRI et al., 1998). To the authors' knowledge there is no description of scleritis by ultrasound in dogs.

It is not possible to differentiate the retina-choroid-sclera complex by ultrasound imaging, so this complex is termed the posterior wall (GONZALEZ; RODRIGUEZ; GARCIA, 2001). In both cases, due to the presence of fluid in the sub-tenon space, there was an anechoic area behind the thickened posterior wall, thereby causing further delimitation of the posterior wall.

In humans, a disease characteristic known as "T signal" (BISWAS, 1998; MACHADO et al., 2009; PERRI et al., 1998) was not evident at the time of presentation due to the advanced stage of intense

wall thickening and excessive loss of curvature of the posterior wall in both cases.

As posterior wall thickness decreased, retinal detachment regressed, vision returned to an apparently normal state, and discomfort was alleviated. However, clinical observation showed that the right eye of patient 2 developed hypotony and blindness. The present findings are consistent with ocular complications in necrotizing scleritis in humans, which can lead to retinal detachment and phthisis bulbi in some cases (URBANO et al., 2003).

The treatments of choice for scleritis are topical and systemic immunosuppressive drugs or immunomodulatory regimens for management (BISWAS, 1998; DAY; MOULD; CARTER, 2008; DENK et al., 2012; GRAHN; SANDMEYER, 2008; MACHADO et al., 2009; PERRI et al., 1998). Systemic corticosteroids are required to provide maximal regression (GILGER; BENTLEY; OLLIVIER, 2007). In the present investigation, the association between systemic corticosteroids and azathioprine has contributed to disease control.

Once remission is established, immunosuppressive therapy may gradually be reduced (GRAHN; SANDMEYER, 2008). Despite there being no recurrence after treatment in some animals, most cases may require low-dose maintenance therapy, as reported in this paper. There was no recurrence of clinical signs or ultrasound alterations in both animals, but the patients were maintained with low-dose therapy.

Posterior sclera involvement was more pronounced in the ultrasound images as compared to that observed in the ophthalmic examination of the anterior sclera. In both animals no biopsy was performed the diagnosis was clinical, ultrasound and therapeutic. Thus, scleritis is not classified as granulomatous because this is a histopathologic characterization, so it is more concise to classify these cases as they were manifested, as diffuse scleritis. The nomenclature "posterior scleritis" has not been described in dogs, but as the posterior sclera was markedly affected, this could be suited to the present cases. Moreover, the ultrasound findings are similar to those described in the human literature regarding posterior scleritis (BISWAS, 1998; MACHADO et al., 2009; OKHRAVI et al., 2005; PERRI et al., 1998), but more exacerbated.

## Conclusion

Scleritis is an ocular disease that can result in visual impairment. Therefore, it is emphasized the important contribution of ophthalmic ultrasound in providing a rapid and accurate diagnosis, which facilitates early treatment and avoids visual complications. The method provided a satisfactory approach to monitor the disease and contribute to positive outcomes of both cases reported. In conclusion, ocular ultrasound is a useful tool in the diagnosis and management of scleritis in dogs.

## References

- BENSON, W. E.; SHIELDS, J. A.; TASMAN, W.; CRANDALL, A. S. Posterior scleritis – a cause of diagnostic confusion. **Archives of Ophthalmology**, v. 97, n. 8, p. 1482-1486, 1979.
- BISWAS, J.; MITTAL, S.; GANESH, S. K.; SHETTY, N. S.; GOPAL, L. Posterior scleritis: clinical profile and imaging characteristics. **Indian Journal of Ophthalmology**, v. 46, n. 4, p. 195-202, 1998.
- DAY, M. J.; MOULD, J. R. B.; CARTER, W. J. An immunohistochemical investigation of canine idiopathic granulomatous scleritis. **Veterinary Ophthalmology**, v. 11, n. 1, p. 11-17, 2008.
- DENK, N.; SANDMEYER, L. S.; LIM, C. C.; BAUER, B. S.; GRAHN, H. B. A retrospective study of the clinical, histological, and immunohistochemical manifestations of 5 dogs originally diagnosed histologically as necrotizing scleritis. **Veterinary Ophthalmology**, v. 15, n. 2, p. 102-109, 2012.
- GILGER, B. C.; BENTLEY, E.; OLLIVIER, F. J. Diseases and surgery of the canine cornea and sclera. In: GELATT, K. N. **Veterinary ophthalmology**. 4th ed. Iowa: Blackwell Publishing, 2007. p. 690-752.
- GONZALEZ, E. M.; RODRIGUEZ, A.; GARCIA, I. Review of ocular ultrasonography. **Veterinary Radiology & Ultrasound**, v. 42, n. 6, p. 485-495, 2001.
- GRAHN, B. H.; SANDMEYER, L. S. Canine episcleritis, nodular episclerokeratitis, scleritis and necrotic scleritis. **Veterinary Clinics of North America: Small Animal Practice**, v. 38, n. 2, p. 291-308, 2008.
- JABS, D. A.; MUDUN, A.; DUNN, J. P.; MARSH, M. J. Episcleritis and scleritis: clinical features and treatment results. **American Journal of Ophthalmology**, v. 130, n. 4, p. 469-476, 2000.
- MACHADO, D. O.; CURI, A. L. L.; BESSA, T. F.; CAMPOS, W. R.; ORÉFICE, F. Esclerite posterior: características clínicas, associação sistêmica, tratamento e evolução de 23 pacientes. **Arquivo Brasileiro de Oftalmologia**, v. 72, n. 3, p. 321-326, 2009.
- McCLUSKEY, P. J.; WATSON, P. G.; LIGHTMAN, S.; HAYBITTLE, J.; RESTORI, M.; BRANLEY, M. Posterior scleritis. **Ophthalmology**, v. 106, n. 12, p. 2380-2386, 1999.
- NANDI, K.; SARKAR, S.; RANJAN, P.; JYOTIRMAY, B. Posterior scleritis: clinical profile and visual outcome in a series of 32 patients. In: ALL INDIAN OPHTHALMOLOGY CONFERENCE, 6., 2009, Jaipur. **Proceedings...** Available from: <<http://www.aioseducation.org/papers2009/UVEA/Uvea6.pdf>>. Viewed: 31 Jan. 2013.
- OKHRAVI, N.; ODUFUWA, B.; McCLUSKEY, P.; LIGHTMAN, S. Scleritis. **Survey of Ophthalmology**, v. 50, n. 4, p. 351-363, 2005.
- PÉREZ-CAMPAGNE, E.; GUÉX-CROSIER, Y.; SCHALENBOURG, A.; UFFER, S.; ZOGRAFOS, L. Giant nodular posterior scleritis compatible with ocular sarcoidosis simulating choroidal melanoma. **Archivos de la Sociedad Española de Oftalmología**, v. 82, n. 9, p. 563-566, 2007.
- PERRI, P.; MAZZEO, V.; DE PALMA, P.; PASTENA, B.; POLICE, G.; RAVALLI, L.; ROSSI, A. Posterior scleritis: ultrasound findings in two cases. **Ophthalmologica**, v. 212, n. 1, p. 110-112, 1998.
- RAHMAN, Z.; BISWAS, J. Current approach in diagnosis and management of scleritis. **Kerala Journal of Ophthalmology**, v. 20, n. 4, p. 341-348, 2008.
- RAMSEY, D. T. The sclera, episclera and corneoscleral limbus. In: PETERSEN-JONES, S.; CRISPIN, S. **BSAVA manual of small animal ophthalmology**. 2nd ed. Gloucester: British Small Animal Veterinary Association, 2002. p. 155-161.
- RIONO, W. P.; HIDAYAT, A. A.; RAO, N. A. Scleritis: a clinicopathologic study of 55 cases. **Ophthalmology**, v. 106, n. 7, p. 1328-1333, 1999.
- SMITH, J. R.; MACKENSEN, F.; ROSENBAUM, J. T. Therapy insight: scleritis and its relationship to systemic autoimmune disease. **Nature Clinical Practice Rheumatology**, v. 3, n. 4, p. 219-226, 2007.
- STERNLICHT, T.; ALLEMANN, N.; MUCCIOLI, C. O emprego da biomicroscopia ultra-sônica no diagnóstico e evolução clínica dos diferentes tipos de esclerite anterior. **Arquivo Brasileiro de Oftalmologia**, v. 64, n. 3, p. 229-232, 2001.
- URBANO, A. P.; URBANO, A. P.; TORIGOE, A. M. S.; URBANO, I.; KARA-JOSÉ, N. Esclerite infecciosa espontânea por *Nocardia asteroides*: relato de caso. **Arquivo Brasileiro de Oftalmologia**, v. 66, n. 2, p. 223-225, 2003.
- URBANO, A. P.; URBANO, A. P.; URBANO, I.; KARA-JOSÉ, N. Episclerite e esclerite. **Arquivo Brasileiro de Oftalmologia**, v. 65, n. 5, p. 591-598, 2002.