

Braz. J. Vet. Res. anim. Sci.  
São Paulo, v.32, n.3, p. 170-172, 1995

## DERMOID SINUS IN A GREAT PYRENEES DOG

### *SINUS DERMÓIDE EM CÃO DOS PIRENEUS*

Aparecido Antônio CAMACHO<sup>1</sup>; José Luiz LAUS<sup>2</sup>; Victório VALERI<sup>2</sup>; Fábio Valiengo VALERI<sup>2</sup>; Newton NUNES<sup>3</sup>

#### SUMMARY

In the scientific literature this is the first case of dermoid sinus described in a Great Pyrenees dog. The diagnosis was made on the basis of anamnesis and dermatology and histopathology findings. The clinical management was excision of the sinus, the owners being informed about the congenital hereditary characteristics of the disease. Six months after surgery the animal was reevaluated on the during several return visits and no dermatologic lesion was detected.

**UNITERMS:** Dermoid cyst; Dogs

#### INTRODUCTION

Dermoid sinus is a congenital dermatologic disease characterized by the presence of single or multiple nodules in the dorsal neck region or in the sacral region, more frequently occurring in Rhodesian Ridgeback dogs, although it has also been reported in other kinds such as Boxer and Shih-Tzu (STEYN et al.<sup>1</sup>, 1939; ANTINI<sup>1</sup>, 1979; SELCER et al.<sup>8</sup>, 1984; HATHCOCK et al.<sup>3</sup>, 1979).

Dermoid sinus is believed to be caused by a gene complex or by a single recessive gene, although studies reported by MANN; STRATTON<sup>2</sup> (1966) have focussed only on the hereditary nature of the affection.

The dermoid sinus lesions is characterized by an incomplete separation between the spinal cord and the skin during the closing of the neural tube in embryo development. The connection of fine hollow cords on the skin surface occurs at the level of the duramater in the sacral region or in the region of the 2<sup>nd</sup> and 3<sup>rd</sup> vertebrae (MULLER; KIRK<sup>5</sup>, 1976).

The macroscopic aspect of the lesion demonstrates small nodules with fistulae on the epidermal surface, with protrusion of spiraled hair tufts, and the presence of sebaceous material and of keratin remnants accompanied by inflammation, possibly leading to meningomyelitis and nervous abnormalities (MULLER et al.<sup>6</sup>, 1989).

The diagnosis is made on the basis of anamnesis, physical examination, fistulography, and biopsy (SCKEOMAN<sup>7</sup>, 1989).

#### CASE REPORT AND DISCUSSION

The main objective of the present report is to describe the diagnosis of a dermoid sinus in a male Great Pyrenees dog aged 1 year and 8 months from the mountain region of the State of Rio de Janeiro. The animal was admitted to the Veterinary Hospital of the Faculty of Agrarian and Veterinary Sciences of Jaboticabal, UNESP. Clinical history revealed that the animal had been presenting skin lesions for 30 days and that he had been unsuccessfully treated with "antibiotics".

Physical/dermatologic examination showed the presence of a lesion located around the entire cervical region. Macroscopic examination revealed edematous and hyperemic skin with orifices presenting hair and exuding sebaceous and purulent matter (Fig. 1, 2, 3).

The clinical diagnosis of dermoid sinus was confirmed by complementary tests including skin biopsy and standard histopathology of the dermal lesions performed at the Pathology and Cytology Institute<sup>6</sup>. Microscopy revealed that the material consisted of squamous epithelial cells of a hyperactive pattern, with isolated desquamation. Cytoplasmic morphology showed a medium rounded volume, with the presence of microvacuolization, with nuclear characteristics of fine and homogeneous chromatin, and with discrete nuclei. Lymphocytes, a mild leukocyte reaction and bacteria were also observed in the infiltrate (Fig. 5, 6).

1 - Professor Assistente Doutor - Faculdade de Ciências Agrárias e Veterinárias da UNESP, Campus de Jaboticabal - SP

2 - Médico - Instituto de Patologia e Citologia "Prof. Dr. Victório Valeri" - SP

3 - Professor Assistente - Faculdade de Ciências Agrárias e Veterinárias da UNESP, Campus de Jaboticabal - SP

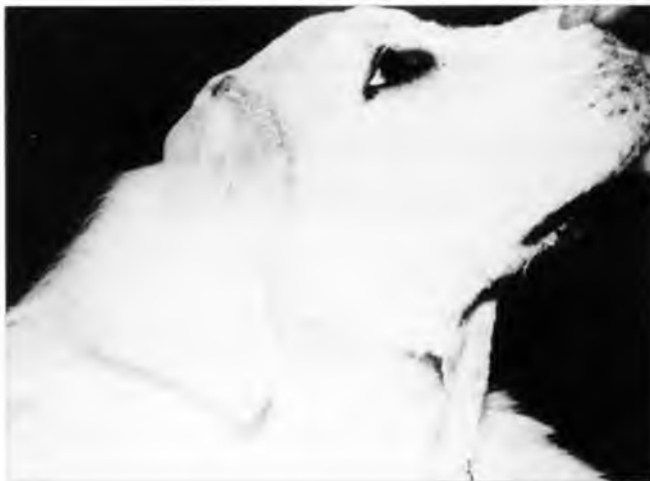According to Gammie<sup>2</sup> (1986), the most indicated therapeutic conduct in cases of dermoid sinus is surgical exeresis. This procedure was followed in the present case in two stages due to the wide extension of the lesion. Surgery was performed by elliptic skin excision in order to reach all external lesions, and was then followed by ample subcutaneous divulsion up to various cords observed, so they could be dissected, sutured and sectioned. Finally, the subcutaneous tissue was rejoined with single n° 2 catgut and the skin was sutured with single n° 4 nylon stitches. Dressings based on 10% Timerosal and daily injections of ampicillin at the dose of 50 mg/kg body weight were prescribed. The skin stiches were removed 10 days later.

The animal was reevaluated for six months on the occasion of several return visits and was found to be free of any dermatologic lesion (Fig. 4).

It should be pointed out that an attempt was made to investigate the occurrence of dermoid sinus in other Great Pyrenees dogs from the same breeder, since the breeder reported that a similar disease had been observed in other dogs. However, these dogs could not be located because they were probably taken to other states by their owners.

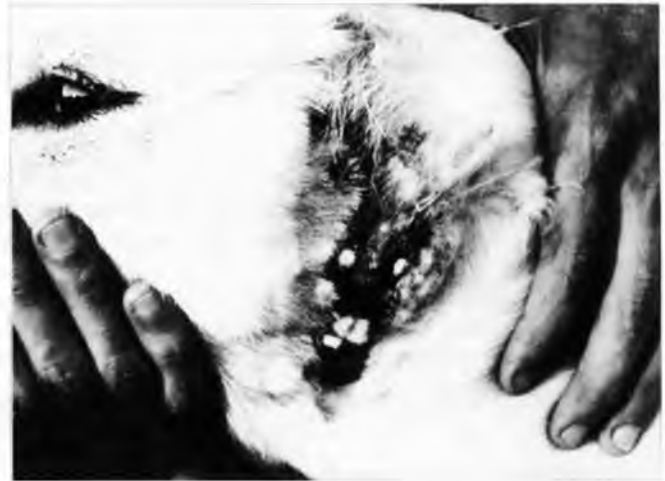In summary, the present report: 1) demonstrates that the Great Pyrenees dog breed can also be affected by dermoid sinus; 2) justifies control by the prevention of reproduction of affected animals on the part of veterinarians and breeders; 3) supports the success of surgical treatment for the correction of dermoid sinus.

\* Prof. Dr. Victório Valeri - Pathology and Cytology Institute.



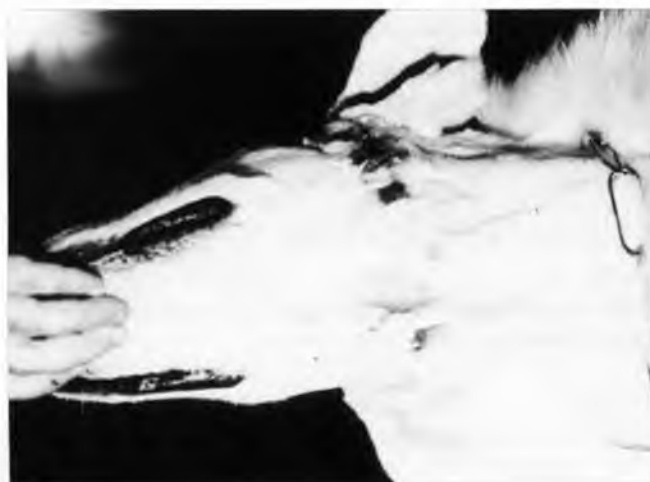**FIGURE 1**

Dermoid sinus in a Great Pyrenees dog: right lateral view.



**FIGURE 2**

Dermoid sinus in a Great Pyrenees dog: note the fistulae on the epidermal surface with protrusion of spiraled hair tufts.



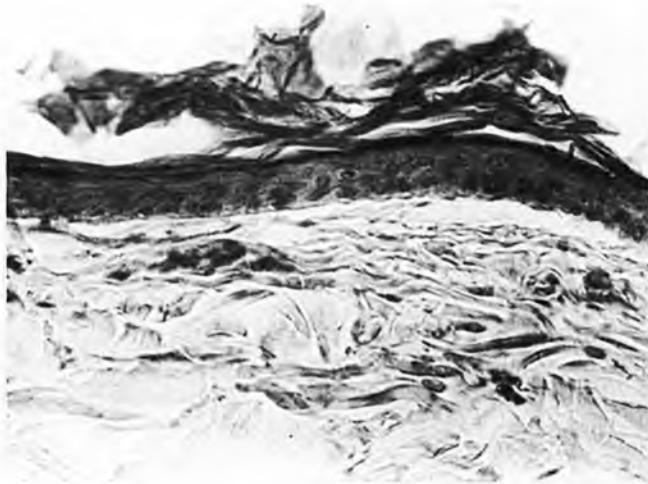**FIGURE 3**

Dermoid sinus in a Great Pyrenees dog: ventral view.



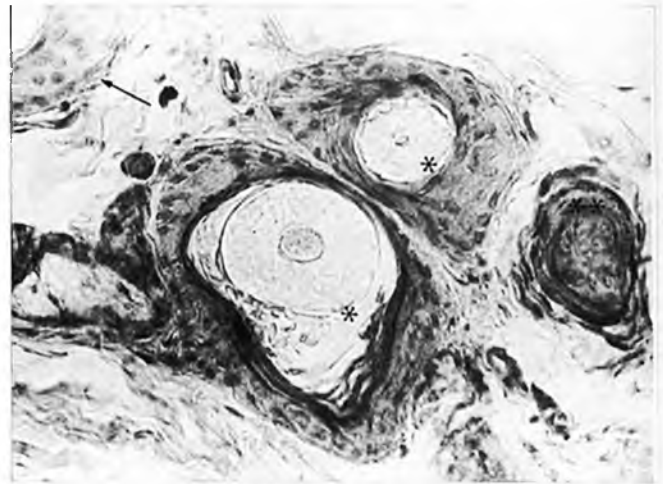
**FIGURE 4**

Great Pyrenees dog 6 months after exeresis of the dermoid sinus.



**FIGURE 5**

Microscopic aspect of a dermoid sinus in a dog. Note the stratified, keratinized epithelium lying on top of fibrous tissue. HE, 400 x.



**FIGURE 6**

Macroscopic aspect of a dermoid sinus in a dog. Note two pilose follicles (\*) and a sebaceous gland (\*\*) located immediately below the epithelium (arrow). HE, 400 x.

## RESUMO

Os autores relatam a ocorrência do primeiro caso de Sinus Dermóide em Cão dos Pireneus. O diagnóstico fundamentou-se na história clínica, nos achados dermatológicos e na histopatologia. A conduta clínica indicada foi a exérese do Sinus e a orientação do proprietário no sentido de excluir o animal da vida reprodutiva.

**UNITERMOS:** Cisto dermóide; Cães

## REFERENCES

- 1-ANTIN, I.P. Dermoid in a Rhodesian Ridgeback. *Journal of the American Veterinary Medical Association*, v.157, p.961-2, 1970.
- 2-GAMMIE, J.S. Dermoid sinus removal in a Rhodesian Ridgeback dog. *Canadian Veterinary Journal*, v.27, p.250-1, 1986.
- 3-HATHCOCK, J.T.; CLAMPETT, E.G.; BROADSTONE, R.V. Dermoid sinus in a Rhodesian Ridgeback. *Veterinary Medicine Small Animal Clinician*, v.74, p.53-6, 1979.
- 4-MANN, G.E.; STRATTON, J. Dermoid sinus in Rhodesian Ridgeback. *Journal of Small Animal Practice*, v.7, p.631-42, 1966.
- 5-MULLER, G.H.; KIRK, R.W. *Small animal dermatology*, 2.ed. Philadelphia, W.B. Saunders, 1976.
- 6-MULLER, G.H.; KIRK, R.W.; SCOTT, D.W. *Small animal dermatology*, 4.ed. Philadelphia, W.B. Saunders, 1989.
- 7-SCKEOMAN, L.J. *Practical canine dermatology*, 3.ed. California, A.V.P., 1989.
- 8-SELCKER, E.A.; HELMAN, R.G.; SELCKER, R.R. Dermoid sinus in a Shih-Tzu and a Boxer. *Journal of the American Animal Hospital Association*, v.20, p.634-6, 1984.
- 9-STEYN, H.P.; QUINLAN, J.; JACKSON, C.A., apud MANN, G.E.; STRATTON, J., Ridgeback dogs. *Journal of the American Veterinary Medical Association*, v.10, p.170-4, 1939.

Recebido para publicação em 05/05/94  
Aprovado para publicação em 13/12/95