

STANDARDIZATION OF A NEW PRECORDIAL CHEST LEADS SYSTEM IN THE DOG

ALEXANDRE AMARAL NUNES
Médico Veterinário

PAULO JORGE MOFFA
Médico
Instituto do Coração da Faculdade de Medicina da USP

MASAO IWASAKI
Professor Livre-Docente
Faculdade de Medicina Veterinária e Zootecnia da USP

NUNES, A.A.; MOFFA, P.J.; IWASAKI, M. Standardization of a new precordial chest leads system in the dog. *Braz. J. vet. Res. anim. Sci.*, São Paulo, 27(2):233-246, 1990.

SUMMARY: This study proposes a new precordial chest system in which the exploring electrode forms an approximately perpendicular plane to the cardiac apical-basal axis (oblique lateri-lateral plane). The established positions are closely related, successively recording the right ventricle, interventricular septum and left ventricle. The method was applied with 20 selected healthy dogs, and the records were substantially homogeneous in the morphology of the registered waves, despite the wide variations in body conformations and sizes of the dogs. Some cases of heart diseases are presented, in which the diagnosis was only possible or complete by using the oblique lateri-lateral plane.

UNITERMS: Electrocardiography; Dogs

INTRODUCTION

Electrocardiography provides fundamental data to diagnose cardiac diseases in dogs and cats, mainly taking in account that only the specialized centers have other complementary methods, besides this one and the simple chest radiologic examination.

In 1949 LANNEK⁸ published a statistical study about the normal electrocardiogram in dogs, including precordial leads, and its parameters were adopted since then, with some changes³.

The chest leads which have been used since DETWEILLER & PATTERSON³ (1965) are: CV₅RL (fifth

intercostal space at the right edge of the sternum), CV₆LU (sixth intercostal space at the left costochondral junction), CV₆LL (sixth intercostal space at the left edge of the sternum), and V₁₀ (over the dorsal spine of the seventh thoracic vertebra, between the scapulas).

Although they are not recent, the unipolar precordial leads are not being universally used yet in canine electrocardiography⁴ and they are not well established, even though it is recognized that they are particularly useful to detect right or left ventricular enlargements, to diagnose myocardial infarction, bundle branch blocks, cardiac arrhythmias, and to confirm the data obtained from the six hexaxial leads¹¹.

The influence of the chest conformation^{5,2,1} and of the distance between the electrodes and the heart, the excessive skewness obtained by measuring the electric parameters and the frequent bimodal distribution of the parameters values where the skewness are minimum⁶ complicate the establishment of normal values in dog electrocardiogram. There are no adequate criteria yet to detect electrocardiographically left ventricular enlargement^{3,11}, tenuous right ventricular enlargements⁴, or to define accurately the extension of myocardial infarction or fibrotic areas on the ventricular wall in dogs.

The present work has the objective of standardizing a new precordial lead system, forming approximately a plane, which tends to be perpendicular to the heart apical basal axis (oblique lateri-lateral plane). This system permits the registration of the electrical potentials in the right ventricle (RV), interventricular septum and left ventricle (LV) consecutively, and when they are interpreted together with the leads of the frontal plane, they provide a global visualization of the electrical phenomena of heart activity.

A more complete record is obtained, from two planes (frontal and oblique lateri-lateral), which may help with the interpretation of the electrocardiographic record, not in the light of standards, which are difficult to establish and highly ambiguous, but as an harmonic and associated whole.

MATERIAL AND METHOD

Animals

GROUP 1: 20 clinically normal dogs were selected from the kennel of Faculdade de Medicina Veterinária e Zootecnia da Universidade de São Paulo, mongrels,

being 9 females and 11 males, adults and of diverse ages.

The evaluations to select dogs with perfect health state were

- a) routine physical examination, with special attention to the cardiac and respiratory systems;
- b) laboratory examination to detect microfilariae of *Dirofilaria immitis* in peripheral blood, by using the modified Knott technique, and direct drop of blood examination⁹;
- c) radiologic chest examination in two positions (left lateri-lateral and dorso-ventral);
- d) electrocardiographic examination (frontal plane and, in some dogs, the CV₆LU lead).

GROUP 2: Five cardiac dogs were selected among those assisted in the Central Ambulatory of Hospital Veterinário da Faculdade de Medicina Veterinária e Zootecnia da Universidade de São Paulo, and submitted to clinical examination, including the electrocardiographic records in the oblique lateri-lateral plane (OLLP). The animal n^o 1 was a german shepherd, female, 9 years old; n^o 2 a mongrel, large physical size, male, 10 years old; n^o 3 a mongrel, medium physical size, male, 7 years old; n^o 4 a poodle, male, 10 years old and n^o 5 a mongrel, medium physical size, female, 9 years old.

Equipments

An electrocardiograph model ECG-4* and a Formica table were used for positioning the animal. To make contact between the electrode and the skin, alligator clips and alcohol were used.

Precordial electrocardiographic examination

The electrocardiographic record was made without chemical restraint. With the animal in standing position on the examination table, the precordial exploratory electrode (V) was put at the third right intercostal space between the costochondral junction and the sternum (CV₂R lead). After this the dog was put in right lateral recumbency, with its head and neck on the table and its limbs stretched parallel between themselves at an angle of 90° with the body as in standing position. The limb electrodes were then put just over the olecranon on the caudal aspect of the appropriate foreleg, and over the patellar

ligament on the anterior aspect of the appropriate hindleg.

The record of the leads of the frontal plane (D₁, D₂, D₃, aVR, aVL, and aVF) and of CV₂R were made again. Then the precordial exploratory electrode was shifted to the standardized positions, forming 6 unipolar precordial leads. The alcohol left in the previous position was carefully dried before recording the following lead

Standardized precordial leads (Fig. 1): CV₂R, located at the 3rd right intercostal space, between the costochondral junction and the sternum; CV₁, located at the 2nd sternebra, on the median line; CV₂, located at the 3rd left intercostal space, between the costochondral junction and the sternum; CV₃, located at the 4th left intercostal space, next to the costochondral junction; CV₄, located at the 5th left intercostal space, from a middle distance between the costochondral junction and the imaginary line of the chest in its larger axis (between the dorsal line and the sternum); CV₅, located at the 6th left intercostal space in the imaginary median line between the dorsal line and the sternum.

The method of making vectorial loops from precordial leads plane obtained was adopted, aiming a better understanding of the electrical phenomenon³.

RESULTS

Group 1

The evaluation of the results was directed to the global electric distribution of the cardiac activation, without much care in measuring the amplitude or duration of the recorded waves.

The standardized precordial leads determined a plane, the oblique lateri-lateral plane (OLLP) (Fig. 2), almost intermediate between the frontal plane and the transverse plane (obtained with the D₁ and V₁₀ leads).

In the frontal plane SAP ranged from 30° to 90° (mean of 68,7 and standard deviation 15,3°). In the OLLP the axis turned from right to left, being slightly dorsal. P wave was isoelectric or slightly negative in CV₂R, and CV₁, isoelectric or slightly positive in CV₂, and positive in CV₃, CV₄ and CV₅.

The amplitude of P did not surpass 2,0mm in the precordial leads, and its duration did not exceed 0,04s, being generally longer and having smaller amplitude in CV₃. The Tab. 1 presents the situation of P in relation to the precordial leads, expressed in percentage. (e.g. CV₂ lead recorded P wave "minus-plus" in 40% of the dogs, and positive P wave in 60% of them).

* FUNBEC, with Regisgraf¹ register paper

In the frontal plane SAQRS ranged from 50° to 90° , (mean of $70,75^{\circ}$). In the OLLP the complex turned from right to left, ventrally and in counter-clockwise direction (Fig. 4). The morphologies of the QRS complex according to the leads were: CV₂R presented the "RS" pattern (mean amplitude of R=6,07mm and S=6,6mm). CV₁ presented the same morphology, but with smaller amplitude. In two cases (10%) the complex was isodiphasic in its second portion CV₂ presented the "RS" pattern in 50% of the cases and "R" in the remainder. CV₃ presented R wave in 90% of the dogs (18), being 7 of them (38,9%) with a little notch in the final portion of the complex; in 10% of the dogs "Rr" was noted. CV₄ presented "qR" morphology in 13 dogs (65%), being "q" sometimes very small, and "R" in 7 dogs (35%). In CV₅ "qR" was obtained in 90% (18 dogs) and "R" in 10% of the cases.

According to the most common morphology in each lead and to the averages of the obtained amplitudes, a standard sequence was determined (Fig. 3 and 4).

Table 2 expresses the morphology of T wave in the precordial leads in percentage (e.g. in CV₅, T wave was positive in 30% of the dogs, isoelectric in 25% and negative in 45%). Its presentation in the CLLP was cranio-ventral and slightly to left or to right. T wave was positive in all leads, except in CV₅, which can be positive, negative or "minus-plus".

Group 2

Animal n^o 1 - diagnosis: area of myocardium necrosis (Fig. 5). If the only recorded chest lead had been CV₆LU, the "S" wave bigger than 0,7mV could be suggestive of hypertrophy of the right ventricle⁷, though there was not any confirmation in the frontal plane. By examining the OLLP, the "S" wave is noted in CV₂, CV₃ and CV₄ and reduction of electric power in CV₅. There is no large "R" wave or increase in the R/S relation in CV₂R or deep "q" wave in CV₅ suggestive of right ventricular enlargement. It is an electrically inactive area in the region of the septum and free wall of left ventricle, which corresponded to an necrotized area as verified later with necropsy. The radiologic examination did not present any change in the cardiac silhouette.

Animal n^o 2 - diagnosis: Right ventricular enlargement. Fig. 6 shows in the frontal plane a "q" wave well marked in D₂, although it does not exceed the limit of 0,5mV, and in CV₆LU a "S" wave bigger than 0,7mV. The oblique lateri-lateral plane shows clearly the overload of the right ventricle through "QR" pattern in CV₄ and CV₅. The vectorial loop of QRS is in clockwise direction, and for this reason, there was no change in the R/S relation in CV₂R, and the

morphology of CV₃ is "rS". There is atrial fibrillation.

Animal n^o 3 - diagnosis: Left ventricular enlargement. Fig. 7 shows an "R" wave widened in D₂, D₃ and aVF and ST junction depression. In the OLLP is noted an large "S" wave in CV₂R and large "R" in CV₃, CV₄ and CV₅. Left ventricular enlargement was confirmed with the radiologic examination.

Animal n^o 4 - Diagnosis: Cardiac metastasis of bronchogenic carcinoma (Fig. 8). In the frontal plane there is "QS" in D₁ and aVL, without change in CV₆LU. By examining the OLLP we note an inactive area in the region of the septum and high lateral wall of left ventricle (CV₃, CV₄ and CV₅ leads). The radiologic examination revealed a great pulmonary involvement suggesting neoplastic formations. With the necropsy, it was verified neoplastic formations in the lungs and heart (septum, contiguous portion of RV and Wall of LV, towards the heart base) and mediastinal lymphonodes. In the histopathology was diagnosed bronchogenic carcinoma, with cardiac metastasis.

Animal n^o 5 - Diagnosis: Complete right bundle branch block (Fig. 9). In spite of being well detectable in the frontal plane, the record is more complete when the OLLP is included, allowing a better outline of the waves which represent the block.

DISCUSSION

The chest leads allow the determination of the heart dipole in a more accurate way than the other leads, however, due to the great proximity between the lead and the heart, animals with narrow thoraces will have larger deflections than those which have more rounded thoraces^{5,2}. The precordial leads recognized in veterinary medicine^{8,3} have been useful to confirm certain diagnosis, but because they do not keep any relationship between themselves, they are adopted only under the form of static standards obtained from averages. HAMLIN & SMITH⁵ (1960) mention that unless the records obtained from the chest leads of each body shape be meticulously characterized, the interpreter will not know if a particular record showing, for instance, a high positive deflection in the 5th left intercostal space is due to narrow chest, enlargement of left ventricle, or aberrant ventricular activation.

The establishment of normal values is difficult in the dog, where the chest conformations are very diverse. The studies of HILL⁶ (1968) on the dog ECG in 6 frontal plane leads plus the 4 chest leads in use

³ record the excessive deviation in the measuring of certain electrocardiographic parameters in normal dogs (e.g. R wave in D_2), and in the parameters whose deviations were minimum (e.g. R wave in aVF), the distribution is preferably bimodal. Besides this, the unipolar precordial leads are not well established in the dog as in the cat ¹¹, and they are not universally used, being V_{10} the most popular ⁴.

In human electrocardiography the chest conformation also influences the obtained record but, inspite of this, the morphologies of the QRS complex are more constant in the horizontal plane than in the frontal one, when one studies the normal heart ¹. This led us to research a chest lead system in the dog, arranged to form, as it is possible, a plane. When the properties of the dipole and of the electrocardiographic record apparatus are known, besides the heart position in the chest and the ventricular activation sequence, one can determine qualitatively with electrocardiographic configuration to expect from a given lead ⁵. The interventricular septum in the dog forms a plane deviated from the median sagittal plane by an angle of 45° , and inclined, with its dorsal border being cranial in relation to the ventral border, forming an angle of 45° with the ventral plane ⁵. From these informations, we tried to determine a lead system wich, by exploring the cardiac area, would keep its elements in the same imaginary plane, and with anatomical points of reference that allowed the application of the method in dogs with any chest conformation. The oblique lateri-lateral plane obtained is approximately perpendicular to the heart apical basal axis (Fig. 2), and in fact it is not constituted of only one plane, but we consider it so, from a practical point of view.

With the purpose of determining the correspondence between the explored points at the chest surface and the respective points of the heart, 40x15mm needles were introduced in two necropsied dogs, from the settling point of each lead towards the imaginary center of the heart, then some colouring was injected. The colored points corresponded to the following areas: Free wall of RV correlated to CV_2R ; paraseptal region of RV correlated to CV_1 and CV_2 , septal region correlated to CV_3 , paraseptal region of LV correlated to CV_4 and high lateral region of LV correlated to CV_5 . The determination thus established was coherent with the lead lines position.

P wave presented constant morphology in all dogs. The QRS complex also registered an homogeneous pattern, in spite of the variations of the body shape and size of the studied animals. The QRS vectorial loop was always put in counter-clockwise direction and its morphology was similar to that in the transverse plane ^{2,10} (formed from D_1 and V_{10}). Note that CV_5 has
Braz. J. vet. Res. anim. Sci., São Paulo, 27(2):233-246, 1990.

an anatomical proximity with the classical CV_6LU lead and its electrocardiographic record is similar in a normal dog, but it allows a better "visualization" of the right ventricular ("q" wave). The T wave in the dog is quite variable in the frontal plane, being more constant in the transverse plane, where it is ventrally directed and usually toward the right or slightly to the left, never being sufficiently led to the left to produce negative T wave in CV_5RL ³. HILL ⁶ (1968) obtained positive T wave in this lead in 98.5% of 70 dogs. In the oblique lateri-lateral plane (OLLP) the vectorial loop was similar to that of the transverse plane, being directed in the ventro-cranial direction, deviating slightly to the left or to the right, but being always positive in CV_2R , CV_1 , CV_2 and CV_3 .

APPLICATION OF THE METHOD

This lead system has been incorporated to the routine of our electrocardiographic service. Some difficulties were noted, as far as restless animals are concerned, for the time of manipulation is longer than that used to simply record the frontal plane. Obese animals or that with very small chest hamper the correct positioning of the chest electrode. The "r" and "s" waves from the CV_1 lead were smaller in relation to the rest of them, due to the protection of the global electrical phenomenon on it. This determines a break in the general harmony of the record, as the phenomenon from CV_2R successively to CV_5 is considered (Fig. 3 and 4).

The OLLP, associated to the frontal plane (and to the CV_6LU lead) has allowed a good understanding of the cardiac activation phenomena of the dog. As the CV_5 lead preferably records the action potentials of the high lateral region of left ventricle, next to the heart base, the CV_6LU lead has also been incorporated to the dog's routine electrocardiographic record, wich better visualizes the free wall of LV. For examining the apex, CV_6LL lead is recorded, as it is already established. With these procedures the record is quite complete, allowing a global focus on the electrical events on the heart cycle.

The right ventricular enlargement is not frequently detected by the canine electrocardiography, since the dominant ventricular chamber is the left one, besides being simultaneously activated with the right one. Therefore, for the recognition of RV anomalies it must be markedly compromised ⁴. It has been noted that in some dogs with RV enlargement radiographically diagnosed, and with normal ECG in the frontal plane and in CV_6LU , the study of OLLP showed R/S relation increased in CV_2R , and an increase of "q"

wave in CV₅ (and sometimes CV₄) proportionally to its "R". This leads to suppose that the inclusion of this plane to the routine electrocardiographic record will allow a more adequate analysis of volume increases that are not so evident. In some cases, with great increase of RV, there is an inversion of QRS vectorial loop direction, becoming clockwise (Fig. 6). These observation is in accordance with those obtained in the transverse plane².

In human medicine, where electrocardiographic examination is already well studied and standardized, it is difficult to establish the diagnosis of slight LV enlargement. Being the human heart average mass 270g, some authors demonstrate that there is no correlation between the heart mass and the QRS amplitude if the organ has less than 450g¹. In veterinary medicine, decisive criteria for LV enlargement diagnosis are still not well established. The vectorial loop and axis are not generally changed in form or settling direction as often occurs with RV enlargement². Due to the LVE electrocardiographic diagnosis be based mainly in the increase of the QRS voltages, it can be influenced by the fact that voltage of the limb leads, and especially the precordial ones, is influenced by the distance between the electrodes and the heart. In young dogs, emaciated dogs or in that with narrow chest, the criteria for increased voltage are not so valid. Conditions as thoracic or pericardial effusion, pneumothorax and obesity can reduce the amplitude of QRS deflections recorded in the body surface⁴. The OLLP analysis allows that the electrical potentials of RV and LV be related (as occurs in the human horizontal plane), supposing that any of the mentioned factors would change the record of both of them, keeping relatively unchanged their proportions. Thus we would not be limited only to the QRS complex millivoltage criterium considered normal in each lead (Fig. 7).

CONCLUSION

Despite of the small number of animals on the present work for considering the obtained results as definite standards of morphology, it allows that a homogeneous sequence of chest leads located in the oblique lateri-lateral plane be determined. The record can also be better explored to determine relations that allow a better comparison between the RV and LV from the same animal, so that one be not limited to set standards of normality in each lead, wich are subjected to several influences from extrinsic factors.

From our point of view, the precordial leads must not be used in the dogs only to confirm data obtained

in the other leads, or when some pathology is suspected, for some conditions will pass unnoticed, as demonstrated with dogs from the group 2. We understood that they should be incorporated to the electrocardiographic routine, to complement the frontal plane.

The precordial lead system standardized here (OLLP) is not so different from the one established by LANNEK⁸ (1949), however it allows an exploration of the cardiac activation in a more complete and homogeneous way, making possible a more accurate diagnosis of conduction disturbances, electrically inactive regions, and ventricular enlargements.

NUNES, A.A.; MOFFA, P.J.; IWASAKI, M. Padronização de um novo sistema de derivações precordiais no cão. *Braz. J. vet. Res. anim. Sci.*, São Paulo, 27(2):233-246, 1990.

RESUMO: Este estudo propõe um novo sistema de derivações precordiais no qual o eletrodo explorador (V) forma, aproximadamente, um plano perpendicular ao eixo ápico-basal cardíaco (plano látero-lateral oblíquo). As posições estabelecidas são estreitamente relacionadas, registrando sucessivamente o ventrículo direito, septo interventricular e ventrículo esquerdo. O método foi aplicado em 20 cães sadios selecionados, e os registros foram substancialmente homogêneos na morfologia das ondas, a despeito das grandes variações no tamanho e formato do tórax dos cães. Alguns casos de patologias cardíacas são apresentados, nos quais o diagnóstico só foi possível ou completo usando-se o plano látero-lateral oblíquo.

UNTERMOS: Eletrocardiografia; Cães

REFERENCES

- 01-CARNEIRO, E.F. *O eletrocardiograma*. 3.ed. Rio de Janeiro, Atheneu, 1983. p.123-124.
 - 02-DETWELER, D.K. Cardiovascular disease in animals: clinical considerations. In: LUISADA, A.A., ed. *Cardiology*. New York, Mc Graw-Hill, 1961. v.5, Section 27, p.10-42.
 - 03-DETWELER, D.K. & PATTERSON, D.F. The prevalence and types of cardiovascular disease in dogs. *Ann. N. Y. Acad. Sci.*, 127:450, 481-516, 1965.
- Braz. J. vet. Res. anim. Sci.*, São Paulo, 27(2):233-246, 1990.

238 NUNES, A.A.; MOFFA, P.J.; IWASAKI, M.
Standardization of a new precordial chest leads system in the dog.

- 04-ETTINGER, S.J. & SUTER, P.F. *Canine cardiology*. Philadelphia, W.B. Saunders. 1970. p.118-145.
- 05-HAMLIN, R.L. & SMITH, C.R. Anatomical and physiologic basis for interpretation of electrocardiogram. *Amer. J. vet. Res.*, 21:701-708, 1960.
- 06-HILL, J.D. The electrocardiogram in dogs with standardized body and limb positions. *J. Electrocardiology*, 1:175-182, 1968.
- 07-HILL, J.D. Electrocardiographic diagnosis of right ventricular enlargements in dogs. *J. Electrocardiology*, 4:347-357, 1971.
- 08-LANNEK, N. *A clinical and experimental study on the ECG in dogs*. Stockholm, Royal Veterinary Collegy, 1949.
- 09-NEWTON & WRIGHT, 1956 apud ETTINGER, S.J. *Textbook of veterinary internal medicine: diseases of the dog and cat*. 2.ed. Philadelphia, W.B. Saunders, 1983. p.1104.
- 10-PASTORE, C.A.; TOBIAS, N.M.O.; MOFFA, P.J.; MORAES, A.P.; BRUM, J.M.G.; RIBEIRO, M.B.; DEL NERO JUNIOR, E.; VERGINELLI, G.; PILLEGI, S.; ZERBINI, E.J.; DECOURT, L.V.; ARMELIN, E. Aspectos vetocardiográficos do infarto do ventrículo direito. Estudo experimental em cão. In: CONGRESSO BRASILEIRO DE CARDIOLOGIA, 37., *Resumos. Arq. bras. Cardiol.*, 37:156, 1981.
- 11-TILLEY, L.P. *Essentials of canine and feline electrocardiography*. St. Louis, C.V. Mosby, 1979. p.16,64.

Recebido para publicação em 12/09/89

Aprovado para publicação em 15/05/90

TABLE 1 - Morphology of P wave according to the frequency (in percentage recorded in precordial leads (OLLP))

P	+	-/+	-
CV _{2R}	--	40	60
CV ₁	--	70	30
CV ₂	20	80	--
CV ₃	100	--	--
CV ₄	100	--	--
CV ₅	100	--	--

TABLE 2 - Morphology of T wave according to the frequency (in percentage) recorded in precordial leads (OLLP).

T	+	-/+	-
CV _{2R}	90	10	--
CV ₁	80	20	--
CV ₂	85	15	--
CV ₃	95	--	5
CV ₄	85	10	5
CV ₅	30	25	45

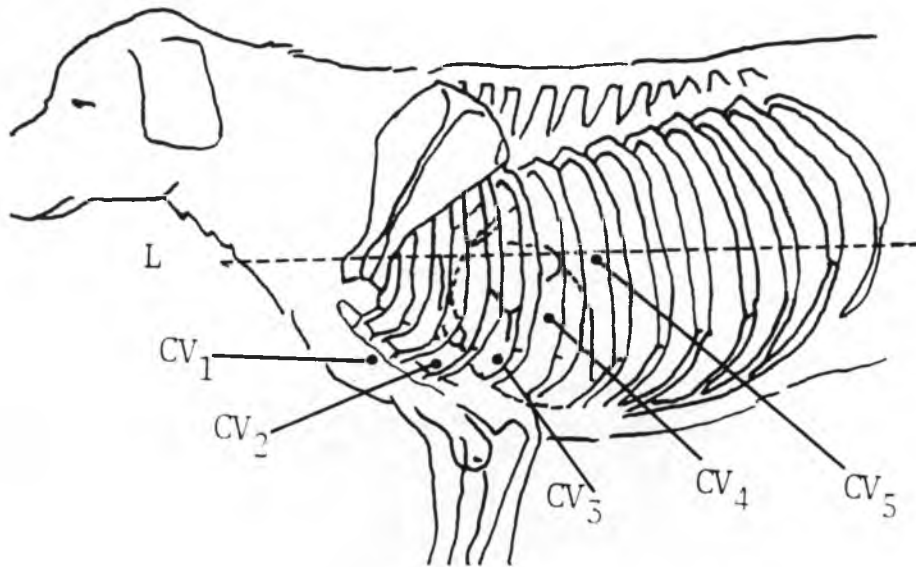


FIGURE 1 — Oblique lateri-lateral plane (OLLP): dog in right lateral recumbency. CV_{2R} — corresponds to CV₂, on the right side. CV₁ — at 2nd sternbra, on the median line. CV₂ — at 3rd left intercostal space, between the costochondral junction and the sternum. CV₃ — at 4th left intercostal space, next to the costochondral junction. CV₄ — at 5th left intercostal space, from a middle distance between the costochondral junction and the imaginary median line of the chest in its larger axis (L). CV₅ — at the 6th left intercostal space in the imaginary median line between the dorsal line and the sternum.

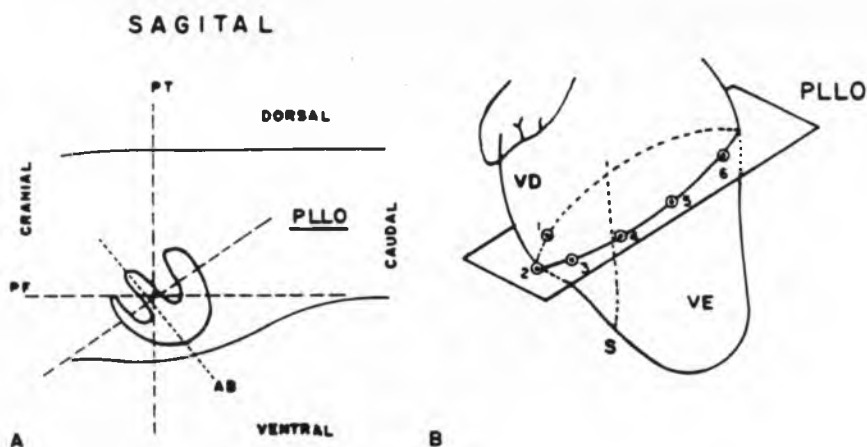


FIGURE 2 — Oblique lateri-lateral plane (PLLO), saw through sagittal plane. Notice the intermediate position between the transverse (PT) and frontal (PF) planes, located nearly perpendicular to the apical-basal cardiac axis (AB). VE — left ventricle; VD — right ventricle; S — interventricular septum; numbers from 1 to 6 correspond to electrodes from CV_{2R} to CV₅.

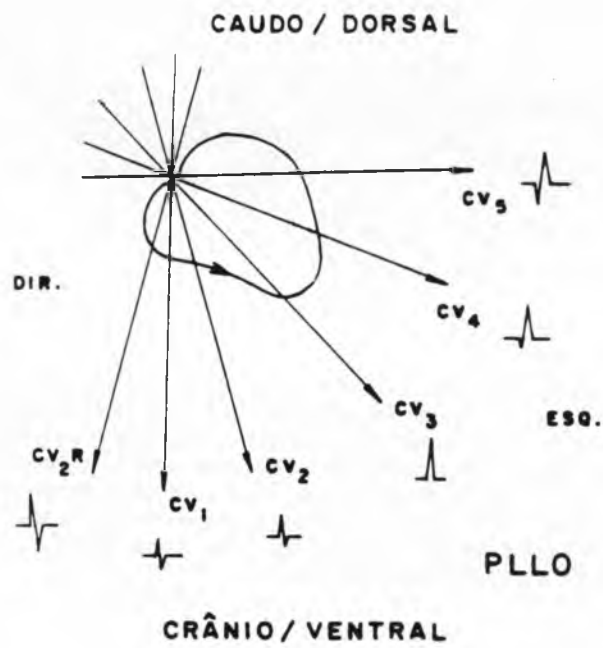


FIGURE 3 – Vectorial loop of QRS complex traced from OLLP. QRS morphologies more frequent in each lead. DIR – right. ESQ – left.

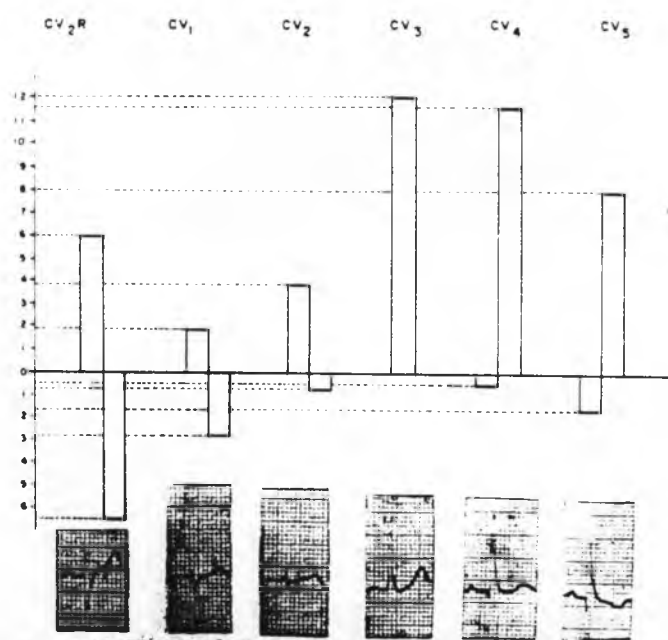


FIGURE 4 — Schedule representative of median amplitude, in millimeters, of "R" waves and negative waves, on oblique lateri-lateral plane leads; electrocardiographic record that assimilates these pattern (10 mm = 1mV).

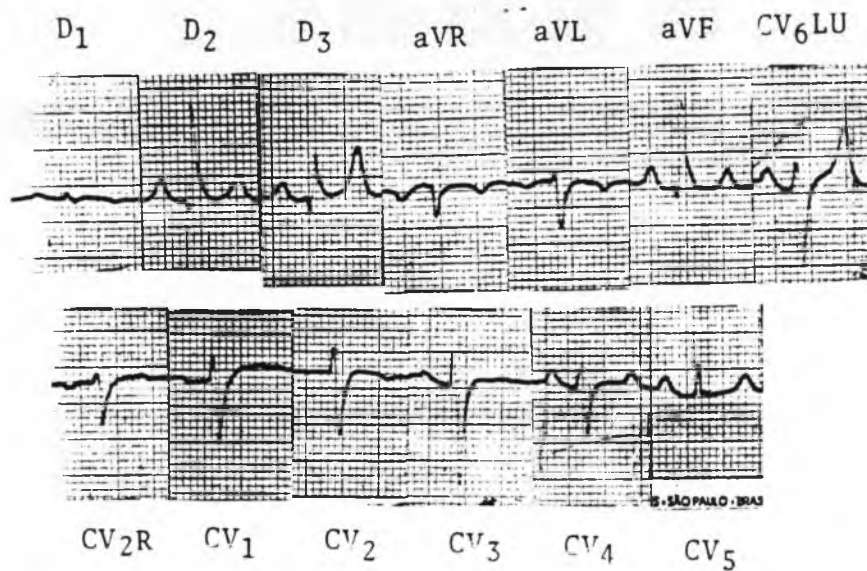
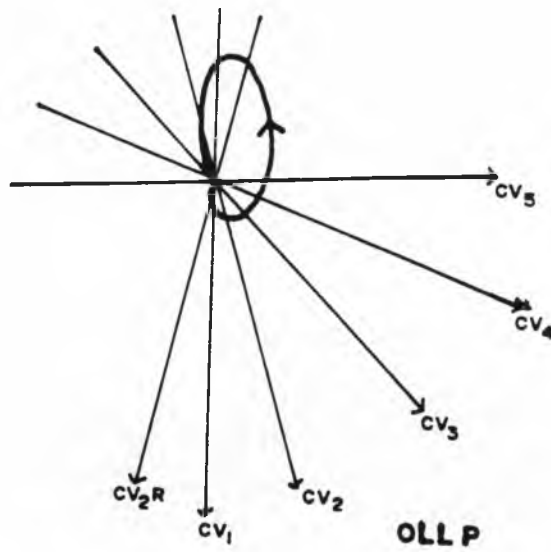


FIGURE 5 - Electrically inactive area in septum and left ventricle free wall. There is deep "S" wave in CV₆LU, "rS" pattern in CV₂, CV₃, CV₄, and decrease of electric power in CV₅. Vectorial loop representative of the electric activation process.

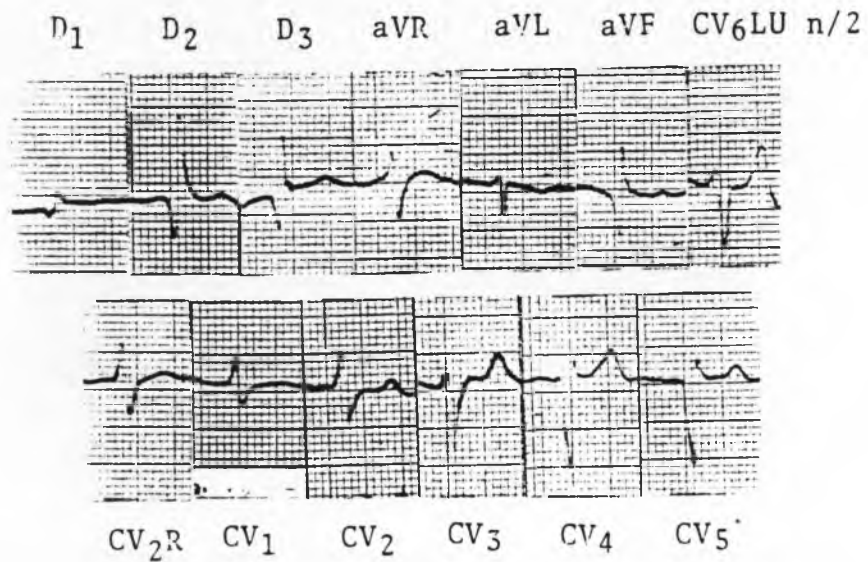
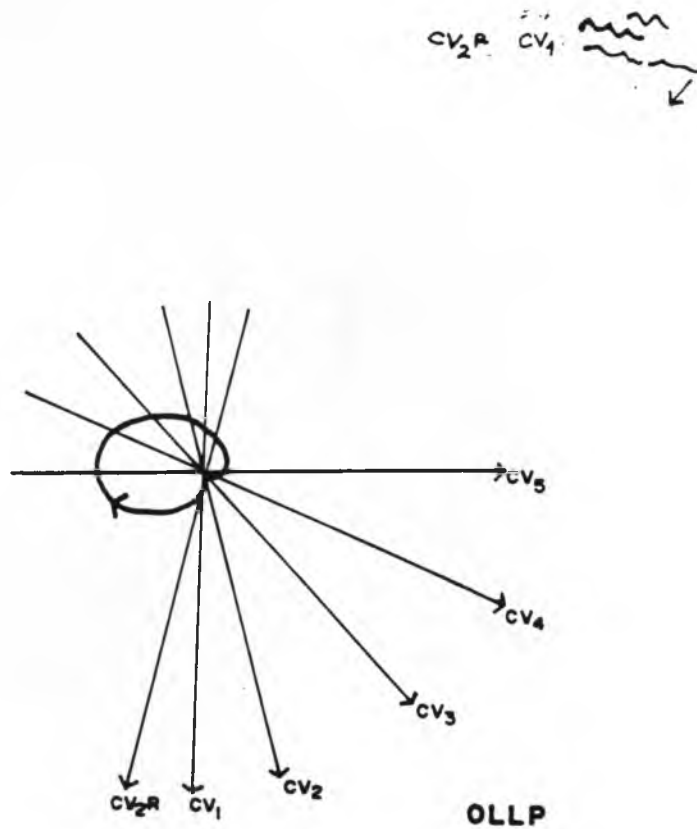


FIGURE 6 – Right ventricle enlargement. There are marked "q" waves in D₂, D₃ and aVF, and S wave larger than 0,7mV in CV₆LU. In OLLP there is rS pattern in CV₃, Qr in CV₄ and CV₅. The QRS vectorial loop is in clockwise direction, and there is atrial fibrillation.

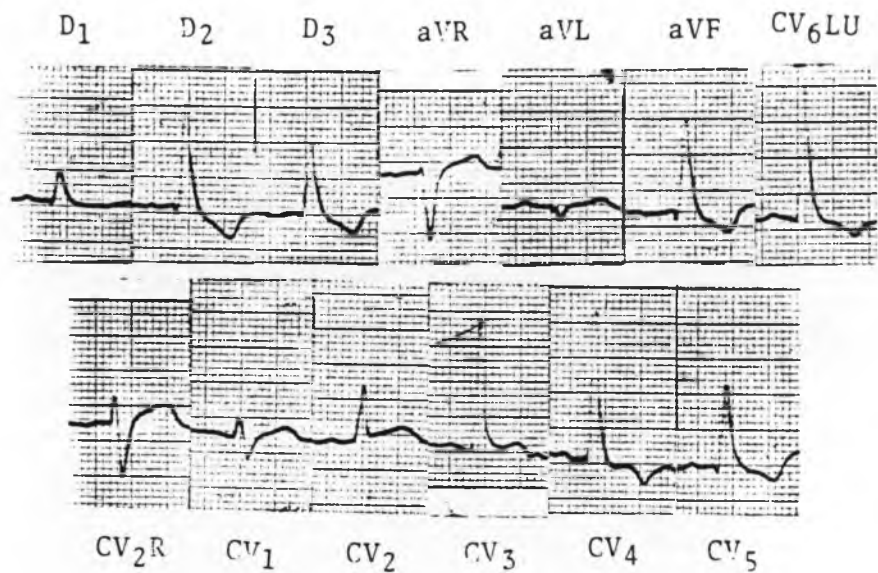
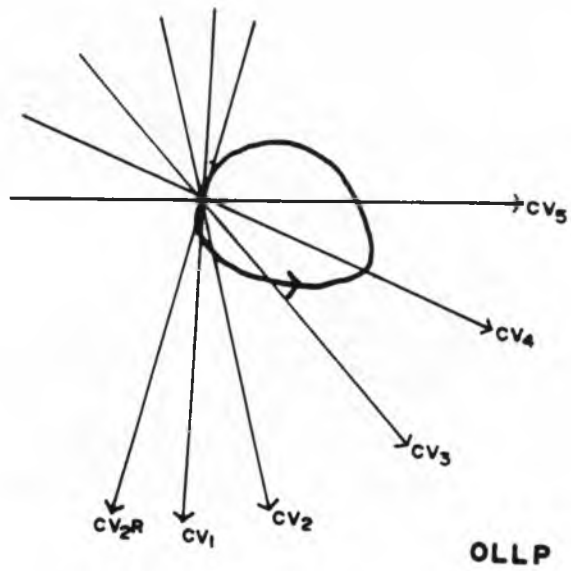


FIGURE 7 – Left ventricular enlargement. There is wide and large R in D₂, D₃ and aVF, and CV₆LU (0,07s). In OLLP there is large and deep S in CV₂R, and large R in CV₃, CV₄ and CV₅. The right ventricle is almost no manifested in CV₅ (q wave).

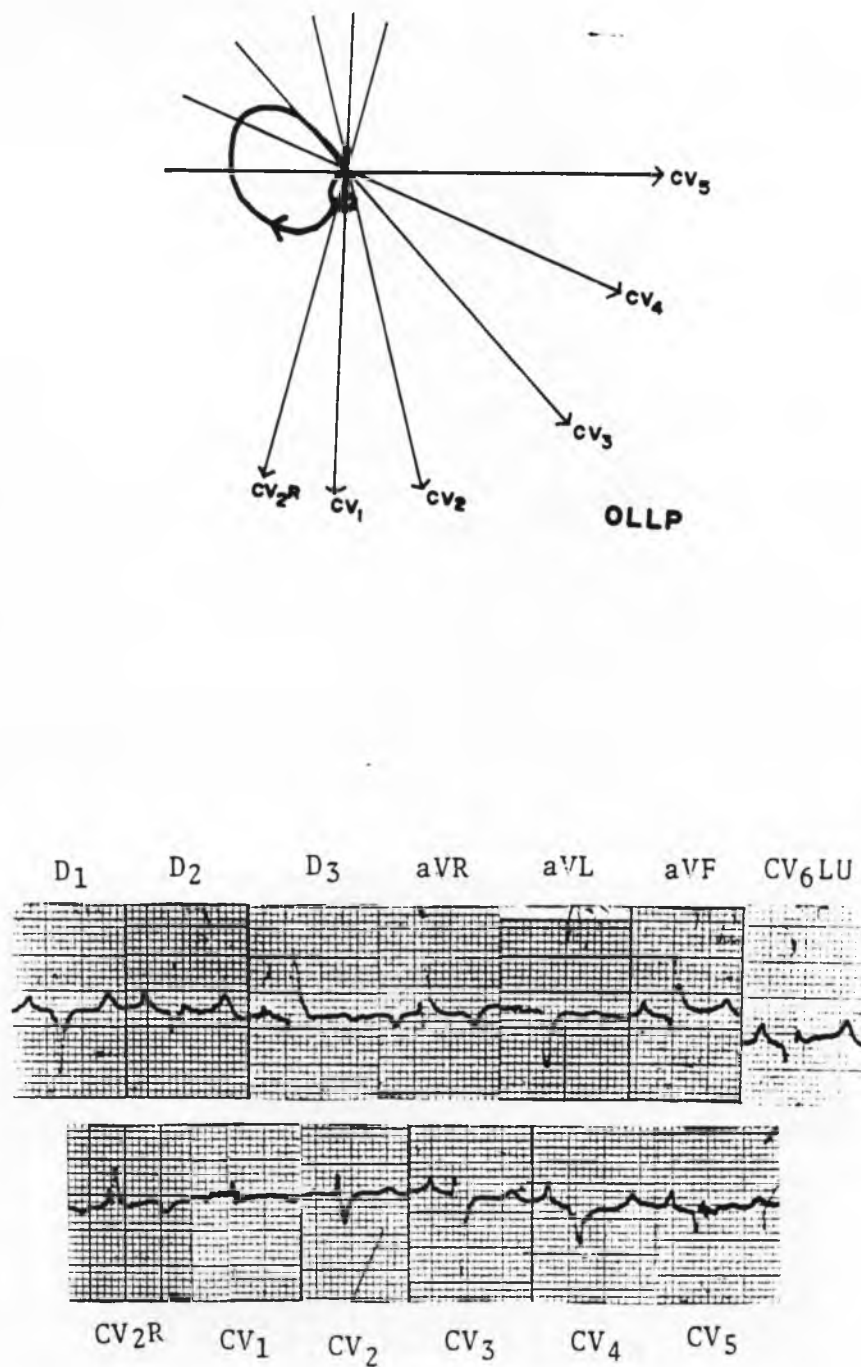


FIGURE 8 – Electrically inactive area in septum and left ventricle near to basis, with corresponded to cardiac metastasis of bronchogenic carcinoma. There is QS pattern in D₁ and aVL, and electrical axis +130°. In OLLP there is rR pattern in CV_{2R}, rS in CV₃, and QS in CV₄ and CV₅.

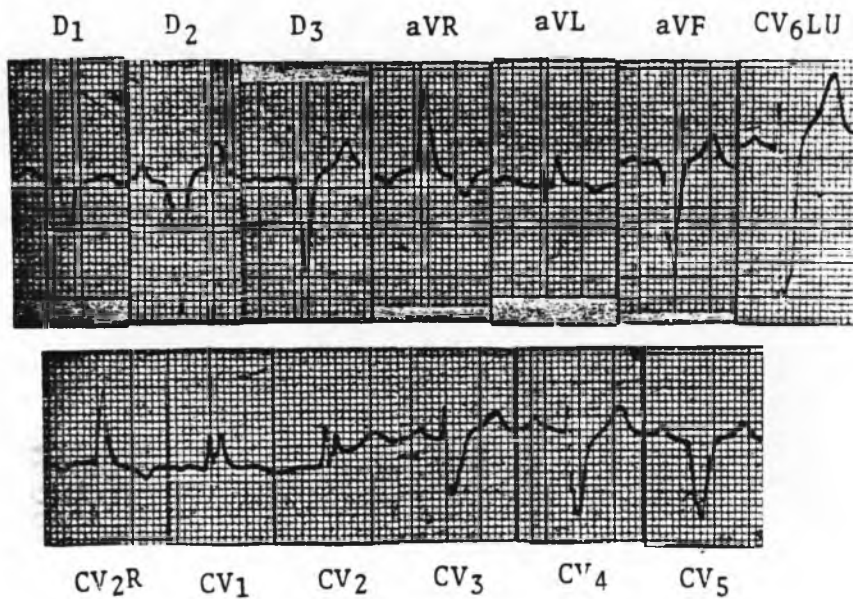
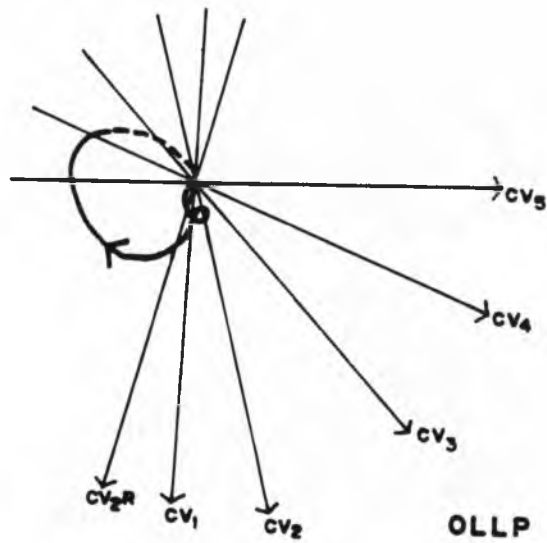


FIGURE 9 – Right bundle branch block. The QRS duration is 0,08s there is large wide S in D₁, D₂, D₃, aVF and CV₆LU. In OLLP there is rR pattern in CV₂R, RR' in CV₁ and CV₂ and rS in CV₃, CV₄ and CV₅.