

Glial fibrillary acidic protein (GFAP) immunoreactive astrocytes in the CNS of normal and rabies-infected adult cattle. I. Hippocampus and dentate gyrus

Astrócitos imunorreativos à proteína glial fibrilar ácida (GFAP) em SNC de bovinos normais e de bovinos com raiva. I. Hipocampo e giro dentato

Gisele Fabrino MACHADO¹; Antonio Carlos ALESSI²

CORRESPONDENCE TO:
Antonio Carlos Alessi
Departamento de Patologia
Veterinária. Faculdade de
Ciências Agrárias e Veterinárias
da UNESP
Rodovia Carlos Tonanni, Km 5,
14870-000 - Jaboticabal - SP -
Brasil
e-mail: alessi@fcav.unesp.br

1 - Departamento de Medicina
Veterinária Preventiva
Faculdade de Ciências Agrárias
e Veterinárias da UNESP -
Jaboticabal - SP
2 - Departamento de Patologia
Veterinária.
Faculdade de Ciências Agrárias
e Veterinárias da UNESP -
Jaboticabal - SP

SUMMARY

Glial fibrillary acidic protein (GFAP) belongs to the group of intermediate filaments of the cell cytoskeleton. It is present in astrocytes and in some ependymal cells. Detection of GFAP is useful for the identification of astrocytes in a highly specific manner. In the present study, peroxidase antiperoxidase (PAP) immunohistochemical staining, with a specific antibody against GFAP was employed to determine the distribution and morphology of astrocytes in the hippocampus and dentate gyrus of normal cattle and cattle naturally infected with rabies. Paraffin sections of buffered formalin-fixed tissue were used. Positively brown coloured astrocytes in each region were classified into four levels of intensity. The number of astrocytes per mm² was determined using a straight scale ocular micrometer. Nuclear area, larger and smaller diameter of astrocytes were also determined with an image analyser system. It was observed that the morphology of astrocytes varied in the different microregions of hippocampus and dentate gyrus. Cattle with rabies showed astrogliosis represented by strong immunoreaction, enlargement of cell body, cytoplasm and processes. The nuclei were also enlarged and light in colour. Astrocytosis was also present. Neurons showed no alterations. These results represent a contribution to the knowledge of the normal distribution and morphology of astrocytes which permits a better understanding of pathological conditions.

UNITERMS: Astrocytes; Bovine; Rabies.

INTRODUCTION

Astrocytes are important cells of the central nervous system (CNS) that provide nutritional and structural support for neurons, formation of the blood brain barrier² and other functions, as reviewed by Montgomery¹² (1994). Parpura *et al.*¹⁴ (1994) suggested that astrocytes affect the functional properties of neurons.

Astrocytes respond to a wide variety of stimuli, and the cellular changes which subsequently develop are reliable indicators of underlying brain pathology^{8,10}. Reactive astrocytosis is generally demonstrated by the immunohistochemical detection of glial fibrillary acidic protein (GFAP), an intermediate filament component of the cytoskeleton. GFAP expression is an aspect of astrocytosis that must be considered in different situations⁴. On the other hand, the function of GFAP in astrocytes is not clear. Mice lacking GFAP on astrocytes develop and reproduce normally¹⁵.

Distribution of GFAP in the normal rat brain was studied by Kálmán; Hajós⁷ (1989) and Hajós; Kálmán⁵ (1989). Similar studies were undertaken in marmosets¹¹, sheep⁶ and Japanese quail³. Other studies conducted on normal or pathologic CNS of mice¹ and pigs⁹ showed morphological aspects of GFAP immunoreactive astrocytes and GFAP expression in normal and pathological conditions. On the other hand, veterinary literature is very limited in information about the participation of astrocytes in the pathogenesis of natural

diseases affecting different animal species¹².

The objective of the present study was to investigate the distribution and the morphology of GFAP immunoreactive astrocytes in the hippocampus and dentate gyrus of normal cattle and of cattle naturally infected with rabies virus.

MATERIAL AND METHOD

The encephalons of 16 normal adult cattle, i.e., cattle apparently not bearing encephalopathies, were obtained at slaughterhouses in the region of Jaboticabal - SP. The encephalons of 8 adult cattle with rabies transmitted by bats were obtained from the necropsy service of the Department of Veterinary Pathology, FCAV, Unesp. Rabies was diagnosed at Instituto Pasteur, São Paulo, using direct immunofluorescence with antibodies against rabies virus and a biological test in suckling mice.

The whole encephalons were fixed in 10% phosphate buffered formalin, pH 7.2, for 8 days and sections of the hippocampal formation were obtained. The slices were embedded in paraffin, sectioned and stained with hematoxylin-eosin or processed for immunohistochemistry, utilising the peroxidase antiperoxidase (PAP) method. To avoid detachment of the sections, slides were pre-coated with a smear of Poly-L-lisine (SIGMA) diluted 0.01% in distilled water.

For immunohistochemistry, tissue sections were

deparaffinized, rehydrated and incubated with 50% methanol plus 3% hydrogen peroxide for inhibition of endogenous peroxidase. In sequence, slides were rinsed in phosphate buffered saline (PBS) and incubated with 0.1% trypsin (DIFCO) diluted in PBS, for 25 minutes at 37°C. The slides were then rinsed in PBS and incubated overnight at 4°C with polyclonal anti GFAP antibody (DAKO) diluted 1:300. Normal rabbit serum (SIGMA), instead of the primary antibody, was used as the negative control. Sections were then rinsed in PBS, incubated with linking antibody (sheep anti rabbit IgG - SIGMA) diluted 1:25 for 30 minutes, rinsed again and incubated with PAP complex (SIGMA) 1:200 for 30 minutes. In the next step, sections were rinsed in PBS and incubated with diaminobenzidine (SIGMA) 0.03% plus 0.03% hydrogen peroxide for a period of 5 to 8 minutes, under light microscopy control of the chromogen reaction. The sections were then washed in running tap water, counterstained with hematoxylin, dehydrated and mounted with coverslips.

The slides were examined under the light microscope by two observers. Positively brown coloured cytoplasm and processes of astrocytes were classified as weak (+), moderate (++), strong (+++) and very strong (++++). The number of astrocytes per mm² in each analysed region was determined using a 100-square integrating graticule mounted in an eyepiece of magnification 6,3x (REICHERT) and a 40x objective. For this parameter the number of nuclei in astrocytes with brown coloured cytoplasm and processes was considered. Data are presented as an average of three fields per layer per animal for each group. Nuclear area, larger and smaller diameter were determined in 20 astrocytes per animal with an image analyser system (Video Plan - ZEISS). The Student "t" test was employed to compare groups.

RESULTS

The GFAP immunoreactive cytoplasm of astrocytes was clearly identified by the brown colour of the cytoplasm and typical morphology (Figs. 1 and 2). Negative controls, i.e., sections where the primary antibody was replaced with normal rabbit serum, showed no positive reaction.

The distribution of positive immunoreactivity and the density of astrocytes are shown in Tab. 1. Normal cattle showed astrocytes

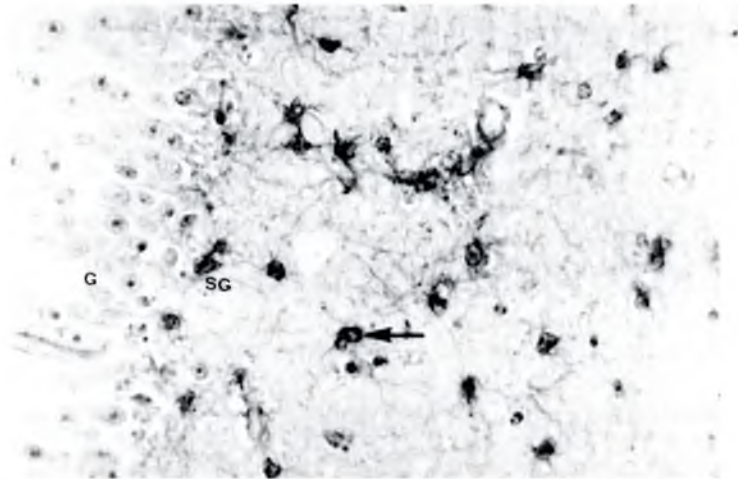


Figura 1

Microscopic appearance of the dentate gyrus of a normal cow. Astrocytes (arrow) in the subgranular zone (SG) of the dentate gyrus show thin processes. G - granular cells. PAP anti GFAP, 400x.

of uniform morphology and constant pattern of distribution in different layers of the hippocampus. In this group of animals, few astrocytes with long processes were observed between cells of the pyramidal molecular layer of the hippocampus gyrus.

The lacunar molecular layer was the most positively brown coloured structure. Astrocytes in this region showed thin, medium length, sinuous and branched processes varying in number from cell to cell (Fig. 1).

The pyramidal molecular layer of the dentate gyrus showed more immunoreactive cells than the stratum radiatum and stratum oriens. In the latter two structures, astrocytes showed a star shape, thin, medium length processes and round or elongated nuclei. Most of the astrocytes showed a single process.

The number of astrocytes/mm² in normal animals was similar in the different layers. The highest density was observed in the hilus of the dentate gyrus (Tab. 1).

In the granular layer of the dentate gyrus immunoreactivity was confined to some processes arising from astrocytes located in the subgranular layer. These astrocytes were numerous and their

Table 1

GFAP immunoreactivity and astrocyte density in the hippocampus and dentate gyrus of normal (N) and rabid (R) cattle. (Jaboticabal, São Paulo, 1994).

	GROUP N (n=16)		GROUP R (n=8)	
	REACTIVITY	ASTROCYTES/mm ² ± SD	REACTIVITY	ASTROCYTES/mm ² ± SD
Lacunar molecular layer	++++	56.8 ±14.8	++	96.3* ±45.0
Subgranular zone	++++	45.1 ±21.0	++++	85.2* ±24.0
Pyramidal molecular layer	+++	43.8 ±21.0	+++	63.6 * ±19.1
Hilus of dentate gyrus	+++	61.1 ±28.9	+++	131.5* ±53.0
Stratum radiatum	++	44.4 ±14.1	+++	104.9* ±64.2
Stratum oriens	++	40.1 ±20.9	+++	64.2* ±16.6
Pyramidal cell layer	+	47.5 ±14.1	++	98.8* ±44.4

+ = weak; ++ = moderate; +++ = strong; ++++ = very strong

* = p < 0.05

Table 2

Mean nuclear area, and widest and shortest diameters of GFAP-immunoreactive astrocytes in the hippocampus and dentate gyrus of normal and rabid cattle. (Jaboticabal, São Paulo, 1994).

GROUP	AREA (μ^2) \pm SD		WIDEST DIAMETER (μ) \pm SD		SHORTEST DIAMETER (μ) \pm SD	
Normal (n=16)	55.9	\pm 17.5	10.9	\pm 1.8	7.1	\pm 1.1
Rabid (n=8)	151.3*	\pm 37.7	18.1*	\pm 2.6	11.6*	\pm 1.8

* = $p < 0.01$

cell bodies were deeply stained and showed thin, branched processes. Astrocytes of this type were also present in the hilus of the dentate gyrus, but in smaller numbers.

Histologic sections of hippocampus and dentate gyrus from rabid animals showed GFAP immunoreactive cells differing in morphology from those observed in the normal group of animals. Cattle with rabies showed evident astrogliosis in most of the layers. The number of astrocytes/mm² was also greater (astrocytosis) in all layers ($p < 0.05$). Reduced immunoreactivity was only observed in the lacunar molecular layer (Tab. 1).

The nuclear area, and the widest and shortest diameters of the nucleus were larger in the astrocytes from rabid cattle (Tab. 2).

Astrocytes between neuronal cell bodies in the pyramidal cell layer of the hippocampus showed evident clear and enlarged nuclei.

In the stratum oriens, stratum radiatum and pyramidal molecular layer, astrocytes showed hypertrophic cell bodies with strong and clearly demarcated processes. The nuclei were enlarged, well demarcated, lighter in colour and the chromatin was condensed at the periphery. Nucleoli were also evident in the center of the nuclei (Fig. 2). Astrocytes located in the hilus of the dentate gyrus and subgranular zone were also hypertrophic and numerous (Fig. 2). Astrocytes with these characteristics were also present in the granular layer of the dentate gyrus. In the stratum radiatum the number of astrocytes/mm² was strongly increased (Tab. 1).



Figura 2

Microscopic appearance of the dentate gyrus of a cow with rabies. There are enlarged astrocytes (arrow) with enlarged nuclei and strong processes in the subgranular zone (SG). G - granular cells. PAP anti GFAP, 400x.

DISCUSSION AND CONCLUSIONS

During the last decade many studies contributed to the understanding of the functions of astrocytes and their participation in diseases of the CNS^{2,4,8}. Most of the studies were undertaken experimentally *in vitro* or *in vivo* using mice or rats. As stated by Montgomery¹² (1994), few articles in the veterinary literature have dealt with astrocytes and their reactions or contribution to disease. The conclusion is that, despite the large number of diseases affecting the CNS of many species of mammals and birds, research in this field is not extensive.

In the present study, we investigated the normal distribution, density and morphology of GFAP immunoreactive astrocytes in the hippocampus and dentate gyrus of normal cattle. The results obtained mainly concerned the second aspect analysed, i.e., the distribution, density and morphology of GFAP immunoreactive astrocytes in rabies-infected cattle.

Astrocyte distribution and morphology in normal cattle have some particularities when compared to other species. They are similar to those reported by Jeffrey *et al.*⁶ (1990) in sheep. The pattern of the astrocytes permitted to classify them as fibrous¹². The cellular density of astrocytes observed in the regions under study was apparently lower than that observed in rats and mice by Kálmán; Hajós⁷ (1989) and Alessi *et al.*¹ (1992), respectively. These authors reported a high density of astrocytes in the hippocampus and dentate gyrus.

The lacunar molecular layer and subgranular zone showed the strongest immunoreactivity, comparable to the results obtained in mice by Kálmán; Hajós⁷ (1989). Using the same immunohistochemical method employed here these authors conducted a detailed study in which they described the distribution of astrocytes in the forebrain. In a similar study with Japanese quail³, the authors also found a number of GFAP immunoreactive cells smaller than that found by Kálmán; Hajós⁷ (1989).

The rabies-infected cattle studied here presented a different distribution of immunoreactivity (Tab. 1). The lacunar molecular layer showed less immunoreactive astrocytes than did normal animals, while other zones showed equal or higher scores. This diminished immunoreactivity means a smaller number of prolongations or loss of glial filaments, because the number of nuclei was higher (Tab. 1). On the other hand, more immunoreactive astrocytes in other zones indicate functionally reactive astrocytes. Their morphological aspects were those of reactive astrocytes, i.e., large processes and large cell bodies strongly immunostained, prominently enlarged and light nuclei with the presence of nucleoli (Fig. 2). The determination of nuclear area and diameter provided objective data about the enlargement. No alterations were detected in the neuronal cell bodies of the hippocampus or dentate gyrus.

Although the rabies-infected cattle studied here died naturally, or were sacrificed with terminal clinical symptoms of the disease, the histopathological changes observed were discrete, consisting of the presence of neuronal inclusion bodies and small perivascular cuffs in other regions of the CNS, but not in the hippocampus or dentate gyrus. In fact, it is admitted that morphologic alterations in rabies encephalitis are not as drastic as are the clinical symptoms and dysfunctions¹³ especially in cattle. Therefore, the astrocyte alterations recorded here may indicate a more important participation of these cells in the pathogenesis of rabies than it was suspected. The immunostaining technique improved the identification of astrocytes and permitted an evaluation of the extent of alterations. Astrocytes are very important for providing nutritional and structural support for neurons; in addition,

it was recently proposed that astrocytes affect the functional properties of neurons¹⁴.

In conclusion, GFAP immunoreactive astrocytes in hippocampus and dentate gyrus of normal, adult cattle are present in all the layers at a density ranging from 40.1 to 61.1 cells/mm². In rabies-infected adult cattle, these regions show prominent astrogliosis and astrocytosis, in spite of the absence of neuronal alterations. The influence of these reactive astrocytes on the pathogenesis of rabies is still under investigation.

Acknowledgements

We wish to thank F.A. Ardisson, M.I.Y. Campos, N. Tel, and E. Homem for technical assistance. We are indebted to Fapesp and CNPq for financial support.

RESUMO

A proteína glial fibrilar ácida (GFAP) pertence ao grupo dos filamentos intermediários do citoesqueleto celular. Está presente nos astrócitos e em algumas células do epêndima. A identificação da GFAP é empregada para identificar astrócitos com excelente especificidade. Neste trabalho, o método imunohistoquímico da peroxidase-antiperoxidase (PAP), utilizando anticorpo primário anti-GFAP, foi empregado para estudar a distribuição e a morfologia de astrócitos no hipocampo e giro dentado de bovinos normais e também de bovinos com raiva, naturalmente adquirida. Foram utilizados cortes em parafina de material fixado em formalina tamponada. Astrócitos corados positivamente em marrom foram classificados em quatro níveis de intensidade. O número de astrócitos por mm² foi determinado com uso de ocular integradora. Área, maior e menor diâmetro do núcleo dos astrócitos foram determinados com sistema analisador de imagens. Observou-se que bovinos com raiva mostraram astrogliose, apresentando forte imunorreatividade, aumento de tamanho do corpo celular e dos processos citoplasmáticos. Mostraram também astrocitose, sendo que, em todas as camadas do hipocampo e do giro dentado, o número de astrócitos foi maior que nos animais normais. O núcleo também se apresentava aumentado e pouco corado. Células nervosas da região estudada não apresentavam alterações importantes. Os resultados colaboram para o conhecimento da distribuição e da morfologia de astrócitos imunorreativos à GFAP, em bovinos normais e em bovinos com raiva.

UNITERMOS: Astrócitos; Bovinos; Raiva.

REFERENCES

- 1 - ALESSI, A.C.; BLAKEMORE, W.F.; TANKS, P.; NASH, A.A. Reação astrocítica em camundongos infectados com o vírus da encefalomielite murina de Theiler. In: REUNIÃO ANUAL DA FEDERAÇÃO DE SOCIEDADES DE BIOLOGIA EXPERIMENTAL, 7, Caxambu, 1992. **Anais**, n. 1, 131, p. 35.
- 2 - BIGNAMI, A. **Discussions in neuroscience**. Amsterdam, Elsevier Science, 1991. vol. VIII, p. 1-45.
- 3 - CAMERON-CURRY, P.; ASTE, N.; VIGLIETTI-PANZICA, C.; PANZICA, G.C. Immunocytochemical distribution of glial fibrillary acidic protein in the central nervous system of the Japanese quail (*Coturnix coturnix japonica*). **Anatomy and Embryology**, v.184, n. 6, p.571-81, 1991.
- 4 - ENG, L.; GHIRNIKAR, R.S. GFAP and astrogliosis. **Brain Pathology**, v.4, n. 3, p.229-37, 1994.
- 5 - HAJÓS, F.; KÁLMÁN, M. Distribution of glial fibrillary acidic protein (GFAP)-immunoreactive astrocytes in the rat brain. II. Mesencephalon, rhombencephalon and spinal cord. **Experimental Brain Research**, v.78, n. 1, p.164-73, 1989.
- 6 - JEFFREY, M.; WELLS, G.A.H.; BRIDGES, A.W. An immunohistochemical study of the topography and cellular localisation of three neural proteins in the sheep nervous system. **Journal of Comparative Pathology**, v.103, n.1, p.23-35, 1990.
- 7 - KÁLMÁN, M.; HAJÓS, F. Distribution of glial fibrillary acidic protein (GFAP)-immunoreactive astrocytes in the rat brain. I. Forebrain. **Experimental Brain Research**, v.78, n. 1, p.147-63, 1989.
- 8 - LANTOS, P.L. Cytology of the normal central nervous system. In: WELLER, R.O. **Nervous system, muscles and eyes**. Systemic pathology. Edinburgh, Churchill Livingstone, 1990. p.3-35.
- 9 - MACHADO, G.F.; LEMOS, K.R.; ALESSI, A.C. Aspectos sobre a distribuição de astrócitos e reação astrocítica em algumas afecções neurológicas dos animais. In: ENCONTRO NACIONAL DE PATOLOGIA VETERINÁRIA, 6, Santa Maria, 1993. **Anais**, p.8.
- 10 - MALHOTRA, S.K.; SHNITKA, T.K.; ELBRINK, J. Reactive astrocytes - a review. **Cytobios**, v.61, n. 246/247, p.133-60, 1990.
- 11 - MCDERMOTT, K.W.G.; LANTOS, P.L. The distribution of glial fibrillary acidic protein and vimentin in postnatal marmoset (*Callithrix jacchus*) brain. **Developmental Brain Research**, v.45, n. 2, p.169-77, 1989.
- 12 - MONTGOMERY, D.L. Astrocytes: form, functions, and roles in disease. **Veterinary Pathology**, v.31, n.2, p.145-67, 1994.
- 13 - MURPHY, F.A. Rabies pathogenesis. **Archives of Virology**, v.54, n. 4, p.279-97, 1977.
- 14 - PARPURA, V.; BASARSKY, T.A.; LIU, F.; JEFTINIJA, K.; JEFTINIJA, S.; HAYDON, P.G. Glutamate-mediated astrocyte-neuron signalling. **Nature**, v.369, n. 6483, p.744-7, 1994.
- 15 - PEKNY, M.; LEVÉEN, M.P.; ELIASSON, C.; BERTHOLD, C.; WESTERMARK, B.; BETSHOLTZ, C. Mice lacking glial fibrillary acidic protein display astrocytes devoid of intermediate filaments but develop and reproduce normally. **EMBO Journal**, v.14, n. 8, p.1590-8, 1995.

Received: 6/3/96
Accepted: 17/2/97