

Braz. J. vet. Res. anim. Sci.,
São Paulo, v.33, n.3, p.144-148, 1996.

Ectopic osteomyelogenous response to demineralized bone matrix implant in busulphan treated mice

Resposta osteomielogênica ectópica ao implante de matriz óssea desmineralizada em camundongos tratados com bussulfano

Julietta Rodini Engrácia de MORAES¹; Flávio Ruas de MORAES¹;
Aureo Evangelista SANTANA¹

CORRESPONDENCE TO:
Julietta Rodini Engrácia de Moraes
Faculdade de Ciências Agrárias e
Veterinárias da UNESP
Rodovia Carlos Tonanni, km 5 -
Campus Jaboticabal
14870-000 - Jaboticabal - SP - Brasil

¹ - Faculdade de Ciências Agrárias
e Veterinárias da UNESP -
Jaboticabal - SP

SUMMARY

Swiss female mice (25-30 g; n = 100) were four times treated i.p. with busulphan (20 mg/kg), with 15 day interval between doses. Blood was collected by retroorbital puncture from treated and non treated control animals (n = 15) for white blood cell count, hematocrit and hemoglobin evaluation, before treatment and on 30th, 60th, 90th days following the first dose of the drug. On day 60 both treated (60 survived animals) and non treated (n = 15) animals received intermuscular implant of demineralized bone matrix (DBM-10 mg). All of them were killed 30 days after implant (90th day post busulphan initial dose) for histological analysis of esternal bone marrow (EBM) and ectopic osteomyelogenous response to the DBM implant. Thirty days after the first dose of busulphan, leukopenia and drop in the granulocyte, lymphocyte and monocyte numbers were observed. The hematocrit and hemoglobin rate decreased on 60th day. Histological analysis of the EBM of the test group showed hypocellularity, sinusoid capilar distention and reduction in megakaryocyte numbers. Control animals showed 100% positive response to DBM implant with the formation of metaplastic plaques made of bone trabeculae forming cavities filled with haematopoietic cells. 46.7% of the test animals had positive osteomyelogenous response, similar to that of the control groups, except for hypocellularity and more adipocytes; 25% displayed late and incomplete response with predominance of cartilaginous component, less neoformed bone tissue and absence of haematopoietic cells; the remaining 28.3% did not respond at all.

UNITERMS: Demineralization; Bones; Busulphan.

INTRODUCTION

Administration of high doses of busulphan, a cytostatic agent, for long periods, ends in hypoplasia or aplasia of the bone marrow. This occurs due to a permanent damage of the stem cells, jeopardizing their capacity to proliferate and differentiate haematopoietic cell lineages resulting in pancytopenia (Morley; Blake⁶, 1974; Morley *et al.*⁸, 1975; Trainor; Morley¹⁶, 1976; Pugsley *et al.*¹⁰, 1978).

The intermuscular implant of demineralized bone matrix (DBM) in mice leads to the appearing of metaplastic osteomyelogenous plaques within 30 days, with haematopoietic component physiologically and morphologically similar to the autologous marrow of the implanted animal (Urist; Strates²⁰, 1971; Reddi; Huggins¹², 1972; Urist; Craven¹⁹, 1980). The whole process is triggered by a morphogenetic protein (Bone Morphogenetic Protein-BMP) associated to the collagen of calcified tissues (Urist; Strates²⁰, 1971; Nilsson *et al.*⁹, 1986).

The aim of this study was to analyse the ectopic osteomyelogenous response induced by intermuscular DBM implant in busulphan-treated mice.

MATERIAL AND METHOD

Demineralized bone matrix (DBM) preparation

For the DBM preparation femur and tibia diaphyses were obtained from male and female mice. They were killed by prolonged ether inhalation, bones collected and soft tissues discarded. The material was processed according to Urist's¹⁸ technique (1973) slightly modified by Iderhia *et al.*¹ (1984).

DBM implant

Under light anesthesia with ether, animals were placed in lateral decubitus and after antisepsis with iodinated alcohol, a 1.5 cm incision was done in the left thigh skin and fascia. 10.0 mg of DBM was then put between biceps crural and lateral vastus muscles.

DBM efficiency evaluation

DBM efficiency in inducing ectopic osteomyelogenesis was previously tested through an intermuscular implant in naive animals (n = 15). Thirty days after DBM implant, the animals were killed by prolonged ether inhalation, and metaplastic plaques collected, fixed in Bouin's solution and processed according to standard histologic technique sections (6 μ m)

embedded in paraffin and stained with hematoxylin-eosin.

Busulphan treatment

Swiss, virgin, female mice (n = 100), weighing 25 to 30 g were treated intraperitoneally with 20 mg/kg of busulphan (Myleram-Welcome) given four times with fortnight interval between doses. Busulphan tablets were macerated, diluted and homogenized in a fresh water-acetone solution (4:1). From 100 treated animals 40 died and 60 were used for DBM implants. Control group (n = 15) received equal volume of diluent solution.

Hematologic evaluation

During treatment with busulphan, leukogram, hemoglobin and hematocrit rates from both test and control groups were evaluated at 30 day intervals until the 90th day following the immunosuppressant drug injection. Blood samples were taken from retroorbital plexus, diluted 1:20 in Turks' solution and total leukocyte numbers counted in Neubauer's chamber. Differential leukocyte counting was performed on panchromatically stained smears. Hematocrit rates were obtained by centrifugation of blood samples in capilar tubes for microhematocrit. Hemoglobin value was determined through the cyanomethahemoglobin method, and optical density of the solution was evaluated through spectrophotometry (Coleman-295).

Ectopic osteomyelogenous response in both control and treated animals

Ninety days after initial treatment with the immunosuppressor and 30 days after the DBM implant, animals from both test and control groups were killed and metaplastic plaques or similar in the implant site were surveyed. The plaques, as well as the sternum, were taken out and processed for histological evaluation as was described elsewhere.

Results were considered positive when the metaplastic plaques presented newly formed bone trabeculae with marrow cavities filled with haemopoietic tissue and absence of cartilaginous tissue. This is similar to the observed in the DBM efficiency evaluation in naive animals. Plaques with predominance of cartilaginous tissue over bone component and rare or absent haematopoietic tissue, were considered positive but with incomplete and of late development. Implants were considered negative when connective tissue capsule was formed surrounding the implanted DBM in the absence of cartilaginous, bone or haematopoietic tissues.

The sternum bone marrow evaluation was done by analysing haematopoietic cell population and its possible relation to busulphan's effect.

Statistical analysis

The results were analysed statistically through variance of

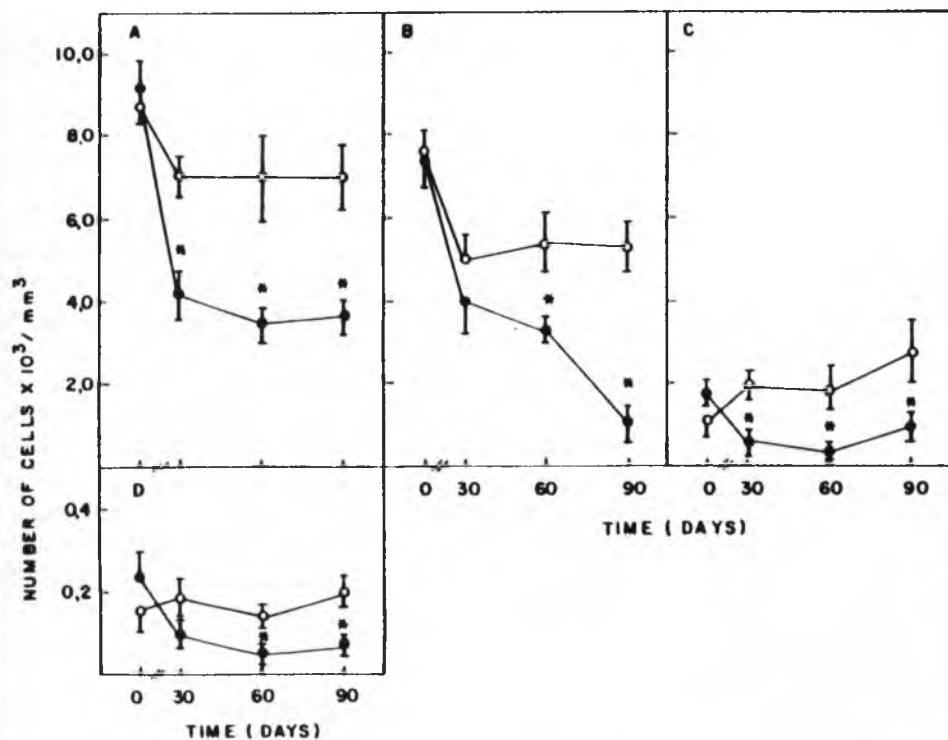


Figure 1

Effect of busulphan-treatment upon circulating leukocytes.

(A) total leukocytes;

(B) lymphocytes;

(C) granulocytes;

(D) monocytes.

(o) control animal (n = 15);

(●) treated animals (n = 60).

The results are means and SEM.

(*) significant difference (p<0.05) in relation to control group

means ($p < 0.05$) and by Tuckey's test (Snedecor; Cochran¹⁵, 1974).

RESULTS

Effect of treatment with busulphan upon circulating blood

Leukopenia with significant cell decrease ($p < 0.05$) was observed 30 days after the first dose of the drug, progressed and lasted until 9th day (Fig. 1A). Lymphocytopenia, ($p < 0.05$) which also lasted until the 90th day (Fig. 1B), reduction in the granulocyte numbers 30 days after the initial treatment, worsening on the 60th day, and a mild recovery on the 90th day (Fig. 1C), monocytopenia ($p < 0.05$) on the 60th day following the first dose of busulphan (Fig. 1D), were the blood leukocyte disturbances observed.

As to hematocrit values, there was a significant difference

($p < 0.05$) between the test and control groups only on 60th day (Fig. 2A). Hemoglobin levels of the test group had significant ($p < 0.05$) decrease on the 60th and 90th days with a slight recovery on the 90th day (Fig. 2B).

Effect of busulphan treatment upon bone marrow

The histologic study of the EBM of treated animals 90 days after the first dose of busulphan showed hypocellularity, sinusoid capillar dilation and a significant ($p < 0.05$) reduction (50%) on megakaryocyte numbers (control: 10.92 ± 0.36 ; test: 4.38 ± 0.67). Many of them showed karyolysis signs.

DBM efficiency evaluation

All of the test animals showed plaque formation, that was comprised by trabeculae of bone tissue forming cavities filled by haematopoietic tissue, similar to that of the sternal bone marrow (EBM) and without any cartilaginous tissue.

Response to DBM implant

Control animals

Thirty days after the intermuscular DBM implant a positive response was observed in all of the control animals, with formation of metaplastic plaques of bone trabeculae in which haematopoietic cells-filled cavities were seen. No cartilaginous tissue was observed. These results were similar to those observed in the DBM efficiency evaluation in naive animals.

Test animals

Sixty animals survived to the toxic effects of busulphan. Among them 28 (46.7%) had a positive response - similar to that observed in the control group - to the intermuscular implant of DBM. The haematopoietic tissue forming the ectopic bone marrow showed hypocellularity, sinusoid capillar dilation and moderate numbers of adipose tissue. In other 15 animals (25%) from this group, even though metaplastic plaque formation occurred, it was incomplete, with less neoformed bone tissue, predominance of cartilaginous tissue and absence of haematopoietic components. This response also considered delayed, once at that same time (30 days), in control animals, there was a predominance of bone trabeculae, forming haematopoietic component-filled cavities and absence of cartilaginous tissue.

In the remaining 17 animals (28.3%), just a fibroblastic reaction around DBM particles was observed. There was no cartilaginous, bone or haematopoietic tissue formation. This response pattern was considered negative.

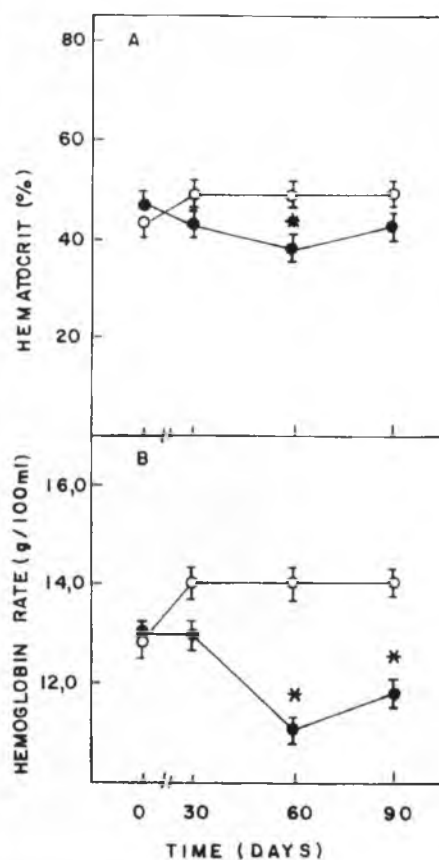


Figure 2

Effect of busulphan-treatment upon hematocrit (A) and hemoglobin rate (B). (o) control animals (n = 15); (●) treated animals (n = 60). The results are means and SEM. (*) significant difference ($p < 0.05$) in relation to control group.

DISCUSSION

The evident reduction of white blood cells due to the toxic

effect of busulphan, as previously referred by Morley; Blake^{5,6} (1974), was also observed in the surviving mice of experimental group. Lymphocytopenia seems to be the main determinant of leukopenia, even though lymphocytes were the predominant white blood cell type found in the peripheral blood. The earlier decrease of leukocyte number observed on the 30th day, when compared to the data of Iderhia *et al.*³ (1984), could be explained by the fact that they carried out first hematological examination only on the 55th day post busulphan treatment, so that any precocious alterations could be observed by them. Moreover, treatment schedule modifications were introduced in the present work: while Iderhia *et al.*³ (1984) used 3 doses of 20 mg/kg and 1 of 10 mg/kg with 15 day interval among them, followed by a 5th dose of 20 mg/kg on the 105th day, 4 doses of 20 mg/kg with 15 day intervals were used in this work.

Hematocrit and hemoglobin values decrease, as well as histological alterations like hypocellularity, sinusoid dilation and decrease on megakaryocyte number - observed on EBM of treated mice - essentially proved the effect of busulphan causing permanent lesion of stems cells, as referred by Morley; Blake⁷ (1975). Some evidence exists that the colony, forming units which survive the treatment, loose their proliferating and maturation capacity (Dun; Elson², 1970). The formation of metaplastic plaques of bone and haematopoietic tissue observed by Urist¹⁷ (1965) and Bang; Urist¹ (1967) was essentially the same as observed in all control rats in the present case. On the other hand, the intermuscular implant of DBM in busulphan treated animals resulted in a positive response in about half of the animals

from experimental group on day 30 post treatment. Ectopic marrow tissue was hypocellular and with higher rate of adipocytes than in the control animals.

As could be expected, formation of BMP and haematopoietic tissue occurred within 30 days after intermuscular implant of DBM in all control animals, in the same way as observed by other authors (Urist¹⁷, 1965; Bang; Urist¹, 1967; Urist; Strates²⁰, 1971; Reddi; Huggins¹², 1972; Reddi; Anderson¹¹, 1976; Wlodarski; Jacobsiak²¹, 1978; Iderhia *et al.*³, 1984; Santana¹⁴, 1988; Moraes; Moraes⁴, 1993). On the other hand, only 46.7% of treated mice showed weak positive response, comprised by hypocellular marrow with high number of adipocytes. The higher rate of complete osteomyelogenic plaques formation and earlier response seen by the authors, when compared to the results obtained by Iderhia *et al.*³ (1984), were probably related to the difference of protocol introduced in the present research, that is, busulphan doses and intervals between each one. The most important difference introduced was the time when DBM implant was carried on: 60 days after first treatment, in opposition to 135 days referred by them. Earlier implant may result in more effective osteomyelogenic response. This could be explained by the fact that mononuclear phagocytes play an important role in heterotopic ossification induced by DBM that leads to the production of factors influencing its development (Sakata; Takagi¹³, 1986; Moraes; Moraes⁴, 1993). Therefore, busulphan-induced leukopenia may interfere directly in the successful implant of DBM, that is, the least number of leukocytes, specifically monocytes, the smaller is the probability of induction of heterotopic ossification.

RESUMO

Camundongos Swiss, fêmeas, (25-30 g; n = 100) receberam 4 injeções de bussulfano (20 mg/kg, ip) a intervalos de 15 dias (n = 100). Antes do tratamento e após 30, 60 e 90 dias, os animais deste e de um grupo controle (n = 15) foram avaliados quanto ao leucograma, taxa de hemoglobina e hematócrito por meio do sangue colhido por punção retroorbital. Sessenta dias após o início do tratamento, 60 animais sobreviventes do grupo tratado e 15 animais do grupo controle receberam implantes intermusculares de matriz óssea desmineralizada (MOD-10 mg). No 90^o dia (30 dias após o implante) foram sacrificados para exame histológico da medula óssea esternal (MOE) e da resposta osteomielogênica ao implante de MOD. Trinta dias após o início do tratamento observou-se leucopenia, com diminuição do número de granulócitos, linfócitos e monócitos nos animais que receberam bussulfano. O hematócrito e a taxa de hemoglobina apresentaram-se diminuídos no 60^o dia. O exame histológico da MOE do grupo tratado revelou hipocelularidade, dilatação dos capilares sinusóides e redução do número de megacariócitos (50%). Os animais controle apresentaram 100% de resposta positiva ao implante de MOD, havendo formação de placas metaplásicas compostas por trabéculas ósseas contendo cavitações preenchidas por células hematopoiéticas. Em 46,7% dos animais tratados observou-se resposta osteomielogênica semelhante à do grupo controle, mas com hipocelularidade e maior componente de adipócitos; 25% apresentaram resposta osteomielogênica tardia e incompleta com menor componente ósseo, maior componente cartilaginoso e ausência de células hematopoiéticas; nos 28,3% restantes a resposta foi negativa.

UNITERMOS: Ossos; Desmineralização; Bussulfano.

ACKNOWLEDGMENTS

We thank Mrs. M.Y.I. Campos and Miss F.A. Ardisson for technical assistance.

20-URIST, M.R.; STRATES, B.S. Bone morphogenetic protein. *Journal of Dental Research*, v.50, p.1392-406, 1971. Supplement.

21-WLODARSKI, K.; JAKOBISIAK, M. Cytological analysis of bone marrow present in the bone nodules induced by human F1 cells in mice. *Folia Biologica*, v.24, p.215-8, 1978.

REFERENCES

- 1-BANG, G.; URIST, M.R. Bone induction in excavation chambers in matrix of decalcified dentin. *Archives of Surgery*, v.94, p.781-9, 1967.
- 2-DUN, C.D.R.; ELSON, L.A. The comparative effect of busulphan (Myleran) and aminochloramionbucil on haemopoietic colony forming units in the rat. *Cell and Tissue Kinetics*, v.3, p.131-41, 1970.
- 3-IDERHIA, N.M.; VUGMAN, I.; FALCÃO, R.P. Ectopic bone marrow development in experimental busulfan-induced hypoplastic anemia in mice. *Blut*, v.48, p.277-84, 1984.
- 4-MORAES, J.R.E.; MORAES, F.R. Effect of a persistent inflammatory process on experimental heterotopic ossification. The influence of macrophages. *Brazilian Journal of Medical and Biological Research*, v.26, p.53-66, 1993.
- 5-MORLEY, A.; BLAKE, M.A. An animal model of chronic aplastic marrow failure. I. Late marrow failure after Busulphan. *Blood*, v.44, p.49-56, 1974.
- 6-MORLEY, A.; BLAKE, M.A. Haematopoietic precursor cells in experimental hypoplastic marrow failure. *Australian Journal of Experimental Biology and Medical Science*, v.52, p.909-14, 1974.
- 7-MORLEY, A.; BLAKE, M.A. Observer error in histological assessment of marrow hypocellularity. *Journal of Clinical Pathology*, v.28, p.104-8, 1975.
- 8-MORLEY, A.; TRAINOR, K.; BLAKE, M.A. A primary stem-cell lesion in experimental chronic hypoplastic marrow failure. *Blood*, v.45, p.681-8, 1975.
- 9-NILSSON, O.S.; URIST, M.R.; DAWSON, E.G.; SCHMALZRIED, T.P.; FINERMAN, G.A.M. Bone repair induced by bone morphogenetic protein in ulnar defects in dogs. *Journal of Bone and Joint Surgery*, v.68, p.635-42, 1986.
- 10-PUGSLEY, C.A.J.; FORBES, I.J.; MORLEY, A. Immunologic abnormalities in an animal model of chronic hypoplastic marrow failure induced by Busulphan. *Blood*, v.51, p.601-10, 1978.
- 11-REDDI, A.H.; ANDERSON, W.A. Collagenous bone matrix-induced endochondral ossification and hemopoiesis. *Journal of Cell Biology*, v.69, p.557-72, 1976.
- 12-REDDI, A.H.; HUGGINS, C.B. Biochemical sequences in the transformations of normal fibroblasts in adolescent rats. *Proceedings of the National Academy of Sciences of the United States of America*, v.69, p.1601-5, 1972.
- 13-SAKATA, H.; TAKAGI, K. Effect of bone marrow mononuclear phagocytes on the bone matrix-induced bone formation in rats. *Clinical Orthopaedics and Related Research*, v.220, p.253-8, 1986.
- 14-SANTANA, A.E. *Benzenismo experimental. Desenvolvimento de medula óssea ectópica*. Ribeirão Preto, USP, 1988. Tese (Doutorado) - Faculdade de Medicina de Ribeirão Preto.
- 15-SNEDECOR, G.W.; COCHRAN, G.B. *Statistical methods*. Ames, Iowa State University, 1974.
- 16-TRAINOR, K.; MORLEY, A.H. Screening of citotoxic drugs for residual marrow damage. *Journal of the National Cancer Institute*, v.57, p.1237-40, 1976.
- 17-URIST, M.R. Bone formation by autoinduction. *Science*, v.150, p.893-9, 1965.
- 18-URIST, M.R. A bone morphogenetic system in residues of bone matrix in the mouse. *Clinical Orthopaedics and Related Research*, v.91, p.210-20, 1973.
- 19-URIST, M.R.; CRAVEN, P.L. Bone cell differentiation in avian species. *Federation Proceedings*, v.29, p.1680-5, 1970.

Recebido para publicação: 27/10/93

Aprovado para publicação: 08/11/95