

Brazilian Journal of Veterinary Research and Animal Science (2003) 40:73-78  
ISSN printed: 1413-9596  
ISSN on-line: 1678-4456

## Real time B-mode ultrasound in pacas pregnancy (*Agouti paca*, Linnaeus, 1766)

### Ultra-sonografia em tempo real e modo B em prenhez de pacas (*Agouti paca*, Linnaeus, 1766)

Fabrício Singaretti de OLIVEIRA<sup>1</sup>;  
Márcia Rita Fernandes MACHADO<sup>2</sup>;  
Júlio Carlos CANOLA<sup>1</sup>

1 Departamento de Clínica e Cirurgia Veterinária da Faculdade de Ciências Agrárias e Veterinárias da UNESP, Jaboticabal - SP  
2 Departamento de Morfologia e Fisiologia Animal da Faculdade de Ciências Agrárias e Veterinárias da UNESP, Jaboticabal - SP

#### Summary

The aim of this study was to establish the pregnancy period of *paca* by means of ultrasound use. Nine pregnant pacas were periodically scanned with a two-frequency sectorial electronic transducer of 5.0 and 7.5 MHz, in B mode, from ultrasound detection of embryo vesicle or fetus until the parturition. Animals were placed in an iron-bar squeeze cage and remained in standing position during sessions. A dark cloth was used to cover the cage and fruits were offered during ultrasound session to avoid aggressive reactions. The more premature occurred detection of pregnancy, the greater the period of ultrasound examination until the birth of the offspring. All gestation delivered only one newborn weighting  $796.5 \pm 74.36$  grams (mean value  $\pm$  standard error of the sample) and  $33.46 \pm 0.60$  centimeters (mean value  $\pm$  standard error of the sample) of length (from rostral edge of nose and distal portion of tail). The length of *paca* pregnancy ranged from 135 to 139 days.

#### Key-words

Paca.  
Ultrasonography.  
Pregnancy.

#### Correspondência para:

FABRÍCIO SINGARETTI DE OLIVEIRA  
Departamento de Clínica e Cirurgia Veterinária  
Faculdade de Ciências Agrárias e Veterinárias da UNESP  
Via de Acesso Prof. Paulo Donato Castellane, s/n  
14884-900 - Jaboticabal - SP  
e-mail: [singaretti@ig.com.br](mailto:singaretti@ig.com.br)

Received: 02/07/2002  
Accepted: 21/12/2002

#### Introduction

Rodents are considered experimental models due to their characteristics as small size, low commercial price and short period of pregnancy. Precise information about reproductive aspects of these species is rare, what can cause misinterpretation of many experiments<sup>1</sup>.

Search for new species to be used as experimental models enhances

the importance of searches about placenta and pregnancy of rodents, essential for man and other animal species<sup>2</sup>.

In Costa Rica, pacas raise in captivity have 31,16 day-period of heat cycle<sup>3</sup> and 33,40 day-period in Brazil<sup>4</sup>. Pregnancy period of these rodents is about 114 days, varying from 85 to 156 days<sup>3</sup>, 115 days<sup>5,6,7</sup>, 116 days<sup>8</sup>, 150 days<sup>4</sup> and about 155 days, varying from 138 to 173 days<sup>9</sup>.

Usually, only one neonate occurs

by birth and hardly, two or three<sup>7,10,11,12</sup>. Youngs are born with 23 cm in length<sup>11</sup>, or 24 to 30 cm<sup>12</sup>, from the rostral edge of nose to distal portion of tail; its body weight varies from 550 to 800 grams<sup>12</sup>, is about 710 grams<sup>6</sup> and it is, approximately, 650 grams<sup>11</sup>.

Since paca is a rodent whose period of pregnancy has not been precisely stated, it was aimed, in this study, to state this period with ultrasound, as well as the size and weight of newborns.

## Material and Method

Twelve female adult and 6 male adult pacas were used, identified by microchips that were applied in their cervicodorsal region. These animals belong to Wild Animals Sector of the College of Agricultural and Veterinarian Sciences, São Paulo State University, Jaboticabal, São Paulo, Brazil and were kept in groups of one male and two females per pen of 15 m<sup>2</sup> area, with a water flow of one meter width, 1.5 m of length and 0.5 m of depth. There was also a brick burrow, subdivided in three inside portions.

The handling, including tranquilization of pacas, previously and during ultrasound sessions, was adopted according to descriptions of Oliveira<sup>13</sup>.

The ultrasound sessions were done once a week but, due to an abortion and absence of new pregnancies for four months in a row, this interval was changed to every two weeks and then monthly until animals became adapted to this handling, what took about a year. Interval between sessions was decreased until reach approximately 10 days.

Ultrasound sessions were done in B mode with a two-frequency sectorial electronic transducer of 5.0 and 7.5 MHz (LC 100 Vet™, Pie Medical®, The Netherlands). First, urinary bladder was visualized for

identification of uterine horns and detection of probable pregnancy. In case of evidence of pregnancy, two perpendicular measures of placenta were taken, in longitudinal cut, to state relationship between size of the calculated area of this organ and age of the fetus; measures of fetal heart were also taken since its ultrasound visualization, that happened some weeks after visualization of placenta, always trying to evidence this organ in such a plan that evidenced its larger area; longitudinal and transversal plans were not used so, during intra uterine life, cardiac chambers can not be defined and sized, preventing to state these plans. Measures of the longitudinal length of fetus were not used, because in some weeks, they reached dimensions that prevented its whole visualization in ultrasound monitor.

## Results

During 18 months, nine pregnancies were detected in early phases with visualization of embryo vesicles or fetus in early stages of development and ultrasound exams were performed until delivery of offspring, happening after 100 days (two cases), 110 days (one case), 114 days (one case), 117 days (three cases), 122 days (one case) and 131 days (one case). Paca examined by ultrasound at 110 days and in one female examined at 117 days, ultrasound detection of pregnancy happened after 18 days of separation from male, when both were considered non pregnant; that increased scanning time to 128 and 135 days in these two animals.

In female examined during 131 days, ultrasound detection of pregnancy was more premature than pacas scanned during 122, 117, 114 or 100 days. In the same way, female examined during a 122 days, detection of pregnancy was more premature

than animal scanned for 117 days, 114 or 100 days. Therefore, it was estimated that ultrasound detection of pregnancy of paca happened with ninth day after breeding through visualization of embryo vesicle in early stage of development and total period of pregnancy lasts 135 to 139 days.

One embryo resorption and three miscarriages in different females happened along the experiment.

Linear regression equation of placenta area development (y1) over time (x) was  $y1 = 2.565x + 5.0146$  and linear regression equation of fetus heart area development (y2) over time (x) was  $y2 = 0.4636x - 0.4613$ , what means that while the placenta area increases 2.565 cm<sup>2</sup>, the fetus heart area increases 0.4636 cm<sup>2</sup> at the same period. The test of parallelism and coincidence of these two straight lines was significative ( $p > 0.05$ ),

**Table 1**

Mean areas of heart and of placenta of paca fetus obtained with ultrasound in each interval of days before delivery (\* not visualized in ultrasound). Jaboticabal- SP, 2002

Interval of days before delivery	Area of placenta (cm <sup>2</sup> ) ± standard error of the sample	Area of fetus heart (cm <sup>2</sup> ) ± standard error of the sample
120-129	0.73 ± 0.02	*
110-119	2.50 ± 1.01	*
100-109	4.72 ± 1.06	*
90-99	7.44 ± 0.68	*
80-89	8.39 ± 1.42	0.27 ± 0.07
70-79	10.34 ± 1.16	0.42 ± 0.07
60-69	11.27 ± 2.02	0.86 ± 0.22
50-59	14.83 ± 2.55	1.20 ± 0.29
40-49	18.29 ± 1.57	1.75 ± 0.32
30-39	20.71 ± 2.24	2.22 ± 0.18
20-29	23.12 ± 3.37	2.91 ± 0.38
10-19	25.49 ± 2.70	3.31 ± 0.22
1-9	28.11 ± 3.23	3.78 ± 0.40

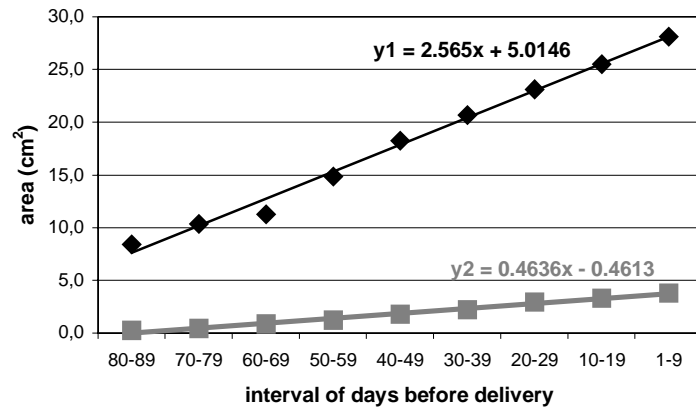
**Table 2**

Weight and length of paca offspring at birth. Longitudinal length was taken from rostral edge of nose to distal portion of tail. F: female; M: Male; <sup>a</sup>Mean value and standard error of males and females; <sup>b</sup>Mean value and standard error of females; <sup>c</sup>Mean value and standard error of males. Jaboticabal, SP, 2002

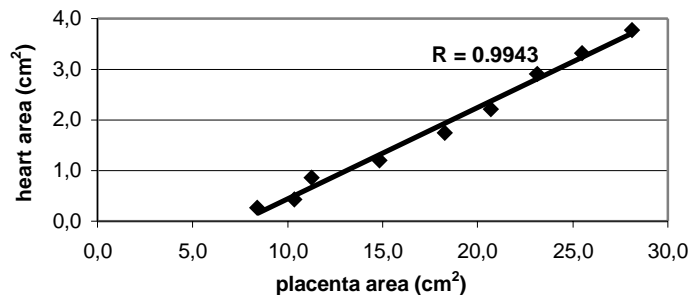
Sex of offspring	Weight (g)	Longitudinal length (cm)
F	902.50	34.60
F	731.10	32.80
F	770.00	33.50
M	770.60	34.20
M	724.30	33.00
M	815.10	33.40
M	741.90	32.90
M	642.20	33.30
M	691.80	33.40
	<sup>a</sup> 754.39 ± 74.36	<sup>a</sup> 33.46 ± 0.60
	<sup>b</sup> 801.20 ± 89,86	<sup>b</sup> 33.63 ± 0.91
	<sup>c</sup> 730.98 ± 60.38	<sup>c</sup> 33.37 ± 0.46

**Figure 1**

Graphic of linear regression equations of developments of placenta (y1) and of heart (y2) areas in paca fetus. Jaboticabal, SP, 2002

**Figure 2**

Correlation between development of placenta and of heart areas in paca fetus. \*R: Correlation coefficient. Jaboticabal, SP, 2002



that is, lines are not parallels because their angular coefficients are different (Figure 1).

Mean values of the placenta area, from 120 to 129 days before delivery, and the ones of fetus heart, from 80 to 89 days before delivery are indicated in Table 1. Using these measures from 89-80 days before delivery until parturition, there could be shown the coefficient of correlation (R) between areas of these two organs during their developments, which was 0.9943 or 99.43 %, and significative ( $p < 0.05$ ), that is, these variables present a high positive correlation, what represents a proportional development almost

perfect between placenta and fetus heart (Figure 2).

All gestation resulted in one newborn litter, which weighted  $754.39 \pm 74.36$  g (mean value  $\pm$  standard error of the sample) and presented mean longitudinal length, contained between distal portions of tail and nose, of  $33.46 \pm 0.60$  cm (mean value  $\pm$  standard error of the sample) (Table 2).

## Discussion

Using dimension of uterine horns, embryos and fetuses sizes

visualized by ultrasound of nine pregnancies studied until birth, the period of pregnancy of paca was estimated ranging from 135 to 139 days, differing from reports of 114,28 days<sup>3</sup>, 115 days<sup>5,6,7</sup>, 116 days<sup>8</sup>, 150 days<sup>4</sup> or 155 days<sup>9</sup> for this gestation period.

Ultrasound visualization of embryo vesicle of paca, using a two-frequency transabdominal transducer of 5.0 and 7.5 MHz, was possible on ninth day after breeding, just like for mares<sup>14</sup>, and short-tailed gray opossum<sup>15</sup>, and similar to eleventh day reported in cats<sup>16</sup> and to thirteenth days described in poneys<sup>17</sup>.

Adverse alterations in embryo and in fetus were also visualized with ultrasound during pregnancy in pacas. Vestiges of placenta liquid inside uterus were also found in three different females after scanning, which characterized miscarriages<sup>18</sup>. Reduction of embryo fluid with ecogenicity and flattening of embryo vesicle, invagination of uterus wall at embryo vesicle and non cardiac activity of embryo could also be found by ultrasound, indicating embryo death and resorption<sup>18,19</sup>.

Only one offspring was born in each delivery<sup>7,10,11,12</sup>, weighting 754.39

$\pm 74.36$  g, similarly to 550 to 800 g<sup>12</sup> and 710 g<sup>6</sup>, and different from 650 g<sup>11</sup> already reported.

In relation to the size of newborns, measured from rostral limit of nose and distal portion of tail, the mean length of  $33.46 \pm 0.60$  cm was higher than 23 cm<sup>11</sup> and a interval of 24 to 30 cm<sup>12</sup> already described by other authors.

## Conclusions

The period of pregnancy ranges from 135 to 139 days and visualization of embryo vesicle by ultrasound was possible on ninth day after breeding. Mean value of placenta was  $0.73 \pm 0.02$  cm<sup>2</sup> (mean value  $\pm$  standard error of the sample) from 120 to 129 days and  $28.11 \pm 3.23$  cm<sup>2</sup> (mean value  $\pm$  standard error of sample) from 1 to 9 days before delivery and the mean value for the area of fetus heart was  $0.27 \pm 0.07$  cm<sup>2</sup> (mean value  $\pm$  standard error of sample) from 80 to 89 and  $3.78 \pm 0.40$  cm<sup>2</sup> (mean value  $\pm$  standard error of sample) from 1 to 9 days before delivery.

All gestation resulted in one newborn litter, weighting 754.39  $\pm$  74.36 g and measuring  $33.46 \pm 0.60$  cm.

## Resumo

O objetivo deste estudo foi estabelecer o tempo de prenhez da paca por meio de ultra-sonografia. Nove pacas prenhes foram periodicamente acompanhadas com um transdutor eletrônico setorial bi-frequencial de 5,0 e 7,5 MHz, em modo B, desde a detecção ultra-sonográfica da vesícula embrionária ou do feto até o nascimento dos filhotes. Os animais foram colocados em uma gaiola de ferro de prensagem lateral e permaneceram em posição quadrupedal durante as sessões. Um pano escuro foi usado para cobrir a gaiola e frutas foram oferecidas durante o exame ultra-sonográfico para evitar reações agressivas. Quanto mais precocemente ocorreu a detecção de prenhez, maior foi o período de acompanhamento ultra-sonográfico até o nascimento dos filhotes. Apenas um filhote nasceu por parto, com  $796,5 \pm 74,36$  gramas (valor médio  $\pm$  desvio padrão da amostra) e  $33,46 \pm 0,60$  centímetros (valor médio  $\pm$  desvio padrão da amostra) de comprimento (entre a borda rostral do focinho e a extremidade distal da cauda). O período de prenhez da paca abrange 135 a 139 dias.

## Palavras-chave

Pacas.  
Ultrassonografia.  
Prenhez.

## References

- 1- BJÖRKMAN, N.; DANTZER, V.; LEISER, R. Comparative placentation in laboratory animals—a review. **Scandinavian Journal of Animal Science**, v. 16, n. 4, p. 129-158, 1989.
- 2- HAMELLETT, W. C.; RASWEILER IV, J. J. Comparative gestation and placentation in vertebrates. **Journal of Experimental Zoology**, v. 266, n. 5, p. 343-346, 1993.
- 3- MATAMOROS, Y.; PASHOV, B. Ciclo estral del tepezcuinte (*Cuniculus paca*, brisson) en cautiverio. **Brenesia**. v. 22, p. 249-260, 1984.
- 4- NOGUEIRA, T. M. R. **Alguns parâmetros fisiológicos e reprodutivos da paca (*Agouti paca*, Linnaeus, 1766), em cativeiro**. 1997. 131 f. Dissertação (Mestrado em Produção Animal) – Faculdade de Ciências Agrárias e Veterinárias, Universidade Estadual Paulista, Jaboticabal, 1997.
- 5- CLARK, J. D.; OLFERT, E. D. Rodents (Rodentia). In: FOWLER, M. E. **Zoo & wild animal medicine**, 3. ed. Philadelphia: W.B. Saunders, 1986. p. 728-737.
- 6- KLEIMAN, D. G.; EISENBERG, J. F.; MALINIAK, E. Reproductive parameters and productivity of caviomorph rodents. In: EISENBERG, J. F. **Vertebrate ecology in the northern neotropics**. Washington: Smithsonian Institution, 1979. p. 173-183.
- 7- PÉREZ, H. C., HERNÁNDEZ, F. Z. Comportamiento reproductivo y datos de la alimentación de Agouti paca. **Acta Zoologica Lilloana**, v. 35, p. 283-285, 1979.
- 8- COLLET, S. F. Population characteristics of *agouti paca* (rodentia) in Colombia. **Biological Series**, v. 5, n. 7, p. 601, 1981.
- 9- SMYTHE, N. Paca. In: ROBINSON, J. G.; REDFORD, K. H. **Microlivestock: little known small animals with promising economic future**. Washington: National Academy, 1991. p. 263-269.
- 20- DEUTSCH, L. A.; PUGLIA, L. R. R. **Os animais silvestres: proteção, doenças e manejo**. Rio de Janeiro: Globo, 1988. p. 45-50.
- 10- BENTTI, S. B. Roedores de la america tropical. **Natura**. v. 70, n. 1, p. 40-44, 1981.
- 11- MATAMOROS, Y. Notas sobre la biologia del tepezcuinte, *Cuniculus paca*, brisson, (rodentia: dasyproctidae) en cautiverio. **Brenesia**, v. 19/20, p. 71-82, 1982.
- 12- MONDOLFI, E. La laca o paca. **Defesa de la Naturaleza**, v. 2, n. 5, p. 4-16, 1972.
- 13- OLIVEIRA, F. S. **Diagnóstico e acompanhamento ultra-sonográfico da prenhez em pacas (*Agouti paca*, Linnaeus, 1766)**. 2002. 45 f. Dissertação (Mestrado em Cirurgia Veterinária) – Faculdade de Ciências Agrárias e Veterinárias, Universidade Estadual Paulista, Jaboticabal, 2002.
- 21- EMMONS, L. H. **Neotropical rainforest mammals: a field guide**. Chicago: The University of Chicago Press, 1990. p. 204-205.
- 14- JAINUDEEN, M. R.; HAFEZ, E. S. E. Diagnóstico de prenhez. In: HAFEZ, E. S. E. **Reprodução em animais domésticos**. 6. ed., São Paulo: Manole, 1995. p. 446-460.
- 15- MILES, K. G.; SONEA, I. M.; JACKSON, L. L.; RIEDERSEL, E. A.; RIEDERSEL, D. H.; JACOBSON, C. D. Ultrasonographic pregnancy detection and inhalation anesthesia in the gray short-tailed opossum (*Monodelphis domestica*). **Laboratory Animal Science**, v. 47, p. 280-282, 1997.
- 16- NYLAND, T. G.; MATTOON, J. S. Ultrasonography of the genital system. In: \_\_\_\_\_. **Veterinary diagnostic ultrasound**. Philadelphia: W.B. Saunders, 1995. p. 141-164.
- 17- GINTHER, O. J. **Ultrasonic imaging and reproductive events in the mare**. 3. ed. Wisconsin: Equiservices, 1986. p. 195-224.
- 18- KÄHN, W. **Veterinary reproductive ultrasonography**. Hannover: Schlütersche Verlagsanstalt und Druckerei GmbH, 1994. p. 69-73, 247.
- 19- LEITH, G. S., ALLEN, A. K. Ultrasonography for reproductive management in the mare. In: NYLAND, T. G.; MATTOON, J. S. **Veterinary diagnostic ultrasound**. Philadelphia: W.B. Saunders, 1995. p. 305-320.
- 20- DEUTSCH, L. A.; PUGLIA, L. R. R. **Os animais silvestres: proteção, doenças e manejo**. Rio de Janeiro: Globo, 1988. p.45-50.
- 21- EMMONS, L. H. **Neotropical rainforest mammals: a field guide**. Chicago: The University of Chicago Press, 1990. p. 204-205.
- 22- MERITT, D. A. The husbandry and management of the paca (*Cuniculus paca*) at lincoln park zoo, Chicago. **International Zoo Yearbook**. v. 28, p. 264-267, 1989.