

Brazilian Journal of Veterinary Research and Animal Science (2004) 41:183-188  
ISSN printed: 1413-9596  
ISSN on-line: 1678-4456

## The carcinogenic potential of cadmium in the palatal and gingival epithelium of rats. A morphologic and morphometric analysis

### Avaliação do potencial carcinogênico do cádmio no epitélio de revestimento do palato e gengiva de ratos. Estudo morfológico e morfométrico

Ana Carolina Fragoso Motta<sup>1</sup>;  
Dante Antonio MIGLIARI<sup>1</sup>;  
Marco Antonio GIOSO<sup>2</sup>;  
Marilena Chinali KOMESU<sup>3</sup>;  
Miguel Angel SALA<sup>3</sup>;  
Ruberval Armando LOPES<sup>3</sup>

1- Departamento de Diagnóstico Bucal da Faculdade de Odontologia da Universidade de São Paulo, São Paulo - SP  
2- Departamento de Cirurgia da Faculdade de Medicina Veterinária e Zootecnia da Universidade de São Paulo, São Paulo - SP  
3- Departamento de Morfologia, Estomatologia e Fisiologia da Faculdade de Odontologia da Universidade de São Paulo, Ribeirão Preto - SP

#### Abstract

Cadmium (Cd) is a heavy metal that exerts a variety of toxic effects, chronic and acute, in exposed organisms. The aim of this study was to investigate the carcinogenic potential of Cd in the palatal and gingival epithelium of Wistar rats. Two groups of animals were studied: group 1 consisted of 5 rats exposed to cadmium chloride (CdCl<sub>2</sub>) in drinking water (300 mg/L) for 6 months; group 2 also consisted of 5 rats placed in the same conditions as those of group 1, but kept free of Cd for 6 additional months. Two other groups (C1 and C2) with the same number of animals, but not exposed to CdCl<sub>2</sub> were used as a control for groups 1 and 2, respectively. All animals were weighed before and after the experimental period. After animals being killed, tissues of interest were fixed in solution of 10% formalin, processed by standard histologic techniques, stained with HE, and analyzed under light microscopy using karyometric and stereologic parameters. Loss of body weight, atrophy of the gingiva and soft-palate epithelium were the principal findings of this study, and verified only in the group 1 ( $p < 0.05$ ). In conclusion, at the concentration tested, Cd presented no carcinogenic effect on the oral tissues within the experimental time period.

#### Key- words:

Cadmium chloride.  
Oral cancer.  
Carcinogenesis.  
Rat .

#### Correspondência para:

ANA CAROLINA FRAGOSO MOTTA  
Departamento de Diagnóstico Bucal  
Faculdade de Odontologia  
Universidade de São Paulo  
Av. Prof. Lineu Prestes, 2227  
Cidade Universitária Armando Salles de Oliveira  
05508-000 - São Paulo - SP  
anacfm@usp.br

Recebido para publicação: 05/11/2003  
Aprovado para publicação: 25/03/2004

#### Introduction

Cadmium (Cd) is an industrial and environmental pollutant of considerable importance that poses a significant health risk to humans and animals. It is widely dispersed into the biosphere by mining and manufacturing processes, and has an extremely long biological half-life that essentially makes it a cumulative toxin.<sup>1,2,3</sup> Cd deposited in the environment can give rise to serious intoxication in human beings and other organisms through different routes,

which include soil, air, water and plants. This metal may be uptaken by plants and agricultural products, which can result in an increase of oral exposure.<sup>4,5,6</sup>

It is well documented that chronic exposure to Cd leads to the development of cancer in many organs, especially the lungs, kidneys and liver.<sup>4,7</sup> Alterations on the oral epithelium and in the salivary glands, characterized by reduction of the nuclear cell under cadmium exposure, have been reported.<sup>8,9,10</sup> There have been only a few studies concerning any possible carcinogenic

effect of Cd in the oral tissues<sup>11,12</sup>, and none of these revealed any association.

The aim of this study was to investigate the carcinogenic effects of Cd, administered through drinking water, on the palatal and gingival epithelium of rats, using morphologic and morphometric techniques.

## Materials and Methods

### Animals

Twenty adult male rats (*Rattus norvegicus albinus*, variety Wistar) weighing 160 to 180 g were housed in groups of five in plastic cages under controlled conditions of temperature (21°C to 25°C), relative humidity (45% to 50%) and light/dark cycles (12 hours of light/ 12 hours of darkness). Rats were given *ad libitum* access to a standard rodent maintenance diet (Nuvilab, Curitiba, PR, Brazil) and tap water.

### Chemical

The cadmium chloride (CdCl<sub>2</sub>) used in this study was obtained from Sigma Chemical Company (St. Louis, MO, USA) with the following specifications: hydrate minimum 98%, water content approximately 2.5 mole/mole. The CdCl<sub>2</sub> was dissolved in drinking (tap) water at the concentration 300 mg/L. The control group drank tap water only.

### Experimental design

CdCl<sub>2</sub> in drinking water was consumed by two groups of five rats. These groups were characterized as follow: 5 animals (group 1) treated with water containing CdCl<sub>2</sub> for 6 months and 5 other animals (group 2) treated with water containing CdCl<sub>2</sub> for 6 months and for another period of 6 months with water free of CdCl<sub>2</sub>. Two other groups of 5 rats, one consuming water free of cadmium for 6 months (group C1) and the other for 12

months (group C2) were used as control for group 1 and 2, respectively. After the experimental period of each group, the animals were individually weighted and subsequently killed by ether anaesthesia. After being killed each animal was submitted to a procedure for removing the structures of interest, i.e, hard and soft palate, and gingiva.

### Histopathologic examination

Tissues were fixed in solution of 10% formalin for 48 hours. Sections of hard and soft palate and gingiva were processed by standard histologic techniques, and stained with hematoxylin and eosin for light microscopy.

### Morphometry

The histologic sections were examined under light binocular microscopy (Zeiss, Germany) with objective of immersion (magnified one hundred times–100x), aided with a device built for karyometric and stereologic analysis.<sup>13,14</sup>

### Mitotic index

A minimum of 1,000 cells in the basal layer were counted, and the number of cells showing arrested metaphase was determined.

### Statistical analysis

Data were analyzed using Mann-Whitney test, and significance was set at  $p < 0.05$ .

## Results

### Body weight

The difference between the mean of the body weight of rats from group 1 (367.60 ± 35.50g) and that of the control group C1 (541.80 ± 32.32g) was statistically significant ( $p=0.004$ ). On the other hand, the difference between the mean of the body weight of

rats from group 2 ( $526.60 \pm 38.19$ ) and that of the control group C2 ( $541.40 \pm 34.67$ ) did not reach statistical significance ( $p = 0.210$ ).

**Histopathologic and morphometric findings**

Analysis of tissue sections by standard techniques, using hematoxylin-eosin staining, showed a decrease of the epithelial thickness, along with variation in the size and shape of nuclei in the epithelium of the soft palate and gingiva of only the animals from group 1

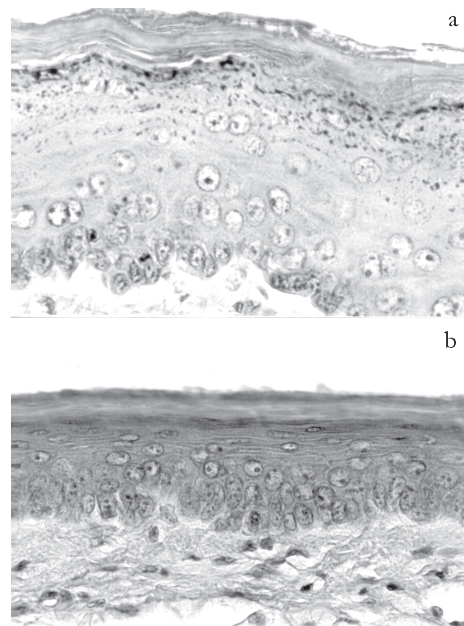
(Figures 1 and 2). A detailed, comparative analysis of morphologic variation of nuclei between animals exposed to CdCl<sub>2</sub> and their respective controls was carried out based on measurement obtained using a karyometric device, and no statistical difference was found in this respect ( $p > 0.05$ ). The stereological values (mean) for epithelial thickness are shown in tables 1 and 2. Significant differences were found between group 1 and C1 with respect to the soft palate and gingival epithelium. For rats of group 2 and C2 there were no statistical

**Table 1**

Influence of Cd on epithelial thickness in hard and soft palate, and gingiva of rats exposed to CdCl<sub>2</sub> for 6 months (group 1) and the control (group C1)

Sites	Epithelial thickness (µm)		p values
	Group 2	Group C2	
<b>Hard palate</b>			
Keratin layer	15.06 ± 3.32 ns	12.32 ± 1.45	p = 0.061
Spinous layer	31.17 ± 4.99 ns	33.29 ± 5.83	p = 0.274
Basal layer	15.56 ± 1.69 ns	16.46 ± 2.86	p = 0.274
Total epithelium	61.80 ± 9.58 ns	62.09 ± 8.07	p = 0.345
<b>Soft palate</b>			
Keratin layer	8.43 ± 0.96 ns	10.81 ± 2.72	p = 0.111
Spinous layer	20.13 ± 2.80 ns	21.01 ± 3.40	p = 0.421
Basal layer	10.82 ± 2.51 ns	12.52 ± 0.83	p = 0.274
Total epithelium	39.39 ± 5.45 ns	44.29 ± 5.62	p = 0.210
<b>Gingiva</b>			
Keratin layer	10.24 ± 0.68 ns	10.63 ± 1.10	p = 0.274
Spinous layer	23.91 ± 3.90 ns	26.36 ± 3.94	p = 0.274
Basal layer	19.55 ± 2.27 ns	17.36 ± 2.01	p = 0.111
Total epithelium	52.56 ± 3.75 ns	52.35 ± 6.37	p = 0.500

Data are expressed as means ± SD  
 ns nonsignificant; p > 0.05 (Mann-Whitney test)  
 \* significant; p < 0.05 (Mann-Whitney test)



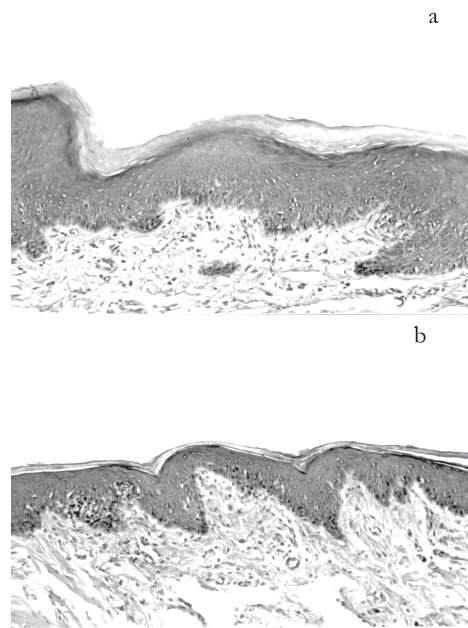
**Figure 1**  
 Photomicrograph of a section of the soft palate of control (a) and cadmium-treated rats for 6 months (b). Notice a decrease of the epithelial thickness, variation in the size and shape of nuclei in the epithelium of animals treated with Cd compared with controls. Hematoxylin and eosin stain (x400)

**Table 2**

Influence of Cd on epithelial thickness in hard and soft palate, and gingiva of rats exposed to CdCl<sub>2</sub> for 6 months and 6 months free of CdCl<sub>2</sub> (group 2) and the control (group C2)

Sites	Mitotic index* (n)					
	Group 1	Group C1	p values	Group 2	Group C2	p values
<b>Hard palate</b>	29.8 ± 2.83 ns	25.4 ± 2.57	p = 0.210	15.2 ± 1.27 ns	19.8 ± 1.52	p = 0.060
<b>Soft palate</b>	20.8 ± 2.54 ns	20.4 ± 2.13	p = 0.160	16.6 ± 2.25 ns	20.1 ± 1.77	p = 0.065
<b>Gingiva</b>	26.2 ± 2.47 ns	18.4 ± 1.26	p = 0.072	14.6 ± 1.36 ns	15.2 ± 1.64	p = 0.245

Data are expressed as means ± SD  
 ns nonsignificant; p > 0.05 (Mann-Whitney test)



**Figure 2**  
Photomicrograph of a section of the gingiva of control (a) and cadmium-treated rats for 6 months (b), showing a decrease of the epithelial thickness in the epithelium of animals treated with Cd compared with controls. Hematoxylin and eosin stain (x200)

**Table 3**  
Influence of Cd on the mitotic index (n) in the oral epithelium of rats exposed to CdCl<sub>2</sub> (groups 1 and 2) and their controls (groups C1 and C2)

Sites	Epithelial thickness (µm)		p values
	Group 1	Group C1	
<b>Hard palate</b>			
Keratin layer	17.14 ± 6.26 <sup>ns</sup>	17.57 ± 5.11	p = 0.421
Spinous layer	29.11 ± 7.39 <sup>ns</sup>	32.49 ± 4.32	p = 0.345
Basal layer	15.51 ± 2.23 <sup>ns</sup>	16.09 ± 0.90	p = 0.421
Total epithelium	56.00 ± 3.79 <sup>ns</sup>	64.37 ± 4.35	p = 0.080
<b>Soft palate</b>			
Keratin layer	7.54 ± 1.43*	10.37 ± 0.44	p = 0.004
Spinous layer	19.71 ± 4.06*	25.73 ± 4.89	p = 0.028
Basal layer	12.83 ± 1.82 <sup>ns</sup>	14.25 ± 1.60	p = 0.111
Total epithelium	40.09 ± 4.75*	50.35 ± 4.65	p = 0.016
<b>Gingiva</b>			
Keratin layer	9.30 ± 1.08 <sup>ns</sup>	9.20 ± 0.81	p = 0.500
Spinous layer	22.28 ± 3.73*	27.29 ± 3.34	p = 0.028
Basal layer	15.80 ± 2.50 <sup>ns</sup>	17.81 ± 1.49	p = 0.111
Total epithelium	45.89 ± 6.68*	54.00 ± 3.99	p = 0.048

Data are expressed as means ± SD  
\* mitotic index: number (n) of cells (of 1,000) showing arrested mitosis in the basal layer  
<sup>ns</sup> nonsignificant; p > 0.05 (Mann-Whitney test)

differences with respect to the epithelial thickness in any of the tissue sections studied.

**Mitotic index**

No statistical difference was found with respect to the mitotic index of the oral epithelium of the animals exposed to CdCl<sub>2</sub> in comparison to their respective controls. These data are demonstrated in table 3.

**Discussion**

In the present study the carcinogenic potential of Cd in the oral epithelium of rats was evaluated by morphologic and morphometric techniques. This investigation was carried out by experimental exposure of rats to CdCl<sub>2</sub> in drinking water (300mg/L). This concentration approaches the critical level for Cd toxicity, thus allowing for an investigation of its harmful action in the animal tissues<sup>15,16</sup>.

Our initial findings showed a decrease of body weight only in those animals exposed to Cd throughout the entire experimental period. In the animals of group 2, those that besides being exposed to Cd spent another equivalent period of time taking water free of Cd did not show a significant loss of body weight in comparison to their control group C2. This suggests that although Cd has a toxic effect on the corporal mass of the animals, this effect is likely to vary directly with the amount of Cd ingested and the time period of exposure. Other similar studies also described loss of weight in animals exposed to Cd.<sup>8,9,10</sup> The mechanism by which Cd reduces body weight has been ascribed to a direct toxic action of Cd in the tissues. It has been shown that exposure to Cd leads to alterations in the hormonal metabolism and reduces the absorption of essential metals to the organism, which may result in anemia and weight loss in exposed individuals.<sup>9,10,17,18</sup>

The changes in the tissues examined in this study were basically limited to a reduction of epithelial thickness by a decrease

in cell number in those animals continuously exposed to Cd, although other changes such as variation in the size and shape of nuclei, characterized by visual examination, were also verified in their oral epithelium sections. Another parameter evaluated for carcinogenic changes was the mitotic index. This index was not statistically different for the exposed animals as compared to that of the control group.

Mitogenic effects by Cd toxicity in epithelial tissues are not well known. Lansdown and Sampson<sup>20</sup> showed an increase of the mitotic index following topical application of Cd in high concentrations on the skin of rats and mice. In our study the Cd was administered orally, a route for which the absorption of Cd is very low, only about 5% is absorbed from the gastrointestinal tract<sup>19</sup>. Consequently, one

might expect a lower concentration of Cd in the peripheral tissues.

Our observations of weight loss and reduction of the epithelial thickness in the rats chronically exposed provides further evidence of a toxic action of Cd on the integrity of the organism and its epithelial structures. Despite the lack of evidence of carcinogenic effect of Cd under the concentration tested in this study, this does not assure that exposed to Cd in different environmental conditions would not present a risk of oral carcinogenesis.

## Acknowledgements

This study was supported by FAPESP (Fundação de Amparo à Pesquisa do Estado de São Paulo). Process number: 99/04803-1.

## Resumo

Cádmio (Cd) é um metal pesado que exerce uma variedade de efeitos tóxicos, crônicos e agudos, em organismos expostos. O objetivo deste estudo foi investigar o potencial carcinogênico do Cd no epitélio do palato e da gengiva de ratos Wistar. Dois grupos de animais foram estudados: grupo 1 que consistiu de 5 ratos expostos a cloreto de cádmio ( $\text{CdCl}_2$ ) em água de bebedouro (300 mg/L) por um período de 6 meses; grupo 2 que também consistiu de 5 ratos submetidos às mesmas condições dos animais do grupo 1, mas permaneceu livre de Cd por um período adicional de 6 meses. Dois outros grupos (C1 and C2) com o mesmo número de animais, entretanto não expostos ao  $\text{CdCl}_2$  foram usados como controle para o grupo 1 e 2, respectivamente. Todos os animais foram pesados antes e após o período experimental. Após terem sido sacrificados, os tecidos de interesse para o estudo foram fixados em formalina a 10%, processados por meio de técnica histopatológica padrão, corados em HE, e analisados sob microscopia de luz, utilizando parâmetros cariométricos e estereológicos. Perda de peso, atrofia do epitélio da gengiva e do palato mole foram os principais achados deste estudo, e verificados apenas no grupo 1 ( $p < 0.05$ ). Em conclusão, Cd não produziu efeito carcinogênico nos tecidos orais, nas condições experimentais empregadas neste estudo.

## Palavras chave:

Cloreto de cádmio.  
Cancer oral.  
Carcinogênese.  
Rato

## References

1. CHIN, T. A.; TEMPLETON, D. M. Effects of  $\text{CdCl}_2$  and Cd-Metallothionein on cultured mesangial cells. *Toxicology and Applied Pharmacology*, v. 116, p. 133-141, 1992.
2. PROZIALECK, W. C. Evidence that E-cadherin may be a target for cadmium toxicity in epithelial cells. *Toxicology and Applied Pharmacology*, v. 164, p. 231-249, 2000.
3. WAALKES, M. P.; ANVER, M.; DIWAN, B. A. Carcinogenic effects of cadmium in the Noble (NBL/Cr) rat: Induction of pituitary, testicular, and injection site tumors and intraepithelial proliferative lesions of the dorso lateral prostate. *Toxicological Sciences*, v.

- 52, p. 154-161, 1999.
4. ELINDER, C - G. Other toxic effects. In: FRIBERG, L.; ELINDER, C - G.; KJELSTRÖM, T.; NORDBERG, G. F. **Cadmium and health: a toxicological and epidemiological appraisal. Effects and response.** Florida: CRC Press, 1985. p. 159-204.
  5. MÜLLER, M. et al. Oral cadmium exposure of adults in Germany 1: cadmium content of foods tuffs and beverages. **Food Additives and Contaminants**, v. 13, p. 359-378, 1996.
  6. MÜLLER, M. et al. Oral cadmium exposure of adults in Germany 2: market basket calculations. **Food Additives and Contaminants**, v. 5, p. 135-141, 1998.
  7. INTERNATIONAL AGENCY FOR RESEARCH ON CANCER. **Monographs on the Evaluation of the Carcinogenic Risk of Chemicals to Humans**, v. 58, p. 119-237, 1993.
  8. BRAGA, A. S. et al. Efecto tóxico del íon cádmio sobre la glândula submandibular de rata adulta. **Revista Chilena de Anatomía**, v. 19, p. 183-190, 2001.
  9. LOPES, T. R. V. P. et al. Morphometric study of the effects of cadmium on the structure of the rat submandibular gland. **Investigação. Revista Científica da Universidade de Franca**, v. 1, p. 58-61, 1999.
  10. PINTO, D.M.G. et al. Ação do Cd na glândula submandibular de fetos de rata. Estudo estereológico. **Revista da Escola de Farmácia e Odontologia de Alfenas**, v. 20, p. 13-15, 1998.
  11. COLLINS, J. F.; BROWN, J. P.; PAINTER, P. R. et al. On the carcinogenicity of cadmium by the oral route. **Regulatory Toxicology and Pharmacology**, v.16, p.57-72, 1992.
  12. COLLINS, J. F. et al. On the oral carcinogenicity of cadmium. **Regulatory Toxicology and Pharmacology**, v. 23, p. 298-299, 1996.
  13. SALA, M. A. et al. Karyometric study of basal cell carcinoma. **Brazilian Dental Journal**, v. 5, p. 11-14, 1994.
  14. VALERI, V. et al. Relationship between cell nuclear volume and dioxyribonucleic acid of cell of normal epithelium, of carcinoma *in situ* and of carcinoma the uterine cervice. **Acta Cytologica**, v. 11, p. 488-496, 1967.
  15. BERNARD, A.; LAUWERYS, R. Cadmium in human population. **Experientia**, v. 40, p. 143-152, 1985.
  16. NOMIYAMA, K.; NOMIYAMA, H. Critical concentration of the "unbound" cadmium in the rabbit renal cortex. **Experientia**, v. 42, p. 149, 1982.
  17. KOBAYASHI, S.; KIMURA, M. Effects of orally administered cadmium on alkaline phosphatase isoenzymes in rat tissues. **Journal of Pharmacobiodyn**, v. 8, p. 853-863, 1985.
  18. ROBERTSON, A. et al. Effects of iron deficiency on metallothionein-I concentrations in blood and tissues of rats. **Journal of Nutrition**, v. 119, p. 439-445, 1989.
  19. LANSDOWN, A. B. G.; SAMPSON, B. Dermal toxicity and percutaneous absorption of cadmium in rats and mice. **Laboratory Animal Science**, v. 46, p. 549-554, 1996.
  20. WAALKES, M. P. Cadmium carcinogenesis in review. **Journal of Inorganic Biochemistry**, v. 79, p. 241-244, 2000.