

Use of fresh autogenous vaginal tunic in the experimental lamellar keratoplasty in dogs (*Canis familiaris*, Linnaeus, 1758)

Emprego da túnica vaginal autógena, a fresco, em ceratoplastia lamelar experimental em cães (*Canis familiaris*, Linnaeus, 1758)

Paula Diniz GALERA¹; José Luiz LAUS²; Affonso Luiz FERREIRA³

CORRESPONDENCE TO:
Paula Diniz Galera
Hospital Veterinário da Universidade de Cuiabá
Rua Itália, s/n – Jardim Europa
78015-480 – Cuiabá – MT
e-mail: pgalera@zaz.com.br

1-Departamento de Clínica e Cirurgia do Hospital Veterinário da UNIC, Cuiabá – MT
2-Departamento de Clínica e Cirurgia da Seção de Oftalmologia da Faculdade de Ciências Agrárias e Veterinárias da UNESP, Jaboticabal – SP
3- Departamento de Morfologia do Centro Universitário Barão de Mauá, Ribeirão Preto – SP

SUMMARY

Autogenous vaginal tunics have been researched in lamellar keratoplasty in dogs using fresh autogenous grafts in the repair of superficial keratectomies. Fourteen dogs have been used for the evaluation at the early, intermediary and late postoperative periods. Photophobia, blepharospasm, ocular discharge, edema, neovascularization and pigmentation have been observed. The results have showed that the original procedure is useful for the repair of corneas after superficial keratectomies.

UNITERMS: Cornea; Keratoplasty; Tunica vaginalis; Dogs.

INTRODUCTION

The cornea represents an important ocular barrier against foreign agents.

Among the diseases located in the cornea, the most common are corneal ulcers or ulcerative keratitis^{30,32}.

Ulcerative keratitis can be classified in a number of ways. One of the most common adopted classification is according to the lesion depth, i.e., superficial, deep stromal, and descemetocoele. As for the keratitis evolution, it can be classified as complication-free; progressive and refractory keratitis³². The most evident clinical signs are blepharospasm, photophobia, excessive lacrimation, edema, cellular infiltration, ocular discharge and vascularization are reactions that follow the corneal injury^{9,14}.

The corneal therapeutic includes clinical and surgical management, isolated or concomitant. Among the most frequently clinical procedures, there are antibiotics therapy, wetting agents, and the use of atropine and antiproteases^{10,12,20,29,30}. Surgical procedures are destined to serious cases, in which the agent remains or the symptoms may evolve³³.

There are many prescribed surgical procedures, such as grid or punctated keratotomy, contact lenses, a third eyelid flap, 180° or 360° conjunctival pedicle grafts, corneoscleral transposition, graft-free conjunctival, corneal transplants and

corneal grafts^{5,10,12,20,23,24,26,29,33}. Many studies are being carried out about keratoplasties and new techniques have been researched to find an ideal material.

Allotransplantations^{6,11,25} and autotransplantations have been investigated and compared, in which autotransplantations^{13,18,22} have showed better results.

Recent and promising studies on biological membranes have been targeted here in our environment. Equine pericardium preserved in glycerin has been used in the repair of the injured cornea of dogs³. Xenogenic amniotic membrane was used in the keratoplasties in dogs, with positive results⁴, as well as homologous peritoneum⁸.

Corneal-free autogenous grafting and pediculate graft of the conjunctiva have been compared both being feasible techniques^{16,19}.

Due to the search for new and effective procedures, the sardine scale has been used in the repair of superficial keratectomies in dogs¹⁵ and the renal equine capsule^{2,17} as well.

It is worthy the search for new materials, which should be closest to the ideal one, despite their extensive availability. In this way, the target was the use of autogenous vaginal membrane testes in the repair of lamellar keratectomy in dogs.

MATERIAL AND METHOD

Animals

Relating to the use of the animals in this research, they were treated according to the ARVO Resolution. Fourteen nondefined breed adult male dogs with normal eyes weighing about 10 kg were used. They have been furnished by the Kennel of the "Governador Laudo Natel Veterinary Hospital" and by the College of Agrarian Sciences and Veterinary College in the Jaboticabal campus of the "Universidade Estadual Paulista", UNESP (Paulista State University). Previously to the selection and separation into groups of two, the animals were clinically examined and ophthalmic evaluations included Schirmer Tear Test, fluorescein test, slit-lamp biomicroscopy, direct ophthalmoscopy and applanation tonometry. Later, were identified and kept in suitable kennels.

Experimental Groups

The dogs were divided into 7 groups of two animals each (G1, G2, G3, G4, G5, G6 and G7). The corneas were observed daily, until the 120th postoperative day. The testes of the groups 1, 2, 3, 4, 5, 6, and 7 were observed on the 1, 3, 7, 15, 30, 60 and 120 days of the postoperative periods, in which they were submitted to the bilateral orchidectomy and optical microscopy.

The corneas were evaluated daily until the 120th postoperative day.

Surgical Management

Food and water fasting had been previously enforced to the operative procedures for 12 hours. The animals received tiletamin/zolazepan^a (5 mg/kg) by intravenous route, and were maintained with halothane anesthesia^b and oxygen inhalation in closed circuit. Then we passed on to the routine procedures for the antisepsis and preparation of the surgical fields (ocular and pre-scrotal).

Approach to obtain the autogenous vaginal tunic

The scrotum has been cranially incised³¹, and the right testis exteriorized. The vaginal tunic has been incised and a fragment of 6 mm diameter was taken from it. This fragment was maintained in a saline solution.

The pre-scrotal region has received Wolf's suture with simple interrupted stitches using nylon 4-0^c. The vaginal tunic was not sutured. As postoperative procedures, the scrotal membrane was flushed daily with sterile saline solution at the rate of 0.9% aqueous dilution.

Keratoplasties

Keratoplasties have been performed with the help of surgical microscope and magnified 10 times. Blepharostase and fixation of the eyeball as well as

canthotomy have been performed when necessary. A superficial keratectomy was produced with a 5 mm-diameter trephine about half of the stroma. The lesion has been repaired with previously obtained autogenous vaginal tunic. The graft has been sutured in the defective cornea with simple interrupted pattern using 9-0-nylon. Ophthalmic ointment^d was used every 12 hours for 15 days after surgery and the animals received Elizabethan collar.

Evaluation procedures

Keratoplasties evaluation

The assessment of the animals occurred at intervals of 24 hours until the 120th day. Postoperative periods: G1 was observed on the first day, G2 until the third day, G3 until the 7th day, G4 until the 15th day, G5 until the 30th day, G6 until the 60th day, and G7 until the 120th day.

Subjective values of graduation have been checked (Nihil: absent, +: light; ++: moderate, +++: intense) and attributed only to those of macroscopic phenomena such as photophobia, blepharospasm, ocular discharge (present or absent during the period and classified according to its kind), edema, conjunctival hyperemia, chemosis, corneal pigmentation and corneal vascularization and the interurrences about the transparency.

Testes evaluation

The testes have been also clinically examined during the postoperative periods as to the scaring and interurrences close to the scrotum. Bilateral orchidectomy has been carried out at the end of each evaluation period (1, 3, 7, 15, 30, 60 and 120 days) and the testes, as being a control of its contralateral, submitted to the histopathology. So that, after their excision, they have been cleaned with sterile saline solution, immersed in a 0.9% buffered formalin and colored with haematoxylin-eosin.

RESULTS

Keratoplasties evaluation

The ophthalmic analysis has showed alterations normally observed in the keratoplasties. Ocular discomfort has been observed during the three postoperative days, and became more intense on the 7th day; it persisted until 15-20 postoperative days. After these steps, there was a regression and on the 60th postoperative day it has become less significative.

Photophobia and blepharospasm appeared light (+) on the first day and became more intense on the 3rd day after

^a Zoletil - Virbac.

^b Halothane - Hoechst.

^c Mononylon 4-0 Ethicon - S.A.

^d Epitezan - Frumtost.

the surgery. There was a gradual regression on the 15th day, and disappeared on the succeeding periods. Ocular discharge has been predominantly mucoserous and was observed in the first two postoperative weeks (++/+++), it has suffered a regression and it became absent on the 30th day after surgery.

As to the edema, it appeared on the 7th day (+) and became more intense at the end of the second week (+++). However, it has become less intense, in the latter period. The edema has always been limited to the surroundings of the graft, without interfering with the corneal transparency in distant areas.

Neovascularization has been observed in all the corneas. It began light (+) on the 7th postoperative day and became intense (+++) on the 15th day. On the 30th day after the surgery the neovascularization showed moderate (++) and became less intense (+) on the 60th and 120th day.

Conjunctiva hyperemia and chemosis have been showed in variable grades. They were light (+) on the first to the 15th day. Nevertheless, the animals that have received canthotomy, and also those that blepharostasis demanded more intensive manipulations, showed intense signs (+++) on the three first days of postoperative periods.

Pigmentation as intercurrent phenomenon with the corneal repairation has been displayed close to the graft's region and adjacencies. It was light on the 60th day and moderate on the 120th day. There are retention cists, common in these cases, on the 120th day, when decide to support the stitches. (Fig. 1).

Tests evaluation

Clinically, discreet local edema and hyperthermia were denoted on the first three postoperative days close to the scrotum. Macroscopically, after the orchidectomy, solid alterations have not been found. Taking into consideration the research in the light of optical microscopy, the testes have showed normal on the first three postoperative days, with active spermatogenesis. There has just been a discreet bilateral vascular congestion.

On the 15th day, there was spermatogenesis decrease with degenerated spermatogonia, interstitial edema and interstitial cells with a degenerated nucleus on those testes from where fragments of the vaginal tunic have been excised. In the contralateral, a similar phenomenon has been identified, nevertheless in an expressively less emphasized degree. However, in the fourth month, the spermatogenesis had already been evident in both testes, which have not presented trouble due to the surgical trauma, which they had undergone (Fig. 2 and 3).

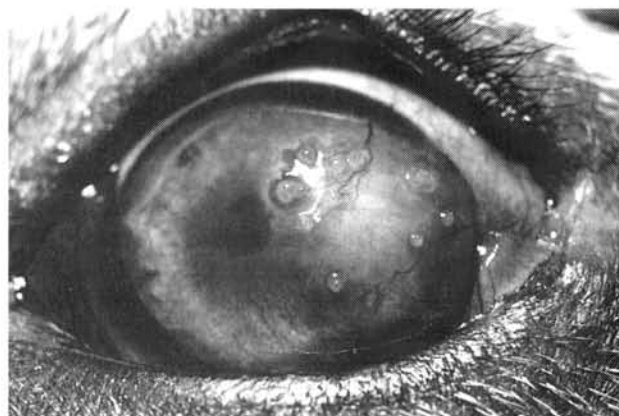


Figure 1

Lamellar keratoplasty in dogs using fresh autogenous vaginal tunic, on the 120th postoperative day. Discreet opacity, pigmentation in the grafting area, as well retention cists are present.

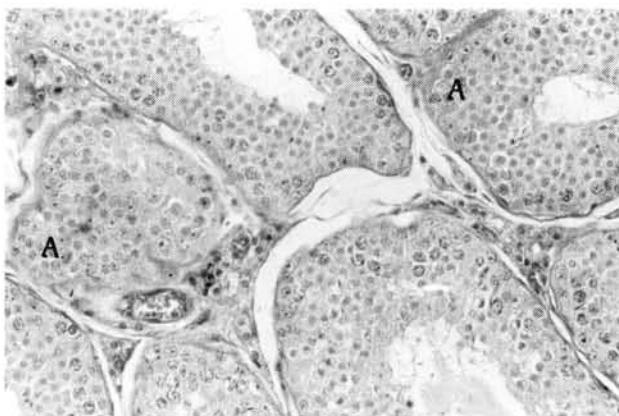


Figure 2

Photomicrographic image showing seminiferous tubules regeneration (A) returning to spermatogenesis (B), on operated testis on the 120th postoperative day (H.E. 440X).

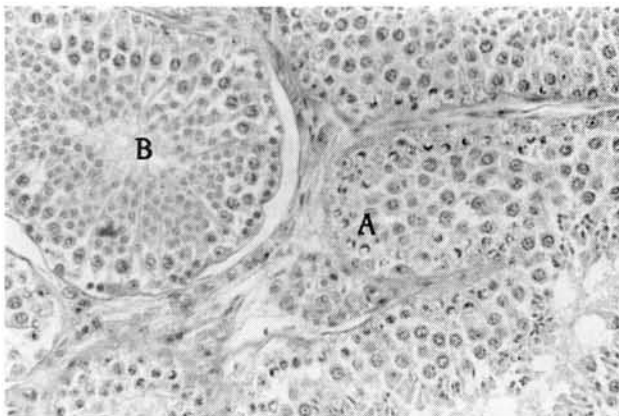


Figure 3

Photomicrographic image showing seminiferous tubules regeneration (A), on testis control on the 120th postoperative day (H.E. 440X)

DISCUSSION

Preceding works accomplished by our team have confirmed that as to keratoplasties, macroscopic technique allows us to accompany and check safely the evolution of the postoperative periods^{2,16,19}. Noteworthy is the humanitarian treatment given to the animals' eyes when enucleating is an unnecessary conduct. As for the collected results, the principal agent for the ocular discomfort is the surgical trauma that was observed during the beginning of the postoperative periods. Chemosis appeared in the first week and was always associated with those animals which canthotomy was necessary. There has been individual variation as to the intensity and duration of the temporal and kinetic phenomena, as to the conjunctiva hyperemia it has followed the course of the preceding signs. Ocular secretion has been manifested predominantly in mucous form and intensified at the intervals of three to seven days. Corneal edema has been present in the circumjacency areas of the grafting, but not interfering significantly with the sight. It appeared in a discreet way during the 7 first days and became intense on the 15th day, tending to regression at the late phases. By means of the use of xenogenic amniotic membrane in penetrating keratoplasties, corneal opacification in the circumjacency areas of the grafting was observed 24 hours during the postoperative with significant attenuation on the 7th day⁴.

Pigmentation deposition, surrounding the areas where keratoplasties have been performed, was observed between the 60th and the 120th days in some of the animals. Some authors have reported to the occurring pigmentation in the process of the corneal reparations^{8,27,29}. The scar, which inexorably is distinct as a final keratoplasties result^{2,3,16,21,22,29} has occurred indistinctly among the animals despite of the relative individual variations of the cicatricial dimensions macula²⁹. The corneal transparency, which in the final context is always the main sought objective in order to keep the animals able to see, has been present in the remaining areas of the cornea.

As for the testes lesions and their consequences in the face of the vaginal tunic, the edema must be taken into consideration, mainly during the first three days, which has happened due to the surgical management.

There have not been evidences of any kind of secretion close to the scrotal wounds. Morphologically, expressive alterations had not been found during the period right after

the surgery, besides discreet bilateral congestion due to the surgical trauma. The appearance of degenerated spermatogonia, interstitial edema and interstitial cells with degenerated nucleus was observed on the 15th postoperative day in the testes which have undergone surgery due to the inflammatory process of the remaining vaginal tunic. Traumatic and focal process comprise such features¹. In such process, the affected testes have displayed normality and smoothness as to their consistency, but not necessarily presenting size alteration⁷. Similar but discreet phenomena have occurred in the contralateral testes used as a control. The repercussion to a testis, when the contralateral is injured, is called Sympathic Orchiothy²⁸.

Focal tubular degeneration, accompanied with normal tubules areas, occurred on the 30th day, on both testes. However, testicular degeneration and infertility due to it were transient when their cause was temporary²⁸. There was seminiferous tubules regeneration with spermatogonia in two months after the surgery and genesis has occurred on both testes, noteworthy, it happened in the 4th postoperative month.

CONCLUSION

According to the results of the research we have concluded that:

1. The autogenous fresh vaginal tunic is an effective and low-cost grafting for lamellar keratoplasties in dogs;
2. The corneas which have received them evolved according to the macroscopy within the classical patterns of the cicatricial repair with few scar sequelae;
3. Autografting through the fresh vaginal tunic, progressively during the cicatricial process, causes transparent corneas, but with occasional macula and pigmentation close to the grafting areas;
4. The fragment of the autogenous vaginal tunic gathering has reflected into transient testicular degeneration, with posterior regeneration.

ACKNOWLEDGEMENTS

The authors are thankful to "Fundação de Amparo à Pesquisa do Estado de São Paulo" (FAPESP), to "Ethicon S.A." and to Fort Dodge.

RESUMO

Empregou-se a túnica vaginal autógena, a fresco, na ceratoplastia lamelar em cães. Foram utilizados 14 cães, a serem avaliados nos períodos iniciais, intermediários e tardios. Fotofobia, blefarospasmo, descarga ocular, edema, neovascularização e pigmentação corneanas foram observados. Os resultados mostraram ser a técnica factível de utilização na reparação corneana após ceratectomias superficiais.

UNITERMOS: Córnea; Ceratoplastia; Túnica vaginal; Cães.

REFERENCES

- 1- ACLAND, H.M. Sistema reprodutor do macho. In: CARLTON, W.W.; Mc GAVIN, M.D. **Patologia veterinária especial de Thomson**. 2.ed. Porto Alegre : Artmed, 1998. Cap. 13, p.582-3.
- 2- ANDRADE, A.L. *et al.* The use of preserved equine renal capsule to repair lamellar corneal lesions in normal dogs. **Veterinary Ophthalmology**, v.2, p.79-82, 1999.
- 3- BARROS, P.S.M. *et al.* Reparação cirúrgica da córnea de cães usando pericárdio de equino conservado em glicerina. In: CONGRESSO BRASILEIRO DA ANCLIVEPA, 13., 1990, Gramado. **Resumos...** Gramado : ANCLIVEPA, 1990. p.11.
- 4- BARROS, P.S.M. *et al.* Preserved equine amniotic membrane used in the repair of the cornea of the dog. **Investigative Ophthalmology & Visual Science**, v.36, n.4, p.S982, 1995.
- 5- BARROS, P.S.M. *et al.* The use of xenologous amniotic membrane to repair canine corneal perforation created by penetrating keratotomy. **Veterinary Ophthalmology**, v.1, n.2-3, p.119-23, 1998.
- 6- BERNIS, W.O. Further trials with partial penetrating keratoplasty in dogs. **Southwestern Veterinarian**, v.15, n.1, p.30-44, 1961.
- 7- FELDMAN, E.C.; NELSON, R.W. **Disorders of testes and epididymides**. Philadelphia: W.B. Saunders, 1996. Cap. 27, p.708-9.
- 8- GARCIA, J.A. *et al.* Implante de peritônio homólogo conservado após ceratectomia lamelar em cães. **Brazilian Journal Veterinary Research and Animal Science**, v.33, p.290-4, 1996. Suplemento.
- 9- GONÇALVES, C.P. **Oftalmologia**. 4.ed. Brasília: Atheneu, 1975. p.131-40: Queratites.
- 10- HELPER, L.C. **Magrane's canine ophthalmology**. 4.ed. Philadelphia: Lea & Febiger, 1989. p.102-49: Diseases and surgery of the cornea and sclera.
- 11- JENSEN, E.C. Experimental corneal transplantation in the dog. **Journal American Veterinary Medical Association**, v.142, n.1, p.11-22, 1963.
- 12- KERN, T.J. Ulcerative keratitis. **Veterinary Clinics of North American Small Animal Practice**, v.20, n.3, p.643-66, 1990.
- 13- KHODADOUST, A.A.; SILVERSTEIN, A.M. Transplantation and rejection of individual cell layers of the cornea. **Investigative Ophthalmology**, v.8, p.180-95, 1969.
- 14- LAFORGE, H. Pathologie de la cornée chez le carnivores domestiques. **Recueil de Médecine Veterinaire**, v.165, n.3, p.247-56, 1989.
- 15- LAUS, J.L. **Emprego da escama de sardinha (*Sardinella brasiliensis* - Steidachner, 1859), conservada em glicerina, como sucedâneo de córneas no reparo de ceratectomias superficiais: Estudo experimental em cães. (*Canis familiaris* - Linnaeus, 1758). Jaboaticabal, 1994. 71p. Tese (Livro Docência em Medicina Veterinária) – Faculdade de Ciências Agrárias e Veterinárias, Universidade Estadual Paulista.**
- 16- LAUS, J.L. *et al.* Comparação entre ceratoplastias lamelares por enxertos autógenos, livres, de córnea e pediculados de conjuntiva. Estudo experimental no cão (*Canis familiaris* - Linnaeus, 1758). **Brazilian Journal Veterinary Research and Animal Science**, v.33, n.1, p.41-6, 1996.
- 17- LAUS, J.L. *et al.* Bilateral lamellar keratoplasty in descemetocele treatment in dog with botulism by use of equine renal capsule and conjunctival pedicle graft. **Ciência Rural**, v.29, n.2, p.355-9, 1999.
- 18- MEDEIROS, O.T. **Estudo biomicroscópico e imunológico da ceratoplastia experimental em coelhos, com córneas autólogas e homólogas frescas conservadas em câmara úmida**. Belo Horizonte, 1973 156p. Tese (Doutorado) – Universidade Federal de Minas Gerais.
- 19- MORALES, A. *et al.* Comparação entre enxertos autógenos livres e pediculados de conjuntiva no reparo de ceratectomias superficiais. Estudo experimental no cão (*Canis familiaris* - Linnaeus, 1758). **Brazilian Journal of Veterinary Research and Animal Science**, v.33, n.1, p.28-31, 1996.
- 20- NASISSE, M.P. Canine ulcerative keratitis. **Compendium Continuing Education**, v.7, n.9, p.686-701, 1985.
- 21- PANCHBAI, V.S.; KULKARNI, P.E. Lamellar corneal transplantation in buffalo calves (*Bubalus bubalis*) -I. (Autogenous and Homogenous Grafts). **Indian Veterinary Journal**, v.63, p.737-40, 1986.
- 22- PANCHBAI, V.S.; KULKARNI, P.E. Penetrating corneal transplantation in Buffalo calves – III. (Autogenous and Homogenous Grafts). **Indian Veterinary Journal**, v.64, p.223-6, 1987.
- 23- PARSHALL, C.J. Lamellar corneal – scleral transposition. **Journal of American Animal Hospital Association**, v.9, p.270-7, 1973.
- 24- PEIFFER, Jr. *et al.* Surgery of the canine and feline orbit, adnexa and globe. Part 6: Surgery of the cornea. **Companion Animal Practice**, v.1, n.7, p.3-13, 1987.
- 25- POLACK, F.M. Histopathological and histochemical alterations in the early stages of corneal graft rejection. **Journal of Experimental Medicine**, v.116, p.709-17, 1962.
- 26- POWEL, N.G. Cirurgia da córnea. In: BOJRAB, M.J. **Cirurgia dos pequenos animais**. 2.ed. São Paulo : Roca, 1986. p.66-71.
- 27- SCAGLIOTTI, R.H. Tarsconjunctival island graft for the treatment of deep corneal ulcers, descemetoceles, and perforations in 35 dogs and 6 cats. **Seminars in Veterinary Medicine and Surgery (Small Animal)**, v.3, n.1, p.69-76, 1988.
- 28- SHAUL, D.B. *et al.* Surgical treatment of testicular trauma: effects on fertility and testicular histology. **Journal of Pediatric Surgery**, v.32, n.1, p.84-7, 1997.
- 29- SLATTER, D. Cornea and sclera. **Fundamentals of veterinary ophthalmology**. 2. ed. Philadelphia: W.B. Saunders, 1990. p.257-303.
- 30- STARTUP, F.C. Corneal ulceration in the dog. **Journal of Small Animal Practice**, v.25, p.737-52, 1984.
- 31- VAN SLUIJS, F.J. Orquidectomia no cão. **Atlas de cirurgia de pequenos animais**. São Paulo : Manole, 1993. p.108-9.
- 32- VAUGHAN, D.; ASBURY, T. Córnea e esclerótica. **Oftalmologia geral**. São Paulo : Universidade de São Paulo, 1977. p.71-87.
- 33- WHITLEY, R.D. Canine cornea. In: GELATT, K.N. **Veterinary ophthalmology**. 2. ed. Philadelphia: Lea & Febiger, 1991. p.307-56.

Received 02/05/2000
Accepted: 10/01/2001