



Graduate Medical Education Research Journal

Volume 1 | Issue 1

Article 11

December 2019

Sarcoidosis of the Mandibular Condyle: A Rare Disease That Can Mimic Malignancy

Chad Sloan

University of Nebraska Medical Center

Ben LaCrosse

University of Nebraska Medical Center

Lei Yu

University of Nebraska Medical Center

Alexander Braun

University of Nebraska Medical Center

Scott Lauer

University of Nebraska Medical Center

See next page for additional authors

Follow this and additional works at: <https://digitalcommons.unmc.edu/gmerj>



Part of the [Higher Education Commons](#), [Oral and Maxillofacial Surgery Commons](#), [Pathology Commons](#), [Radiology Commons](#), and the [Surgery Commons](#)

Recommended Citation

Sloan, C., LaCrosse, B., Yu, L., Braun, A., Lauer, S., Donovan, T., Baker, J., , Untrauer, J. Sarcoidosis of the Mandibular Condyle: A Rare Disease That Can Mimic Malignancy. Graduate Medical Education Research Journal. 2019 Dec 13; 1(1).

<https://digitalcommons.unmc.edu/gmerj/vol1/iss1/11>

This Case Report is brought to you for free and open access by DigitalCommons@UNMC. It has been accepted for inclusion in Graduate Medical Education Research Journal by an authorized editor of DigitalCommons@UNMC. For more information, please contact digitalcommons@unmc.edu.

Sarcoidosis of the Mandibular Condyle: A Rare Disease That Can Mimic Malignancy

Abstract

Sarcoidosis can involve any of the organs, however intraosseous involvement is rare and ranges from 5 to 15%, with lesions of the mandible being even rarer – currently with few known cases reported. Intraosseous lesions involving the mandible have been noted to be asymptomatic or associated with chronic jaw pain. Additionally, mandibular involvement can present as a lytic bone lesion mimicking osseous malignancy. Chronic polyarthritis is commonly associated with the progression of sarcoidosis and intraosseous involvement has been considered a late-stage sequelae. We report a case of biopsy-proven sarcoidosis within the mandibular condyle in an asymptomatic 56-year-old Caucasian female who had no preceding polyarthritis or symptomatic progression of disease, discuss the imaging features, and report management.

Keywords

Intraosseous sarcoidosis, lytic mandibular condyle lesion

Creative Commons License



This work is licensed under a [Creative Commons Attribution-Noncommercial-No Derivative Works 4.0 License](https://creativecommons.org/licenses/by-nc-nd/4.0/).

Authors

Chad Sloan, Ben LaCrosse, Lei Yu, Alexander Braun, Scott Lauer, Timothy Donovan, John Baker, and Jason Untrauer

Sarcoidosis of the Mandibular Condyle: A Rare Disease That Can Mimic Malignancy

Chad Sloan^{1*}, Ben LaCrosse^{2*}, Lei Yu², Alexander Braun³, Scott Lauer³, Timothy Donovan², John Baker³, Jason Untrauer¹

*Co-first authors

¹University of Nebraska Medical Center, Department of Surgery, ²University of Nebraska Medical Center, Department of Radiology

³University of Nebraska Medical Center, Department of Pathology and Microbiology

<https://doi.org/10.32873/unmc.dc.gmerj.1.1.011>

Abstract

Sarcoidosis can involve any of the organs, however intraosseous involvement is rare and ranges from 5 to 15%, with lesions of the mandible being even rarer – currently with few known cases reported. Intraosseous lesions involving the mandible have been noted to be asymptomatic or associated with chronic jaw pain. Additionally, mandibular involvement can present as a lytic bone lesion mimicking osseous malignancy. Chronic polyarthritis is commonly associated with the progression of sarcoidosis and intraosseous involvement has been considered a late-stage sequelae. We report a case of biopsy-proven sarcoidosis within the mandibular condyle in an asymptomatic 56-year-old Caucasian female who had no preceding polyarthritis or symptomatic progression of disease, discuss the imaging features, and report management.

Introduction

Sarcoidosis is a common systemic inflammatory granulomatous disease with multi-organ involvement. Sarcoidosis has been described for over 100 years, however the exact etiology remains unknown. It can be found in any race and age, with predilection for African American and female patients.¹ Sarcoidosis is a diagnosis of exclusion and often based on clinical, radiologic and histologic findings. Sarcoidosis most commonly involves the lungs, lymph nodes and skin, but can have manifestations in any of the organs. Osseous sarcoidosis is rare, reported in 5-10% of all the sarcoidoses.²⁻³ It is usually found in short bones like phalanges of the hands and feet. Patients are usually asymptomatic, but can present with bone pain or chronic polyarthritis.¹ Bony involvement is often noted incidentally on imaging studies acquired for other unrelated complaints. Mandibular condyle sarcoidosis is an even rarer entity, with, to our knowledge, only a countable number of reported cases in the English literature.⁴ Here, we report a case of incidentally diagnosed mandibular condylar sarcoidosis in an asymptomatic patient. We obtained consent to use this case for educational purposes.

Case

A 56-year-old Caucasian female initially presented to our emergency department (ED) for right upper quadrant pain and chest tightness in December 2017. A past medical history was significant for Type 1 diabetes mellitus, gastroesophageal reflux disease, hypothyroidism, chronic headaches, cervical cancer, and a 12 pack-year smoking history. The patient was admitted to the hospital for full cardiac work-up including laboratory evaluation, an echocardiogram, and a stress echocardiogram that were all negative. Computed tomography (CT) angiogram of the chest was also obtained, which demonstrated mediastinal and bilateral hilar lymphadenopathy (Figure 1). While these findings could represent granulomatous or infectious process, malignancy was not excluded. Referral to outpatient pulmonology was made and the patient underwent transbronchial needle aspiration of the mediastinal lymph nodes. The cytopathology results revealed non-caseating granulomas consistent with granulomatous lymphadenitis. Gomori Methanamine-Silver stains were negative for fungal and acid-fast Bacillus. These findings were compatible with sarcoidosis (Figure 2). The patient also had a history of a known lesion within the right mandibular condyle that was followed by a neurosurgeon, utilizing magnetic resonance imaging (MRI) and CT. A review of the outside imaging records indicated indeterminate trabecular erosion of the right condylar head, with slight progressive expansion over a period of three years, indeterminate for benign neoplasm,

inflammatory process, or idiopathic joint erosion. The patient was referred to the oral and maxillofacial Surgery (OMFS) team for further evaluation.

The patient was seen in the OMFS clinic with a physical exam that did not reveal any palpable or visual facial asymmetry. The patient had appropriate maximal incisal opening and lateral mandibular excursions. There was no expansion of bone or soft-tissue noted at the right TMJ. In addition, there was no tenderness to palpation, clicking, crepitus, or locking upon open/close maneuvers. However, on the contralateral side, there was noted tenderness of the left temporalis with discomfort of the left TMJ upon open/close maneuvers; although there was no clinically appreciated clicking, crepitus, or locking. All other aspects of the head and neck exam were unremarkable. Repeat CT study showed lytic lesion of enlarged right mandibular condyle (Figure 3). Given the clinical and radiographic assessments, along with the recently diagnosed pulmonary sarcoidosis, a CT-guided biopsy was recommended and completed by interventional radiology (Figure 4). Pathology results revealed negative Fite and Gomori methanamine-silver stains for both acid fast and fungal organisms, respectively. Histopathology indicated non-caseating epithelioid granulomas consistent with sarcoidosis of the right mandibular condyle (Figure 5). The patient continues to be followed for manifestations of sarcoidosis, with no further locoregional treatment of the mandibular lesion currently indicated, given its asymptomatic nature.

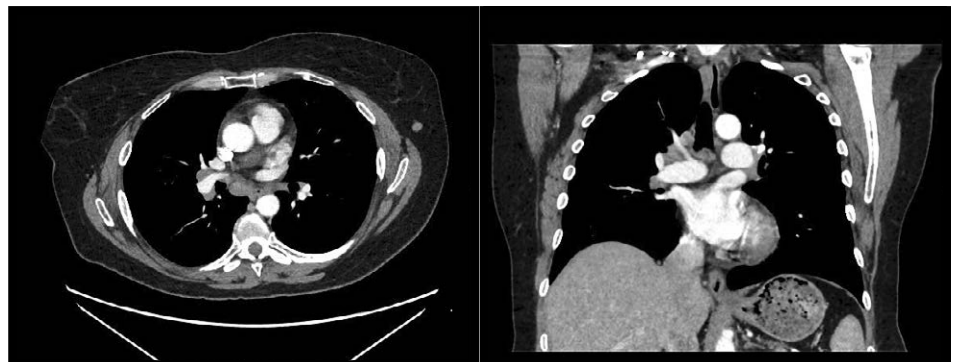

Figure 1. Axial and coronal contrast enhanced CT images of the chest show enlarged mediastinal and bilateral hilar lymph nodes. These are the most common radiographic findings of sarcoidosis.

Discussion

Osseous sarcoidosis generally involves small bones in the hands and feet.^{1,2} Infrequently, large bones may also be affected. Small bone sarcoidosis has a typical lace-like lytic appearance with cortical preservation on radiography. The lesions are often incidental and bilateral.² The radiographic finding is pathognomonic in a patient with a confirmed diagnosis of sarcoidosis.^{2,3} Large bone sarcoidosis is often occult on radiographs although it can present as a lytic or sclerotic

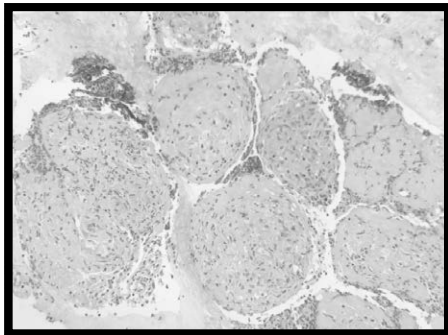


Figure 2. Biopsy specimen of mediastinal and hilar lymph nodes showing non-caseating granuloma, captured at 200x magnification on H&E stain.

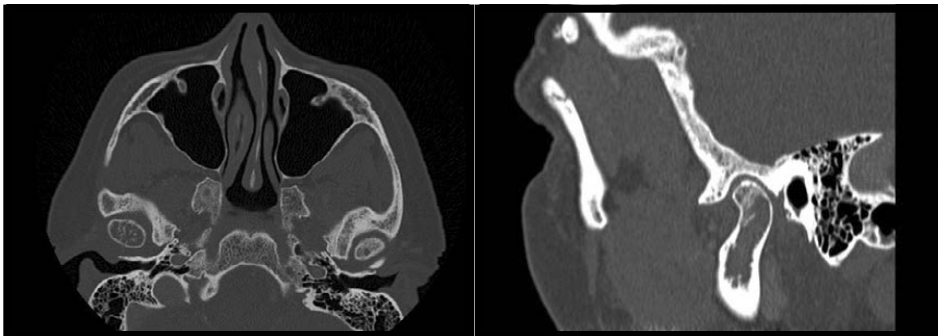


Figure 3. Sagittal and axial maxillofacial CT demonstrated lytic appearance of enlarged right mandibular condyle with increased trabeculation. No significant bony erosion, right temporomandibular joint space is preserved.

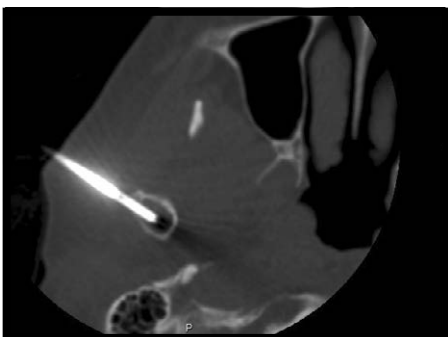


Figure 4. CT guided biopsy of right mandibular condyle lesion with a 13 gauge needle.

lesion, or both. Due to the nonspecific radiographic appearance in large bones, it is difficult to differentiate osseous sarcoidosis from other diseases including osseous metastases or myeloma.^{5,6} Benign entities such as a hemangioma could also be considered if the osseous trabeculation is somewhat preserved. Magnetic resonance imaging (MRI) can detect lesions that are otherwise occult on radiographs. The lesions usually have low signal on T1 weighted images, increased or isointense signal on T2 weighted images, and the lesions enhance upon contrast administration.⁶ These MRI features are nonspecific, though if preserved marrow fat is present within the lesion this may help differentiate a benign from malignant lesion.^{5,6}

There are fewer than 25 reported cases of sarcoidosis affecting the jaw bones and furthermore even less involving the mandibular condyle.⁴ When involving the jaw, it most frequently involves the anterior maxilla and posterior mandible with the most common clinical presentation being abnormal tooth mobility or aggressive periodontitis.⁴ Despite the patient in our case being asymptomatic at the right temporomandibular joint space, there have been reports of TMJ

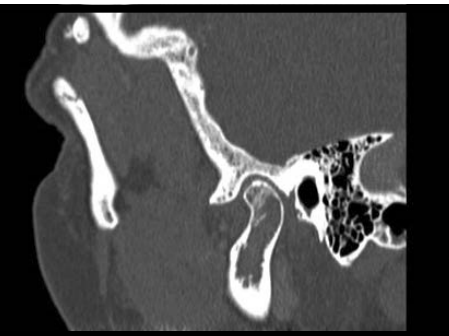


Figure 5. Non-caseating granuloma with lamellar bone of the mandible, captured at 200x magnification on H&E stain.

pain when sarcoidosis has been found to involve the mandibular condyle.^{4,7,8}

It is important to differentiate osseous sarcoidosis from malignant bone lesions as the management is notably different. Asymptomatic osseous sarcoidosis usually does not require treatment. Medical treatment is reserved for symptomatic patients and combined with the treatment for systemic sarcoidosis.^{1,3,4}

Conclusion

Mandibular condyle sarcoidosis is extremely rare and can present as an expansile intraosseous lytic lesion that can be questionable for malignancy with or without clinical symptoms. Clinicians should consider sarcoidosis in the differential diagnosis for a lytic mandibular lesion in patients with systemic sarcoidosis. ■

References

- 1 Hunninghake GW, et al. "ATS/ERS/WASOG statement on sarcoidosis. American thoracic society/ European respiratory society/world association of sarcoidosis and other granulomatous disorders". *Sarcoidosis, vasculitis, and diffuse lung diseases: official journal of WASOG*, 16.2 (1999): 149.
- 2 Koyama, Takashi, et al. "Radiologic manifestations of sarcoidosis in various organs". *Radiographics*, 24.1 (2004): 87-104.
- 3 Nessrine, Akasbi, Abourazzak Fatima Zahra, and Harzy Taoufik. "Musculoskeletal involvement in sarcoidosis". *Jornal Brasileiro de Pneumologia*, 40.2 (2014): 175-182.
- 4 Suresh, Lakshmanan, et al. "Intraosseous sarcoidosis of the jaws mimicking aggressive periodontitis: a case report and literature review". *Journal of periodontology*, 75.3 (2004): 478-482.
- 5 Dunfee BL, et al. "Radiologic And Pathologic Characteristics Of Benign And Malignant Lesions Of The Mandible". *Radiographics*, 26.6 (2006): 1751-1768.
- 6 Moore, Sandra L, Alvin E Teirstein. "Musculoskeletal sarcoidosis: spectrum of appearances at MR imaging". *Radiographics*, 23.6 (2003): 1389-1399.
- 7 Thomas R. Thomas et al. "Sarcoidosis with involvement of the mandibular condyle". *Journal of Oral Surgery*, 34.11 (1976): 1026-1030.
- 8 Fain, Emily T, et al. "Temporomandibular Joint Arthritis in Pediatric Sjogren Disease and Sarcoidosis". *Journal of Rheumatology*, 38.10 (2011): 2272-2273.