

5-1-1938

## Toxic adenoma of the thyroid : pathology and physiology

Richard C. Porter  
*University of Nebraska Medical Center*

This manuscript is historical in nature and may not reflect current medical research and practice. Search [PubMed](#) for current research.

Follow this and additional works at: <https://digitalcommons.unmc.edu/mdtheses>



Part of the [Medical Education Commons](#)

---

### Recommended Citation

Porter, Richard C., "Toxic adenoma of the thyroid : pathology and physiology" (1938). *MD Theses*. 692.  
<https://digitalcommons.unmc.edu/mdtheses/692>

This Thesis is brought to you for free and open access by the Special Collections at DigitalCommons@UNMC. It has been accepted for inclusion in MD Theses by an authorized administrator of DigitalCommons@UNMC. For more information, please contact [digitalcommons@unmc.edu](mailto:digitalcommons@unmc.edu).

**TOXIC ADENOMA OF THE THYROID**

**PATHOLOGY**

**PHYSIOLOGY**

**RICHARD C. PORTER**

**PRESENTED**

**TO**

**THE COLLEGE OF MEDICINE**

**UNIVERSITY OF NEBRASKA**

**OMAHA**

**1938**

## INTRODUCTION

The thyroid gland has been observed and studied since the time of Hippocrates, with constant additions to the knowledge of anatomy, physiology and pathology. In the last few years the subject has emerged from the realm of supposition and taken the form of a series of distinct problems studied in a scientific manner.

This paper has been written, not in an attempt to further the knowledge concerning toxic adenoma by additional experimentation, but rather by the coordination of the existing facts.

480969

## CONTENTS

History of the Thyroid Gland.....	1
Etiology of Nodular Goiter.....	5
Normal Structure of the Thyroid Gland.....	8
Pathology of Nodular Goiter.....	15
Physiology of the Thyroid Gland.....	30
Thyroid Pituitary Relationship.....	32
Thyroid Gonads.....	34
Thyroid Pancreas Relationship.....	35
Thyroid Chromaffin Relationship.....	36
Physiology of Symptoms.....	37
Cardiovascular Symptoms.....	38
The Basal Metabolic Rate.....	44
Gastro-Intestinal Manifestation.....	48
Nervous and Mental Symptoms.....	51
Bibliography.....	55

## History of the Thyroid Gland

Knowledge of the thyroid gland begins with Hippocrates, who while mentioning the tumors of the neck, did not recognize them as thyroid growths, but describes them as a deformity of the body which may undergo changes and produce a thick, heavy material.(1) While Hippocrates made no distinction between the various tumors of the neck, but considered them all the same type of growth, it remained for Celsus, who lived in the same period, to differentiate them.

Celsus recognized the tumors of the thyroid as separate and distinct from the abscesses and gave to them the name of "Bronchocele".(1) Later Aetius, in his description of the Bronchocele, called it a fleshy tumor which arises in the throat from the cortex of the larynx. Leonicensus has a more bizarre explanation of the tumor and went so far as to claim it was caused by phlegm, the phlegm being combined with black bile, which mass caused induration by its dryness.(2)

The first man to have a faint glimmer of the cause of the condition was Arnoldus de Villanova(1230-1313), who while admitting he did not know the cause, stated

that diet played a primary role. Baccius(1571), believing the cause of the disease to be the water supply rather than the diet, gave in support of his theory a description of the people of Salzburg whose source of water supply was a mountain stream and who were all "strumous".

The purpose of the thyroid gland was unknown and unthought of until the time of Eustachius, who claimed that it was for the purpose of lubrication of the larynx and the voice box.(1)

Wharton(1610-1673) was the first to describe the gland correctly and give it the title "thyroid", derived from the Greek word meaning shield.(3) From the time of Wharton to Crewelhin, who lived in 1840, very little progress was made in the anatomical studies of the gland. Crewelhin, after completing a series of dissections, found that there was no duct to the gland, which discovery led to the beginning of the investigation of the true nature of the thyroid.(2)

During the later part of the eighteenth century, attention was again turned to the function of the gland. Forestrius, in 1845, described exophthalmus but thought

it was due to straining at childbirth.(1) It remained for Guiseppe Flagini in 1788 to realize that there was a connection between exophthalmus, palpitation and goiter.(1) Basedow, in 1799, gave a clearer account of the condition and laid the blame to tuberculosis rather than thyroid disease.(3) Caleb Parry, in 1815, writing on the same condition, was the first to publish an accurate account of the symptoms.(4) Twenty years later Robert Graves, in a monograph on exophthalmus, attempted to explain the disease and in doing so gave us one of the most complete and logical accounts of the condition that has been written.(5)

The next important step in the studies of the thyroid gland was William Gull's observation on myxedema, which was confirmed by Theodore Kocher in 1883 in his paper on the effect of the removal of the thyroid gland, and again in 1891 by Murray who was able to demonstrate the curative effects of glycerine extract of sheep's thyroid when given to a patient with myxedema.(6)

Bawman, in 1895, showed that iodine in firm, organic combination was a constituent of normal thyroid tissue. It remained for Kendall, in 1916, to isolate a substance

which had the same action as dessicated thyroid. This finding stimulated experimentation on the action of the hormone and resulted in the confirmation of Magnus Levy's work on the regulation of body heat by the thyroid gland.(6)

Since that time much work has been done on the mechanism by which the thyroid gland controls metabolism, but as yet little has been accomplished. However, with our present conception of the interrelations of the thyroid gland with the rest of the endocrine system, it is to be hoped that a conclusion will soon be reached.



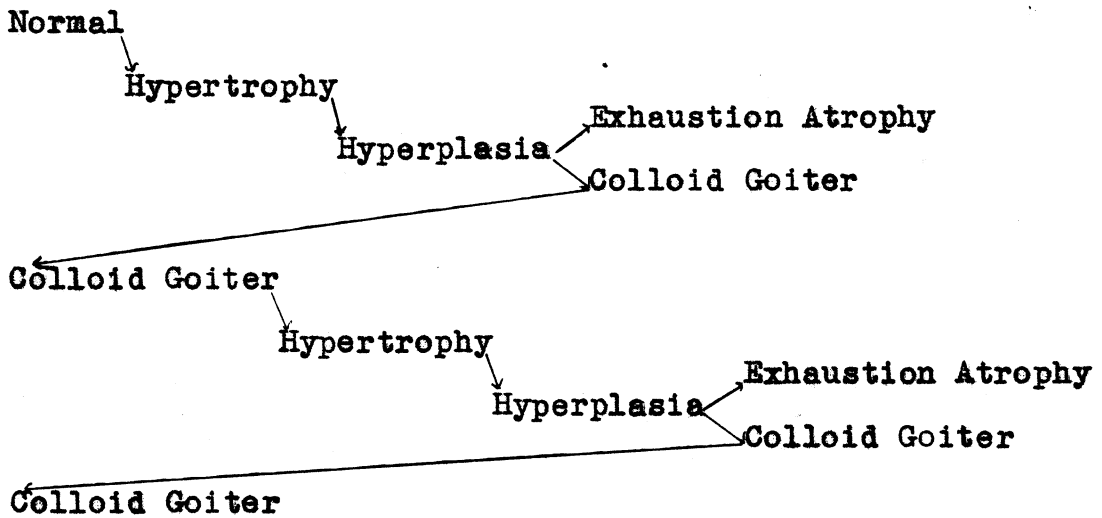
## Etiology of Nodular Goiter

Wolfler, in 1880, started a controversy which has been settled only recently when he stated that nodular goiter was derived directly from fetal rests.(7) Virchow was the first man to dispute the theory of Wolfler, and he had, at the time, even less proof than Wolfler. However, his statement that fetal adenoma, or nodular goiter, was nothing more than a different stage of colloidal goiter, met with considerable ridicule and was not considered as being very probable.(8) However, in recent years with the advent of the modern laboratories, considerable work has been done on this problem with a good many theories resulting.

Goetsch, in 1920, published a paper in which he states that not only are the nodular thyroids the results of growth from fetal rests but also the diffuse adenomatosis seen in thyroids is caused by the growth of these fetal rest cells.(9) Parsons also takes the same side of the question and states in addition that the masses of colloid found in the adenomas have as their origin carcinogenic tissue. In fact, he goes even as far as to say that the colloid material itself is of the nature of a true tumor.(10)

Rienhoff(11) in 1926, and Rienhoff and Lewis(12) in 1927, called attention to the fact that a great many of the nodules had the appearance of old colloidal goiter. This observation led them to postulate that that nodular goiter was caused by a process of involution following a period of local hyperplasia. In 1931, Womack and Cole further substantiated this idea by their work on dogs. Using an artificial stimulus on the thyroid gland, they found that following removal of the stimulus, involution of the hyperplastic area would occur. Or by the administration of iodine, involution would occur. And in either case, involution was followed by a replacement of the tissue by fibrous tissue, producing a nodule similar to the adenoma.(13) Graham(14) and Thomas(15) in 1928 stated that the adenoma was formed as a result of involution of hyperplastic areas in the thyroid gland, resulting from an old colloid goiter. Hinton(16) explains the formation of the nodules in much the same way as Hertzler(17), on the basis of involutinal changes in the thyroid gland. He states that in most instances the nodule is due to an involution of a colloid to a normal phase, leaving areas of colloid encapsulated in the gland here and there.

It is more or less an accepted fact now that nodular goiter is really a result of a continuous process of alternating involution and hyperplasia. This is in reality nothing more than Marine's(18) idea of the thyroid cycle, which he published in 1931 and which may be shown as below:



## Normal Structure of the Thyroid Gland

A cross-section of the normal gland reveals a smooth, shining surface which when minutely inspected with the naked eye, shows areas of colloid collected in small lobules separated by very scanty, thin, fibrous septa. The follicular markings and the small areas of colloid follicles vary in distinctness according to their number in proportion to the interfollicular stroma.

When the connective tissue investing the normal gland is stripped away, the gland is revealed as a complex mass of tissue which is divided and broken up into many regions of parenchyma. These larger regions are in turn made up of groups of follicles of different number, shape and size, depending on the location, shape and size of the region which the follicles compose. The form of these areas varies visibly and there appears to be a total lack of uniformity not only between those of various divisions of the gland, but also between those of various glands. These areas of the parenchyma may best be described as connecting or antecedent bars, bands, or plates of tissue.(19) The entire lobe of the thyroid is irregularly traversed by bands or systems of connective tissue which carry in them blood vessels, lymphatics and

nerves. It is in this manner that the parenchyma is divided and subdivided into many regions which as previously stated have the greatest diversity in shape and size with but one constant feature, namely, that all of these regions are connected to each other at one or more points on the structure.(20) In the normal gland, in no case is the parenchyma so completely surrounded that it is not connected at one or more points to the next lobule. As the center of the gland is reached, it is noted that the compactness and density of the structure is much greater than that closer to the periphery. This is true of all normal glands and probably represents the result of compression on the peripheral structures of the gland by adjacent structures of the neck such as the trachea, large blood vessels and other structures found in that region.(21)

The connective tissue stroma surrounding the follicles and making up the septa of the gland, are composed of a loose connective tissue which contains in its substance numerous blood vessels, nerves and lymphatic channels. The blood vessels and nerves do not vary in structure or in size from those found in any other normal gland of the body. The lymphatic chain is very complete and nearly surround the entire follicle. These channels

in all reality form rather a "sea" in which numerous columns of thyroid parenchyma are floating. The lymph channels also contain quite a number of small lymph nodules which show no hyperplastic or hypertrophic changes.(22)

The follicles of the normal gland vary a great deal in size and shape. This again depends upon their location in the gland and the size of the area which they make up. The greater majority of follicles being of a comparatively small size. A number of them contain hardly any lumen. The larger follicles which may be up to one m.m. in diameter have a lumen which contains typical colloid. As regards distribution, there appears to be no fixed location in relation to size of the follicles, but rather the large and small follicles appear to be distributed rather equally throughout the gland. The shape of the follicles depends a good deal on the size of the individual follicle. The smaller follicle tends to be more nearly spherical, although there is a variation in the degree of perfectness of the sphere, while the larger follicles appear to have a greater variety of shape, varying from perfect spheres to oblong, various hexagonal and octagonal shaped figures.

Some of these bizarre shapes may be explained on the basis of cupping of the walls from slight external pressure of the connective tissue stroma, while others result from resting on a dome of an adjacent follicle.(19) The outside wall of the epithelium, except for an occasional facet or cupping is smooth, showing no outpocketing or buddings. However, the inside of the follicle may show outpocketing into the lumen and consequently into the colloid material contained therein.

The cells lining the acini have been the subject of a great deal of controversy as to the type of normal cell making up the normal follicle. Marine believes that the cells are of a low, cuboidal nature, any columnar cells or other structural types being of pathological nature. He differentiates the cells into two types, the chief and colloidal cells, the chief cells predominating in the normal gland, the colloid cells being found in the normal gland but in lesser quantities. The chief cells are attached to a delicate vascular connective tissue framework at their bases.(18) The nuclei are vesicular in shape, stain well in contrast to the cytoplasm of the cell and often show nucleoli. The cytoplasm is faintly granular in character and

uniform in consistency and density throughout the cell.

(23) There can be seen, by special staining methods, mitochondria. They appear as minute rods and are scattered fairly uniformly throughout the cells.(24)

The colloidal cells, according to Marine's conception, are nothing more than chief cells which have lived their normal span of life, secreted their colloid, and are now in the process of degeneration.(21) These cells differ from the chief cells in having an irregular density of the cytoplasm and often show vacuoles. The staining characteristics of the cytoplasm are also different in that the cytoplasm of the colloid cell generally stains pale and uneven. The nucleus is pycnotic, stains deeply and shows very little structural differentiation. Loeb has shown that mitotic figures found often in pathological sections are not to be found in normal cells.(25) Goormaghtigh and Thomas differ in their opinion of the type of cells that are typical of normal thyroid tissue. They believe that Marine's conception of columnar cells in thyroid being pathologic is quite false. They state that a series of normal thyroids found around Ghent, Belgium, which is an area in which endemic goiter is not found, showed four types of cells of which one



type was typical columnar epithelial cells.(26) They are supported in this view by Norris, who states that the columnar epithelium found in thyroid tissue is not pathognomonic of hypertrophy of the gland tissue, but rather a normal structure in a normal gland.(27) However, in view of the fact that all hyperplastic thyroids show a predominance of columnar epithelium and that columnar epithelium in the normal gland is comparatively rare, it is my opinion that the strictly normal functioning thyroid, if there is such a thyroid gland, is composed of acini made up of cuboidal epithelium.

The type and amount of colloid in the follicle also varies in the normal thyroid gland. In many sections the central portion of the follicle may contain a portion of colloid which stains deeply, while the periphery may contain a lighter staining colloid, or in other acini the central portion of the acini may be the only part that contains colloid.

Hertzler states that the degree of staining reaction depends upon the age of the colloid being stained. He states that the difference in the degree of staining reaction in the central and peripheral parts of an acini is due to the age of the colloid, that near the center

being stained deeper than that on the periphery because of the greater age of the central colloid.(28) Murray(29) and Boyd(30) disagree with most workers in that they claim that all acini in normal glands are completely filled with colloid. They state that the lack of colloid in the acini of normal glands is due to a postmortem change in which the colloid has undergone degeneration and been partially absorbed. The epithelial cells, having torn loose from their basement membrane, migrate to the center of the acinis and form a solid mass of cells.

## Pathology of Nodular Goiter

The nodule can be palpated and is composed of sharply localized areas of hypertrophy and hyperplasia, while the intervening parenchyma of the gland presents the microscopic picture of the normal thyroid. The morbid process in most cases remains confined to certain localized, well defined areas, rather than becomes diffuse throughout the gland. Boyd(32) states that the site of the adenoma may be governed by the degree of circulatory interference that is taking place in a localized area. He has shown that on microscopic examination the nodule shows frequently dilation of blood vessels and lymphatics. (32) Marine and Lenhart attribute the location to the changes in the circulation of the glands caused by involution and hyperplastic changes during the cycle of thyroid disease.(33) In the gross specimen the tumors or nodules of the thyroid are readily palpable and vary in size from shot-like nodules to tumorfactions the size of a man's fist. This lack of uniformity of size has been explained by various workers in various ways. Keilty in a paper on the inflammatory nature of toxic and nontoxic adenomas, states that a very high percent of adenomas, both toxic and nontoxic, are the results of inflammatory changes. He attributes the lack of uniformity in size

to the different localized areas of the gland.(34)  
This may be true in the nontoxic group, but it is highly improbable that the etiology of the toxic nodules could be on the basis of an inflammatory nature. Rienhoff and Lewis have presented the idea that the size of the nodule is dependant on the number of cycles of involution and hyperplasia that the nodules have undergone.(12) This is highly possible but in accepting such a theory, we must find the primary cause for the location of the nodule. Marine states that the most probable factor determining location of the gland is the condition of the circulation in that area, as any variation in a gland of the blood supply to different localized areas would cause a difference in the rate of growth of the tissues in the respective areas.(21) It seems most logical that variation in the circulatory system of the gland is the primary cause of the difference in size.

In the gross specimen on section, the nodules form sharply circumscribed areas with fibrous incapsulation. These tumors appear to be composed of parenchymatous tissue and toward the center contain small cysts and areas of connective tissue.

Microscopically, the nodules are composed of thyroid

parenchyma in a state of hypertrophy and hyperplasia. In the majority of nodules the acini are of three structural types: (a) the cells appear as diffuse masses without the formation of acini, (b) as small acini with very small lumens containing very little colloid, (c) as large acini with larger lumens and containing small amounts of colloid material. The larger acini generally show the characteristic papillary infoldings which give the acini its odd shape. (35) There are a number of factors which play a part in the type of acini seen in the nodules. Gale Wilson in a description of the pathology of nodular goiter, states "small buds can be seen on many of the acini, but no constriction indicative of follicular division can be seen". His interpretation of the buds is by two processes: (a) the infolding of the distended follicle causes a fusion of the walls of the follicle so that normally where there was one acinus, we now have two or three, (b) he states that the formation might be due to fusion of a large and small follicle. (36) Body states that while a great deal of the bizarre shapes and sizes are due to the foldings of the collapsed follicles, a greater number are the results of budding from the follicle itself. He has demonstrated this in a

number of cases by the use of serial sections in which he was able to follow through a bud from its point of union with the original follicle to its dome-shaped mass of cells.(32) This, incidentally, may account for the masses of cells without a lumen mentioned by Goetsch.(37) Collier attributes the difference in size and shape to the age of the nodule and its relative position in the cycle of hyperplasia and involution, stating that the small follicles with small lumens probably belong to the comparatively new formed adenomas still in a stage of hyperplasia, while the older colloidal nodules or nodules in the stage of involution show larger acini with larger lumens.(38)

The epithelium lining these acini shows the characteristic histologic changes associated with an increased functional activity of cells. Marine states that the process of hyperplasia and hypertrophy is initiated by an enlargement of the normal cells, which are normally cuboidal in shape to a columnar type of cell.(39) Later the process of hypertrophy begins to take place with the large increase in the numbers of cells as can be seen by the increase in mitotic figures seen on special examination of the parenchymal tissue. Loeb in 1919

showed by his work on the thyroid glands of guinea pigs that coincident with hypertrophy of the thyroid gland of the guinea pig a great number of mitosis occurred. The size of the cells was likewise altered from low cuboidal to markedly high columnar cells in the hyperactive glands.(25)

Goetsch in a cytological study of a series of adenomas of the thyroid, both toxic and nontoxic, found that there was a distinct difference in the number of mitochondria present in the cells of toxic adenoma as contrasted to the number present in normal gland tissue. While the mitochondria were morphologically the same as those found in normal thyroid cells, there was a striking abundance of the mitochondria everywhere in the parenchymal cells of the toxic adenoma. He further states that this is true of all of the cells of the parenchyma of the nodule whether of the columnar or cuboidal type. The cells also vary markedly in size and shape and have a larger nuclei showing nucleoli and which are richer in chromatin than the normal cell's nuclei. As a control for this experiment, sections of normal thyroid gland were fixed and stained by the same method, and the number of mitochondria seen in the cells

was very definitely smaller. This was also found to be true in non-toxic nodular goiters.(24) Key, in 1925, substantiated this work and made some additions to the knowledge of cell structure found in toxic adenomas. He found on careful study of the parenchymal cells of toxic adenomas that they contained minute, clear vesicles in the cytoplasm of a definite shape and located in the apical zone of the cell, the cells showing active hyperplasia having the greatest increase in number. These vesicles he termed the chromophobe antecedent, or the precursors of the colloid normally formed by the normal cells.(23)

In certain areas of the parenchymal tissue there can be seen areas of cellular degenerative. These are most commonly found in the walls of the acini of large size and which are completely filled with colloid. The cells show vacuoles not unlike those of the chromophobe antecedent type, but differing in that they are irregular, generally contain debris, and are not localized to any one area. The cytoplasm is fuchsinophilic in staining qualities, the mitochondria are fragmented, and the nucleus is generally pycnotic in shape.



The amount and properties of the colloid present in the toxic adenomas has long been the subject of much speculation. Marine states that hypertrophy is characterized by a definite decrease in the stainable colloid of the acini.(21) This is further substantiated by Means, who states that one of the primary characteristics of a toxic nodular goiter is the lack of stainable colloid.(40) Jackson adds support to this view in his work on the pathology of the toxic nodular goiter in which he has paid special attention to the size of the acini and their contents. His findings showed that in the toxic nodular goiter, 70.1 per cent of the acini were smaller than those of the normal gland, the measurements of the normal acini being two to three times as large.(41)

The character of the colloid is also markedly changed in toxic adenoma. Hertzler(42) and Wilson(43) describe the characteristic colloid of toxic nodular thyroid as staining with heamatoxylin rather than with eosin in the first stage of toxicity. As the process proceeds, the changes become more noticeable in the irregularity in the density of the stain, and lighter staining qualities of the colloid and finally the presence of vacuoles in the colloid. The significance

of these changes in the properties of the colloid is not definitely known, but Hertzler claims that the first toxicity of the toxic nodular goiter is due to degeneration of the colloid, which in turn sets up the process of cellular degeneration in the acini and parenchymal cells of the nodule. He fails to explain the presence of the large number of mitosis and the change of the cuboidal to the columnar type of cells.(40) This might be explained as a reaction of the tissue to repair the areas damaged by the toxic substance, if there is such a toxin. Further evidence in favor of this view is that the nodules often show areas of glandular tissue composed of columnar cells with increased mitochondria and areas of degenerating acini made up of the typical degenerating cells.

As contrasted with non-toxic nodular goiters, the colloid has poor staining qualities, is vacuolated and is spread unevenly throughout the acini; while in the non-toxic type of nodule the colloid is uniform throughout the acini and stains with the same intensity as the colloid of the normal glandular tissue.

Williamson and Pearse, in 1923, found the lymphatic

spaces of the nodule to have been decreased very markedly partly as a result of the vast increase in number of acini in the toxic gland, but mainly because of the increase in connective tissue stroma and enlargement of small blood vessels adjoining the lymph sinuses as the involution process starts in certain areas of the nodules.(22) Wilson found on examination of a number of specimens that the lymphatic spaces often contained colloid. He attributed this to a rupture of the follicle walls with subsequent release of the colloid rather than an actual physiological process.(36)

A characteristic of the nodule is its definite encapsulation by fibrous connective tissue. Upon careful microscopic examination of the capsule, it appears to be the result of a hypertrophy of the connective tissue trabeculae covering the normal thyroid follicles. Plummer, in a recent paper, thought the increased connective tissue surrounding the nodules may be due in part to an inflammatory process resulting in the characteristic laying down of connective tissue in replacement of the damaged tissues.(44) Broders and Plummer(45) in a later paper on acute capsulitis of partially degenerated thyroid adenoma, show that quite a few of the

greatly enlarged adenomas have a thick fibrous capsule surrounding them and on careful correlation of laboratory and clinical finding, they arrived at the conclusion that an acute infection of the preexisting adenomas was the cause of the greatly thickened capsule. These observations, while being true in certain cases, do not apply to the majority, as they show no evidence of acute infection of the nodule or its capsule. Graham(14), Parsons(10), Hertzler(42) and Marine(30) believe that the capsule is the result of the compression on the surrounding tissue with resulting atrophy of the surrounding parenchyma which will be replaced by the connective tissue that normally replaces atrophic glandular structures of the body. In view of the fact that as the nodule enlarges, it causes a good deal of pressure to be placed on the surrounding tissue with resulting loss, or partial loss, of blood supply and finally atrophic changes in the immediate zone of compression with connective tissue replacement of the atrophic tissues, it would seem logical that the capsule was formed by compression in a majority of cases.

Rienhoff and Lewis give further proof for the origin of the capsule by pressure, by the finding of

small acini within the stroma of the capsule. These areas of acini, while being made up of almost perfect epithelium and perfect structure, are nevertheless very much smaller than those found in normal thyroid tissue. It is the idea of Rienhoff and Lewis that the compression of the surrounding tissue caused the lack of development.(12) Hertzler takes a different view on the matter in his article on the fetal adenoma in which he says that the intrastromar acini are a normal occurrence in the stroma of a normal thyroid gland and should not be considered pathological changes.(28)

The factor of compression, however, does play an important part in the production of degenerative changes in the center of the adenoma, such as cystic areas, areas of old hemorrhage and hyaline degeneration. Marine and Lenhart attribute degenerative changes of the adenoma to hyaline degeneration of the blood vessels and of the lymph channels which they claim is a normal process in senile atrophy of tissues. In a series of cases studied microscopically, they found that the majority of degenerative changes appeared in nodules of long standing duration, while those that were of comparatively recent origin showed few of the degenerative changes.(33)

Plummer believes that the areas of hemorrhage into cysts are caused by a secondary infection of the nodules in a number of cases, but does not commit himself by limiting the etiologic factors to this one cause.(45) Hertzler states in his recent treatise on thyroid pathology that the causes of degeneration are probably caused by a combination of the compression and the senile atrophy factors.(42) Boyd attributes the degenerative changes to changes in the circulation of the adenoma, but neglects to explain the cause for the circulatory changes. He states, "A striking feature of the tissue is the presence of large, thin-walled blood vessels, and it is evidently these which are responsible for the frequent hemorrhages." (32) The genesis of the degenerative process is as yet quite obscure, but the presence of greatly dilated vessels some undoubtedly blood vessels and others lymphatics, suggest that local interference plays a part.

The microscopic picture of the degenerative changes seen consists of rarefaction of the tissue, the stroma being replaced by a thin, structureless, clear-staining material which resembles to a certain extent the colloid in normal acini. The acini are evidently separated from each other and show various degrees of disintegration,

from acini with no lumen to a few disintegrating cells scattered throughout the hyaline matrix. As the center of the nodule is reached, we find areas which are cyst-like in character and contain varying amounts and types of material. Some show the characteristics of an old hemorrhage into the cyst. Plummer claims that the majority of these hemorrhages are due to other pathological process aroused by acute infection rather than any other cause.(45) But looking at the problem from a different viewpoint, it seems logical that the effects of pressure play an important part for the following reasons:(1) The areas of degeneration are nearly always found within the center of the nodule where the pressure is the greatest. (2) The thin walls and dilated lumens of the blood vessels and the relatively few vessels found in that location point to interference with the circulation due to pressure with a resulting atrophy of the tissues.

The occurrence of the cyst-like areas has been explained by pointing out that in various old adenomas of the thyroid, there have been found acini of very large lumens which have been depleted, or contain very little of their colloid. It is thought that these acini

when in the center of the degenerative process, do not in all cases collapse, but due to the firmness of the surrounding hyaline matrix, retain to a certain extent their original shape. As a result, when the pressure increases due to a supervening infection or whatever the cause may be, blood vessels rupture into the lumen of the cyst resulting in the cysts that contain hemorrhagic areas.

The above mentioned areas of degeneration, if looked at from the viewpoint of the physiologist, would be called areas of involution of the gland rather than degeneration, as they are thought by many to represent the involutinal changes resulting from the gland adopting itself to the abnormal condition of secretion and nearing its normal functional level again with a consequent atrophy of the excessive hyperplastic and hypertrophic areas within the glandular tissues. This is further substantiated by the character of the epithelial cells which in the majority of cases show signs of degenerative changes as pycnotic nuclei, large vacuoles and a tendency of the cells to pull loose from the basement membrane.

Rienhoff and Lewis(12) have found on examining a number of specimens of known age that the proportion



of hyperplastic and hypertrophic tissue to that showing involutinal changes is roughly proportional to the age of the nodule and the number of exacerbations and remissions it has undergone. They found that as a general rule, the older the patient the greater would be the amount of involutinal changes found. So that in a number of young patients the nodules did not show as great an amount of degenerative changes as did that of the older ones.

## Physiology of the Thyroid Gland

The function of the thyroid gland is to act as a pacemaker of metabolism. This function is performed by means of the secretory products of the gland. Kendall in 1914, isolated from the thyroid a crystalline substance which contained from 60 to 65 per cent of iodine. This substance he called thyroxin.(47) Kendall was unable at the time of his first work to determine the formula of the substance and it remained for Harrington to show that the compound possessed the formula of  $C_{15}H_{11}O_4NI_4$ .(48) Kendall in his later work on the action of the substance came to the conclusion that it is the only physiologically active substance made in the thyroid gland. In contrast to Kendall's theory, Sloan believes that the action of the gland depends on the presence of more factors than thyroxine alone.(49)

The mechanism by which the colloid is formed is still under dispute, there being two theories as to its origin, the merocrine and the holocrine. The merocrine type of secretion consists of evacuation of the contents of the cell into the follicle while the cell is not destroyed but regenerates and resumes its function.

The holocrine in contrast to the merocrine theory, states that the cell ruptures and its whole structure is used in the production of the colloidal material.

The discharge of the hormone of the thyroid into the blood and lymph streams is caused by a deficiency stimulation rather than an actual nervous stimulation. This has been shown by virtue of the fact that transplants of thyroid tissue devoid of any nervous connection, function efficiently and produce a normal product. We may state then, that the secretion is a result of a deficiency of thyroxine in the blood and tissue in large enough quantities to promote normal metabolism.

The primary function of the thyroid gland that has been found up to the present date, is that of regulation of body metabolism. This was first demonstrated by Magnus Levy in 1895 using the newly developed calorimeter by which method he was able to show the heat production to be lowered as much as 40 per cent.(6) Murray in 1891, added another bit of confirming evidence when he treated a case of Gull's disease with glycerin extract of fresh thyroid and was able to maintain the patient in perfect health for twenty-eight years.(51) Later experimentors and clinicians have found confirming

evidence in their treatments of myxedema and hyperthyroidism.

Formerly, it was believed that the thyroid gland had the power of neutralizing poisons resulting from metabolic processes. But the present conception of the site of action of thyroxine has tended to discredit the detoxification theory which has very little scientific proof for its defense.

Another function assigned to the thyroid is that of an antibody formation. This problem has been rather thoroughly studied and while the results are somewhat contradictory, they do not tend to show any direct association of the thyroid with antibody formation.(51)

#### Thyroid Pituitary Relationship

It has long been known to students of goiter that animals and individuals with large parenchymatous goiters have greatly enlarged anterior pituitaries. Smith showed by means of removing the pituitary in tadpoles without injuring the adjacent brain structures that the anterior pituitary was a master gland and that it controlled the functional state of many organs, thyroids,

adrenals, gonads and others.(52)

The pituitary hypertrophy after thyroidectomy, is much greater the younger the animal used. Histologically, the elements of the anterior pituitary becomes hypertrophic but the most striking single change is the disappearance of the eosinophil granules. Smith first noted in tadpoles that hyposectomy caused a marked involution of the thyroid; the injection of fresh anterior pituitary substance restoring such atrophic thyroids to normal and even producing hypertrophy in these glands.(52) It has recently been shown that fresh emulsions of the anterior pituitary gland when given to normal young animals causes a marked hyperplasia and hypertrophy of the thyroid. There is also a rapid loss of the iodine store in the gland, an increase in blood iodine, in the metabolic rate, and in the excretion of the calcium and creatine and exophthalmus develops.

It was early observed by many workers that the daily administration of the thyrotropic factors to rats and guinea pigs or rabbits brought about, in from thirty to forty days, a resistance to thyroid stimulating factor and the thyroid slowly regressed to its quiescent or

colloid state again. Collip and Anderson have shown that the serum of such recovered animals, while not preventing thyroid hyperplasia following injection of the thyrotropic factor, did prevent the characteristic increase in metabolism, calcium, excretion and the like.(53)

### Thyroid Gonads

The fact that during menstruation and pregnancy the thyroid frequently enlarges and that the incidence of goiters in pregnancy, puberty, and the menopause is increased, has led physiologists to recognize for centuries that there is a very close relationship between the thyroid and the gonads. It appears that effects of the thyroid on the gonads and vice versa could be explained as effects mediated through the anterior pituitary. There is abundant evidence to show that the response of the pituitary to thyroidectomy is not limited to stimulating an increased production of the thyrotropic hormone, but that there is an increase in the growth hormone and its gonadatropic factor as well. A depression of the thyrotropic factor by the administration of thyroxine probably depresses the gonadatropic factor. In rabbits that have been thyrodectonixed at four or five months of age, there is

noticed at the time of puberty a frequent increase in sexual activity. So also injecting large doses of estrogenic substance appears to decrease the amount of the gonadotropic factor produced by the pituitary as well as depressing the thyroid glands. These effects are understandable if one assumes that the same pituitary cell produces more than one hormonal factor. There is evidence that the eosinophilic cells may be responsible for the production of thyrotropic and growth-promoting factors.(6)

#### Thyroid Pancreas Relationship

Burns and Marks(54) and Bodansky(55) found that dogs were less sensitive to the hyperglycemic action of epinephrine than normal animals. Bodansky reported that thyroidectomized sheep were more sensitive to insulin than normal animals. Conversely, it has been shown that feeding thyroid or thyroxine to thyroidectomized rabbits decreases the hypoglycemic action of insulin. Bodansky believes that the thyroid hormone promotes glycogenolysis and that it is because of this action that the hypoglycemic action of insulin is increased after thyroidectomy and decreased by thyroid feeding. This may be partially explainable on the basis

of the thyroid sensitizing the sympathetic nervous system to action of epiniphrin.

#### Thyroid Chromaffin Relationship

In 1911, it was shown that if a dose of epiniphrin was given and the thyroid nerves stimulated simultaneously the rise in blood pressure is much greater than that found after the injection of epiniphrin alone. Blau and McNamara had the same effect after using thyroxine in conjunction with epiniphrin.(56) These observations point to the conclusion that the thyroid hormone increases the irritability of the sympathetic nervous system or sensitizes in some way the tissues innervated by it so that they are more sensitive to stimulation by epiniphrin.

On the other hand, it has been shown that injection of one to three mg. of thyroxine in dogs caused a gradual hyperglycemia in the course of three to six hours and that this did not occur when the adrenal veins were ligated prior to the injection of thyroid. These would suggest a direct stimulation of the chromaffin system.



## Physiology of Symptoms

Size and shape of tumor----The gland is always enlarged and usually nodose and asymmetrical. The nodules being usually large and irregular shape altho it may be quite small. The nodule lacks any regular shape; that is, it may grow to a large size and be regular in shape. The mass is firm to the palpating finger in contrast to the gland seen in Basedow's disease which is usually soft to the touch early in the disease and finally has fibrous feeling in the later stages. The nodule lacks any suggestion of pulsation which is very often felt in Basedow's disease, due to the greatly increased vascularity of the gland seen in that condition. The same holds for the phenomena of compressibility which is seen in Basedow's disease and is again due to the increased vascularity of the gland and results in the ability of the examiner to compress the diseased gland to about one third of its size. There is another characteristic of the nodule in a toxic nodular goiter and that is its insidious growth. In many cases in which the nodule is small, the complaint of the patient is not of a nodule in the gland but rather of palpitation or of gastro intestinal symptoms. In fact many of these

cases have been treated for years as a primary cardiovascular problem rather than an endocrine disturbance.

### Cardiovascular Symptoms

The cardiovascular symptoms of nodular goiter may be outlined as follows:

1. Tachycardia
  - a. Palpitation
  - b. Dyspnea
2. Auricular fibrillation
3. Congestive heart failure
4. Heart block
5. Hypertension
6. Angina pectoris

The cardiac changes found in hyperthyroidism have been shown to be purely functional and without any permanent pathology in cases that receive proper treatment. As soon as the underlying hyperthyroid condition is removed, the heart loses its irregularities and comes back to normal in a vast majority of cases. It is only in the cases that are allowed to stand for years that the condition shows lesions of the cardiac musculature.

Tachycardia is usually the first cardiac symptom to appear and in great many cases is the complaint that brings the patient to the physician. The tachycardia differs from that in Grave's disease in that it is usually mild, the pulse rate varying from 90 to 110 in early cases, the only discomforts being attacks of palpitation, dyspnea and dizziness. In later stages of the disease the pulse rate may go up to as high as 120 or 135, but is seldom any higher.

As the disease progresses, the attacks become more frequent and in a majority of cases if the condition is allowed to go unchecked, arrhythmia develops. The commonest of the arrhythmias is auricular fibrillation. Following close in the footsteps of auricular fibrillation is congestive heart failure. Hypertension is also found in a good many late cases of toxic nodular thyroid. The question of whether heart block and angina are not the results of some previous heart pathology rather than primary with the toxic nodular goiter is still open to debate. In fact, the question of whether or not all of the cardiac symptoms of toxic nodular goiter cannot be explained on the basis of previous cardiac lesions is still being debated. Foss, in a recent article on

the heart in toxic goiter, states that the majority of thyrocardiacs are individuals who previous to the onset of the thyroid disturbance suffered from organic heart disease.(57) Taking the other side of the question are Rankin and Grimp, who state that in analyzing 1,045 cases of auricular fibrillation they found the causative factor to be hyperthyroidism in 32 per cent of all cases. They quote also the figures of Willis and Pemberton who make the statement that 25 per cent of all cases of hyperthyroidism fibrillate, with persistence in 10 per cent of the cases.(58) Hurxthall claims that auricular fibrillation can be the result of hyperthyroidism in patients with hyperthyroidism. In his article on hyperthyroidism and heart disease, he makes the following statement, "It is true that auricular fibrillation occurs more frequently in people with coincident heart disease and hyperthyroidism. Nevertheless, its cessation in over 50 per cent of the cases after operation without any other medication to bring about normal rhythm is indicative of cause and effect." He goes even further in his paper when he states that 80 per cent of cases with hyperthyroidism and congestive heart failure are caused by the hyperthyroid condition.(59)

In the case of heart block there is a great deal of question as to whether the hyperthyroid condition is primary. Stewer in commenting on the frequency of heart block stated that in his opinion the condition was very rare.(60) Davis and Smith have recorded six cases of heart block in hyperthyroidism, but in all cases the condition followed a severe infection. In a careful study of the literature they were able to find only four cases of heart block associated with hyperthyroidism and all of the four were suffering from severe infection at the time of appearance of the symptoms.(61)

Angina pectoris, likewise, has been much discussed as to whether it is the result of hyperthyroidism or a combination of effects due to previous heart pathology and hyperthyroidism. Shambaugh was able to produce angina pectoris in dogs by occluding the coronary arteries. He went further into the study and found that if the coronaries were partially occluded without the production of angina attacks, the attacks could be brought on by adrenalin injections. Levine and associates have shown that in a series of cases with angina, an increased sensitivity to adrenalin existed as they could by small injection of adrenalin, precipitate

attacks of angina. The question is still far from settled, however.(63)

The exact mechanism by which the cardiac symptoms are caused is not clearly known, altho there are a number of theories on the question. Hurxthall in a discussion of the problem, states that there are a number of factors which might cause increased heart action: 1. The demands for increased circulation in the body as the result of the increased metabolism. 2. The peripheral dilatation of blood vessels demands a greater blood supply. 3. The direct effect of the thyroid secretion on the heart muscle. 4. The possibility that nervous control may be affected.(59) All of these theories have been at least in part, ruled out by other experimentors. Yates has shown that the action of thyroxin continues after removal of the bundle of His and after complete denervation of the heart.(64) This has been substantiated by the work of Markowitz and Yates who showed that the heart of a chick embryo, grown in culture, which was completely devoid of any nervous elements, reacted to the thyroxine by an increase in rate.(65) These experiments do not exclude the factors of Hurxthall entirely but show very conclusively that

the phenomena is not dependent on any one of them alone. MacDonald has shown some very interesting results from his work on the action of thyroxinized hearts. He showed that if epiniphrin was injected into a heart previously perfused with thyroxine, the increase in the number of beats perminute was greater than in hearts not perfused with thyroxine previous to the injection of epiniphrin.(66)

In conclusion, it must be said that exact mechanism of increased action with resulting functional disturbances is far from solved at the present date.

## The Basal Metabolic Rate

As a general rule, the basal metabolic rate in toxic adenoma is considerably less than it is in Grave's disease. The patient may be very ill with marked symptoms of thyrotoxicemia and severe cardiovascular disturbances and still show only a slight rise in the local metabolic rate. A further study of toxic adenoma will show that a rise in the basal metabolic rate is not always associated with the same severity of symptoms that a similar rise in Basedow's disease would imply.

In examining the basal metabolic rates of a series of cases with toxic adenoma, it is interesting to note that there is a striking lack of uniformity in the curves of the basal metabolic rates. The basal metabolic rate may also vary a good deal in the same case. It may be low and the patient show beginning symptoms of thyrotoxicemia while in the later cases there may be a marked increase of the metabolic rate with no increase of the toxic symptoms.

The course of the disease varies with the individual cases. In some severe cases the basal metabolic rate may be as high as plus 50 throughout the course of the disease. While in others the disease may be present for years with no notable increase in the basal metabolic rate.



The exact nature of the mechanism or mechanisms causing the increase in the basal metabolic rate are as yet not known. During the last fifteen years numerous investigators have worked on the problem with as yet no definite solution. One of the earliest theories was to the effect that thyroxine acted on the central nervous system which through increased stimulation caused the rise in basal metabolic rate. This theory has not held up as is shown by the work of Reine and Wolf, who by using guinea pigs which had the nerves to and from the heart severed, found that the thyroxine, when injected intravenously, exerted precisely the same effect as on muscle with an intact nerve supply. This work has received confirmation by a number of other experimentors. Lewis and McEachern showed that when thyroxine was administered to an intact animal by mouth and a piece of tissue removed and placed in physiological conditions that piece of tissue as long as it survived would continue to show the phenomena characteristic of the hyperthyroid animal. This work was done by feeding animals thyroxine by mouth and later removing their hearts and placing them in a normal saline bath. The hearts continued to beat throughout

the remainder of their life at a much greater rate than those of the normal animals used as a control.(67) The result of these experiments and those of Reine and Wolfe indicate clearly that the action of thyroxine is not limited to the central nervous system, alone. Davis and DeCorta went deeper into the problem when they were able to show that thyroxine perfused through a heart removed from the body of an animal had the same effect as thyroxine given by mouth. They also found that thyroxine had no effect on macerated tissue.(68)

Numerous investigators have noticed that the carbohydrate metabolism of muscle in hyperthyroidism has been profoundly affected. It has been shown that the glycogen stores have been depleted under conditions which normally led to production of glycogen. Also that lactic acid accumulates in the blood in greater concentration than normally. This has led investigators to postulate that the increased metabolism is due to a consequent greater demand for oxygen to bring about oxidation of the increased amounts of lactic acid. The fact that the muscles of the hyperthyroid animal do utilize more oxygen has been proven by MacDonald.(66) The rest of

the theory has been disproven by the work of Andrus and McEachern who showed that by administering thyroxine to tissues and then stopping the carbohydrate metabolism by the use of sodium fluoride, that the increased metabolic rate still was maintained while the carbohydrate metabolism was not completed.(69) McEachern in a later experiment has shown that while augmented oxygen utilization persists in the tissue of the hyperthyroid animal after its isolation from the body, a commensurate increase of carbohydrate metabolism cannot be demonstrated in tissue other than the kidney.(70) So it must be said that the increased basal metabolic rate is not due to an increased carbohydrate metabolism.

Langley stated in 1915, that the increased basal metabolic rate was due to increased muscular tonus, muscular fibrillation and muscular activity.(71) This has not held up as it has been shown that upon anesthetizing an animal in order that he may be free from increased muscular activity and then injecting it with thyroid extract the basal metabolic rate rises to quite a marked degree while the musculature of the animal was quite relaxed through the entire process.

Recently there has been much written about the re-

relationship of the adrenals to the increased basal metabolic rate in hyperthyroidism. Andrus and McEachern in experiments on guinea pigs showed that after removal of the adrenal glands of the animal the high basal rate still could be obtained on the injection of thyroxine.(72)

Andrus and McEachern as a result of a series of experiments completed in 1937 claim that certain respiratory enzymes found in tissues are increased in amount and potency in hyperthyroidism and may be in part responsible for the rise in basal metabolic rate in the condition.(72) No one has as yet repeated or reduplicated the results. It would appear from the work of the numerous investigators that the action of the thyroid gland in causing an increased basal metabolic rate is far from a simple reaction but rather calls into play a number of factors. The only theory which thus far holds good, and it is not entirely complete as yet, is that stating that the thyroxine acts directly on the individual cells, perhaps by means of increased respiratory enzymes, altho this has not been confirmed as yet.

#### Gastro Intestinal Manifestation

One of the commonest gastro intestinal symptoms of

hyperthyroidism is constipation. This frequently takes the form of a severely obstinate constipation which ordinary therapeutic methods fail to cure. As in the previous symptoms a great many theories as to its cause have been presented.

If we take the theory of increased sensitivity of the musculature of the gastro intestinal tract to adrenalin as put forth by Wohl(73), the explanation is fairly simple. Accepting the statement that there is an increased sensitivity to adrenalin in cases of hyperthyroidism we find that the rest of the theory is in accord with modern concepts of gastro intestinal physiology. The sympathetic nerves to the gastro intestinal tract causing an inhibiting effect on the musculature of the gastro intestinal tract, thereby producing a spasticity of the gut and lack of peristalsis that delays the emptying time of both the stomach and the intestine. But at the present time the question as to whether or not adrenalin acts more effectively in the presence of an excess of thyroxine has not been settled. Goetsch and his associates in some recent experiments have shown that the typical picture of hyperthyroidism can be produced by the injection of epiniphrin into an animal with a mild

degree of hyperthyroidism. Contrary to the opinion of Goesch is the recent work of White who has devised a new method for the quantitative determination of adrenalin in the blood. His results so far have shown no increase in adrenalin in the blood of hyperthyroid patients.(74) W.Timme gives as an explanation of the gastro intestinal symptoms on the basis of corresponding involvement of the parathyroids in any case of hyperthyroidism. He states not only in the parathyroids involved but also the adrenals and anterior pituitary gland, The exact mechanism depends upon a deficient parathyroid activity which in time produces an upset in calcium metabolism and results in spasticity of the gastro intestinal tract. He further postulates that in cases of diarrhea in hyperthyroidism the mechanism is due to a vagotonia which produces effects opposite from that of the sympathetic system and a consequent hypermobility.(75) Whether or not this holds is hard to say as there has been very little work to show one way or the other. Smithies in a discussion of the mechanism of gastro intestinal symptoms in hyperthyroidism states that there is a definite relationship between thyroid, adrenals and pancreas. He explains further by

stating that when the supranel gland is speeded up there follows an acute suprarenalism.(77) According to Edmonds there is a depression of the pancreas as the result of the hypo-functioning pancreas. The explanation is not entirely clear by virtue of the fact that the acute or very sudden rise in adrenal secretion would tend to promote a very marked degree of intestinal spasticity which would be difficult to overcome by the hypo-pancreatism. However, the fact that diarrhea is a fairly common gastro intestinal symptom of hyperthyroidism has been shown by Scorf who found that in a series of eighty cases of hyperthyroidism, twenty per cent had hypermotility of the gastro intestinal system as shown by the X-ray of the gastro intestinal system using the Barium meal technique. It may be stated here that Scorf believes that part of the weight loss occasionally seen in hyperthyroidism may be explained on the basis of hypermotility of the gastro intestinal tract and a consequent poor absorption of food substances.(78)

#### Nervous and Mental Symptoms

The mental symptoms found in toxic nodular goiter are on the whole somewhat milder than those found in

Grave's disease. The mental conditions as seen in toxic nodular goiter comprise a vast number of conditions. Katzenblogen and Lutton state that there is no specific type of psychosis associated with hyperthyroidism. They have found in cases that they have treated that the psychosis found most commonly are as listed below: schizophrenia, anxiety states, presenile psychosis, toxic delerium, agitated depression, senile depression, recurrent depression, mania, paranoid reaction, psychonerosis and epilipsy. From their study of the problem they make two conclusions: (a) Hyperthyroidism does not coincide specifically with any one type of psychosis. (b) That the content of psychosis associated with hyperthyroidism does not differ essentially form similar types without hyperthyroidism.(79)

The question as to whether hyperthyroidism is the primary causative agent in the mental conditions seen frequently with hyperthyroidism or wether the hyperthyroidism is the result of the mental disturbance has been the subject of a large amount of contraversy. Kaiser has found that frequently persons with an autonomic umbalance show an emotional tension and present the clinical symptoms of thyrotoxicosis. These



individuals show tachycardia, weight loss, palpitation and even raised basal metabolic rate. However, the thyroid is normal.(80) Stoddard has shown that the physical signs of hyperthyroidism with the exception of exophthalmus are identical with the symptoms manifested by normal persons expressing fear.(81) Pottinger states that emotional and psychic stimuli influence cellular activity the same as cellular action and claims that the hyperthyroidism can be caused by an autonomic upset.(82) Ginsburg's beliefs may be expressed in the following excerpt from an article on thyrotoxicosis stimulating primary neurosis: "A depressive psychosis may develop in the course of a thyrotoxicosis, not as a mere casual phenomena but definitely dependent upon the toxic products. The condition has cleared up and failed to recur when the thyrotoxic condition was cured."(83) Woodbury, however takes a different viewpoint on the question and claims that it is impossible to assign to the thyroid any basic causative role in psychosis. It may, however, aggravate a preexisting psychosis or it may precipitate a psychosis in a susceptible individual. (84) Dunlap and Moersch in a study of fifty cases of mental disease and hyperthyroidism suggest that there is

no connection between the two, other than a coincident one. Their figures based on 1,700 cases out of which fifty were suffering from hyperthyroidism show that there is very little relationship between the two.(85)

Crile has repeatedly emphasized the fact that there is a very important relationship between the thyroid adrenal and autonomic nervous system.(86) However, with our present knowledge of the condition, it is impossible to make a definite statement as to whether the hyperthyroidism is the etiological agent or the result of a psychic disturbance.

## BIBLIOGRAPHY

1. Brown, H. M. A review of the history of the disease known as goiter. Wisconsin Med. J. 16:240, 1917.
2. Norhen, A.H. and W.A. History of the thyroid. West. J. of Surg. 44:488-500, 1936.
3. Halsted, W. S. Operative history of goiter. Johns Hopkins Hospital Reports 19:71, 1919.
4. Parry, Caleb Hillier Elements of pathology and therapeutics, Vol.1. General Path, Bath, England R. Cruttwell, 1815.
5. Ginsburg, S. Toxic adenoma. Arch. of Int. Med. 44:73, 1929.
6. Marine, David Physiology and interrelations of Gull's disease. J. A. M. A. Vol.104, 2249-2256, 1937.
7. Wolfler Quoted by Halsted, see Ref. 3
8. Virchow Quoted by Halsted, see Ref. 3
9. Goetsch, E. Studies on disorders of the thyroid gland. Endocrinology, 4, 389, 1920.
10. Parsons, W. B. Jr. Adenoma of the thyroid. Ann. of Surg. 85:707, 1927.
11. Rienhoff, W. F. Jr. Involution of regressive changes in the thyroid gland in cases of exophthalmus goiter and their relation to the origin of the so called toxic adenomas. Arch. of Surg. 13:391, 1926.

12. Rienhoff and Lewis, D. Relation of hyperthyroidism to benign tumors of the thyroid gland. Arch. of Surg. 16:79, 1928.

13. Womach, N.A. and Cole, W.H. Normal and pathological repair in the thyroid gland. Arch. of Surg. Vol. 23:466-476, 1937.

14. Graham, A. Nodular goiters, their relation to neoplasia. Am. J. of Surg. 7:163, 1929.

15. Thomas, H. M. Nodular goiter with hyperthyroidism. Arch. of Surg. 16:117, 1928.

16. Hinton, J. W. Nodular goiter. Ann. of Surg. 95:499, 1932.

17. Hertzler, A. E. Pathogenesis of goiter considered as one continuous disease process. Arch. of Surg. 16:61, 1928.

18. Marine, D. and Lenhart, C.H. Colloid goiter. Bull. Johns Hopkins Hosp. 20:131, 1909.

19. Rienhoff, W. F. Jr. Gross and microscopic studies of the thyroid in man. Arch. of Surg. Vol. 19:986, 1929.

20. Plummer, H. S. Surgical pathology of the thyroid gland. Philadelphia, Pa. J.B.Lippincott Co. 1936.

21. Marine, David Pathogenesis and prevention of simple endemic goiter. J. A. M. A. Vol. 104:2334-2340, 1935.

22. Williamson, G.S. and Pearse, I.M. Structure of the thyroid gland in man. *J. Of Path and Bact.* 26: 459-469, 1923.

23. Key, J. A. The secretion antecedents and mitochondria in pathological thyroids. *Arch. of Surg.* 11:254, 1925.

24. Goetsch, E. Functional significance of mitochondria in toxic thyroid adenomata. *Johns Hopkins Hosp. Bull.* 27:129, 1916.

25. Loeb, Leo. Studies in compensatory hypertrophy in the thyroid gland. *J. of Med. Research Vol.* 40:199, 1919.

26. Goormaghtigh, N. and Thomas, F. The functional reaction of the human thyroid. *Am. J. of Path.* Vol. 10:713-729, 1934.

27. Norris, E. H. The morphogenesis of the follicle in the human thyroid gland. *Am. J. of Anat.* 20:411-416, 1916.

28. Hertzler, A. E. Mixed tumor of the thyroid gland. *Arch of Surg.* 16:1187, 1928.

29. Murray, I. The thyroid gland in the full-time fetus and in the newly born infant. *Brit. Med. J.* 1:5, 1927.

30. Boyd, W. *Surgical pathology*  
W.B.Saunders and Co. Philadelphia, Pa, 1929.

32. Boyd, W. The identity of adenoma of the thyroid. *Tr. A. M. Phys.* 47:268, 1932.

33. Marine, D. and Lenhart, C.H. Pathological anatomy of the human thyroid gland. Arch. Int. Med. 7:506, 1911.
34. Kielty, R. A. The inflammatory nature of nodular goiter as a chronic thyroiditis. Am. J. of Clin. Path. 11 57-68, 1931.
35. Broders, A C. Surgical pathology of the thyroid gland. Texas State Med. J. 31:608-615, 1936.
36. Wilson, Gale Thyroid follicle in man. Anat. Rec. 37:31-61, 1927.
37. Goitsch, E. Pathology of goiter. Northwest Med. J. 21:97, 1922.
38. Collier, F. A. Adenoma and carcinoma of the thyroid gland. J. A. M. A. 92:457,462, 1929.
39. Marine, David and Bowman, E.J. Further studies on the etiology of nodular goiter. Tr. Am. Phys. 47:261-267, 1932.
40. Means, J. H. The thyroid gland and its diseases. J.B.Lippincott Co. Philadelphia, 1937.
41. Jackson, J. W. Shape and size of thyroid follicle in health and disease. Anat. Rec. 48:219, 1931.
42. Hertzler, A. E. Surgical pathology of the thyroid gland. J.B.Lippincott Co. Philadelphia, 1931.

43. Wilson, L. B. A study of pathology of thyroids from cases of toxic non-exophthalmus oiter. Am. J. of Med. Sc. 147:344-351, 1914.

44. Plummer, W. A. Symptoms due to gross hemorrhage into cystic adenoma of the thyroid. Minn. Med. 12:599-601, 1929.

45. Broden, A.C. and Plummer, W.A. Hemorrhage into advance of the thyroid. Am. J. of Surg. 23:63-69, 1934.

47. Kendall, E. C. The isolation in the crystalline form of the compound containing iodine which occurs in the thyroid. Trans. Ass. Am. Phys. 30:420, 1915.

48. Harrington, C. R. Chemistry of thyroxine. Biochem. J. 20:293-300, 1926.

49. Sloan, E. P. The thyroid. Charles C. Thomas, Baltimore, Md. 1936.

50. Murray, G. R. Life history of the first case of Gull's disease treated by thyroid extract. Brit. M. J. 1:359, 1920.

51. Marine, David The present status of the functions of the thyroid gland. Physiol. Rev. 2:521, 1922.

52. Smith, P. E. Effect of removal of the pituitary gland in tadpoles. Proc. Soc. Exper. Biol. & Med. 16:81, 1918-1919.

53. Collip, J.B. and Anderson, E.M. Production of serum inhibitory to the thyrotropic hormone. Lancet 1:76, 1934.

54. Burn, J.H. and Marks, H.P. Relation of the thyroid gland to the action of insulin. J. Physiol. 60:131, 1925.

55. Bodansky, A. Action of insulin on thyroid-ectomized sheep. Proc. Soc. Exper. Biol. & Med. 21:46, 1923.

56. Blau, N.F. and McNamara, H. Sympathetic activity after prolonged administration of thyroxin. Proc. Soc. Exper. Biol. & Med. 27:997, 1930.

57. Foss, H. L. The heart in toxic goiter. Penn. Med J. 39:671-681, 1936.

58. Rankin, F. and Grimp, A. E. Cardiac manifestations of hyperthyroidism. Kentucky Med. J. 34:509-513, 1936.

59. Hurxthall, L. M. The thyrocardiac. Surg. Clin. N. Am. 16:1533-1536, 1936.

60. Stewer, L. G. Complete heart block in hyperthyroidism following acute infection. Am. Heart J. 9:81, 1923.

61. Davis, A.C. and Smith, L.H. Complete heart block in hyperthyroidism following acute infection. Am. Heart J. 9:815, 1923.



63. Levine, S.A. and Cutler, R.H. and Eppinger, E. C. Total thyroidectomy in the treatment of congestive heart failure and angina pectoris. New England J. of Med. 209:667, 1933.

64. Yates, W. M. The tachycardis, time factor, survival period and seat of action of thyroxine in the perfused hearts of animals. Am. J. of Physiol. 98:338, 1931.

65. Markowitz, C and Yates, W.M. Response of embryonic heart muscle to thyroxine. Am. J. of Physiol. 100:152, 1932.

66. MacDonald, C. H. Work of the hyperthyroid Heart. Am. Heart J. 13:687, 1937.

67. Lewis, J.K. and McEachern, D. Investigation of lactic acid metabolism in hyperthyroidism. Trans. Assoc. Am. Phys. 18:65-75, 1934.

70. McEachern, D. Metabolism of isolated surviving tissue from animals rendered hyperthyroid with thyroxine. Bull. Johns Hopkins Hosp. 56:145, 1935.

71. Langley, H. and Kato, J. Effects of increased muscular tonus on basal metabolism. Am. J. of Physiol. 18:432, 1915.

72. Andrus, E. C. & McEachern, D. Nature of increased metabolism in hyperthyroidism. West. J. of Surg. 45:16-26, 1937.

73. Wohl, M. G. The increased sensitivity of the gastro intestinal tract to epiniphrin in hyperthyroidism. Med. Clin. N. Am. 14:1017, 1931.

74. White Quoted by N. G. Maddock and F. A. Collins. Thyroid crisis, its relation to liver and adrenals. West. J. of Surg. 44:513-521, 1936.
75. Timme, W. Discussion of thyroid disturbances. J. A. M. A. 97:515, 1931.
76. Smithes, F. Discussion of thyroid disturbances. J. A. M. A. 97:515, 1931.
77. Edmonds Quoted by Smithies in above article.
78. Scorf, M. Gastro intestinal manifestations of hypertension. J. of Lab & Clin. Med. 21:1253-1258, 1931.
79. Katzenelbogen, S. and Lutton, F. H. Hyperthyroidism and psycho-biological reactions. Am. J. of Psychiatry 91:968-982, 1935.
80. Kaiser, N. W. The thyroid factor in mental disease. Ohio State Med. J. 31:430-436, 1935.
81. Stoddard, W. The mind and its disorders. P. Blakiston & Co, Philadelphia, 1922.
82. Pottenger Symptoms of visceral disease. C. V. Mosby Co, St. Louis, Mo., 1922.
83. Ginsburg, S. Marked thyrotoxicosis simulating primary newrosis. J. of Nervous and Mental Diseases 76:331, 1932.
84. Woodbury, M. S. The psycho-neurotic syndrome of hyperthyroidism. J. of Nervous and Mental Diseases 47:401, 1918.

85. Dunlap, H.F. and Moersch, E.P. Associated  
psychic manifestations in hyperthyroidism.  
Am. J. of Psychiatry 91:1215-1228, 1935.

86. Crile, George The neuroglandular system.  
Am. J. of Med. Sc. 189:276-280, 1925.