

5-1-1938

Ophthalmoscopic study of the fundus in cardiovascular disease

Roy M. Matson
University of Nebraska Medical Center

This manuscript is historical in nature and may not reflect current medical research and practice. Search [PubMed](#) for current research.

Follow this and additional works at: <https://digitalcommons.unmc.edu/mdtheses>



Part of the [Medical Education Commons](#)

Recommended Citation

Matson, Roy M., "Ophthalmoscopic study of the fundus in cardiovascular disease" (1938). *MD Theses*. 677.

<https://digitalcommons.unmc.edu/mdtheses/677>

This Thesis is brought to you for free and open access by the Special Collections at DigitalCommons@UNMC. It has been accepted for inclusion in MD Theses by an authorized administrator of DigitalCommons@UNMC. For more information, please contact digitalcommons@unmc.edu.

AN OPHTHALMOSCOPIC STUDY
OF THE FUNDUS
IN CARDIOVASCULAR RENAL DISEASE

by
Roy M. Matson

Senior Thesis Presented to the
College of Medicine, University of
Nebraska, Omaha, 1938.

CONTENTS

	Page
I. Introduction-----	1
II. The Ophthalmoscope-----	2
A. History	
B. Principle	
C. The Diopter	
III. Types of Ophthalmoscopes-----	4
A. Electric	
B. Stereoscopic and Polarizing	
C. Restricted Light	
IV. Ophthalmoscopic Examination-----	6
A. Direct	
B. Indirect	
V. Anatomy of:-----	10
A. Papilla	
B. Retina	
C. Chorioid	
VI. Normal Fundus-----	15
A. Types	
1. Uniform Stippled	
2. Tesselated	
3. Albinotic	
B. Ophthalmoscopic Study	
1. Papilla	

480955

2. Retinal Vessels	
3. Macula	
4. Chorioid	
VII. Common Anomalies of Fundus-----	20
A. Of Papilla	
B. Of Retina	
C. Of Chorioid	
VIII. Types of Retinal Arteriosclerosis-----	23
A. Normal Retinal Vessels	
B. Senile Sclerosis	
C. Syphilitic Arteriosclerosis	
D. Hypertension without Retinal Arteriosclerosis	
E. Hypertension with Retinal Arteriosclerosis	
F. Complications of Hypertension with Retinal Arteriosclerosis.	
G. Retinal Arteriosclerosis without Hyper- tension	
IX. Types of Hemorrhages and Exudates Observed in Retinitis-----	48
X. Ocular Fundus in Hypertension-----	51
XI. Ocular Fundus in Nephritis-----	54
XII. Ocular Fundus in Diabetes-----	57
XIII. Conclusions-----	61

INTRODUCTION

-1-

Dr. Harry Friedenwald in his Doyne Memorial lecture in 1930, states: "Nowhere else in the living body are we able to study the blood vessels of the size of the central artery and its branches to the finest arterioles than in the fundus. The man with the ophthalmoscope is impressed by its importance in the recognition of the early signs of general disease and of its general diagnostic and its prognostic value. But its greatest value lies in the possibility it affords to help solve the problems that have so long baffled medical science, in the search for ultimate causes of conditions that are so common, so varied in their manifestations and so serious in their course." (39) Nowhere else is our duty so imperative to study the minutest details of the picture, as in the vessels of the retina, because they are offshoots from the vessels of the brain, and certain conclusions can be drawn from their condition with reference to that of cerebral vessels.(1) The appearance of the blood vessel walls afford some excellent insight into the past, an explanation of the present, and a glimpse into the future.(44)

HISTORY OF THE OPHTHALMOSCOPE

-2-

A. The ophthalmoscope was invented by Helmholtz in 1851. It brought about an important event in general medicine by enabling one to explore the interior of the eye and study lesions about which we previously had little knowledge during life. Of equal importance is the ability of recognizing changes in the fundus that make up valuable signs in diagnosing systemic diseases.(64)

B. The essential principle of the instrument is a perforated mirror. It is mounted on a convenient handle and supplemented behind by a disc containing concave and convex lenses. The mirror reflects light into the interior of the eye while the perforation allows a part of this light to pass into the eye of the observer after returning from the patients eye. The lens disc supports a series of lenses arranged successively from stronger to weaker. Any of these can be brought opposite the perforation by applying the finger to the milled edge of the disc. Opposite each lens a number indicates its strength in diopters.(20)

C. The unit of lens measure is the diopter. By international agreement a diopter has been accepted as the strength of that lens which has its focus at a

distance of one meter. If the dioptric strength of a lens be known, its focal length can be determined by division into one hundred centimeters. The lens is spoken of as being plus or minus depending on whether it be convex or concave. The strength of the lens is in diopters in either case. In a normal eye the fundus can be studied through the aperture without any lens, but if the eye under examination be hypermetropic a plus lens is necessary; if it be myopic a minus lens is necessary for a clear view. (36)

TYPES OF OPHTHALMOSCOPES

-4-

The electric ophthalmoscope is self luminous, a small electric lamp is placed in the handle and its rays reflected into the patients eye by a reflector placed at a suitable angle. The current for the light comes either from a battery in the handle or a portable storage battery, or the house current through a rheostat. The type with the battery in the handle is the most convenient to use and may be carried by the general practitioner in his bag. The greatest advantage of the electric type is that the fundus can be studied by the direct method.

Other variations of the ophthalmoscope are the polarizing and the stereoscopic ophthalmoscopes. In the former the light is polarized by interposing nicol prisms. The result is a reflexless useful instrument for studying the macula through a small pupil. It was popularized in 1921 by Salomonson. The latter was introduced in 1861 by Giraud-Teulon. This is an instrument by which two similar pictures of the same object are made to overlap so that the images are seen as one, thereby giving a picture of solidity and relief. (64)

OPHTHALMOSCOPY BY RESTRICTED LIGHT

-5-

Ophthalmoscopes may be used in various ways. It has been found that by varying the types of light different parts of the fundus are brought out more readily than other parts. In 1903 Mayou found that by using a red free light the macula and retina could best be seen and studied as the chorioid does not show up with such a light. For the best study of the blood vessels, a yellow-green light differentiates them most readily. The red light which has the longest waves penetrates into the chorioid and shows up the pigment variations and, as a result, the fine pigmentary changes can be readily noted. (64)

OPHTHALMOSCOPIC EXAMINATION

-6-

According to W.N. Offut, the essentials for a good ophthalmoscopic examination are the full dilatation of the pupils by some mydriotic, the maximum illumination from the ophthalmoscope, the proper lenticular correction in the ophthalmoscope, and a working knowledge of the physiological variations, especially of the blood vessels. (61) With these essentials kept in mind we shall now proceed to the different types of ophthalmoscopy which are two in number, the direct and indirect.

A. The direct method of ophthalmoscopic examination is the method of choice in the United States. In this method the patient is seated with eyes directed forward, the examiner sits or stands facing him; usually at his right side if the right eye is to be examined and at the left side if the left eye is to be examined. If the ophthalmoscope without electric illumination is used a light is placed at the patients right side when the right eye is examined and at his left side when the left eye is examined. It is quite difficult to make a systematic examination of the eye without a working knowledge of the ophthalmoscope, but even if one be familiar with the latter it is still necessary to have a systematic method of examination to avoid

overlooking many important points. (36)

The method to be discussed here is the one where the examination commences from the anterior and proceeds posteriorly in definite steps. The first step is that of inspection. It should cover everything that can be seen without the use of instruments. A good light is essential. The cornea is the first structure to be examined. In general practice this is the seat of many eye involvements and should be examined carefully as for foreign bodies, ulcers, and opacities. The anterior chamber is next examined, as for opacities. The iris and pupil should be examined together. (64)

The second step is to take the patient to a dark room and with a plus twenty diopter lens of the ophthalmoscope, the light is focused onto the cornea into the anterior chamber, the iris, the pupil, and the lens; and these are then inspected the second time. If the source of trouble is not located the third step follows.

In this step the first structure to be examined is the lens. This is done by turning the disc so that a plus sixteen diopter lens is in position behind the aperture of the instrument. If the ophthalmoscope is about two and one-half inches from the patient's eye

it will be in focus and any opacity of the cornea, the anterior chamber, or the lens will appear black, because they are opaque. A beginning opacity of the lens as a cataract can be readily diagnosed by the ophthalmoscope.

The fourth step is an examination of the vitreous by looking through a plus eight diopter lens with the ophthalmoscope at close range. The patient is requested to look up, then down, and from right to left; if the vitreous be pathological black spots might be seen floating in it and a diagnosis made. If the vitreous be clear the fifth step follows.

This is a study of the fundus. For this the disc is rotated to approximately a plus or minus five-tenths diopter lens, depending on whether the patient be normal, myopic, or hypermetropic. The usual landmark in the fundus is that of the nervehead. It is studied with respect to its margin, its elevation, its vessels, and its size and color. The retinal vessels are next studied; they are studied in respect to reflex, size, color, tortuosity, crossings, change in number, and phenomena of pulsation. The macula is studied for its color, shape, size, and possible configuration.

By refocusing, the deeper structures of the fundus

may be studied as to the amount and type of pigmentation present and as to the vessels of the chorioid.

(36) (64)

B. The indirect method of ophthalmoscopy is used in the European countries and rarely in the United States; therefore it will be mentioned just briefly. The position of patient and examiner is practically the same as in the direct method except the ophthalmoscope is farther from the patient. By holding the ophthalmoscope about fifteen inches from the eye to be examined, a lens of plus sixteen to twenty diopters is held by the fingers of the examiner directly in front of the patients eye; by moving this lens back and forth a clear view of the fundus is obtained. The patient moves his eyes in various directions as in the direct method of examination. By indirect ophthalmoscopy the magnification of the fundus image is less than in the direct method, but a larger area of the fundus is seen at one time. (36) (64) (31)

NORMAL ANATOMY

-10-

A. Optic disc: The optic nerve enters the eyeball through the lamina cribrosa of the sclera medial to and a little below the posterior end of the optic axis and there forms the papilla.

The optic nerve is a portion of the brain that projects forward and is enclosed in three sheaths; the dura, the arachnoid, and the pia. The intraspaces of these correspond to those of the brain and connect with the lateral ventricles. The two outer sheaths pass over into the two outer layers of the sclera while the pia helps form the lamina cribrosa and connects with the chorioid. (31) (1)

The optic nerve is circular and 4 mm. thick. It is made up of nerve fibers and connective tissue. The nerve fibers run parallel to each other and number approximately five hundred thousand. They have a medullary sheath and are supported by neuroglia. The pial sheath that surrounds the nerve sends septa into it that carry lymphatics and blood vessels.

All of the optic nerve fibers are not of the same size but average 2 μ in diameter. The smallest supply the macula and make up the point of finest vision. They occupy the lower outer portion of the disc in the

form of a wedge. (1)

The lamina cribrosa is made up of numerous fibers of connective tissue at the inner surface of the sclera. They cut transversely through the nerve to form numerous meshes through which the nerve passes but now reduced to 1.6 mm. in diameter due to the loss of the medullary sheathes which occurs as the nerve enters the lamina cribrosa. (1)

The vessels of the papilla are the central artery and vein that come out of the physiological cup which in turn divide into a superior and inferior, which again subdivide into a medial and lateral; these subdivide many times and spread out over the retina. The lamina cribrosa is supplied by innumerable capillaries which are carried in by the connective tissue from the pia. These give color to the papilla. (1)

B. The retina is a grey cloudy membrane $\frac{1}{3}$ mm. thick. It is closely connected with the sclera in two places, at the optic nerve and at the fovea centralis. The pigment layer is in close contact with the chorioid when the retina is torn loose, but embryologically and physiologically it is a part of the retina. The macula lutea is the center of the retina and is yellowish with a dark brown central point, the fovea cen-

tralis. (1) (31)

The retina is transparent. Its presence is recognized only by the vascular contents in it, consequently the pigment of the pigment layer and not the retina makes up the color of the fundus.

There is an outer and an inner layer--the inner lies next to the vitreous humor and the more distant is the outer. The outer layer is composed of rods and cones while the inner portion of the retina makes up the cerebral layer. The retina is also attached to the chorioid at the ora serrata. (1) (31)

The nerve fibers are bundles of plexuses. They are seldom medullated; if they are they form white spots. The nerve fibers radiate from the papilla but those from the temporal side make an arch about the macula. The macula itself is supplied by extremely fine fibers from the temporal margin of the disc.

The macula is approximately 4 mm. lateral and inferior to the papilla. It is ordinarily transversely oval and 1.7 to 2 mm. in diameter. The margins are slightly raised and the center depressed to be called the fovea centralis. The cones increase at the expense of the rods in the center of the macula. Toward the periphery the rods increase and the cones

decrease but both cease at the ora serrata. (1) (31)

Nutrition of the retina is from the central artery and from the chorioidal vessels that supply the cerebral layer. The branches of these vessels are always covered by some nerve fibers. The fovea centralis is without blood vessels but the capillary network from the retinal vessels lie at its margin. (1) (31)

C. The chorioid is connected loosely with the sclera, quite firmly with the pigment layer of the retina, and consists chiefly of vessels; it varies from .05 to .08 mm. at the ora serrata to .01 to .02 mm. at the posterior pole. The vascular supply is through the ciliary vessels from the ophthalmic artery and furnishes the vessels that supply the outer layers of the retina and the macula. (1)

The chorioid makes up two unequal portions, depending on the arterial supply. The posterior which is the larger extends from the papilla into the equator, while the anterior which is the smaller extends from the equator to its transition into the ciliary body. The posterior is supplied by the posterior ciliary arteries and is the main blood supply. The anterior is supplied through the recurrent branches of the long posterior arteries. The equator has the poorest

blood supply and consequently is often the first location of pathology. (1)

The veins are more numerous than the arteries. They usually leave at the equator in four to six large vessels and in highly myopic eyes leave at the posterior pole. The vessels of the chorioid are flat, they have no light streaks, they divide unevenly, they have many anastomosis, and they have no uniform direction. Besides vessels the chorioid contains elastic fibers and pigment cells. (1) (31)

NORMAL FUNDUS

-15-

The color of the fundus is due chiefly to pigment, some to blood vessels, and some to visual purple. The pigment is found in the pigment epithelium of the retina and in the intravascular spaces of the chorioid. This distribution of pigment causes three normal types of fundi. (1) (31) (64)

A. Types: First, the uniform stippled fundus in which the uniform appearance is due to the pigment epithelium containing so much pigment that the underlying chorioid cannot be seen. In this type the color is red, brown-red, or black-brown, depending on the amount of pigment.

Second, the tessellated fundus in which the epithelial pigment is less. The underlying chorioid with its intravascular pigment can be discerned as well as its anastomosing vessels. The vessels appear as light bands on the black background.

Third, albinotic fundus in which the pigment epithelium practically lacks pigment; therefore the markings of the chorioid are more easily seen, but since practically no pigment is contained here either, the sclera shows through the retina and chorioid to give a whitish yellow background on which the chorioidal

vessels appear dark.

Some eyes may contain variations or combinations of all three types for in some areas one type is more pronounced than the others and the opposite is also true. The pigment is usually more concentrated next to the papilla even in the albinotic type. (1) (31())64)

B. Ophthalmoscopic study: 1. By means of an ophthalmoscopic study of the fundus, the disc is either circular or oval with the long axis vertical. The color is made up of red from the nutrient capillaries, and a glistening white from the nerve fibers. The whole produces a pinkish cream color of the disc but varying in different individuals. The effect of contrast also occurs, a well pigmented fundus making the disc appear whiter than it does in a blond.(31)

The surface of the papilla is not uniform in color. Proceeding from the edge towards the center we find that the border of the chorioidal opening varies from a light to a brownish grey and almost black; and it frequently marks the outer side by a dark pigmented crescent. The border of the sclerotic opening and the inner sheath of the nerve form a slender zone of glistening white. Just as the chorioidal opening varies in size and shape, the amount of sclerotic tissue

visible varies from a thin line to a well marked crescent that might be mistaken for pathology. (1) The general surface of the inner half of the disc is quite pink while the outer is much lighter by contrast and occasionally might be mistaken for beginning atrophy.

(1) In the center of the papilla is the depression called the physiological excavation. The center may appear white from the connective tissue that surrounds the central vessels.

2. The central artery leaves the disc near its center. It divides as it emerges into a superior and inferior branch which in turn repeatedly subdivide and spread over the entire retina except the macula. The corresponding veins enter the disc separately a short distance apart; sometimes there are two to each artery. They are about $\frac{1}{3}$ larger than the arteries and their course is more tortuous. (31) In some persons pulsations can be seen as the veins enter the disc, but pulsations in the artery are visible only in pathology. (1) A few small vessels are derived from the short ciliary arteries and pierce the disc to radiate onto the retina.

The vessels are fine transparent tubes filled with blood. The light falls on them so that their centers

are bright and shining, which is more readily seen in the arteries. It is essential to be able to distinguish the arteries from the veins especially for the purpose of studying pathology. The arteries differ from the veins in that they are smaller, a bright red, almost scarlet, a bright central streak that is well marked, a fairly straight course, usually cross over the veins, and pulsations are rarely seen; while the veins are larger, a dull red, a color that is more uniform, a more tortuous course, usually cross under the arteries, and pulsations are readily seen. (1) (44) (61)

3. The macula is difficult to see; it is situated at the posterior pole of the eyeball about two disc diameters lateral to the disc. It is generally oval, duller than the surrounding fundus and lacking in visible vessels, but pink from many capillaries. In the center by close observation a definite small spot can be distinguished which is the fovea centralis. (31) (64)

4. The chorioid if the pigmentation be not too heavy gives the fundus a tint of red from its extensive vascular supply. Normally it varies from a dull pink in the blond to a dull purplish red in the brunette.

The details of the inner layers cannot be seen. But in the tessellated fundus which has already been discussed the pigment layer causes the surface of fundus to appear granular. The degree of pigmentation influences appearance of the deeper layers of the chorioid. (20)

ANOMOLIES OF THE FUNDUS

-20-

It sometime occurs that some structures are not normal in appearance and are not pathological but may appear so if one be not aware of them. These are the anomolies. The first of these to be considered is not in the fundus but in close relation to it, namely the vitreous humor. During fetal life the hyaloid artery, which is a branch of the central artery of the retina, passes through the vitreous to provide nutrition to the developing lens. Around this vessel is a canal called the hyaloid canal; which ordinarily disappears at five or six months of intrauterine life. If it be not absorbed it usually detaches from the lens and floats in the vitreous humor. Remanents of the artery itself are seldom seen and if present appear as dark lines running anteriorly through the vitreous. (10)

A. Of papilla: The medullated nerve fibers are a congenital condition in which the nerve fibers are not deprived of their medullary sheaths as they leave the lamina cribrosa. This causes the appearance of white flame shaped radiations, extending outward from the disc margins. The appearance of opaque nerve fibers is outstanding and might possibly lead to an error in diagnosis. (1((20) (10)

The coloboma of the papilla is infrequently seen. It appears as a depression in a part or in the whole of the optic disc with apparant elevation of portions or all of the periphery. It is a pale blue color with a definite border of pigmentation. The neighboring structures may not show any defect. (10)

In congenital cupping the physiological excavation is deeper than usual and may appear as the cupping of glaucoma. But in the former, the excavation does not extend to the disc margin as in glaucoma and neither are there visible arterial pulsations. (10)

B. Of retina: The presence of cilio-retinal vessels has been considered by some to be a congenital anomoly. According to Elschnig they occur in every seventh eye. They might be seen emerging from the border of the papilla and extend into the retina. Ordinarily they are of large size with little luster and no reflexes. (10)

The congenital arterio-venous aneurism of the retina was first reported by Fuchs. This is rarely seen and is composed of an anastomosis between an artery and a vein. The most common vessels anastomosing are the superior temporal vein and the inferior temporal artery.

The coloboma of the retina is sometimes found with

the coloboma of the chorioid. In this case the retinal vessels are cut off short at the margin of the affected area. (10)

The coloboma of the macula occurs rarely. When present it appears as a large white depressed area not below but to the outside of the optic nerve in the region of the macula. (31)

TYPES OF RETINAL ARTERIOSCLEROSIS

-23-

In the ophthalmoscopic study of the fundus in cardio-vascular renal diseases as in the diseases of the kidney, there has been no unanimous acceptance of a classification by the ophthalmologists. However some men, as H. Friedenwald and J. S. Friedenwald, after studying two thousand cases have given us a classification that seems to cover the field quite efficiently. Also F. Gipner, after six years of intensive study on this subject has given us a classification quite similar to that of the Friedenwalds. H. Friedenwald suggests that if in all cases the same type of an ophthalmoscope were used and the pupils under observation were of approximately the same dilatation, there would be more unanimity of opinion as to the findings of the lesions in the fundus and their classification. The study of cardio-vascular renal diseases will be discussed according to these two classifications. (39) (44)

A. Normal retinal vessels: In the healthy young or middle aged adult the caliber of the artery and vein is regular with no tendency to alteration of the lumen, even at the arterio-venous crossings. At these points the normal translucency of the artery permits one to see the blood column as a shadow on the vein

below. (44) The normal retinal vessel walls are transparent; it is the blood contained within them that makes the vessels visible; the deeper the vessel the darker they appear in color. The color of the artery is dependent on the amount of blood it contains. Thus in severe anemia and heart failure the arteries appear to be pale and thin. (4) In respect to the relationship of the arteries to the veins, the central artery and its branches are approximately two-thirds to three-fourths of the diameter of the central vein and its branches. (1) (44)

In young patients the fundus is characterized by light reflexes of varying intensity, due to the smoothness of the retinal surfaces. (4) The size of this reflex is quite constant in different normal fundi if the same ophthalmoscope be used and the pupils be of about the same size. (39) On the arteries it is usually brighter, more intense, narrower, and more sharply defined than on the veins. The more superficial the vessel the more distinct the reflex. In lowered blood pressure the reflex broadens and in elevated blood pressure it narrows. (1) The width of the arterial reflex is closely related to the width of the blood column. (40) As the vessels course at different depths, the reflex

is useful in the determination in the difference of level; for at any change of elevation, no matter how slight, the reflex disappears where the bend takes place. (1) The cause and origin of the reflex is still a debatable subject, but the concensus of opinion seems to indicate that it comes from the perpendicular surface of the blood column. (82)

In the normal vessels of the fundus it is common to observe venous pulsations. The best point of observation for such is where the vein descends into the excavation; the blood column seems to be driven backward towards the periphery with each stroke. The venous pulsation is normal in the eyes of the young but if present in the aged or if absent when pressure is applied on the eyeball it suggests pathology. The arterial pulse is normally absent and if present it is pathological. (1)

B. Senile sclerosis: Normally the aging sclerotic process of the retinal arteries is very slow. (5) After sixty years of age most people show loss of some translucency, and there is thickening with narrowing of the retinal arteries. If this be absent it is an exception. (44) Histologically this thickening of the wall is connective tissue growth, and an increase of

the elastic elements while the endothelium remains unchanged. There is no actual reduction in the blood vessel lumen but the appearance of such must be caused by the decreased transparency of the walls so less of the blood stream is seen. (76) However, there are some people who reach very advanced age and still retain normal retinal vessels consequently any sclerotic process in the retinal vessels is considered pathological. (4) This condition is not associated with any irregularity of the lumen of the arteries and its presence in the chorioidal vessels show through the senile retina as mild chorioidal sclerosis. (44)

Senile sclerosis may be associated with senile atrophy of the optic nerve. It effects vision usually only when it becomes sufficiently advanced to interfere with the nutrition of the retina. (79) In old people a low degree of non inflammatory atrophy of the optic nerve sometimes occurs, caused by atheromatous disease of the larger vessels. (31) An excess of colloid bodies may present a picture of senile central spotted chorioretinitis. (44)

In premature senility the retinal arteries show advanced sclerosis. Those persons that show senile sclerosis between forty and sixty are not as likely to

reach old age as those who do not show it at this time.

(4) There might be a slight compression of the veins at the arterio-venous crossings, or it might be absent. However vascular hypertension usually is not present in this condition. (44) The average blood pressure elevation is from 150 to 160 systolic to 80 to 90 diastolic. Any higher blood pressure is caused by a complicating essential hypertension. (4)

C. Syphilitic arteriosclerosis: This condition is an endovasculitis of patchy distribution which may affect only one or two of the vessels of the retina, and it may be present in only one eye. (39) It is sometimes compared to atheroma of the larger vessels of the body. The caliber of the arteries and veins are quite normal in appearance, but the reflex stripe is unevenly exaggerated. (44) Circumscribed bulky white exudations may occur along the large blood vessels to form white lines or may occur in the region of the macula. (31) At one or more points along the arteries the lumen are markedly constricted, and there might be present a complete obliteration due to endarteritis obliterans. In these areas new vessel formation and collateral circulation are often seen. (44) Beading of the vessels when present is due to the fatty degeneration of the

nodules of the proliferated subendothelium. In the macular area the small arteries may show corkscrew tortuosity, but these are rare and seen only in the late stages of syphilis. They might also be seen in the advanced cases of sclerosis from hypertension. They indicated extensive endothelial proliferation. (44)

When the thickened artery crosses the vein the compression is usually at right angles. When this type of sclerosis occurs it is believed to be due to endothelial damage as a result of the toxins circulating in the blood. Also, as a result of the latter, syphilis and tuberculosis present a similar picture of perivasculitis. (44) Perivasculitis is the process of sclerosis that follows partial or total occlusion, whereby the arterial wall may be replaced, covered, or lined on either side by connective tissue. (4)

In certain cases of cerebral syphilis there may occur an optic nerve atrophy preceded by an optic neuritis, which often presents an unusual picture that may have characteristic elevations of the papilla which extends outward on the retina. The elevation of the retina causes the margins of the papilla to be obscure. The peripapillary edema is a reddish-grey to a pure grey ring one to two papillary diameters broad and around

the entire nerve. An elevation of the papilla may not be present but any previous excavation may be filled in by edematous tissue. (1)

The first manifestations of syphilis involving the chorioid and retina are usually dark spots scattered about the fundus. These may be few in number but more often they are many. These dark spots tend to be round or oblong. The margins appear to be fringed. This fringed appearance of the chorioidal lesions is quite constant. In the large spots, due to de-pigmentation, small bare areas are seen. These are of a blue-white or yellow-grey color. Occasionally over these plaques the chorioidal vessels are atrophied and do not show up in the ophthalmoscopic picture, but in such cases the retinal vessels are readily seen coursing over the de-pigmented areas. (10)

Syphilis of the retina may appear as a diffuse exudate on the retina accompanied by lines of exudation along the vessels. These may spread out and have a white fluffy appearance or they might be elongated and feather-like. The latter type occurs in the retinitis proliferans of syphilis. When the chorioid and retina are involved at the same time it is called choroido-retinitis. If this occurs in numerous places and of

various sizes at the same time, the term pepper and salt fundus is used. (10)

The ophthalmoscopic study of syphilis is not definite. In discussing syphilitic arteriosclerosis Woltman in an abstract by Gipner stated: "because of the patchy non-uniform distribution of this type of sclerosis a patient with the clinical signs of advanced central nervous system arteriosclerosis may be observed to have retinal arteries that would not be considered abnormal for his age." (44) Friedenwald in his discussion on syphilitic arteriosclerosis states that syphilis produces nothing distinctive in the retinal vessels, that the scattered vascular lesions are only suggestive; that they are not found in Tabes of Paresis but are found fairly often in the central nervous system type of syphilis. (39)

D. Hypertension without arteriosclerosis: In the classification of Friedenwald he includes in this group essential hypertension, acute nephritis, mild toxemias of pregnancy, increased intracranial pressure, cardiac decompensation with transitory hypertension, and hyperthyroidism with high systolic pressure. In the essential hypertension class he includes those individuals of advanced years with beginning hypertension that usually

show at the onset at least, no retinal arteriosclerosis. This class will be discussed more later. The acute nephritis included here is that which maintains the high blood pressure for only a short time. The cardiac decompensation with transitory hypertension is self explanatory. In hyperthyroidism, when the condition be corrected, the vascular disturbance returns to normal. He includes only the mild toxemias of pregnancy and not those which do not return to normal after the uterus has been emptied. In brief, he includes only those cases of hypertension, with the exception of hyperthyroidism, that extend over only a brief period of time. (39) Wagener states that he believes that if a blood vessel be in a constricted condition for ten days or more its walls undergo changes which cause it not to return to normal. (78)

In the group just mentioned the eye grounds are normal, or at most show slight arterio-venous constriction. (39) Although not definitely proved, yet the belief seems to be growing that the cause of the hypertension in the essential, in nephritic, and in the toxemias of pregnancy is of an angiospastic nature. (70) These spasms are segmentary contractions of the muscular coat of the artereolar walls. It might be found

transient in young patients without pathological significance. It may result in complete or partial closure of a vessel. When closure is complete a picture of blocking of the central artery is produced with ischemia, disappearance of the arteries, and a cherry red spot in the macular region. It may cause temporary loss of the visual field, depending on whether a main branch or one of the subdivisions be involved. However in hypertension spasms are fortunately incomplete, although complete spasms with loss of vision have occurred. A segmentary partial spasm may be found near the optic disc or anywhere along the course of the vessel. At the site of the spasm the artery fades in color and outline. The fading usually comes and goes; the spasm does not show any sharp demarcation at either end or laterally. The length of the spastic segment might be one-half of a disc diameter or more. Distal to the spasm the artery becomes flat, narrow, and pale. When the spasm is nearly complete the current of blood distal to it may show interruptions of white. In early cases of essential hypertension, before the actual spasm occurs, an entire arterial branch may have an unsteady faded appearance, showing segmentary inequality in intensity of color so that the outline cannot be sharply

focused. This type of unsteadiness may imitate very closely a peristaltic motion. This might be called a prodromal sign of hypertension. (4)

In a group of thirty patients with essential hypertension, Selinger found all had inequality of caliber of the retinal arteries, of these, twenty-two had tonic spasm together with an intermittent spasm of one or many medium sized to larger branches of the central artery. In another group of nineteen patients with symptoms of toxemia of pregnancy, he found that all but one showed intermittent or continuous spasm of the smaller, medium sized, or larger branches of the retinal artery. The intermittent were more common by a ratio of seventeen to two. (70) The presence of intermittent spasms facilitates the diagnosis and makes it more certain. Only a segment of an artery or several large branches may be affected. They are an almost constant accompaniment of toxemia of pregnancy and together with other retinal changes are of great prognostic importance. (70)

Vascular changes may be an indication of the action of an irritating substance on the vaso-motor system and thus be on the basis of a systemic disorder as seen in

the toxemias of pregnancy, in essential hypertension, in nephritis, and in other conditions. In such cases they are usually bilateral. However, they may also be the result of local action of toxic substance directly on the musculature of the arteries, as might be seen in the purely local disorders of the eye. In these cases they are unilateral. (70)

The differentiation of the true spastic variations in caliber must be made from the shift in vessel reflexes and the variations in the caliber of the vessels that result from the obliquity in their course, or from the obstruction of part of a vessel by exudates. Furthermore arterial pulsations should not be mistaken for vessel spasms. The arteriosclerotic thickening of a vessel wall with its consequent narrowing of the lumen may be mistaken for a spastic variation in caliber.(70) However, by close observation other pathological findings will aid in the differentiation between arterial spasms and the other disturbances mentioned.

E. Hypertension with arteriosclerosis: Essential and malignant hypertension, sometimes classed as nephrosclerosis, judging by the ophthalmoscopic study should be deemed identical--the difference being one of severity and progress. (26) (7) The line of demarcation

between essential and malignant hypertension is difficult. (7) The malignant differs from the benign by having a persistently high blood pressure and a more rapid course. It also may be the end result of the benign type. Hypertension with sclerosis usually occurs in elderly persons but may occur in younger individuals, and when it does it is of a more serious consequence. (39) Advanced cases of hypertension invariably show vascular retinal lesions; while early mild cases almost always show normal fundi. Retinal changes do not occur in renal disease unless hypertension be present. (68)

In vascular disturbances as arteriolar kidney disease, the high blood pressure is primary; the renal change is secondary and a part of a generalized arteriosclerosis. Furthermore, in nephritis there is evidence of vascular inflammatory changes throughout the body of which, the lesions in the kidney are only a part and occur subsequently to the rise of blood pressure.

(42) In general, arteriosclerosis may be said to follow hypertension with two exceptions, first, essential hypertension occasionally occurs for years without visible changes in the retinal arteries, and second, hyperthyroidism with high systolic pressure which also

may be present for a long period of time without vascular changes. (40)

In both essential and malignant hypertension, spasms of the arteries seem to be the basis of all changes, although isolated spasms in the fundus without hypertension have been seen. Persistent and recurrent spasms are later transformed into permanent narrowings or constrictions at the site of the spasm. (4) Wagener states this change takes ten days or more, (78) and is probably caused by some secondary change in the intima, induced by nutritional disturbance. Constriction differs from spasm in that it has a definite and constant outline. (4)

If a complete spasm of a retinal artery occurs its continuity disappears or is broken, and the artery distal to the spasm disappears or becomes very narrow. The smaller branches below the spasm nearly always disappear but fortunately such a complete occlusion does not occur very often in essential and malignant hypertension. The spastic artery may return to normal but more often it is a permanent constriction; also some arteries may show many hour glass constrictions. In late stages, a perivasculitis may occur, which is a proliferation of the perivascular connective tissue that

may cover the vessel, line it on each side, or replace it. (4)

The course of the arteries is usually quite straight in hypertension and branch at acute to right angles. The arteriovenous crossings are definite with relative venous engorgement and tortuosity of the veins distal to the crossings. (4) (44) (39) The early shadow of the vein behind the artery at the point where they cross can no longer be seen. (61) Friedenwald pointed out that the arteries and veins have a common sheath at the crossing and suggests the obscuring of the venous shadow may be due to the artery pushing the vein back into the retinal tissue as well as the increased density of the vessel wall. He also found that at the point of crossing the extension of the sclerotic process could be traced from the artery to the vein. (39) Tortuosity of vessels that occur is such a variable factor and so often structural in nature that it is unwise to use this as a guide in forming an opinion. Tortuosities of large arterial branches are usually congenital. Tortuosities of small branches are secondary to prolonged hypertension. (4) (39) (44)

The arteriovenous crossing is called Gunn's phenomenon. It appears early and is the only index of exist-

ing hypertension. It is the pressure effect of a hypertensive artery crossing over a vein. This sign is dependent mainly on a high diastolic pressure. The vein becomes narrow or disappears just under the artery. The intensity of this sign is in proportion to the degree of pressure elevation. In essential hypertension it is present on the days when the blood pressure is high and absent when it is low. To be valid the sign must be uniformly demonstrated at all arteriovenous crossings. It is an indication of hypertension rather than of sclerosis. (4)

Ophthalmoscopically, the arteries in hypertensive sclerosis differs from the syphilitic sclerosis in that all branches are involved throughout their course, and no retinal branches appear to be normal even though the degree of sclerosis varies. (44) The outstanding feature in hypertension with retinal arteriosclerosis is the reduction in caliber of the entire arterial tree. With this picture a relationship between the degree of constriction and the blood pressure seems to exist. A rough measure of the blood pressure in this case is when the arteries are reduced to one-half their original size, the diastolic blood pressure is 119 mm. or more except when it is an early case of hypertension before the eye-

ground picture has had time to develop, than it is higher, or when an intercurrent disease has reduced the blood pressure as cardiac decompensation of malignancy, acute infectious diseases, and chronic pulmonary infection. (39)

The fine local variations in caliber of the arteries from constriction, that usually are seen, have associated with them fine irregularities in the light streak. The latter is secondary to the spasm and constriction, because constriction causes a decrease in the size of the blood column. Furthermore, since the arteriolar wall gets its nutrition from the blood within it, the decreased lumen induces a process of hyalinization. The vessel wall becomes thick, glassy, and straight; the caliber becomes smaller. As a result the artery is pale and glistening. The combination of reduced size, the fading of color, and the increased reflex causes a copper wire character. (4) Consequently in many cases, there is an increased visibility of the vessel wall. (4)

Further changes that occur in the retina are chiefly those of malignant hypertension, although the essential type does have hemorrhagic areas as the malignant but not to such an extensive degree. The late stages are more of a nueroretinitis that Wagener and Keith describe as a clinical entity while Volhard and Fahr des-

cribe it as a complication of chronic glomerular nephritis. The two pictures are typical and according to the present clinical standards both have been observed in patients with and without normal renal function.(44)

Keith and his associates describe malignant hypertension in four stages. The first stage is that of hyperemia with mild edema of the disc and peripapillary retina to the extent of five or six millimeters (61) with few superficial linear or flame shaped hemorrhagic areas which may be few or many, and cotton wool exudates. Bedell states that the most suggestive picture in hypertensive retinitis is the disc congested by increased fullness of the disc capillaries. The disc appears pink or even red. (14) According to Gunn the edema is due to an increased tightness of the artery that lessens the rapidity of the blood stream in the capillaries and veins with a tendency for the serum to escape into the tissues. The edema leads to a disturbance of arterial nutrition and to an increase of sclerosis. (61) The arterial constriction is to such an extent that the arteries cannot be followed to the periphery. (61) Histologically the most common finding in the vessels is an intimal thickening of theendaritic type with a variable degree of endothelial proliferation together with

an increase in the adventitia or media. (61) (54)

The second stage is one with the edema of the disc from one to six diopters (54) and edema of the retina which is more marked and extends into the macular region and the periphery. A continued hyperemia together with the hemorrhagic areas and cotton wool exudates become more numerous and are found farther away from the disc and in the deeper layers of the retina as well.

DeSchweinitz was the first to notice that in some arteriosclerotics there was the occurrence of corkscrew terminal arterioles, especially in the macular region.

A few hard white spots are seen near the macula which radiate out from the fovea as the spokes of a wheel.

(61) The hard white spots are composed of large phagocytic cells that have taken up and contain fats and lipoids. These cells come from the pigment epithelium and wander into the retina to phagocytize the droplets of fat and lipid contained in the supporting tissue of the retina, in the glial cells and Muller's fibers. (61)

The third stage is that of the edema receding from the peripheral part of the retina and instead of it there are small spots of proliferated pigment seen. Hard white spots begin to outnumber the cotton wool exudates because the edema plays a very little part in their

formation. (61) The hard white spots arrange themselves into imperfect star figures in the macular region. (54) However, Adams states that the stellate figure which is so commonly heard of is really an exception. The usual finding he states is single white spots (1) which dominate the picture. (61) Hemorrhagic areas become fewer and more peripherally located. The hyperemia of the disc is less evident and begins to fade. As retinitis progresses through these stages associated sclerosis of retinal arterioles increases due partly to perivascular thickening and gliosis from edema of surrounding retina. (54)

The fourth and final stage is where the disc becomes definitely pale and only blurring. This stage is very seldom reached because the patient usually dies in the second or third stage. The increased glial tissue remains as evidence of previous edema which some term secondary atrophy. There is definite perivascular thickening along the walls of many vessels of both veins and arteries. In the late stages of arteriosclerosis Moore noticed that the arteriovenous crossings were right angle compressions. In this stage atrophy replaces the edema of the retina and only a few residual small hard white spots remain usually in the macular region.

Spots of proliferated pigment are numerous especially in the macula and periphery. Patchy sclerosis of the chorioidal arteries is noticeable and occasionally a small hemorrhagic area is seen. (54)

In all cases of retinal arteriolar sclerosis studied by Friedenwald, they developed albuminuric retinitis if followed long enough and furthermore all cases of albuminuric retinitis that he studied showed arteriolar changes on ophthalmoscopic and histological examination. The clinical findings in both with and without albuminuric retinitis showed extremely high hypertension and sooner or later was associated with a rapidly progressing chronic nephritis. He states that we may conclude that retinal arteriolar sclerosis is closely connected with the etiology of albuminuric retinitis. (39)

F. Complications of hypertensive arteriosclerosis:

1. Occlusion of the central artery: This may be caused by a complete spasm of the artery which may or may not relax in time to prevent damage. The most common cause however is an embolus at the bifurcation of the central artery. The patient first becomes aware of this disturbance by sudden or complete blindness, which appears as soon as the artery is obliterated. Immediate ophthalmoscopic examination after this occurs shows

a complete arterial anemia of the retina. The large arteries become thin filaments and the small one invisible. The veins are not markedly contracted except on the papilla itself. The papilla appears pale. (31) Within a few hours as the retina loses its vitality it also loses its transparency, it becomes a milky white which is increased in the region of the papilla and macula. This opacity obscures the outlines of the papilla but the fine ramifications of the retinal vessels which ordinarily are not seen come into view in the vicinity of the fovea on the white background. (61)

The center of the fovea appears on the white background as a vivid red spot because the inner layers of the retina and the retinal cloudiness are lacking at this spot which causes a more pronounced contrast with the milky white adjacent tissue. Small retinal hemorrhages may occur in this region also. (64)

After a few days the interrupted blood stream may be seen slowly coursing through the main retinal branches. (61) It is believed that the cilio-retinal vessels may supply an anastomosis. When the blood returns, the reddened area of the fovea decreases in size. Later the macula flattens and yellow spots appear in the retina in front of or about the fovea. The optic nerve

assumes a white color of optic atrophy, and the arteries are like fine threads while the veins are narrow.

(14) Prognosis for vision is bad.

2. Occlusion of the vein: This condition is a thrombus which occurs proximal to the lamina cribrosa. The most frequent cause is retinal arteriosclerosis with high blood pressure. The point of occlusion is usually noted as being at the arteriovenous crossing where the artery places great pressure on the vein. The loss of vision is not as rapid as that which occurs in arterial occlusion. It is characterized by an enormous distention of all retinal veins; the arteries are so attenuated that they can scarcely be seen. (60) The disc margins are blurred and the color is increased. The blood escapes from the distended veins at many points so that the fundus is filled with scattered hemorrhages. These hemorrhages are usually flame shaped and located near the disc. These keep occurring repeatedly so that eventually the vision is reduced to blindness. Glaucoma is a frequent complication of this disturbance. (61) Prognosis for vision is bad.

G. Arteriosclerosis without hypertension: Thus far we have considered hypertension without arteriosclerosis and hypertension with arteriosclerosis. Now

we shall discuss arteriosclerosis without hypertension. Gipner, in his classification of cardio-vascular renal diseases, describes a senile sclerosis without hypertension as a clinical entity. Friedenwald in his classification uses arteriosclerosis without hypertension as a clinical entity. The difference between these two is that in Gipners classification, which was discussed under senile sclerosis, the lumen are smooth and regular while in Friedenwalds classification, which shall be discussed here, the lumen are rough and irregular and on the order of the nodular form of arteriosclerosis. Research by Kuffer shows that the latter is a common ancient disease. It is most commonly seen and most readily studied in the aorta but it is also very frequently found in the smaller arteries such as the coronary and the cerebral and to lesser extent in the medium sized arteries, while only occasionally it involves the arterioles and smallest vessels. (20) Examinations by O'Harre and Walker show that in this type of arteriosclerosis only eighteen percent show any change in the eyegrounds while in hypertensive patients sixty-eight percent of them show sclerosis in the retina.(62)

In this condition according to Friedenwald when any change occurs in the retina the eye grounds are

quite similar to those of arteriosclerosis with hypertension except that instead of the vascular tree being completely constricted the main arterial branches are full and tortuous. There are arteriovenous constrictions sometimes of considerable degree, visibility of the vessel walls, and variations in caliber from atheromatous nodules in the vessel walls, which are degenerative lesions of the intima and if calcification occurs it is of the media. The lesions bear no special relation to high blood pressure and are almost always found in older people. Sclerosis of the chorioidal vessels appear through the retina as in senile sclerosis described by Gipner. In an advanced stage of this type of arteriosclerosis there are scattered hemorrhages and white spots throughout the fundus. (39)

TYPES OF HEMORRHAGES AND EXUDATES OBSERVED IN RETINITIS

-48-

The observation of the retinal arteries is the first to be considered in an ophthalmoscopic examination, and the hemorrhages together with the exudates are of secondary importance, for if the former be normal the latter should not occur. However, if the vessels be pathological and hemorrhages and exudates have occurred, it will seem that the superficial hemorrhages appear to be in the nerve fiber layer of the retina, and are striate or flame shaped. (10) Superficial hemorrhages usually occur in the early stages of retinitis; deep hemorrhages usually occur in later stages of retinitis, which appear to be found in the internuclear layer and show up as round or granular red spots in the fundus. (44)

Massive hemorrhages with white exudate occur along the course of very distended veins whose blood flow has been obstructed by the crossing of sclerotic arteries and make up the typical picture of venous thrombosis. When the central vein is thrombosed, the disc is edematous and all the veins are swollen and tortuous while massive hemorrhages and exudates are scattered throughout the fundus. (60) The preretinal type of hemorrhages, which are chiefly macular, are rarely seen

in cardio-vascular renal diseases. (44)

The appearance of cotton wool exudates in the retina are as fluffy, soft, superficial white spots in the retina. Fuch's in his "Textbook of Ophthalmology" states that the cause of these are unknown, (31) but Gipner ventures the opinion that they might be due to varicose swollen degenerated nerve fibers. (44) They usually appear in the early stages of retinitis.

The deep type of exudates are divided into three groups: first , the massive sero-fibrinous exudate; second, the macular star; and third, the edema absorbing exudate. (44) The first or the massive sero-fibrinous exudate is found in all retinal layers and even in the sub-retinal layer. It causes flat detachment of the retina around the disc or a globular detachment of the lower retina. In the acute stages of retinitis, it appears first as edema of the disc and peripapillary retina, but in the later stages, as the retinal edema recedes, the exudative material becomes clumped into hyaline like masses, chiefly in the internuclear layer, and is ^{there} attacked by the granular phagocytic cells that become filled with lipoid material. Collections of these cells are responsible for the formation of the second group or macular star and the scat-

tered punctate edema absorbing exudates. (61) The macular star results from radiating traction folds of the retina in the macular region, because at the fovea the macula is more or less firmly attached to the chorioid. The granular cells and exudate fill the thickened folds of the retina, while in the lines of traction the retina is pulled relatively thin and is free from the phagocytic cells and exudates. (44)

The third group or edema absorbing exudates appear ophthalmoscopically as scattered small white angular spots in the retina, and when observed under the microscope, are histologically found to be made up of concentrated clumped fibrinous exudation and granular phagocytic cells. (55)

The hemorrhages and exudates of the types mentioned, which include the macular stars, may be seen in persistent choked disc, the neuroretinitis of nephritis, and the neuroretinitis of malignant hypertension, whether they be from the same cause or not. Therefore they offer very little in the differentiation of the diseases that come under the cardio-vascular renal group. (44)

THE OCULAR FUNDUS IN HYPERTENSION

-51-

The ophthalmoscopic study of the fundus in hypertension will be taken up in three groups: first, mild benign hypertension; second, the severe benign hypertension, which is a transition between benign and malignant hypertension; and third, malignant hypertension. In the mild benign type the arteries have a uniform constriction of their caliber and the lumen is quite regular, while the reflex is uniformly exaggerated.(39) The veins may be normal or relatively dilated with moderate venous compressions at the arterial crossings. The constriction of the arteries has been considered by some as a functional contraction of the vessels to resist the increased vascular tension, and by others as being due to an increase in the fibrous tissue of the artery walls. It is possible that both views are right with the functional contraction preceding fibrosis.(44) As the fibrosis increases, there is a generalized reduction in the caliber of the arteries together with areas of still further reduction in caliber, so that there is a generalized irregularity in the caliber of the retinal arteries giving the picture of hypertensive sclerosis. Gipner states that these patients usually have a diastolic pressure below 115 mm. with little or

no peripheral sclerosis, no signs of impairment of function in the heart, kidneys, or brain. (44)

The severe benign hypertension, which might be considered as being a prodromal stage of malignant hypertension, is characterized by the presence of hypertensive retinitis. The fundus shows marked hypertensive arteriosclerosis with hemorrhages and exudates. The presence of cotton wool spots does not necessarily signify a condition of nephritis. The diastolic blood pressure is over 115 mm.; there is well defined peripheral sclerosis with signs and symptoms that show an impairment of the heart, brain, and kidneys. (44)

The third group or malignant type of hypertension may occur in young adults with severe rapidly progressing hypertension or it may be superimposed on a chronic nephritis that has passed through the stages of hypertensive sclerosis into the hypertensive retinitis to develop edema of the discs, that is characteristic of this type of hypertension. (54) It has been observed that the intracranial pressure of these individuals may increase, this may be an explanation for the optic nerve swelling and the headaches complained of by these patients. (44)

According to Wagener all grades of retinitis,

whether they be mild or severe, run a characteristic course; consequently he has divided them into four stages. (75) In the first stage, the disc is hyperemic and edematous with the edema spreading into the peripapillary retina, while the superficial striate hemorrhages and the soft cotton wool exudates may be present near the disc. In the second stage, the nerve head is swollen higher and the edema becomes more widespread so as to involve the macular region. There are more hemorrhages and exudates, some of which are more deeply situated. By the time the third stage is reached the patients usually die. Here are found signs of recession of the edema in the peripheral retina. Black spots of proliferating pigment develop and the disc appears pale through the edema, due to atrophy. In this stage the hemorrhages are deep, the edema absorbing exudates and the macular star figures develop. Secondary sclerosis of the vessels around the optic disc together with chorioidal sclerosis are present. The fourth group is rarely seen. It is characterized by secondary optic atrophy. The entire disc has blurred margins due to connective tissue changes and perivasculitis, and retinal pigment spots are seen. (44)

THE OCULAR FUNDUS IN NEPHRITIS

-54-

In this ophthalmoscopic study of the fundus, nephritis shall be grouped into four groups: first, the acute and chronic glomerular nephritis; second, the nephrosis; third, the apparent nephritis of pregnancy; and fourth, the nephritis of arteriosclerosis, which Volhard and Fahr term nephrosclerosis and Wagener and Keith term the terminal stage of malignant hypertension. In the first and second groups which are the glomerular and tubular types of nephritis, there are no retinal changes except occasionally when there is some edema of the disc and retina. (39)

In the third group which is a pregnancy nephritis, but classed by some as a nephrosis, is a special form of nephritis. It may be severe in retinal manifestations but the termination of pregnancy causes it to immediately subside. (70) (77) In this group the retinal picture is chiefly one of retinal edema and also edema deep to the retina which may cause retinal detachment. In other respects it is very similar to the retinitis of chronic nephritis and appears simultaneously with high blood pressure. (78) The retinitis of pregnancy usually develops after several pregnancies and ordinarily does not occur with future pregnancies. (44)

Toxic neuronitis with central scotoma or complete blindness may be associated with the nephritis of pregnancy. After the retinitis has cleared away secondary retinal arteriosclerosis, secondary optic atrophy, and peripheral retinal pigment spots may be seen, if the retinitis has been severe and of long duration. The peripheral part of the arteries may be normal. Gipner places this type of arteriosclerosis under secondary arteriosclerosis in his classification. (44)

The fourth group is chronic nephritis associated with high blood pressure, and is a disease most commonly found in individuals from twenty to thirty years of age. (44) This may be divided into four stages. In the first and second stages there is an absence of hypertensive retinal sclerosis. In the second and third stages the edema becomes widespread and massive exudations into the retina takes on the appearance of snow bands around the disc and in the macular region. The color of the disc and fundus is pale from the associated anemia of chronic nephritis. (1) There may be present lobulated retinal detachment which is mostly in the lower retina. The macular star may completely form, because the edema and exudation extends far beyond the macular region. (44)

In the third and fourth stages optic atrophy and secondary sclerosis are present, but the peripheral part of the retinal arteries may be fairly normal in appearance, which is a little different than the typical picture of malignant hypertension. Some use this difference as a differential diagnosis between the end stages of malignant hypertension and the retinitis of nephritis. However, the retinal pigment spots that appear as the edema subsides, corresponds to the late stages of malignant hypertension. (44) Wagener states that in the terminal stages of chronic nephritis the papilla is pale, due to the anemia resulting from that disease, while in malignant hypertension the papilla is hyperemic and may be used in differentiating the two. (75) (80)

THE OCULAR FUNDUS IN DIABETIC RETINITIS

-57-

Folk and Saskin reported in 1935, after studying 150 cases of diabetes, that diabetic retinitis occurred in thirty-three percent of the cases. (38) Others report a lower incidence as twenty percent which is still of quite frequent occurrence. The reason for this type of retinitis has not been determined. Some as Friedenwald believe it is possibly a condition stimulated by glycosuria, (38) while others as Foster and Moore in 1917 (39) and Wagener feel that it is a result of arteriosclerosis, (74) although in some cases of diabetes no arteriosclerosis exists. (39) Friedenwald states, "we have gradually become more convinced that the characteristic lesions known as central punctate retinitis are primarily due to arteriosclerosis. The period of life being forty years or over, the frequent findings of punctate hemorrhages, the occurrence of retinal affection in many cases of diabetic gangrene, and the observation of mild vascular changes in many cases." (39) However, Sugita in 1923 and Jess in 1925 showed that combinations of local retinal lesions with hypercholesteremia could cause the development of white spots in the retina, as seen in diabetic retinitis. (39) Folk and Saskin are of the opinion that the incidence of sclerosis in diabe-

tes is only slightly increased and then only mildly. Furthermore if the patient be placed under proper treatment the occurrence of retinitis lessens and the amount already present improves. Throughout the course of the retinitis the optic disc appears normal or nearly normal. (38)

Wagener, Dry, and Wilder in 1934, after studying 1052 cases of diabetes, divided the retinitis of diabetes into five groups. (74) The first of which is hemorrhage. This occurs in the earliest and mildest type of diabetic retinitis in the form of tiny punctate hemorrhages which are usually in the dilated terminals of the macular region. These hemorrhages are deeply situated and round in shape. The second group is composed of hemorrhages with punctate exudates. This occurs later than the first group but still is early in the disease. At this period there are a few shiny irregular shaped punctate exudates that are deep to, above, or below the fovea in the macular region together with minute hemorrhages, as in group one. The term central punctate retinitis for this condition was introduced by Hirschberg in 1890. Similar exudates and hemorrhages may occur later in other parts of the retina, and they may tend to coalesce. The third group is a

still later stage in which there are hemorrhages and punctate exudates together with cotton wool exudates. As these exudates scatter over the retina the cotton wool patches that appear are typical of hypertensive retinitis and like them lay in the nerve fiber layer of the retina. They are probably dependent on complicating hypertension and angiospasm. In other cases exudate patches are more deeply located, they are more yellow in color and more chronic in appearance than the cotton wool patches. The latter maybe indicates more vascular injury than in the central punctate retinitis.

In the fourth group are hemorrhages or exudates associated with visible lesions in the veins. In certain cases there are marked disturbances of the veins. They maybe more or less dilated and appear cyanotic. In some, nodular dilitations with intervening constrictions suggest mural thrombi. Some sections of the vein may appear obliterated while other sections may appear ensheathed in a layer of heavy yellow-grey infiltration. These lesions are associated with large and very extensive hemorrhages.

Group five is composed of the lesions in the veins together with hemorrhage into the vitreous. Whenever hemorrhage into the vitreous occurs it is frequently

in association with diseased veins. The result is a sequel of bands of scar tissue that may form, and by means of this newly formed vessels proliferate into the vitreous, so as to look like the retinitis proliferans which is similar to tuberculosis and syphilis. Contraction of the scar tissue may result in a detached retina. (74)

CONCLUSIONS

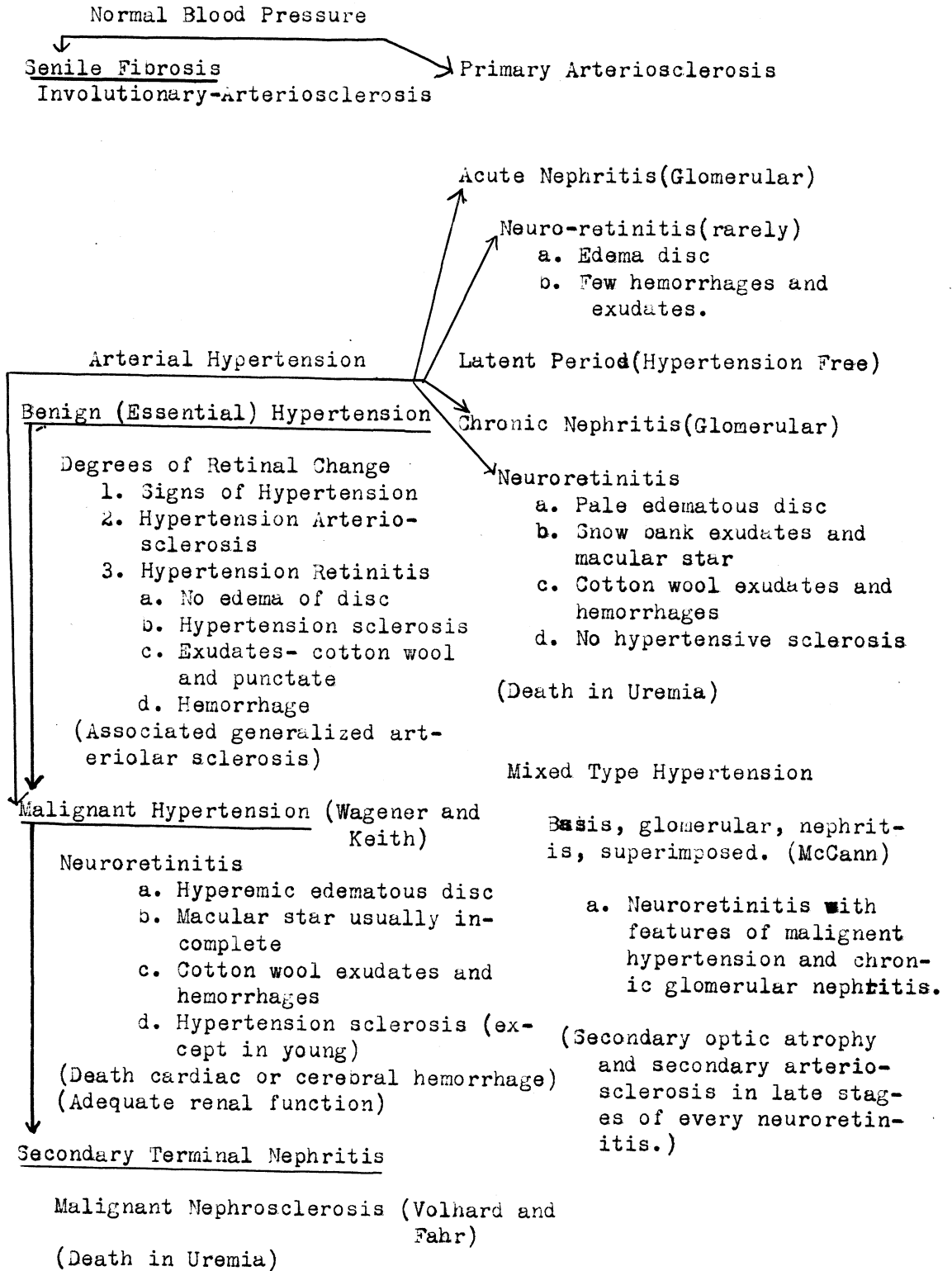
-61-

In conclusion, since the ophthalmoscope was invented by Helmholtz in 1851, a better understanding of the pathological changes in the body in disease, especially those effecting the cardio-vascular renal system, have been much better understood and treated. Nowhere else in the body is it possible to have an almost unrestricted view of the vascular system and its changes, than in the fundus. Here it is possible to study the vessels from the size of the central artery, which may show arteriosclerosis without hypertension, to the smaller vessels as the arterioles and capillaries, which show the changes brought about in hypertension and the resulting vascular sclerosis. A close and thorough study of the vessels of the fundus does give a fairly definite insight into the past, an explanation of what is going on at the present time, and a glimpse into the future in respect to the prognosis of the patient.

Of all vascular lesions, arteriosclerosis is the most common, the most important, and the most obscure. Only through the study of the vessels in the fundus of the eye has any explanation as to the cause of this disease been accomplished. The lesions of the arterioles which are associated with increased blood pressure and

often with cardiac hypertrophy, in the past could be studied to the best advantage only in the kidney, which was at autopsy; but with the advent of the ophthalmoscope it has been possible to study all stages of these vascular changes by direct observation of the vessels in the fundus of the living and sometimes apparently well individual. The rate of change, the degree of change, the effect of treatment and the prognosis of the patient can all be studied at the same time.

DIAGRAM



BIBLIOGRAPHY

1. Adams C.--Ophthalmoscopic Diagnosis, New York City, Ribman Co. 1913.
2. Adams P. H.--The Influence of Vascular Disease in the Retina on the Prognosis as Regards life, Brit. J. Opth. 1:161, 1917.
3. Adams P. H.--Arteriosclerosis and the Eye, Brit. J. Opth. 4:297, 1920.
4. Agatston S. A.-- Classification of Arteriosclerosis Based on the Ophthalmoscope, M. Rec. 145:23-27, Jan. 6, 1937.
5. Agatston S. A.--Changes in the Fundus as a Definite Index to Disease, Arch. Int. Med. 42:455, Oct. 1928.
6. Agatston S. A.--Experimental Hypertension and Retinal Arterial Spasm, Amer. Jour. Opth. 13:4, 309, April, 1930.
7. Agatston S. A.--Relation of Ophthalmoscopic Pictures to Arterial Disease, M. J. and Rec. 123:799, 1926.
8. Agatston S. A.--Fundus as a Definite Index to Arterial Disease with Analysis of 100 Cases, Arch. Int. Med. 42:455, Oct. 1928; Arch. Opth. 57:386 July, 1928.
9. Alt, Adolph--Ophthalmology for the General Practitioner, St. Louis, J.H.Chambers and Co. 40-42, 1893.
10. Atkinson, Taylor--The Ocular Fundus in Diagnosis and Treatment, Philadelphia, 1937.
11. Altnow H.O.--Changes in the Eyegrounds in Vascular Diseases and in Related Conditions, Arch. Int. Med. 40:757, Dec. 1927.
12. Bardsley P.C.--Retinal Signs of Arteriosclerosis Compared with Those Due Simply to Increased Blood Pressure, Brit. J. Opth. 1:239, 1917.
13. Bedell A. J.--Significance of Chorioidal Hemorrhages, Arch. of Opth. 8:186-208, Aug. 1932.

14. Bedell A.J.--The Significance of Some Changes in the Vessels of the Fundus, Arch. of Ophth. 4:695-719, Nov. 1930.
15. Behan J.L.--Fundus Changes in Nephritis, J.A.M.A. 78:1691-1694, June 3, 1922.
16. Benedict W.L.--Retinitis of Cardiovascular and Renal Diseases, Am. J. Ophth. 4:495-499, July, 1921.
17. Benedict W.L.--Retinitis of Acute Nephritis: Report of 6 Cases, M. Clinics N.America 5:275-288, Sept, 1921.
18. Benedict W.L.--Retinitis of Hypertension and Nephritis, J.A.M.A. 78:1688-1691.
19. Blackfan K.D. and Hamilton B.--Boston M. & S. 193: 617, 1925.
20. Boyd, William; Pathology of Internal Diseases, Philadelphia, Lea & Febiger, 1935.
21. Browne, Edgar A.--How to Use the Ophthalmoscope. Philadelphia, Henry C. Lea, 63-70, 1877.
22. Buffum F.H.--Diseases of the Eye, Chicago, Gross & Delbridge, 34-40, 1884.
23. Churchman V.T.--The Ophthalmoscope and the General Practitioner, West Va. Med. J. 28:15-19, Jan. 1932.
24. Clay G.E. & Braird J.M.--Lesions of Fundus Oculi of Special Diagnostic Interest, South M.J. 30:177-181, Feb. 1937.
25. Coats, Geo.--Intra Ocular Vascular Disease, Ophthalmoscope 4:605, 1906.
26. Cohen M.--Lesions of Fundi in Essential Hypertension and in Arterial and Renal Disease, Arch. Ophth. 17: 994-1007, June, 1937.
27. Cohen M.--Lesions of Fundus in Polycythemia Cases. Arch. Ophth. 17:811-818, May, 1937.
28. Corwin Jean & Herrick W.W.--The toxemias of Pregnancy in Relation to Chronic Cardiovascular and Renal Disease. Am. J. Obst- & Gynec. 14:783-796, Dec. 1927.

29. Cushing & Bardley--Subtemporal Decompression in a Case of Chronic Nephritis with Uremia: with Special Consideration of the Neuroretinal Lesion, Am. J. M. Sc. 136:484, 1908.
30. Deaver J. B.--Surgical Anatomy, Philadelphia & London, 1917.
31. Duane, Alexander--Fuchs Text Book of Ophthalmology, Philadelphia & London, J.B.Lippincott Co. 1917.
32. Fellows M.F.--Eyeground Examination as Aid to Prognosis in General Medicine, Journal Lancet 57:294-295, July, 1937.
33. Fick A.E.--Diseases of the Eye and Ophthalmoscopy, Philadelphia, P.Blarkiston, Son & Co. 1896.
34. Fishberg A.M. & Oppenheimer B.S.--The Differentiation and Significance of Certain Ophthalmoscopic Pictures in Hypertensive Diseases, Arch. Int. Med. 46:901, Dec, 1930.
35. Fishberg A.M.--Anatomic Findings in Essential Hypertension, Arch. Int. Med. 35:650, May, 1925.
36. Fisher W-- Ophthalmoscopy, Retinoscopy, and Refraction, Chicago, H.G. Adain Ptg. Co. 1937.
37. Floyd R.--Nephrosis, M. Clin, North Amer. 14:491, 1930.
38. Folk M.L. & Saskin S.--Fundus Oculi of Diabetes, Amer. J. Ophth. 18:432-437, May, 1935.
39. Friedenwald H.--Pathological changes in Retinal Blood Vessels in Arteriosclerosis and Hypertension (Doyle lecture) Trans. Ophth. Soc. U. Kingdom. V50: 452-530, 1930.
40. Friedenwald J. & J.S.--The Retinal Blood Vessel in Hypertension and Arteriosclerosis, Bull-John Hopkins Hosp. V45:232, Oct. 1929.
41. Frost Albert D.--Problems of Interest to the General Medical Man, Ohio State M. J. 33: 505-509, May, 1937.
42. Gager, Leslie T.--Hypertensive Retinal Diseases, Arch. of Ophth. 2:305-315.

43. Gilman, Coit Daniel--The New International Encyclopedia, New York, Dodd Mead & Co. V-15, 1904.
44. Gipner J.F.--Clinical Significance of Retinal Arterial Changes and Retinitis in Cardiovascular Diseases, N.Y. State J. Med. 30:961, 1930.
45. Gresser E.B.--Studies on Retinopathies; Essential Hypertension; Diffuse Glomerular Nephritis; Correlation of Retinal States with Blood Pressure Renal Functional Status etc. Am. J. Ophth. 18: 426-431, May, 1935.
46. Haab O. Dr.--Ophthalmoscopy, New York, Wm. Wood & Co. 16-18, 1895.
47. Hallum A.V.--Eye Changes in Hypertensive Toxemia of Pregnancy, J.A.M.A. V-106:1649, May 9, 1936.
48. Hartridge, Gustavus--The Ophthalmoscope, London, J.&A.Churchill II Ed. 1894.
49. Horton B.F.--Severe Progressive Hypertension with Vasospastic Features, (case) Proc. Staff Meet. May Clin. 10:17-21 Jan, 9, 1935.
50. Horton B.F.--Retinitis associated with Disease of Cardiovascular System, N.Y. Med. Jour. & Med. Rec. June 20, 1923.
51. Horton B.F.--Retinal Angiospasm: Its Relation to Arterial Disease, Amer. Jour. Ophth. 13:4, P. 309, April, 1930.
52. Horton B.F.-- Retinal Vessels in Evolution of Ophthalmoscopic Findings, Med. Rec. Nov. 21, 1934.
53. Jackson, Edward--Refraction and Diseases of Eye, Philadelphia, W.B. Saunders & Co. 175-179, 1901.
54. Keith N.M., Wagener H.P., & Kernochan J.W.--Syndrome of Malignant Hypertension, Arch. Int. Med. 41:141, Feb. 1928.
55. Keith N.M., Barker N.W., & Kernohan J.W.--Histologic Studies of Arterioles in Various Types of Hypertension, Trans. Assoc. Amer. Phys. V-46:66-68, 1931.

56. Klemperer P. & Otain S.--Malignant Nephrosclerosis, Arch. Path. 11:60 Jan., 1931.
57. Knapp A.--Prognostic Significance of Changes in Retinal Vessels, M. Rec. 87:883, 1915.
58. Lange, Fritz--Hemorrhages in the Fundi in Hypertension, Arch. Ophthal. 2:551-554.
59. Marn A. William--Group Pigmentation of the Retina, Arch. Ophthal. 8:66-71, July, 1932.
60. Moore R. Foster--Retinal Venous Thrombosis, London, Geo. R. Pulman & Sons, Ltd, 1924.
61. Offut W.N.--Fundus in Arterial Hypertension, Kentucky M.J. 35:223-227, May, 1937.
62. O'Harre J.P. & Walker W.G.--Arteriosclerosis, Arch. Inter. Med. 33:343, March, 1924.
63. Osler Sir Wm.--The Principles and Practice of Medicine, N.Y. D. Appleton & Co. 1056-1060, 1930.
64. Parsons J.H.--Diseases of the Eye, N.Y. MacMillan Co. Ed. VI, 1931.
65. Peter, Luther C.--Recent Advances of Interest to the General Practitioner, M. Rec. 145:415-418, May, 1937.
66. Pines N.--Arterial Hypertension and Retinal Changes, Brit. Jour. Ophthal. 11:489, 1927.
67. Pines N.-- Sclerosis of Retinal Vessels, Brit. Jour. of Ophthal. 13:97-126, 161-199, 225-251, 1929.
68. Rolfe, Floyd--Retinal Changes in Hypertension and in Renal Disease, Arch. Ophthal. 6:433-444, Sept, 1931.
69. Sage, Earl C.-- Obstetrical Notes for Juniors, Omaha Nebr. Uni. Nebr. Col. Med. 7-8, 1930.
70. Selinger E.--Angiospasm in Toxemia of Pregnancy and Hypertension(Diagnostic significance) Amer. J. Ophthal. 20:56-59, Jan 1937.

71. Storckheim F. & Troube E.K.--Fundus Findings in Tuberos Sclerosis, Am. J. Ophth. 19:508-509, June, 1936.
72. Stough John T.--Choking of Optic Disc in Diseases other than Tumor of Brain, Arch. of Ophthal. 8: 821-830.
73. Swett W. F.--Reflex Spasm Simulating Embolus of Central Artery; Secondary Glaucoma following Ant- rum Irrigation: Complete Recovery, Amer. J. Ophth. 18:359-360, April, 1935.
74. Wagener H.P., Dry F.J.S. & Wilder R. M.--Diabetic Retinitis, New Eng. Med. Jour. 211:1131-1137, Dec. 20, 1934.
75. Wagener H.P. & Keith N.M.--Cases of Marked Hyper- tension, Adequate Renal Function and Neuroretinit- is, Arch. Tub. Med. 34:374, Sept, 1923.
76. Wagener H.P.--"Observations on Retinal Arterio- sclerosis", Mayo Clinic Member Medical Clinics of N.A. Saunders, 275, July 1923.
77. Wagener H.P.--Retinitis in Pregnancy, J.A.M.S. V-103:1910-1913, Dec. 22, 1934.
78. Wagener H.P.--Arterioles of Retina in Toxemia of Pregnancy, Arch. Ophth. 11:909 May, 1934.
79. Wagener H.P.--Sclerosis of Retinal Arteries, Arch. Ophthal. 3:335, March, 1930.
80. Wagener H.P. & Keith N. M.--Cases of Marked Hyper- tension, Adequate Renal Function, Neuroretinitis, Arch. Int. Med. 34:374, Sept, 1924.
81. Wilmer W.H.--Atlas of the Fundus Oculi, N.Y., The MacMillan Co., 1934.
82. Wilmer W.H., Pierce H.F. & Friedenwald J.S.--The Light Streaks on Retinal Blood Vessels, Arch. Ophthal. 9:368-380, March, 1933.
83. Woltman H.W.--Cerebrospinal Arteriosclerosis, Minn. Med. V-102-107, 1922.

84. Yater W.M. & Wagener H. P.--Ophthalmoscopic Signs
in Disease of the Heart, A.M.J. of Med. Sc. 178:
105, 1929.