



University of Nebraska Medical Center
DigitalCommons@UNMC

MD Theses

Special Collections

5-1-1969

Mesenteric arteriovenous fistula after a gunshot wound

Harold W. Forbes

University of Nebraska Medical Center

This manuscript is historical in nature and may not reflect current medical research and practice. Search [PubMed](#) for current research.

Follow this and additional works at: <https://digitalcommons.unmc.edu/mdtheses>

 Part of the [Medical Education Commons](#)

Recommended Citation

Forbes, Harold W., "Mesenteric arteriovenous fistula after a gunshot wound" (1969). *MD Theses*. 88.
<https://digitalcommons.unmc.edu/mdtheses/88>

This Thesis is brought to you for free and open access by the Special Collections at DigitalCommons@UNMC. It has been accepted for inclusion in MD Theses by an authorized administrator of DigitalCommons@UNMC. For more information, please contact digitalcommons@unmc.edu.

MESENTERIC ARTERIOVENOUS FISTULA AFTER A GUNSHOT WOUND

Harold W. Forbes, B.S.

Chester Q. Thompson, M.D.

John W. Smith, M.D.

From the Department of Surgery, University of Nebraska
College of Medicine, Omaha.

Reprint requests to 3610 Dodge St., Omaha, Nebraska 68131
(Dr. Smith).



THE JOURNAL OF TRAUMA

SPONSORED BY THE AMERICAN ASSOCIATION FOR THE SURGERY OF TRAUMA

WILLIAM T. FITTS, JR., M.D.
Hospital of the University of Pennsylvania
3400 Spruce Street
Philadelphia, Pennsylvania 19104

December 19, 1968

Mr. Harold W. Forbes
Department of Surgery
University of Nebraska
College of Medicine
Omaha, Nebraska

Dear Mr. Forbes:

We are pleased to accept your paper, "Mesenteric Arteriovenous Fistula after a Gunshot Wound," for publication in The Journal of Trauma. It has been reviewed and approved by two editorial consultants, in keeping with our policy.

You should receive galley proofs within a few months. These should be correct and returned to us promptly, together with the original redacted manuscript.

With all good wishes,

Yours sincerely,

William T. Fitts, Jr.
William T. Fitts, Jr., M.D.

WTF/ptb

class of 1969

MESENTERIC ARTERIOVENOUS FISTULA AFTER A GUNSHOT WOUND

Harold W. Forbes, B.S., Chester Q. Thompson, M.D., and

John W. Smith, M.D.

An arteriovenous fistula, by the very fact that it is an abnormal interruption in the vascular system, has illuminated various physiological principles. It has demonstrated such effects as increased cardiac output, increased blood flow, congestive failure and recently has substantiated some of the work done on atherosclerosis.

This vascular anomaly has been known for over 200 years with the description in 1757 by William Hunter¹ of a brachial artery basilic vein "anastomosis" secondary to the surgical procedure of "bleeding". They have been described in numerous locations throughout the vascular tree but only recently have fistulas involving the portal system been reported. These fistulas between the mesenteric vessels have been quite rare with only 11 previously reported in the literature. This is a report of the twelfth case and a review of complications possible with this type of arteriovenous fistula.

Case Report

J.H. (360146) entered Methodist Hospital in Omaha on February 24, 1966, following a 22 caliber gunshot wound to the abdomen. At operation about 1000 ml of blood was

found in the abdomen. There was a tear at the base of the small mesentery which was bleeding. There was a large hematoma within the mesentery extending to the retroperitoneal tissues on the right. The blood clots were evacuated, and the bleeding from the small bowel mesentery was stopped with ligatures.

Ten days later on March 6, 1966, the patient was again operated on for drainage of a retroperitoneal abscess. This and other abscesses were drained, and numerous adhesions were lysed. On March 30, 1966, a third operation was performed because of small bowel obstruction, fecal fistula, a possible arteriovenous fistula and possible gangrene of the bowel. A thrill in the region of the small bowel mesentery was noted at the previous operation but was not present at this time. In addition, there was a very large pelvic abscess which occluded the sigmoid colon causing obstruction and a fistulous tract extending from the posterior aspect of the hepatic flexure medially to the ascending colon and then out through a stab wound in the right flank. The terminal several feet of small bowel were of questionable viability. All the various abscesses were evacuated, and the terminal one third of the small intestine and the right colon were resected. An end-to-end anastomosis between ileum and midtransverse colon was performed. The patient recovered and was discharged.

About two years later, the patient experienced an intermittent burning pain to the right of the umbilicus lasting only four or five days. He had had diarrhea about three to five times per day since his previous hospitalization, but did not have any other gastrointestinal symptoms. The patient was admitted to Douglas County Hospital in Omaha on January 24, 1968. On physical examination the patient was a well-developed, well-nourished 25 year-old man in no acute distress. Blood pressure was 148/90, pulse was 60 per minute. There was a vertical midline abdominal scar. Bowel sounds were normal. There was a continuous machinery type murmur with systolic accentuation over most of the abdomen but loudest above and to the right of the umbilicus. A thrill was felt in this area also. Peripheral pulses were present and equal bilaterally. Laboratory data on admission: Hemoglobin 12.7 gm per 100 ml, hematocrit 42%, white cell count 13,500 with a normal differential, blood urea nitrogen 13 mg per 100 ml, urine analysis within normal limits, negative serology. The chest film showed possible viral pneumonitis on the right and a cardiac diameter of 138 mm which was about 15% greater than at his previous admission about two years ago. A retrograde femoral aortogram showed early filling of the portal system and some dilated mesenteric veins (Fig. 1).

On February 1, 1968, the patient was operated on for a mesenteric arteriovenous fistula. Exploration of the abdomen revealed a prominent bruit which appeared to be at the base of the small bowel mesentery (Fig. 2). The fistula was between a jejunal branch of the superior mesenteric artery and one of the major tributaries of the superior mesenteric vein. There was a sacculation on the venous side approximately 2-cm in diameter. With all the branches of the shunt individually controlled and constricted, a period of observation was maintained to observe whether or not the bowel would become ischemic. Because there appeared to be very adequate collateral circulation it was decided to excise the fistula without resection of any bowel. The pathological report described the vein of the arteriovenous fistula to have a thickened wall due to hypertrophy of the muscle. The patient's postoperative course was uneventful, and he was dismissed on February 9, 1968. His bowel habits have not changed, and he continues to have loose stools two to four times per day. At five months postoperatively he has returned to his job as a laborer for the city and has gained ten pounds. The abdominal pain has not recurred.

Discussion

This is the twelfth documented case of a mesenteric arteriovenous fistula²⁻¹² (Table 1). Eight fistulas

developed following gastric or bowel resection, and four, including this case, were caused by a gunshot wound.

Although this patient also had a bowel resection, a probable fistula was diagnosed at the second operation prior to the bowel resection. The thrill could not be felt at the third operation, and it was thought that the fistula had thrombosed.

There have been few serious complications of mesenteric arteriovenous fistulas because of early diagnosis (average 18 months) and treatment, but from work done on other fistulas it is likely that these could develop serious sequelae after several years. As shown in arteriovenous fistulas outside the portal system, an increasing cardiac output and blood volume causes cardiac dilatation and hypertrophy and eventually congestive heart failure^{13,14}. In the presence of a fistula of large size and of considerable return flow of blood to the right side of the heart, electrocardiograms have shown incomplete right bundle branch block¹⁵. Marked venous collateral circulation with venous stasis is seen with most if not all types of fistulas¹⁶.

Mesenteric arteriovenous fistulas may in time lead to portal hypertension and the complications of ascites¹⁷, esophageal varices¹⁸, and duodenal varices¹⁹. There has not yet been a case of congestive heart failure developing from an arteriovenous fistula in the portal system. This type of fistula is different from the usual type in that

the high resistance venous sinusoidal system of the liver lies between the fistula and the right heart¹⁷, and this apparently takes the place of the peripheral vasculature (arterioles).

The symptoms associated with a mesenteric arteriovenous fistula are rather nonspecific. The most common complaints were vague abdominal pain and mild diarrhea. Three of the 12 patients felt an abdominal thrill. This vague pain is most likely due to transient ischemic episodes in the area of the bowel served by the artery involved in the fistula. This parallels the findings of Koskinen and others that the tissue perfusion is decreased in the extremity distal to an arteriovenous fistula²⁰.

There was evidence of markedly dilated veins on the arteriogram and this was subsequently borne out at the operation. This is also true in an extremity distal to a fistula²⁰. In recent work done by Stehbens²¹, it was shown that the proximal artery of an arteriovenous fistula increased in size and developed a large fusiform dilatation both proximally and distally with much tortuosity and a thickened wall. These and other changes were consistent with degenerative changes in veins. These arteriosclerotic changes, although very similar to aging, were the result of altered hemodynamics.

Summary

This is a report of the twelfth case of a mesenteric arteriovenous fistula with diagnosis by aortography and successful surgical treatment. As with all arteriovenous fistulas there is the possibility of serious cardiovascular manifestations, but because of its location in the portal system and early diagnosis and treatment, these types of complications have been avoided.

Table 1

Summary of Mesenteric Arteriovenous Fistulas

ETIOLOGY	LENGTH OF TIME PRESENT	SURVIVAL	PRESENTING COMPLAINT
Bowel resection ²	4 months	yes	Vague abdominal pain, mild recurrent diarrhea
Gastrectomy ³	3 years	yes	Eructation, fullness, purring in abdomen
Bowel resection ⁴	6 years	yes	Diarrhea (regional ilicitis)
Bowel resection ⁵	1 year	(yes?)	"Blue spells and buzzing in abdomen"
Gunshot wound ⁶	7 months	no	Watery, then bloody diar- rhea, crampy periumbilical pain
Gunshot wound ⁷	3 months	yes	No gastrointestinal or abdominal complaints
Bowel resection ⁸	9 months	yes	Tiredness, dyspnea, palpitations
Bowel resection ⁹	18 months	yes	Vague abdominal pain, ascii- tes, frequent soft stools

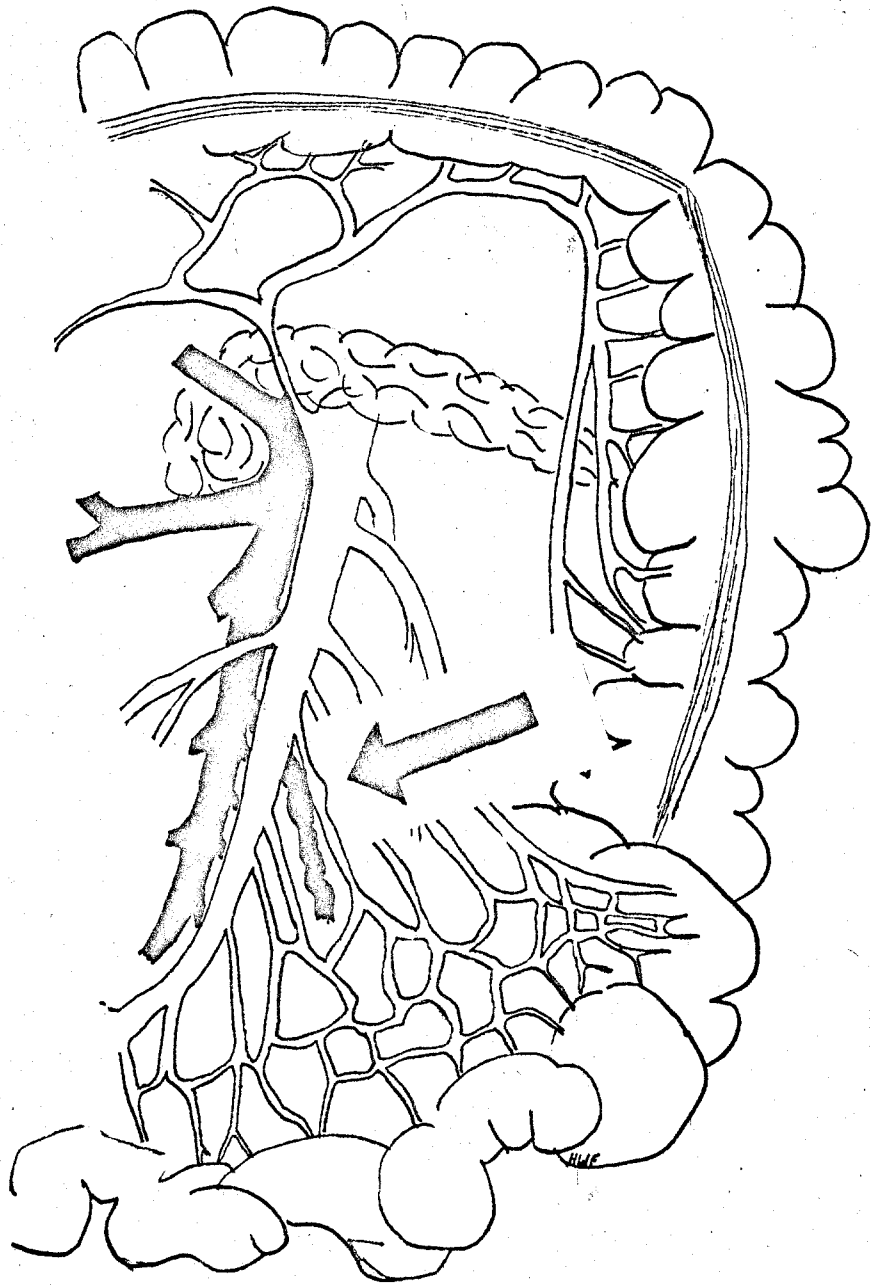
Table 1 (continued)

Bowel resection ¹⁰	2 years	yes	Generalized abdominal cramping, diarrhea
Gunshot wound ¹¹	3 days	yes	Postprandial crampy abdominal pain
Bowel resection ¹²	15 months	yes	Small bowel obstructive symptoms, thrill
Gunshot wound	22 months	yes	Vague abdominal pain
(Authors' case)			

Legends:

Fig. 1. Aortogram demonstrating a well-outlined portal vein within three seconds after injection. The abnormal vessel pattern in the left lower quadrant is consistent with dilated and tortuous veins.

Fig. 2. Site of the arteriovenous fistula.



REFERENCES

1. Hunter, W.: The History of an Aneurysm of the Aorta, with some Remarks on Aneurysms in general, *Med Obs Inq* 1:323-357 1757.
2. Movitz, D., and Finne, B.: Postoperative Arteriovenous Aneurysm in Mesentery after Small Bowel Resection, *J A M A* 173:42-44 (May 7) 1960.
3. Ream, G.B.: A Middle Colic Arteriovenous Fistula Developing as a Postgastrectomy Complication, *Arch Surg* 81:757-760 (Nov.) 1960.
4. Munnell, E.R.; Mota, C.R.; and Thompson, W.B.: Iatrogenic Arteriovenous Fistula: Report of a Case Involving the Superior Mesenteric Vessels, *Amer Surg* 26:738-744 (Nov.) 1960.
5. Durham, M.W., et al: Arteriovenous Fistula of the Mesenteric Vessels, *Western J Surg* 70:9-11 (Jan.-Feb.) 1962.
6. Rabhan, N.B.; Guillebeau, J.G.; and Brackney, E.L.: Arteriovenous Fistula of the Superior Mesenteric Vessels after a Gunshot Wound, *New Eng J Med* 266:603-605 (March 22) 1962.
7. Sumner, R.G., et al: Recognition and Surgical Repair of Superior Mesenteric Arteriovenous Fistula, *Circulation* 27:943-950 (May) 1963.
8. Taylor, R.M.R., et al: Traumatic Fistula Between a Main Branch of the Superior Mesenteric Artery and Vein, *Amer J Med* 38:641-645 (April) 1965.

9. Grafe, W.R., and Steinberg, I.: Superior Mesenteric Arteriovenous Fistula Following Small Bowel Resection, *Gastroenterology* 51:231-235 (Aug.) 1966.
10. Currin, J.F., and Metcalf, B.H.: Postcolectomy Arteriovenous Fistula, *Amer J Gastroent* 46:352-355 (Oct.) 1966.
11. Spellman, M.W., et al: Successful Repair of an Arteriovenous Fistula between the Superior Mesenteric Vessels Secondary to a Gunshot Wound, *Ann Surg* 165:458-463 (March) 1967.
12. Ganshirt, L.W.; Weaver, F.E.; and Olander, G.A.: Mesenteric Arterio-venous Fistula: Review of the Literature and a Report of a Case, *Vasc Surg* 1:82-86 (June) 1967.
13. Holman, E.: Abnormal Arteriovenous Communications: Great Variability of Effects with Particular Reference to Delayed Development of Cardiac Failure, *Circulation* 32:1001-1009 (Dec.) 1965.
14. Muenster, J.J.; Graettinger, J.S.; and Campbell, J.A.: Correlation of Clinical and Hemodynamic Findings in Patients with Systemic Arteriovenous Fistulas, *Circulation* 20:1079-1086 (Dec.) 1959.
15. Amorim, D. de S., and Burchell, H.B.: The Electrocardiogram in Systemic Arteriovenous Fistulas, *Cardiologia* 38:319-334 1961.
16. Hillman, W., et al: Hemodynamic Changes of Arteriovenous Fistula Demonstrated by Arteriography, *Surg Forum* 10:476-480 1959.

17. Foster, J.H., and Sandblom, P.: Portal Hypertension Secondary to an Hepato-Portal Arteriovenous Fistula, Ann Surg 154:300-304 (Aug.) 1961.
18. Madding, G.P.; Smith, W.L.; and Hershberger, L.R.: Hepatoportal Arteriovenous Fistula, J A M A 156:593-596 (Oct. 9) 1954.
19. Wheeler, H.B., and Warren, R.: Duodenal Varices Due to Portal Hypertension from Arteriovenous Aneurysm: Report of a Case, Ann Surg 146:229-238 (Aug.) 1957.
20. Koskinen, E.V.S.; Tala, P.; and Siltanen, P.: The Effect of Massive Arteriovenous Fistula on Hemodynamics and on Bone Growth: An Experimental Study on Dogs, Clin Orthop 50:309-319 (Jan.-Feb.) 1967.
21. Stehbens, W.E.: Blood Vessel Changes in Chronic Experimental Arteriovenous Fistulas, Surg Gynec Obstet 127:327-338 (Aug.) 1968.