



University of Nebraska Medical Center  
**DigitalCommons@UNMC**

---

[MD Theses](#)

[Special Collections](#)

---

5-1-1964

## Role of chromosome abnormalities in early abortions

Richard H. Fairn  
*University of Nebraska Medical Center*

This manuscript is historical in nature and may not reflect current medical research and practice. Search [PubMed](#) for current research.

Follow this and additional works at: <https://digitalcommons.unmc.edu/mdtheses>

 Part of the [Medical Education Commons](#)

---

### Recommended Citation

Fairn, Richard H., "Role of chromosome abnormalities in early abortions" (1964). *MD Theses*. 13.  
<https://digitalcommons.unmc.edu/mdtheses/13>

This Thesis is brought to you for free and open access by the Special Collections at DigitalCommons@UNMC. It has been accepted for inclusion in MD Theses by an authorized administrator of DigitalCommons@UNMC. For more information, please contact [digitalcommons@unmc.edu](mailto:digitalcommons@unmc.edu).

ROLE OF CHROMOSOME ABNORMALITIES  
IN EARLY ABORTIONS

RICHARD HARVEY FAIR

Submitted in Partial Fulfillment for the Degree of  
Doctor of Medicine

College of Medicine, University of Nebraska

February 1, 1964

Omaha, Nebraska

This project was under the direction of James D. Eisen, Ph.D., Assistant Professor of Human Genetics and Chief, Division of Cytogenetics, Nebraska Psychiatric Institute, University of Nebraska College of Medicine. The study was supported by a grant from the Nebraska Institute of Mental Health.

## TABLE OF CONTENTS

	Page
I. Introduction . . . . .	1
II. Materials and Methods . . . . .	3
(a) Techniques of Chromosome Analysis. . . . .	3
(b) Case Presentations. . . . .	7
III. Results . . . . .	16
(a) Critique of author's work . . . . .	16
IV. Discussion . . . . .	17
(a) Presentation of literature review . . . . .	17
V. Conclusion . . . . .	22
VI. Summary . . . . .	23
VII. Tables . . . . .	24
VIII. Bibliography . . . . .	40

## I. INTRODUCTION

Until recent years it was generally accepted that the somatic cell of the human contained 48 chromosomes (23 pairs of autosomes and 1 pair of sex chromosomes)\*. The techniques that were used in arriving at these early observations were crude and limited to only certain types of tissue.

In 1956, Tjio and Levan--employing new techniques such as tissue culture, hypotonic saline treatment and colchicine--observed that the number of chromosomes in the human cell was not 48 but 46 (22 pair of autosomes and 1 pair of sex chromosomes).<sup>1</sup> This observation has since been substantiated many times by other investigators, and the diploid number of 46 is now universally accepted. Three years after this observation, the first human anomaly associated with an abnormal chromosome complement was reported.<sup>2</sup> Since that finding in mongolism, a number of other chromosome abnormalities have been recorded; most are associated with congenital malformations and/or mental retardation. (see Table #3)

While reviewing the literature concerning the relationship between congenital anomalies and abortion, one of the

---

\* See Glossary Table #1.

most interesting and striking facts noted was that the percentage of conceptions that result in spontaneous abortion\* ranges from 10% to as high as 50%.<sup>3</sup> The generally accepted value is around 10%.<sup>3</sup> Death of the fetus, irrespective of cause, precedes abortion in most cases.<sup>3</sup> The various mechanisms responsible for fetal death are listed in Eastman's Textbook of Obstetrics.<sup>3</sup> (see Table #4)

In 1948, Hertig and Rock--studying early aborted tissue and embryos--reported that they found 47% of the specimens so grossly malformed as to be incompatible with life.<sup>4</sup>

In 1963, Carr published a report stating that he had examined the chromosome complement of 35 spontaneous abortions and found 8 to have definite abnormalities.<sup>7</sup>

In preparation for the work to be discussed in this paper, training in the techniques of human cytogenetics was obviously required. This training included familiarization with the methods of tissue culture for chromosome studies, karyotype and buccal smear analysis, pedigree construction and interpretation of results.

---

\* Spontaneous abortion is defined according to the definition found in Eastman's Textbook of Obstetrics.<sup>3</sup>

"Abortion is the termination of a pregnancy at any time before the fetus has attained a stage of viability." The stage of viability is described as, "an infant weighting less than 500 grams or of less than 20 weeks gestation."

## II. MATERIALS & METHODS

Cooperation in the study was obtained from the departments of Obstetrics and Pathology of the University of Nebraska College of Medicine. Permission was granted to obtain a history from each patient and to utilize the facilities of the pathology department for examination of the expelled products of gestation. For completeness, every probable aborting patient that was seen in the University Emergency Room was screened for possible inclusion in the study. Many of the fetuses were not suitable for study for various reasons: questionable spontaneity, insufficient tissue for examination, and inadequate storage of specimen until it could be processed for tissue culture. Because of these limitations, the selection of subjects resulted in the study not representing the universe in a statistical sense.

The procedure was as follows: The obstetrical resident was instructed to place the passed tissue into isotonic saline and place it in the refrigerator as soon as the patient was cared for. The specimen was then taken to the pathology department where a gross examination was performed. (see Table #6) Following the gross examination, the tissue

was divided into two classes, placental and foetal, and set up for tissue culture.

The technique that was used for preparing the specimen for chromosomal analysis is a modification of that established by T. C. Hsu:<sup>5,6</sup>

- a. The tissue is washed in three changes of Eagle's MEM<sup>\*1</sup> to which has been added Penicillin and Streptomycin (100  $\mu$ /cc of each).
- b. The tissue is minced as fine as possible with sharp pointed scissors in the third change of medium.
- c. About three pieces of the finely minced tissue are placed separately on a cover slip. The cover is then inserted into a Leighton culture tube. 0.5 cc of culture medium<sup>\*2</sup> is then placed into the tube carefully and the tube capped. This is incubated at 37<sup>o</sup> centigrade for about 24 hours to allow the atmosphere of the Leighton tube to become saturated.

---

\*1 Eagles Basal Medium acquired from Baltimore Biological Laboratories.

\*2 80% Eagles, 10% pooled fetal calf serum, 10% human serum Type AB, to which Penicillin, Streptomycin and Mycostatin have been added at final concentrations of 100  $\mu$ /cc each.



Caution must be taken not to disturb the tissue as it rests upon the cover slip, for if it does not settle and become attached, the tissue will not grow.

- c. After the first twenty four hour period, an additional 1.5 cc of culture medium is added. The culture is then watched daily for growth. Time to change the medium is determined by the pH, which is maintained at a value of 7.2.
- d. Ideally, the cells will begin to grow in about 5-6 days, and in about two weeks they will begin to show rapid growth (the log phase of tissue culture). When the cover slip is covered with a monolayer of cells, the culture is sacrificed.

Harvesting the cells is done as follows:

- a. 24 hours before harvest the culture medium is changed to insure maximum growth.
- b. Colcemide<sup>\*</sup> is added to the tube making the concentration .05  $\mu$ /cc. The culture is then allowed to incubate for 4-6 hours. This concentration of colcemide and length of culture time has been found to promote an optimal mitotic index and

---

\* Colcemide is the trade name for an experimental drug produced by Ciba Company. It is a purified derivative of colchicine.

state of chromosome contraction. Colcemide is used to arrest the dividing cells during metaphase, causing an accumulation of contracted metaphase figures.

- c. Addition of hypotonic solution is used to swell the cells and to allow adequate separation of the chromosomes when squashed. Distilled water is added to the culture, diluting the solution 3:1. This is allowed to incubate for 30 minutes.
- d. All of the solution is now drained from the tube.
- e. The cells are now ready for fixation. 60% acetic acid, freshly prepared, is added for a period of 30 minutes. The cells are ready to be stained and squashed.
- f. The cover slips are carefully removed from the culture tubes and the large pieces of tissue are removed.
- g. A drop of 2% aceto-oricein is placed on a clean microscope slide. The cover slip is then placed, cells down, over the drop of stain and the preparation squashed with thumb pressure.
- h. The edges around the cover slip are sealed with wax (Krönigs cement).

The specimens are now ready for chromosome analysis. Chromosomes in 50 different cells should be counted, and several representative cells selected for analysis. These representative cells are then photographed for karyotype preparation and permanent record.

During the first five months that this study was in progress, nine specimens were obtained which were satisfactory for study. The case histories follow:

Case #1 (University of Nebraska Hospital #-53373)

A thirty nine year old white female was admitted July 21, 1963 with the chief complaint of abdominal cramping and vaginal bleeding of eight hours duration. Her last menstrual period had been in April 10, 1963. The patient had been experiencing spotting for the past three months, but had not consulted a physician with this pregnancy.

Past obstetrical history reveals two normal full term pregnancies, the last one in 1947.

There wasn't any significant past medical or family history that would contribute to the study of possible factors responsible for suspecting congenital malformations.

Pathological examination:

1. A fetus measuring 11.5 cm crown-rump and weighing 200 grams. The sex was male. The specimen was not grossly remarkable.

2. The placenta measured 10x10x3.5 cm. The only abnormality was evidence of marginal sinus rupture.
3. Tissue taken for culture included pieces of placenta and skeletal muscle from the lateral abdominal wall of the fetus.

Case #2 (University of Nebraska Hospital #-17526)

A nineteen year old white female was admitted on August 28, 1963 with the chief complaint of abdominal cramping, vaginal bleeding and passage of tissue at home. This patient's last pregnancy had been a normal full term pregnancy terminating the fall of 1962. Since that time she had intermittantly been taking Enovid. The patient presented herself at the Obstetrical Clinic of the University in May saying she was pregnant. At this time, however, the attending physician could find no clinical evidence of pregnancy. On Friday, August 23, she again came to the clinic and maintained that she was pregnant and had been since April. The attending physician again found no clinical evidence and ordered a frog test. The pregnancy test was performed on a urine specimen taken on Monday, August 27, and was reported negative. As noted above, she aborted on Tuesday, August 28. Her last menstrual period was on April 10, 1963. At the time of admission she stated that she had been amenorrheic for the past four months, spotting slightly for the last two months, and experiencing active bleeding for the past week.

The patient's past medical and family history contributed nothing to the study of possible factors responsible for suspecting congenital malformation or familial propensity to abortion.

The past obstetrical history revealed only one previous pregnancy, the one mentioned above.

Pathological examination:

1. A fetus of crown-rump length of 7 cm. The specimen was not grossly remarkable and the sex was not able to be determined.
2. Pieces of the placenta containing multiple small polyps. These polyps contained blood and degenerating tissue infiltrated by acute inflammatory cells.
3. Tissue taken for culture was skeletal muscle from lateral abdominal wall and placental tissue.

Case #3 (University of Nebraska Hospital #-37840)

A twenty six year old negro female was admitted to the emergency room on September 9, 1963 with the chief complaint of abdominal cramping, vaginal bleeding and passage of a large clot while at home. The patient's last normal menstrual period was in May 1963. The menstrual period on June 8, lasted eight days and had some abnormal appearance, "a dusty color", but no large clots or excessive bleeding.

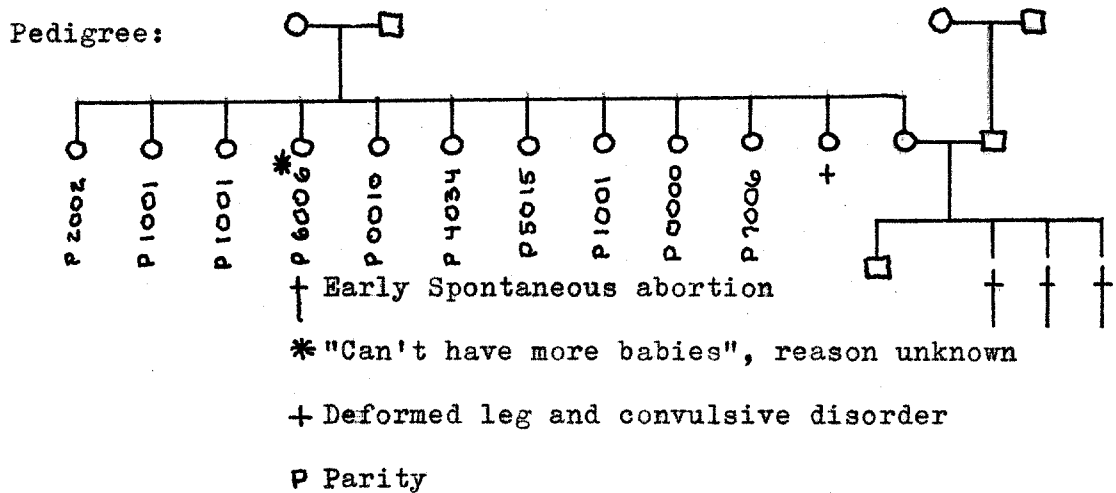
The patient is relatively sure that she got pregnant on July 14 or 15. On July 19, she underwent fluoroscopy

(barium enema) for suspected lower bowel lesion. She experienced some spotting on July 20.

The past medical history revealed no major illnesses or surgical operations. She has not recently been on any medication. She was exposed to the mumps about six months of age.

Past obstetrical history: The patient had a normal full term pregnancy in 1954. She had had three consecutive abortions in 1956, 1960, and the present one in 1963. All abortions were less than three months gestation. Treatment in all cases consisted of D & C; the case in 1960 required several transfusions.

The family history is represented in the following



Pathological examination:

1. Placental tissue showing marked degeneration and inflammation.
2. Tissue taken was of placental origin.

Case #4 (University of Nebraska #-54580)

A thirty two year old white female was admitted on October 30, 1963 with the chief complaints of vaginal bleeding. The last normal menstrual period was about one year ago. Since that time she has been intermittently spotting.

The past obstetrical history reveals seven other pregnancies outlined as follows:

1. January 29, 1949: With first husband a full term pregnancy. The patient almost aborted at five months, but was given shots and put to bed. The son born suffered from pyloric stenosis which was successfully corrected by surgery.
2. December 24, 1951: With second husband a girl born after about seven months gestation period.
3. February 7, 1953: With second husband a girl born jaundiced. The patient stated that there was a question of Rh factor.
4. With second husband, an abortion at four months gestation. The patient was in a psychiatric hospital at the time.
5. An abortion at two months following a beating by her second husband.
6. October 15, 1957: A son born jaundiced requiring two exchange transfusions.

7. December 8, 1960: With the second husband, a son born requiring two complete exchange transfusions.
8. Present abortion. Third husband.

Pathological examination:

1. Placental tissue showing marked degeneration and inflammation.
2. Tissue taken was of placental origin. No fetus present.

Case #5 (University of Nebraska Hospital #-39562)

A twenty nine year old negro female was admitted to the emergency room with the chief complaints of abdominal cramping, vaginal bleeding and syncope. Her last normal menstrual period was on August 29, 1963. Her last pregnancy was a normal full term pregnancy in 1960. She had two normal full term pregnancies preceeding 1960.

Past medical and family history contributed nothing to the study of possible factors responsible for suspecting congenital abnormalities or familial propensity to abortion.

Pathological report:

1. Only endometrial tissue present exhibiting a marked ducedual reaction and inflammatory reaction.

Case #6 (University of Nebraska Hospital #-54906)

A twenty one year old negro female was admitted for complaints of abdominal cramping and vaginal bleeding.



The patient completed a full term normal pregnancy only five month ago, and had not had a menstrual period since. She had not had any other pregnancies.

Past medical and family histories contributed nothing to the study of possible factors responsible for suspecting congenital abnormalities or familial propensity to abortion.

Pathological report:

1. Gross examination--the fetus was not grossly remarkable and the placenta measured 8.5 x 6.5 x 3 cm. The fetal surface was slightly degenerated. The microscopic examination revealed marked degenerative changes and inflammation. The chorionic villi were very immature.
2. Tissue taken for culture was from fetus and placenta.

Case #7 (University of Nebraska Hospital #-40-36)

A sixteen year old negro female was admitted on November 6, 1963 with the chief complaints of abdominal cramping and vaginal bleeding. Her last normal menstrual period was in mid-August. Her only other pregnancy was a normal full term pregnancy which terminated about seven months ago. Since that time the patient has been on Enovid; however, she admitted irregularity in taking the drug.

The past medical and family histories contributed nothing to the study of possible factors responsible for suspecting

congenital abnormalities or familial propensity of abortion.

Pathological examination:

1. Gross examination revealed a fetus measuring 3 cm crown-rump length with a possible cervical meningocele. The placental tissue was fragmentary. Microscopic examination of the placental tissue revealed moderated degeneration of the chorionic villi.
2. Tissue from fetus and placenta was set up for culture.

Case #8 (University of Nebraska Hospital #-54580)

A thirty two year old negro female was admitted on October 30, 1963 for vaginal bleeding. This patient was completely unreliable and uncooperative. She stated that she had had five previous normal full term pregnancies and two spontaneous abortions. She couldn't remember the dates of her last normal menstrual period and last pregnancy.

Past medical, family and obstetrical histories were not obtained.

Pathological examination:

1. Gross examination revealed a fetus measuring 17 cm crown-rump length. It appeared to be female. The specimen was not grossly remarkable. Microscopic examination of tissue fragments showed only inflammatory reaction.
2. Tissue from fetus and placenta was set up for culture.

Case #9 (University of Nebraska Hospital #-358 )

A forty two year old negro female was admitted on December 8, 1963 with chief complaint of vaginal bleeding. The patient had had four other normal pregnancies and two early spontaneous abortions. Her last pregnancy was two years ago. Her last normal menstrual period began on September 21, 1963.

Pathological examination:

1. Multiple strands of tissue showing acute inflammation. No chorionic villi were noted.
2. Tissue was taken from the placenta for culture.

### III. RESULTS

Tabulation of the results of the tissue culture and chromosome analysis are presented in Table #6. It can readily be seen from the table that success in obtaining adequate material was poor. Most of the cultures failed to grow. The general reasons for tissue culture failure includes; contamination, tissue that is not viable to start with, loss of culture due to inadequate medium, and loss of control of pH.

The culture from Case #7 (University of Nebraska Hospital #-40-36) that did grow and multiply yielded metaphase plates. Unfortunately, most of these were lost due to improper fixation, staining and/or squash technique. Analyzable plates revealed a normal diploid chromosome number of 46. Valuable lessons were learned. A medium mixture was arrived at which appeared to be adequate, and a systematic method was established for checking the cultures for change of medium. Experience was gained in preparing slides of culture material for microscopic examination.

Because of the lack of sufficient results, conclusion will be drawn with the aid of the work published by Carr and others.<sup>7,8,9</sup>

#### IV. DISCUSSION

Dr. Carr of Toronto, Canada, has given permission for a discussion of his recent unpublished results.

Carr's original study consisted of thirty five spontaneous abortions and six stillborn infants.<sup>7</sup> He did not include those where spontaneity was questionable or where the culture failed. The specimens from stillborn infants were highly selected because a request for tissue culture was usually received only if obvious anomalies were present. Eight of the specimens showed definite chromosome abnormalities. (see Table #5)

Added to the original publication was a report of 19 other cases which included an XO sex chromosome anomaly, an E (16-18) trisomy, a triploid (with an XXY sex chromosome complex), and a culture which produced only tetraploid cells.

Dr. Carr has reported to Dr. Eisen (personal communication) that out of 67 specimens he has obtained:

3-XO's  
3-Trisomy D (13-15)  
2-Trisomy E (16-18)  
2-Triploids  
1-Tetraploid  
1-Trisomy G

There have been reports of other chromosome abnormalities associated with early abortion and stillbirth.<sup>8,9</sup>

Environment versus "defective germ plasm" has been a

major topic of controversy concerning the etiology of abortion for many years. Mall and Meyer<sup>10,11</sup> and later Streeter<sup>12</sup> were among the first to present concrete evidence which reinforced the "defective germ plasm" or "blighted ovum" theory.

Some of the most noteworthy studies carried out in this field were by Hertig and Rock of Boston. Hertig first demonstrated that there is about 30% wastage in animals producing litters.<sup>13</sup> He compared the litter number with the number of corpus leutea. He also showed that about 10% of the defective ova probably produced clinical pregnancy and he compared this to the accepted abortion rate in humans. Other investigators have also noted these high wastage factors in animals with litters.<sup>14</sup>

Hertig and Rock in 1948 reported that out of 26 early embryos studied, 47% were malformed in the trophoblast or dermal tissue or both.<sup>4</sup> Out of 122 uteri of fertile females examined, 104 were exposed to pregnancy at ovulation and 25% conceived for a 25% fertility index. This paper also included an excellent description of the very early stage of normal embryo development. In the discussion found at the end of the paper, the controversy of environment versus germ plasm was presented. Dr. Eastman presented the point that environment does play a major part in etiology of congenital

malformation. Dr. Eastman cited such examples as:

1. Diabetic mothers have a 25% incidence of malformations of their off-spring.
2. He noted the study concerning the effect of rubella during the first trimester of pregnancy.
3. His major point was the fact that the ratio of monozygous to dizygous twins in utero is 1:3 and that the ratio when there is a tubal pregnancy is 15:3.

In 1949, Hertig and Rock again published a paper titled, "A Series of Potentially Abortive Ova Recovered from Fertile Females Prior to the First Missed Menstrual Period."<sup>15</sup> This study was carried out by examining the contents of the uterus following hysterectomy. The hysterectomy date was planned so the female could potentially be pregnant at the time of operation. The indication for hysterectomy was for various reasons. Twenty eight of the 136 women studied conceived. Twelve of the products of gestation were abnormal in some way. Seven of the twelve were so grossly abnormal that they were certain to abort. Four of these seven were so malformed they probably wouldn't have caused clinical pregnancy. The major defects noted were:

1. Multinucleated blastomeres.
2. Absence of embryonic disc and a chorionic cavity.
3. Profound hypoplasia of future placental tissue.

When asked if the abnormal environment which might be present due to the pathological indications for surgery might be a factor, Dr. Rock replied that the endometria of all of the uteri were normal as far as could be determined by modern techniques. He went on to say, "The evidence such as it is indicated that the defective fertilized ovum is due to intrinsic germ plasm quality rather than to the environment and is the main factor in the production of spontaneous abortion." \*

From the above discussion it can easily be seen that most all of the authorities in the field agree that early embryonic malformation is one of the major causes of early abortion. The etiology of early malformation, however, is a topic of controversy even with the major work of Hertig and Rock.

With the new field of cytogenetics, we now have a method for examining this aborted tissue and the parents for possible chromosome abnormalities that might be responsible for early fetal death and abortion.

---

\* He was convinced that the gross abnormalities and even deletion of major parts of the developing conceptus was evidence for the abnormal germ plasm theory.



It must be remembered that because some of the tissue was abnormal or even dead to start with it might not grow in tissue culture. This fact alone might be responsible for the large percentage of tissue culture failure--30% by Carr and 60% in the work. Dr. Carr demonstrated that chromosome abnormalities are present in early aborted tissue to a greater extent than the expected incidence of chromosome abnormalities at birth.

## V. CONCLUSION

It appears as if there is little doubt that early embryonic malformation plays a major role in early abortion. Carr has adequately shown that chromosome abnormalities are indeed associated with some of these early anomalies. At present the evidence is a small series, but it is felt that as the studies in this field continue, more evidence will appear to support this study. We may even begin to arrive at some conclusions as to the specific etiology of these chromosome abnormalities.

Although this paper hasn't contributed to Dr. Carr's excellent report, it must be remembered that perhaps the major goal of the present work was to acquaint the author with the field of cytogenetics. It is felt that this experience in a cytogenetic laboratory was a valuable addition to the author's medical education.

## VI. SUMMARY

1. The dual purpose of the paper was discussed: First to acquaint the author with the field of cytogenetics and its application to clinical medicine, and second, to study the "Role of Chromosomes in Early Abortion".
2. The evolution of the hypotheses that congenital malformations are responsible for a percentage of early abortions is discussed with a review of the publications by Hertig and Rock.
3. The author's attempts at providing experimental evidence that chromosomes do play a role in early abortion is presented.
4. Carr's work is reviewed, in which he shows that chromosome abnormalities (associated with early malformation of the embryo) do play a role in early abortion.

TABLE 1

Reference #16

GLOSSARY

- Acrocentric: Type of chromosome in which the centromere is located near one end. At metaphase it has the appearance of a "Wishbone". Also called subterminal.
- Alleles: A pair of genes situated at a corresponding locus of a pair of homologous chromosomes, having to do with a specific characteristic in offspring.
- Anaphase: Phase of cell division characterized by the movement of chromosomes from the metaphase plate toward the opposite poles. In mitosis it is the longitudinally-doubled chromosomes (chromatids) which separate. In the first stage of meiosis whole chromosomes instead of chromatids separate at anaphase. The second meiotic division is essentially mitotic, with separation of chromatids.
- Aneuploidy: State characterized by an irregular number of chromosomes, not an exact multiple of the basic number characteristic for the species.
- Autosome: A non-sex chromosome.

Centromere: A nonstaining, apparently structureless constriction visible in chromosomes during prophase, metaphase and anaphase. It produces the so-called primary constriction of each chromosome and is the region at which the latter becomes attached to the spindle. Its position, which may be median (metacentric), submedian (submetacentric), or acrocentric (near one end), is constant for a given chromosome and determines its form. Accordingly it assists in the identification of individual chromosomes. Also termed kinetochore.

Chiasma: The point of contact between non-sister chromatids of paired homologous chromosomes seen during the prophase of the first meiotic division. It is the cytologic expression, of completed genetic crossing over, the latter providing for the exchange of genic material between two chromosomes before they separate.

Chromatid: During nuclear division each chromosome presents a longitudinally-double form, each half of which is known as a chromatid. The components of a single chromosome are sister chromatids and are held together at the centromere. When these separate at mitotic anaphase they are

called daughter chromosomes.

Chromatin: The substance in nuclei and chromosomes which stains intensely with basic dyes. It is composed of DNA combined with proteins. In the fixed intermitotic nucleus it usually takes the form of an irregular network of long coiled threads. Larger and denser chromatin particles are known as chromocenters. As a cell undergoes division the delicate coils of chromatin material are gradually transformed into individual chromosomes.

Chromatin-Negative: Refers to nuclei which lack Barr's sex-chromatin mass. Characteristic of the normal human male.

Chromatin-Positive: Refers to nuclei containing the distinctive sex-chromatin body of Barr. Present in the normal human female.

Chromocenter: Deeply staining clumps of chromatin material present in intermitotic nuclei. A chromocenter of characteristic size and shape lying in contact with the nuclear membrane is present in females of many species including man. It is known as the sex-chromatin body of Barr.

Chromosome: One of a finite number of small bodies occurring in pairs into which the chromatin material of a cell nucleus resolves itself prior to cell division. Chromosomes are not visible as such except during cell division. Homologous chromosomes are the two members of one pair, one of maternal, one of paternal origin. At metaphase, the longest human chromosome measures approximately 8 to 10  $\mu$  and the smallest 1.2 to 1.5  $\mu$ . It is the unit structure bearing the carriers of hereditary traits, the genes. The morphologic characteristics of the individual chromosome and their total number is constant for all the somatic cells of a given species. Its major chemical components are DNA, RNA, histones and non-histone proteins.

Crossing over:The exchange of chromatic material between synapsed homologous chromosomes during prophase of the first meiotic division. Occurring when the chromosomes are longitudinally-double, the event involves non-sister chromatids and not whole chromosomes. It takes place between, not at, the loci of genes. The process is responsible for new recombinations of genes in the gametes which differ from the parental

gene combinations in the original germ cells.

Deletion: A chromosomal aberration characterized by detachment and loss of a portion of a chromosome by breakage. In this manner one or more genes may be removed from the organism. The deleted portion fails to survive if it lacks a centromere.

Diploid: The number of chromosomes present in all somatic and primitive germ cells of a species. It is referred to as  $2n$  where  $n$  signifies the haploid (half) number which is found in gametes.

Dominant: Refers to a gene which produces its effect despite the presence of an opposite or contrasting gene.

Duplication: A type of chromosomal aberration characterized by the presence of an extra segment of chromosome which may exist as a separate fragment or may be attached to one of the members of the ordinary chromosomal complement. To be distinguished from aneuploidy and polyploidy in which variations in somatic chromosome number are irregular or exact multiples, respectively, of the basic chromosomal number.

Equational division: The second meiotic division, essentially mitotic in type, characterized by the separa-



tion of sister chromatids. The latter are genetically identical since they are longitudinally-split reduplications of individual chromosomes.

Euchromatin: The chromatin material composing a chromosomal segment which exhibits no variation in staining intensity (isopycnosic) or in condensation at any time during the mitotic cycle.

Euploidy: State in which there is a balanced set a chromosomes. Includes variations in the somatic chromosomal number characterized by the presence of exact multiples of the basic number of that species. Accordingly, these may be haploid (monoploid), diploid, triploid, tetraploid and higher multiple numbers. Complements higher than haploids are called polyploids.

Gamete: In bisexual organisms, the mature germ cell of either sex (spermatozoa or ova) containing the haploid (n) number of chromosomes.

Genes: The basic ultramicroscopic, intramolecular units of heredity arranged linearly at definite points (loci) in a chromosome. They occur in pairs (allelic genes) situated at

corresponding loci of a pair of homologous chromosomes and are capable of producing externally visible body traits composing the phenotype. Apparently, genes function by controlling enzymatic action.

Genotype: The genetic constitution of an organism regardless of the external appearance. Thus, a genetic female may have the physical appearance (phenotype) of a male, and vice versa. Because of the Mendelian phenomena of segregation and recombination, together with exchanges of genes occurring during meiosis, it is probable that no two individuals (barring identical twins), in the course of mankind's existence, have ever had the same genotype.

Haploid: The half number (n) of the basic chromosomal complement (diploid or 2n) of a species. The haploid number consists of one of each pair of chromosomes and is the normal condition in mature germ cells.

Hemizygous: Normal diploid cells with their pairs of homologous chromosomes and genes, are either homozygous or heterozygous for each pair of genes, depending on whether the alleles of

a pair are identical or contrasting. The hemizygous condition refers to the presence of an unpaired gene or chromosome. Haploid gametes, which normally contain a single set of chromosomes, are therefore hemizygous for the genes carried in these chromosomes. Also, the normal diploid heterogametic zygote, containing the partially or totally nonhomologous X- and Y- chromosomes, is hemizygous for the genes represented in the non-homologous segments of the dissimilar sex chromosomes.

Hemizyosity, as an abnormality, exists in monosomic cells in which only one member of a pair of homologous chromosomes is present. Such cells are accordingly hemizygous for the genes located in this particular chromosome.

TABLE 2

Reference #16 & #17

Outline of the identifying characteristics of the seven groups of human mitotic chromosomes according to the "Denver System".

1. The autosomes are numbered in pairs from 1-22.
2. The sex chromosomes are considered separately.
3. The seven groups are classified as follows:

Group 1-3: Large chromosomes with approximately median centromeres. The three chromosomes are readily distinguished from each other by size and centromere position.

Group 4-5: Large chromosomes with submedian centromeres. The two chromosomes are difficult to distinguish, but chromosome 4 is slightly longer.

Group 6-12: Medium sized chromosomes with submedian centromeres. The X chromosome resembles the longer chromosome especially chromosome 6 from which it is difficult to distinguish. This large group is one which presents major difficulty in identification of individual chromosomes.

Group 13-15: Medium sized chromosomes with nearly terminal centromeres ("acrocentric" chromosomes).

TABLE 2 (continued)

Chromosome 13 has prominent satellites on the short arms. Chromosome 14 has small satellites on the short arms.

Group 16-18: Rather short chromosomes with approximately median (in chromosome 16) or submedian centromeres.

Group 19-20: Short chromosomes approximately median centromeres.

Group 21-22: Very short, acrocentric chromosomes.

Chromosome 21 has satellites on its short arms. The Y-chromosome is similar to these chromosomes.

The criteria for determining which group the chromosome belongs to are:

1. The length of the chromosome expressed as a percentage of the total length of an X-containing haploid group.
2. The position of the centromere which may be expressed either as an arm ratio (long arm/short arm).
3. Any other distinguishing feature such as the presence of satellites.

The following is an idiogram of a normal human male with twenty-two pairs of autosomes and an XY sex chromosome constitution:

TABLE 2 (continued)








	Median	Submedian
LARGE	 (1-3)	 (4-5)
MEDIUM	Submedian	
	 (6-12 and X)	
MEDIUM	Acrocentric	Median or Submedian
	 (13-15)	 (16) (17-18)
SHORT	Median	Acrocentric
	 (19-20)	 (21-22 and Y)

TABLE 3

List and explanation of common chromosome abnormalities and their clinical characteristics. Reference #16

Sex	Chromosome Abnormality	Karyotype	Clinical Conditions
F	Trisomy in group 16-18	(47) XX	Cardiac defect, webbed neck, shield like chest, mental retardation.
F	Trisomy in group 13-15	(47) XX	Apparent anophthalmis, cleft palate, hare lip, simian line, polydactyly, cardiac defect, cerebral defect, capillary hemangiomas, mental retardation.
M	Trisomy for No. 22	(47) XY	Sturge-Weber syndrome, mental retardation.
M	Trisomy in group 6-12 apparently 8 & 11	(49) XXY	Cardiac and renal defects, Peculiar facies, malformed external genitalia and testis, mental retardation.
M	Complete trisomy (triploidy)	(69) XXY	Porencephaly, micrognathia, syndactyly, mental retardation.
M	Translocation of No. 22 to one of group 13-15	(45) XY	Malformation of vertebral column, small head contour, abnormal head contour, abnormal sella turcica, mental retardation (polydyspondylism).

TABLE 3 (continued)

Reference #18

13-15 Trisomy

Deafness, seizures, retroflexability of thumbs, polydactyly, cleft palate, hare lip, hemangioma, defects (anophthalmia or micro-ophthalmia).

16-18 Trisomy

Spasticity, clenched fingers, over laping index fingers, micro gnarhia, malformed ears, umbilical or inguinal hernias, ventricular septal heart defect, patent ductus arteriosis heart defect, Meckel's diverticulum, ectopic pancreas.

Some anomalies common to both:

Mental retardation, low-set ears, rocker bottom feet, heart anomalies, increased age of mother at time of conception and failure of infant to thrive.



TABLE 4

Etiological factors responsible for spontaneous abortion.<sup>3</sup>

1. Abnormalities occurring in the ovum itself.
  - a. Those arising from defective chromosomes or genes.
  - b. Those arising from faults in intra-uterine environment.  
(Both of these categories are based on theory.)
2. Abnormalities of the female generative tract.
  - a. Infatible uterus.
  - b. Adnexal inflammation.
  - c. Tumors of the uterus.
  - d. Endocervicitis.
  - e. Displacements of the uterus.
3. Systemic disease on the part of the mother and occasionally of the father.
  - a. Maternal disease.
    1. severe acute infections.
    2. chronic wasting diseases.
    3. syphilis.
    4. endocrine dyscrasias or imbalances.
    5. physical or psychic trauma.

TABLE 5

Summary of the findings from Dr. Carr

Specimen	Chromosome Counts							Karyotypes	Tissue Used
	45	45	46	47	47	3X	4X		
1	4	19	0	0	0	0	0	9	Amnion
2	0	1	2	49	2	0	1	25	Amnion
3	1	0	0	14	0	0	0	9	Limb, Amnion, yolk sac
4	2	0	0	22	0	0	0	13	Amnion
5	8	33	0	0	0	0	0	13	Amnion
6	1	3	1	20	0	0	0	9	Cord, Amnion
7a	1	0	0	0	60	18	0	7	Cord, Amnion
7b	0	1	3	24	1	0	0	9	Cord, Amnion

TABLE 6

Summary of this author's cases.

Case #	Tissue Used	Chromosome Counts
1	Fetal, placental	No growth
2	Fetal, placental	No growth
3	Placental	Bacterial contamination
4	Placental	Moderate growth, no analyzable cells
5	D & C fragments	No growth
6	Fetal, placental	Growth No analyzable cells
7	Fetal, placental	10 cells 46 chromosomes each
8	Fetal, placental	2 cells 46 chromosomes each
9	D & C fragments	No growth

## BIBLIOGRAPHY

1. Tjio, J. H. and Levan, A., The Chromosome Number of Man, *Hereditas*. 42:1, 1956.
2. Conner, P. E., and others, A Review of Chromosomal Studies in the Diagnosis of Mongolism, *Journal of Pediatrics*. 60/4:533-539, (April) 1962.
3. Eastman, N. J., *Williams Obstetrics*, New York, Appleton-Century Crofts Inc., 12th Ed., 1961.
4. Hertig, A. and Rock, J., The Human Conceptus During the First Week of Gestation, *Am. J. Obst. & Gynec.* 55:6, 1948.
5. Hsu, T. C. and Kellogg, D. S., Primary Cultivation and Continuous Propagation in vitro of Tissue from Small Biopsy Specimens, *J. Nat. Cancer Inst.* 24:221-235, 1960.
6. Levan, A. Colchicine-induced C-mitosis in Two Mouse Ascites Tumors, *Hereditas*. 40:1, 1954.
7. Carr, D. H., Chromosome Studies in Abortions and Still-born Infants, *Lancet* II/7308:603 (Sept. 21) 1963.
8. Penrose, L. S. and Delhanty, J. D. A., Triploid Cell Cultures from a Macerated Foetus, *Lancet* II/1261-1262 1961.
9. Delhanty, J. D. A., and others, Triploid cells in a Human Embryo, *Lancet* II/286, 1961.
10. Mall, F. P. and Meyer, A. W., *Studies on Abortuses: A Survey of Pathologic Ova in the Carnegie Embryological Collection*, Carnegie Inst. Wash., 1921, Vol. 12, Pub. No. 275.
11. Mall, F. P., On the Frequency of Localized Anomalies in Human Embryos and Infants at Birth, *Am. J. Anat.* 22:49, 1917.
12. Streeter, G. L., Report on Investigation, Department of Embryology, Pathology of the Fetus, *Contrib. Embryol.*, 30:15, 1931.
13. Hertig, A. and Livingston, R. G., Spontaneous Threatened and Habitual Abortion, Its Pathogenesis and Treatment, *New England J. Med.* 230:797, 1944.

14. Corner, G. W., Embryonic Pathology in Mammals, With Observations Upon Intra-uterine Mortality in the Pig, Am. J. Anat. 31:523, 1922-23.
15. Hertig, A. and Rock, J., A Series of Potentially Abortive Ova Recovered From Fertile Females Prior to the First Missed Menstrual Period, Am. J. Obst. & Gynec. 58:968, 1949.
16. Sohval, A. R., Recent Progress in Human Chromosome Analysis and Its Relation to Sex Chromatin, Am. J. Med. 31/3:397-441, (Sept.) 1961.
17. ""  
Book, J. A. and others, Proposed Standard System of Nomenclature of Human Mitotic Chromosomes, Lancet 1:1063-1065, 1960.
18. Goodman, R. M., Medical Genetics and the Practicing Physicians, GP. 27/2:108, (Feb.) 1963.
19. Penrose, L. S., Recent Advances in Human Genetics, Little Brown and Co., 1961.
20. Hertig, A. and Edmonds, H. W., Genesis of Hydatidiform Mole, A. M. A. Arch.Path., 30:260, 1940.