



PEDIATRIC UROLOGY CASE REPORTS

ISSN 2148-2969

<http://www.pediatricurologycasereports.com>



Bilateral testicular tumor in a patient with adrenogenital syndrome: A conservative approach

Angeline Rojas Díaz¹, Juan David Iregui Parra², Lina Huérfano³, Ana Ortiz Zableh⁴, Jaime Pérez Niño⁵

¹Department of Urology, Universidad Militar Nueva Granada

²Department of Urology, Pontificia Universidad Javeriana

³Department of Pathology, Universidad Militar Nueva Granada

⁴Medical Student, Pontificia Universidad Javeriana.

⁵Department of Urology, Medical School, Pontificia Universidad Javeriana, Hospital Universitario San Ignacio Ad Honorem Professor Universidad Militar Nueva Granada, Hospital Militar Central.

ABSTRACT

Testicular tumors of the adrenogenital syndrome (TTAGS) are a rare disease, with a benign course. We present the case of a 12-year-old patient with congenital adrenal hyperplasia (CAH), precocious puberty and bilateral testicular masses. Hormonal control had been adequate. Incidental finding of bilateral testicular masses, with negative testicular tumoral biomarkers. The patient underwent right testicular sparing surgery, finding an intraparenchymal nodular mass. Pathological study showed a TTAGS, positive for CD99, Melan A, inhibin and synaptophysin markers. Conservative management was decided.

Key Words: Testicular tumors; adrenogenital syndrome; congenital adrenal hyperplasia; leydig cells tumor.

Copyright © 2018 [pediatricurologycasereports.com](http://www.pediatricurologycasereports.com)

Corresponding Author: Ana Ortiz Zableh
Pontificia Universidad Javeriana. Bogotá D.C.-
Colombia

E-mail: aortizz.92@gmail.com

Accepted for publication: 24 January 2018

clinical assessment is needed to identify TTAGS in patients with CAH. The differential diagnosis with Leydig Cell Tumor (LCT) is the principal objective in the evaluation of these patients, due to the fact that their management

al and surgical treatments are available for preventing gonadal dysfunction [1,2].

Case report

12-year-old boy diagnosed with CAH at the age of three, due to precocious puberty; he was referred to the pediatric urology service because of the incidental finding of bilateral

Testicular tumors of adrenogenital syndrome (TTAGS) are an entity presented in boys with congenital adrenal hyperplasia (CAH) [1,2]. These tumors have a benign course, are usually bilateral, localized near the testicular mediastinum [3–5]. Due to their location, these tumors can lead to mechanical obstruction of the seminiferous tubules. A comprehensive

testicular masses. He was being managed with hydrocortisone (25 mg/day) with adequate hormonal control: 17-Hydroxyprogesterone, dehydroepiandrosterone, androstenedione and testosterone levels were between normal ranges.

Physical examination showed a Tanner Scale of A3, P4, G3. The abdomen was soft, non-tender, with no masses. The penis was normal. The right testicle had a volume of 6-8 ml and the left testicle of 8-10 ml. An irregular and hard mass was felt towards the posterior aspects of both testicles [Fig. 1].



Fig. 1. Physical examination.

Testicular tumor markers were negative. Testicular ultrasonography showed testicles of normal size and position, with altered bilateral echogenicity due to a mediastinal hypo echogenic lesion, which occupied 30% of each of the testicles, with micro calcifications [Fig. 2].

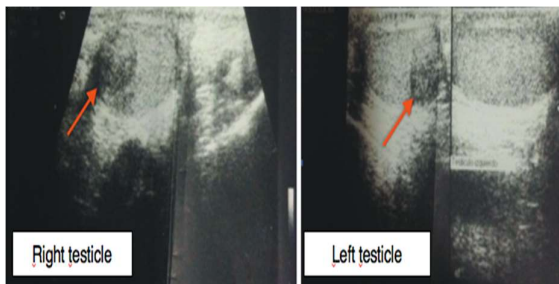


Fig. 2. Testicular ultrasonography: bilateral intraparenchymatous hypoechoic lesion.

The patient underwent right testicular sparing surgery, finding a nodular intraparenchymatous mass towards the posterior aspect of the

testicle, with direct contact to the rete testis, of approximately 3.5 x 1 cm. There were no alterations in the epididymis [Fig. 3A-F]. A complete resection of the mass was accomplished, and it was sent to pathology.

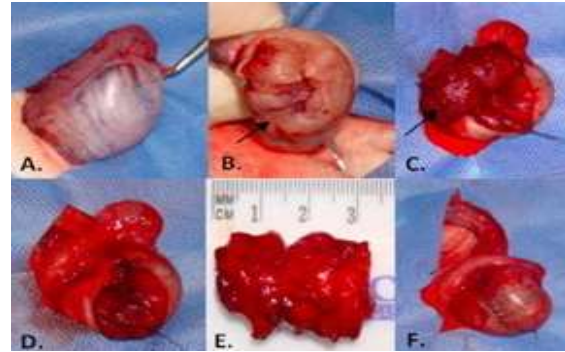


Fig. 3. Right testicular sparing surgery. **A)** Right testicle with usual aspect, with a mass felt in the posterior aspect. **B/C)** Opening of the tunica vaginalis and exposition of the nodular mass. **D)** Complete resection of the mass, no lesions in the testicular vessels. **E)** Surgical specimen. **F)** Closure of the tunica vaginalis, vital testicle.

Histopathological studies reported the mass initially as a LCT, and a new pathology study was requested; immunohistochemistry studies were positive for CD99, Melan A, Inhibin and synaptophysin markers [Fig. 4A-C, 5A,B].

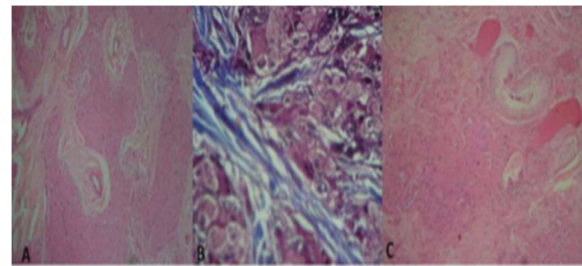


Fig. 4. Hematoxylin and Eosin Staining (H & E): **A)** testicular parenchyma replaced with cords cells with eosinophilic cytoplasm, without Reinke crystals, separated by cord cells. **B)** Trichrome staining enhancing the collagen tracts separating the cord cells. **C)** Testicular parenchyma in contrast with the cords of the Leydig Cells.

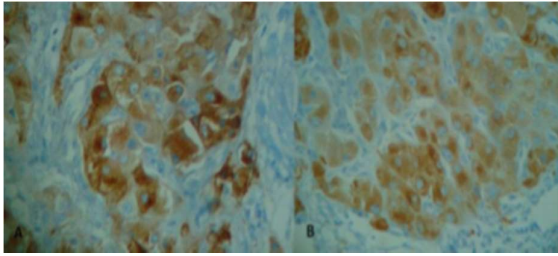


Fig. 5. Immunohistochemistry. **A)** Positive synaptophysin in the cords of the Leydig Cells. **B)** Positive inhibin in the Leydig Cells.

Discussion

During the fifth week of gestation, the adrenal glands develop closely to the gonads, and their separation does not occur until the adrenal glands are prominent. Before this stage, the cortical adrenal tissue can be attached to the gonads. This aberrant adrenal tissue can descend next to the testicles, so ectopic adrenal tissue can be found in the testicles of normal subjects [6] [Fig. 6]. Testicular tumors formed from the remains of adrenal tissue have been observed in cases with elevation of ACTH, as seen in Nelson's syndrome, Cushing's disease and Addison's disease, and in up to 27 to 47% of male patients with CAH [6].

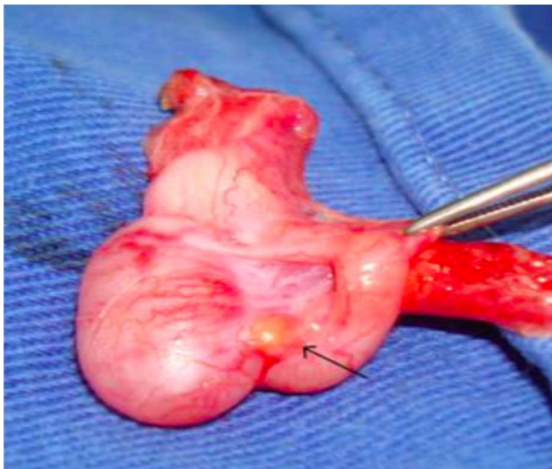


Fig. 5. Paratesticular ectopic adrenal tissue (black arrow).

The adrenogenital syndrome includes a group of recessive autosomal defects in the adrenal

steroidogenesis [7]. The incidence is not known, but has been reported from 8,2 to 94-100% of the patients with CAH [2,8]. It was first described by Lawson Wilkins [5] and identified as testicular adrenal rest tumors resulting from 21-hydroxylase (CYP21A2) deficiency [4].

TARTs are hormone dependent tumors, and their etiology has not yet been confirmed [2,5]. There are few hypotheses now days, and it is believed that their pathogenesis is the result of hyperplastic increase of adrenal rest, that are trapped inside the gonads in the fetal process of the interstitial testicular cells, or cells derived from pluripotent cells of the testicular stroma, that are stimulated by elevated levels of ACTH [2,7,9]. One hypothesis that has been justified by studies shows that testicular tumors formed from adrenal remains produce and express specific adrenal molecules, confirming its great resemblance with this tissue. These remains also have been described in the celiac plexus, the broad ligament and ovaries [4]. Around 27 to 94% of patients with CAH have some form of testicular lesions. In men with CAH, adrenal remains can produce infertility in up to 30% of the patients [4], and oligospermia and azospermia has been seen in more than 40% of patients [2]. One recent study determined that TARTs have multiple steroidogenic properties, including not only the expression of adrenal cortex, but Leydig cell markers as well; they concluded that these tumors might have a more totipotent embryonic cell type [9].

Traditionally, standard treatment of unrecognized tumors of adrenogenital syndrome, steroid resistant tumors and misdiagnosed LCT is orchiectomy. Recently, other studies have demonstrated the viability of testicular sparing surgery as an alternative to the traditional orchiectomy in benign testicular

tumors, as the most important consideration in these patients is fertility [2,7]. Our patient was provided with the alternative of a conservative treatment approach, with testicular sparing surgery, that allowed the resection of the described lesion with free tumor resection margins, and the conservation of the testicular function. A surgical specimen appropriate for immune histopathological studies was achieved, so that we could pin down our diagnosis and adjust the treatment schemes.

These tumors present as a diagnosis problem and have to be differentiated from other tumors that might be found in the testicles, especially LCT [5,6], such as in the case presented in this article. LCT are neoplastic lesions that show transformation of the specialized testicular stroma (Leydig Cells), and count for 1-3% of all testicular tumors; 3% are bilateral and up to 10% show malignancy and can affect any group of age [4]. This is why it is so important to use all the available diagnostic options, so that an adequate evaluation of the surgical pathology is made [4].

TTAGS are bilateral in approximately 83% of cases, they are a benign sequel from an endocrine disease, and appear especially in younger patients [6], between 20 to 40 years old [2,6]. In macroscopic exams TTAGS are big multiple masses with "dark green" nodules, unlike LCT which are small, solid and yellow masses [1,2]. A study of TTAGS by Ashely and co [1], has provided useful microscopic characteristics. In this study, H & E staining revealed extensive fibrosis with adipose metaplasia in 56 to 78% of the cases of TTAGS, unlike LCT, were 0% showed these characteristics. The presence of lymphoid aggregates (67% and 8%), nuclear pleomorphism of 3+ or 4+ grade (56% and 8%) and prominent lipochrome pigment (67% and 15%), were useful characteristics, seen

predominantly in TTAGS. In contrast, there was a complete absence of mitotic figures in TTAGS, while in LCT they are found in 69% of the cases. Reinke's crystalloids are present in only 40% of LCT; therefore, their absence does not exclude LCT. In immunohistochemistry stains, reactivity with synaptophysin was observed in 88% of TTAGS, while in just 8% of LCT. In contrast, inhibin and cytokeratins are equally positive. Needle guided biopsy on its own is not the ideal technique to differentiate TTAGS from LCT [4].

The suppression of the elevated ACTH with glucocorticoid replacement treatment decreases the systemic adrenal hyperplasia and causes a fast regression of the adrenal tumor size in 75% of cases [4,7]. Bricaire and Luton reported in 1966 one case of negative response the glucocorticoid therapy, suggesting that the steroid dose required to cause a regression of the tumor, was considerably greater than the necessary to correct the biochemical levels of 17-cetosteroids [7]. As we exposed with our patient, who had adequate levels of hormonal control, a regression of the tumors was not feasible despite an increase in the treatment dose. It has been postulated that the persistence of the tumor despite glucocorticoid treatment, suggest that the excess of ACTH it is not the only cause of their presence [6]. Nevertheless, benefits from the medical treatment have been described in case reports with different results, depending in the patient selection, the type of CAH and the treatment election [3]. On the other hand, a study demonstrated that to preserve the testicles, surgery has not shown any benefits over the gonadal function in patients with long evolution of bilateral adrenogenital syndrome. This can be explained because of the irreversible damage of the residual testicular tissue, for example as a

result of the chronic obstruction of the seminiferous tubules [2,3]. This leaves the conservative management with steroid replacement as an excellent treatment option.

Conclusions

TTAGS are a different entity from usual testicular tumors, they can be easily misdiagnosed as LCT, but an adequate patient history, a detailed hormonal evaluation, and in selected cases histopathology studies that include specific stain and markers, can confirm the diagnosis, and lead to a proper conservative treatment, preventing the associated gonadal dysfunction.

Compliance with ethical statements

Conflicts of Interest: None.

Financial disclosure: None.

Consent: All photos were taken with parental consent.

References

- [1]Ashley RA, McGee SM, Isotaolo PA, Kramer SA, Cheville JC. Clinical and Pathological Features Associated With the Testicular Tumor of the Adrenogenital Syndrome. *J Urol*. 2007;177(2):546–49.
- [2]Naouar S, Braiek S, El Kamel R. Testicular tumors of adrenogenital syndrome: From physiopathology to therapy. *Presse Med*. 2017;46 (6 Pt 1):572–78.
- [3]Claahsen-van der Grinten HL, Otten BJ, Hermus AR, Sweep FC, Hulsbergen-van de Kaa CA. Testicular adrenal rest tumors in patients with congenital adrenal hyperplasia can cause severe testicular damage. *Fertil Steril*. 2008;89(3):597-601.
- [4]Chaturvedi A, Verma S. Testicular tumours of adrenogenital syndrome. *Diagnostic Histopathol*. 2009;15(8):409–12.
- [5]Ali HH, Samkari A, Arabi H. Testicular adrenal rest “tumor” or Leydig cell tumor. A report of a challenging case with literature review. *Avicenna J Med* 2013;3(1):15–9.
- [6]Bercovici JP, Fiet J, Gibault L, et al. Testicular adrenal rest tumours in salt wasting congenital adrenal hyperplasia (in vivo and in vitro studies). *J Steroid Biochem Mol Biol*. 2005;93(1):67–72.
- [7]Rich M, Keating M, Levin H, Kay R. Tumors of the adrenogenital syndrome: An aggressive conservative approach. *J Urol* 1998;160(5):1838–41.
- [8]Walker BR, Skoog SJ, Winslow BH, Canning DA, Tank ES. Testis sparing surgery for steroid unresponsive testicular tumors of the adrenogenital syndrome. *J Urol*. 1997;157(4):1460-63.
- [9]Smeets EE, Span PN, van Herwaarden AE, et al. Molecular characterization of testicular adrenal rest tumors in congenital adrenal hyperplasia: lesions with both adrenocortical and Leydig cell features. *J Clin Endocrinol Metab*. 2015;100(3):E524-30.

Access this article online

<http://pediatricurologycasereports.com>

Quick Response Code

