

# A Rare Case of Peripheral Odontogenic Keratocyst in the Buccal Space:A case Report

著者	Bhoj Raj ADHIKARI, Durga PAUDEL, Fumiya HARADA, Tetsuro MORIKAWA, Eiji NAKAYAMA, Tsuyoshi SHIMO, Hiroki NAGAYASU, Yoshihiro ABIKO
journal or publication title	北海道医療大学歯学会雑誌
volume	38
number	1
page range	29-35
year	2019-06-30
URL	<a href="http://id.nii.ac.jp/1145/00064741/">http://id.nii.ac.jp/1145/00064741/</a>

## 〔CLINICAL REPORT／症例報告〕

A Rare Case of Peripheral Odontogenic Keratocyst in the Buccal Space :  
A Case Report

Bhoj Raj ADHIKARI<sup>1,2</sup>, Durga PAUDEL<sup>1</sup>, Fumiya HARADA<sup>3</sup>, Tetsuro MORIKAWA<sup>1</sup>,  
Eiji NAKAYAMA<sup>4</sup>, Tsuyoshi SHIMO<sup>5</sup>, Hiroki NAGAYASU<sup>3</sup>, Yoshihiro ABIKO<sup>1</sup>

<sup>1</sup>Division of Oral Medicine and Pathology, Department of Human Biology and Pathophysiology,  
School of Dentistry, Health Sciences of University of Hokkaido, 1757 Kanazawa Ishikari-Tobetsu, Hokkaido 061-0293, Japan

<sup>2</sup>Division of Dentistry, Kathmandu University School of Medical Sciences, Dhulikhel, Nepal

<sup>3</sup>Division of Oral and Maxillofacial Surgery, Department of Human Biology and Pathophysiology,  
School of Dentistry, Health Sciences of University of Hokkaido, 1757 Kanazawa Ishikari-Tobetsu, Hokkaido 061-0293, Japan

<sup>4</sup>Division of Oral and Maxillofacial Radiology, Department of Human Biology and Pathophysiology,  
School of Dentistry, Health Sciences University of Hokkaido, 1757 Kanazawa, Ishikari-Tobetsu, Hokkaido, 061-0293, Japan

<sup>5</sup>Division of Reconstructive Surgery for Oral and Maxillofacial Surgery, Department of Human Biology and Pathophysiology,  
School of Dentistry, Health Sciences of University of Hokkaido, 1757 Kanazawa Ishikari-Tobetsu, Hokkaido 061-0293, Japan

**Key words** : cyst, peripheral odontogenic keratocyst, buccal space, palisaded basal layer, parakeratinization, tumor

## Abstract

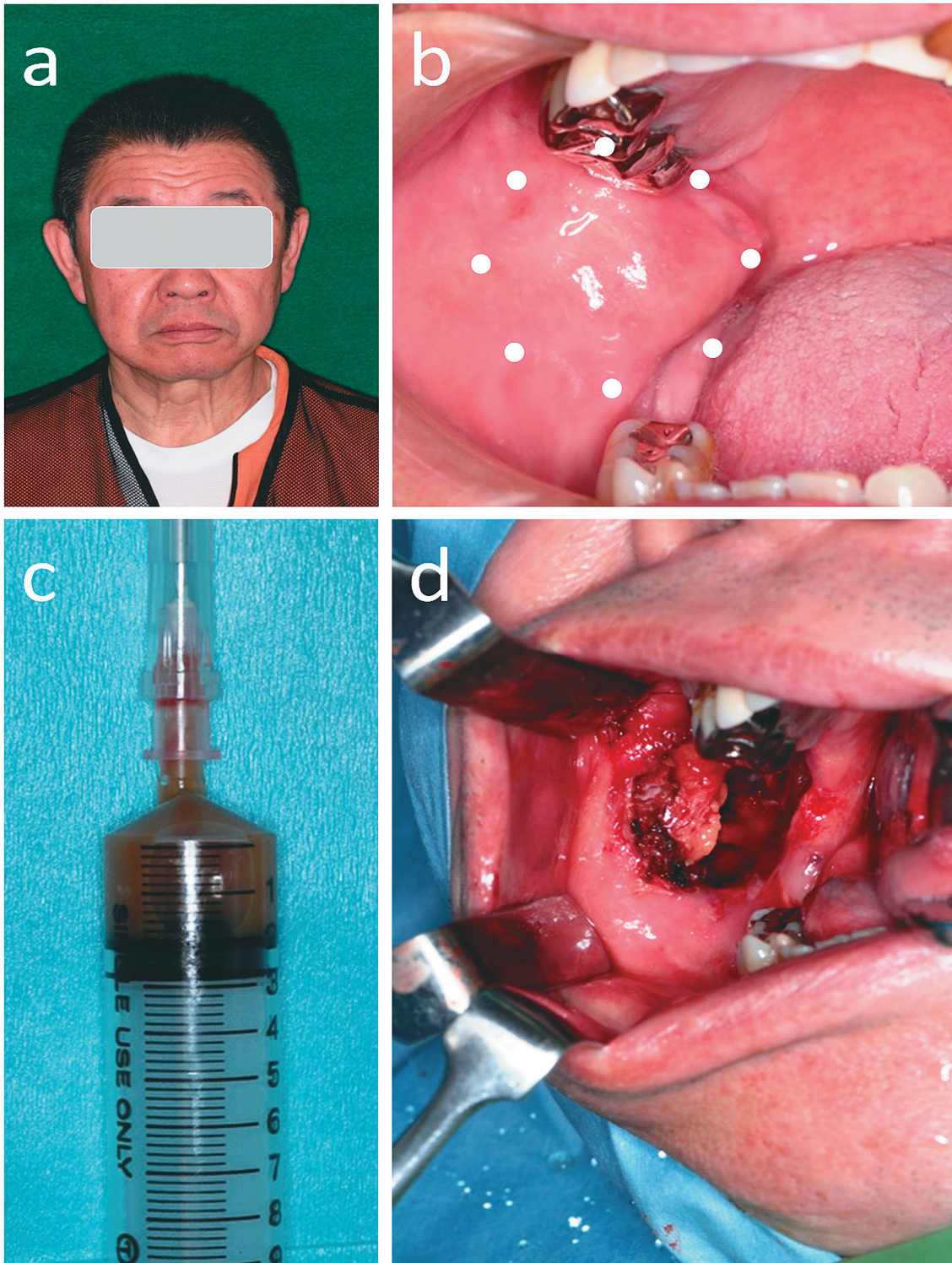
Peripheral odontogenic keratocyst (POKC) is a rare cyst with a histological appearance identical to that of the odontogenic keratocyst, and arises in the soft tissues. Here, we report a case of POKC in the buccal space of a 66-year-old Japanese male. The patient complained of a painless swelling on the right cheek inside the mouth for four years. On examination, a well-circumscribed, mobile soft tissue mass (approximately 25 mm diameter), free from the overlying mucosa or underlying structures was noted adjacent to the right parotid papilla. Computed tomography (CT) and mag-

netic resonance imaging (MRI) revealed a well-circumscribed mass with a homogenous internal structure in the buccal space. Ablation of the mass in the right cheek was performed under general anesthesia. Tissue sections stained with hematoxylin-eosin revealed the presence of a cyst with the lumen lined by parakeratinized stratified squamous epithelium. The parakeratinized layer was strongly stained with cytokeratin (CK 19). The diagnosis and treatment procedures, as based on the literature, are also discussed. This article presents a case of this uncommon entity.

## Introduction

Odontogenic keratocyst (OKC) is a benign odontogenic cystic lesion characterized by a thin, regular lining of parakeratinized stratified squamous epithelium with palisading hyperchromatic basal cells (Neville et al, 2008). The term OKC was first proposed by Philipsen (Philipsen, 1956). It is a locally aggressive lesion with a potential for infiltration and a high rate of recurrence. OKC generally occurs intraosseously, with a high predilection for the mandible. In contrast, peripheral odontogenic keratocyst (POKC) is a rare cyst arising in the soft tissue with a histological appearance identical to that of the OKC (Abe, et al., 2014). Dayan and

colleague reported on this unusual presentation and suggested the diagnostic term of POKC (Dayan, et al., 1988). OKC used to be categorized as a tumor, as it has the potential for infiltration, local aggressiveness, and high rate of recurrence, in addition to the genetic features supporting it to be malignant (Barnes, et al., 2005 ; Vazquez-Romero, et al., 2017). However, a lower rate of recurrence, a characteristic usually not associated with neoplasia, has been documented following marsupialization of the POKC (Pogrel & Jordan, 2004). The clinical and histopathological data were insufficient to support the putative neoplastic nature of this lesion. Therefore, the originally coined term POKC was retained (Speight & Takata, 2018). The origin of these cysts from

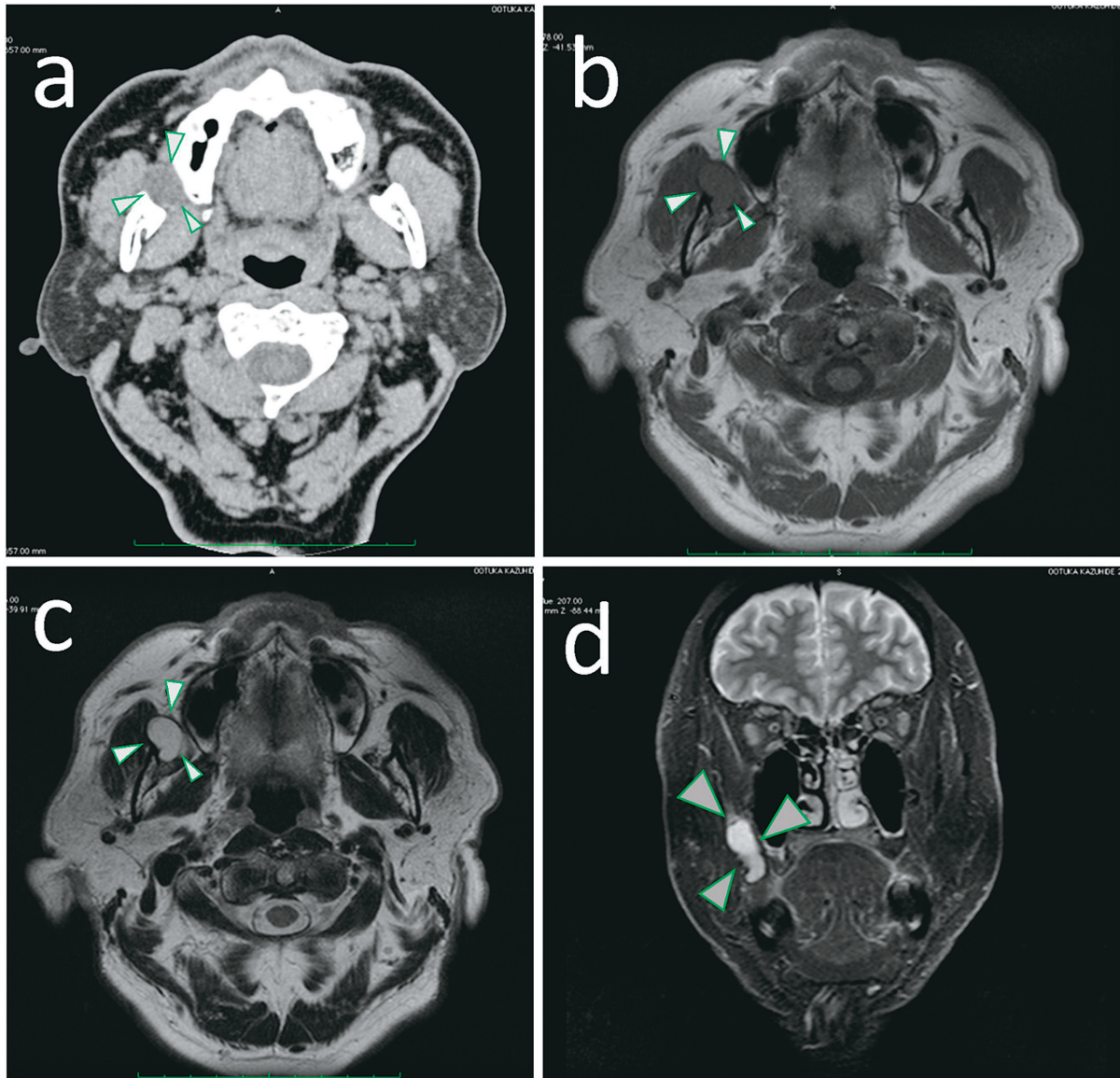


**Fig. 1.** Clinical findings. a) Extraoral findings show bilateral symmetrical face without any visible swelling on right cheek, b) Intraoral finding shows swelling at the right buccal mucosa (dotted area), c) A pus-like grey straw coloured fluid was aspirated from the tumor, d) Intraoperatively, an off-white coloured well-circumscribed mass, located underneath the muscle of right cheek, and adjacent to Stensen duct.

odontogenic epithelium or other tissues has not been confirmed so far. The majority of the POKC have been located on the gingiva. In this paper, we report a case of POKC localized in the buccal space.

### Case Report

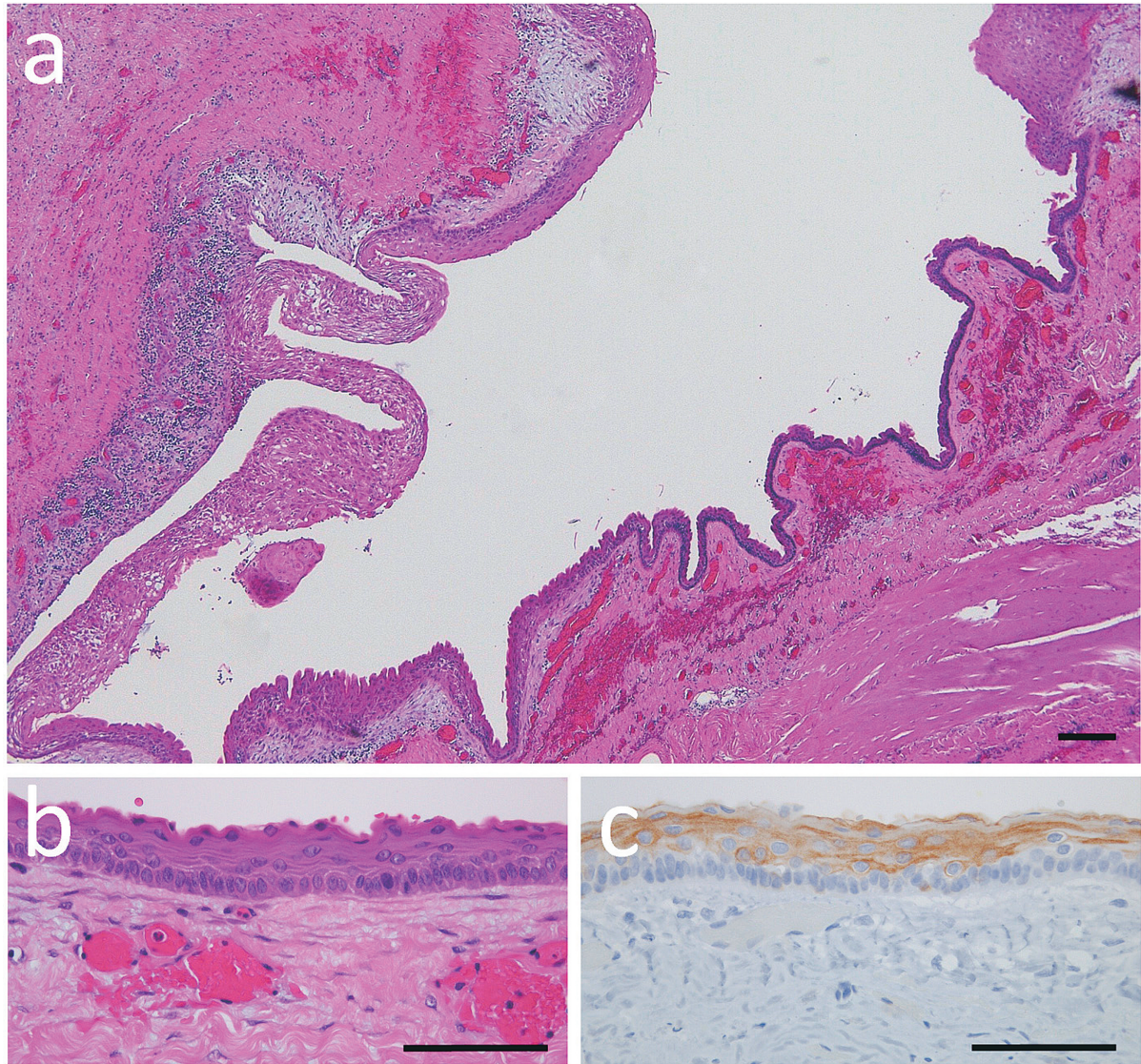
A 66-year-old Japanese male was referred by a general practitioner to the Department of Oral and Maxillofacial Surgery of Health Sciences University of Hokkaido Hospital



**Fig. 2.** Radiographic findings. a) Axial CT, b) Axial MRI (T1), c) Axial MRI (T2), d) MRI (enhanced). A well-circumscribed low density mass is observed in the right buccal space in CT (arrow head). It shows a low signal on T1-weighted MRI and a heterogeneous high signal on T2-weighted MRI (arrow head). Enhanced MRI showed a well-circumscribed mass with homogenous internal structure.

in June 2016. The chief complaint was a swelling in the right cheek, inside the mouth. The swelling had been present for 4 years without any sign of pain or discomfort. His medical history revealed that he had undergone treatment for colon cancer 10 years ago, and was free of any symptoms at the present. On examination, his face was bilaterally symmetrical. No enlarged lymph nodes were noticed in submandibular region and neck. Clinical examination revealed a solid mobile mass, about 23 × 25 mm in size, in the right buccal mucosa adjacent to the parotid papilla, covered by normal oral mucosa. The solid mass was soft, well-circumscribed, mobile, and free from overlying mucosa or underlying structures. No paresthesia or other swellings concomitant

with that of the chief complaint were noted. CT and MRI revealed a cystic mass, 25 mm in size, in the right buccal space. The mass was localized around the region of the posterior maxillary arch and along the lateral wall of the right maxillary sinus. It showed a low signal intensity on T1-weighted MRI and a heterogeneous high signal intensity on T2-weighted MRI. The mass was well-circumscribed and had a homogenous internal structure. Diagnostic imaging revealed no abnormalities in the lymph nodes. The mass was clinically diagnosed as a tumor, and ablation of the mass in the right cheek was performed under general anesthesia. Intraoperatively, an off-white colored mass located underneath the muscles of the right cheek and adjacent to the Stensen's



**Fig. 3.** Histological findings. a) The cyst wall is lined with 4–6 layers of parakeratinized squamous cells arranged in palisaded pattern with a corrugated surface. b) Nuclei of the cells in the basal layer are palisaded. The rete ridge of the epithelium is not evident. c) On immunohistochemistry, the parakeratinized layer was strongly stained with cytokeratin (CK19).

duct, was easily resected from the connected tissue. Discharge of pus-like grey straw-colored fluid was observed from the tumor while separating the superficial tissue. The resected mass was immediately fixed in 10% formalin solution for histopathological examination. The patient is in regular follow-up and currently free of disease.

### Histopathological findings

Tissue sections stained with hematoxylin and eosin revealed a cystic lumen containing keratin flakes, a moderate amount of inflammatory cells, hemosiderin deposits, cholesterol clefts, and giant cells. The lumen of the cyst was lined by a 4–6 cell layer of parakeratinized stratified squamous epithelium. The lining epithelium showed mild surface corrugations and palisading of basal columnar cells forming a

flattened interface with the connective tissue. A uniformly thick connective tissue wall with mild chronic inflammatory cell infiltrate was noted at some locations. Other normal structures like muscle, adipose, and vascular tissue were found over the deeply-seated minor salivary gland tissues. To confirm the histopathological diagnosis of POKC for the present case, we performed immunohistochemistry for its lining epithelium. CK19 was strongly positive in the entire parakeratinized layer of the cystic epithelium. The immunohistochemical profile for the present case was identical to those for OKC.

### Discussion

Here, we present an extremely rare case of a peripheral odontogenic keratocyst in the buccal space. The diagnosis

was based on the specific histological criteria of the tissue sample, including the presence of prominent parakeratinization, a focally corrugated surface, and a well-defined palisading basal layer. POKC arising in the buccal space is extremely rare ; only 5 out of 24 cases (Table 1) have been reported in the buccal space (Abe, et al., 2014 ; Vazquez–Romero, et al., 2017). POKC is reported to occur during the third to seventh decade of life, with a peak incidence in the third decade (Vazquez–Romero, et al., 2017). In the present case, the patient was older than the peak incidence age of the cases previously reported. He had noticed the swelling 4 years prior to visiting the hospital without any signs of pain or aggressive destruction of the adjacent tissue. Previous POKC patients visited 6 months after they noticed the lesion in mouth (Zhu, et al., 2014 ; Buchner, et al., 1979). OKCs often exhibit an aggressive behavior (Zhu, et al., 2014). Thus, POKC should be considered as a differential diagnosis for a swelling in the buccal space.

The differential diagnoses of POKC include gingival cyst, peripheral ameloblastoma, epidermoid cyst, and dermoid cyst (Neville, et al, 2008). The gingival cyst is very common in neonates, but rare in adults (Viveiros, 2019). Unlike POKC, the gingival cyst is located in the gingiva and dis-

plays orthokeratosis (Neville, et al., 2008). POKC may share some clinical features with peripheral ameloblastoma, an odontogenic lesion arising commonly on the buccal mucosa (Isomura, et al., 2009). However, differences in the histopathological features of peripheral ameloblastoma, including neoplastic features, help to differentiate between the two lesions. Although epidermoid cysts are lined by keratinizing epithelium, and the lumen is filled by keratin, they can be differentiated by the presence of sebaceous cells, which are not a common feature in POKC (Neville, et al., 2008). Dermoid cysts in the skin are lined by epidermis that possesses various epidermal appendages, such as sebaceous, eccrine, and apocrine glands that are not present in the POKC (Neville, et al., 2008).

The dislocated and persistent dental lamina during odontogenesis may be the main candidate for the lining epithelium of the cystic components (Ide, et al., 2010). The lesion in the present case was located in the buccal space adjacent to the opening of the parotid duct, a common site of involvement of the dental lamina (Ide, et al., 2010). Other odontogenic lesions such as peripheral ameloblastoma and odontoma that develop in the buccal space were also considered to originate from the dental lamina (Bakry, 1977 ; Isomura,

Table 1 : Summary of the POKC cases reported in English literature

Author	Number of cases	Age (yrs)/gender of patient	Site of lesion	Reference
Stoelinga and colleagues	1	N/A	Maxillary gingiva	Stoelinga, et al.,1975
Buchner and Hansen	2	N/A	Buccal mucosa	Buchner & Hansen,1979
Dayan and colleagues	1	42/M	Left maxillary gingiva	Dayan, et al.,1988
Chehade and colleagues	6	66/F	Left maxillary gingiva	Chehade, et al.,1994
		57/F	Right maxillary gingiva	
		70/M	Left mandibular gingiva	
		37/M	Right mandibular gingiva	
		42/M		
		35/F	Mandibular gingiva	
Fardal and Johannessen	1	41/F	Maxillary and mandibular gingiva	Fardal, et al.,1994
Ide and colleagues	2	38/F	Left maxillary gingiva	Ide, et al.,2002
		46/F	Right maxillary gingiva	
Chi and colleagues	2	81/F	Left maxillary gingiva	Chi, et al.,2005
		64/F		
Preston and Narayana	1	83/F	Left maxillary gingiva	Preston & Narayana,2005
Faustino and colleagues	1	57/F	Left mandibular gingiva	Faustino, et al.,2008
Vij and colleagues	1	56/M	Left maxillary gingiva	Vij, et al.,2011
Grobe and colleagues	1	52/M	Buccal mucosa	Grobe, et al.,2012
Zhu and colleagues	2	44/F	Deep left lateral oral fascia region	Zhu, et al.,2014
		69/M	Deep right lateral oral fascia region	
Sakamoto and colleagues	1	24/F	Mandibular gingiva	Sakamoto, et al.,2014
Abe and colleagues	1	46/M	Left temporalis muscle	Abe, et al.,2014
Vazquez–Romero and colleagues	1	32/M	Left maxillary gingiva	Vazquez–Romero, et al.,2017

N/A : not available ; M : male ; F : female ;

et al., 2009). Based on these findings, it may be reasonable to assume that the lesion in the present case report had originated from the dental lamina.

### Conclusion

Based upon the histological findings, the patient in this case report was identified with POKC in the buccal space, a unique and rare site of occurrence for this disease. Assuming a less destructive clinical course, a conservative surgical treatment was provided and regular follow-up was planned.

### Disclosure of conflict of interest

The authors declare no conflicts of interest associated with this manuscript.

### References

- Abe T, Maruyama S, Yamazaki M, Essa A, Babkair H, Mikami T, Shingaki S, Kobayashi T, Hayashi T & Cheng J. Intramuscular keratocyst as a soft tissue counterpart of keratocystic odontogenic tumor : differential diagnosis by immunohistochemistry. *Human pathology* 45(1) : 110–118, 2014.
- Bakry N. An ectopic odontome in the cheek. *Oral Surg Oral Med Oral Pathol* 43(4) : 583–584, 1977.
- Barnes L, Eveson JW, Reichart P & Sidransky D. Pathology and genetics of head and neck tumours. In : editors. IARC, 2005.
- Buchner A & Hansen LS. The histomorphologic spectrum of the gingival cyst in the adult. *Oral Surg Oral Med Oral Pathol Oral Radiol Endod* 48 : 532–539, 1979.
- Cehade A, Daley TD, Wysocki GP & Miller AS. Peripheral odontogenic keratocyst. *Oral Surg Oral Med Oral Pathol* 77 : 494–497, 1994.
- Chi AC, Owings JR Jr & Muller S. Peripheral odontogenic keratocyst : report of two cases and review of the literature. *Oral Surg Oral Med Oral Pathol Oral Radiol Endod* 99 : 71–78, 2005.
- Dayan D, Buchner A, Gorsky M & Harel–Raviv M. The peripheral odontogenic keratocyst. *Int J Oral Maxillofac Surg* 17(2) : 81–83, 1988.
- Fardal O & Johannessen AC. Rare case of keratin-producing multiple gingival cysts. *Oral Surg Oral Med Oral Pathol* 77 : 498–500 : 1994.
- Faustino SE, Pereira MC, Rossetto AC & Oliveira DT. Recurrent peripheral odontogenic keratocyst : a case report. *Dentomaxillofac Radiol* 37 : 412–414, 2008.
- Grobe A, Hanken H, Blessmann M, Zustin J, Heiland M & Al–Dam A. An odontogenic keratocystic tumor in the buccal space : an unusual site of origin and a review of the literature. *In Vivo* 26 : 847–851, 2012.
- Ide F, Kikuchi K, Miyazaki Y, Mishima K, Saito I & Kusama K. Keratocyst of the buccal mucosa : is it odontogenic? *Oral Surg Oral Med Oral Pathol Oral Radiol Endod* 110(5) : e42–e47, 2010.
- Ide F, Shimoyama T & Horie N. Peripheral odontogenic keratocyst : a report of 2 cases. *J Periodontol* 73 : 1079–1081, 2002.
- Isomura ET, Okura M, Ishimoto S, Yamada C, Ono Y, Kishino M & Kogo M. Case report of extralingival peripheral ameloblastoma in buccal mucosa. *Oral Surg Oral Med Oral Pathol Oral Radiol Endod* 108(4) : 577–579, 2009.
- Neville BW, Damm DD, Allen CM, Bouquot JE. Follicular cysts of the skin. In : Neville BW, Damm DD, Allen CM, Bouquot JE, editors. *Oral and maxillofacial pathology*. 3rd ed. Philadelphia, PA : Saunders ; 2008. p. 32–34.
- Philipsen HP. Om keratocysten (kole steatoma) 1 kaebern. *Tandaegebladet* 60 : 963–981, 1956.
- Pogrel MA & Jordan R. Marsupialization as a definitive treatment for the odontogenic keratocyst. *J Oral Maxfac Surg* 62(6) : 651–655, 2004.
- Preston RD & Narayana N. Peripheral odontogenic keratocyst. *J Periodontol* 76(12) : 2312–2315, 2005.
- Sakamoto K, Morita K, Shimada Y, Omura K, Izumo T & Yamaguchi A. Peripheral odontogenic keratocyst associated with nevoid basal cell carcinoma syndrome : a case report. *Oral Surg Oral Med Oral Pathol Oral Radiol* 118 : e19–23, 2014.
- Speight PM & Takata T. New tumour entities in the 4th edition of the World Health Organization Classification of Head and Neck tumours : odontogenic and maxillofacial bone tumours. *Virchows Arch* 472(3) : 331–339, 2018.
- Stoelinga PJ, Cohen MM Jr & Morgan AF. The origin of keratocysts in the basal cell nevus syndrome. *J Oral Surg* 33 : 659–663, 1975.
- Vazquez–Romero MD, Serrera–Figallo ML, Alberdi–Navarro J, Cabezas–Talavera J, Romero–Ruiz MM, Torres–Lagares D, Aguirre–Urizar JM & Gutierrez–Perez JL. Maxillary peripheral keratocystic odontogenic tumor. A clinical case report. *J Clin Exp Dent* 9(1) : e167–e171,

2017.

Vij H, Vij R, Gupta V & Senqupta S. Odontogenic keratocyst : a peripheral variant. Niger J Clin Pract 14 : 504–507, 2011.

Viveiros SK, Pinho RFC, Custodio M, de Sousa S & Santos Pinto DD, Jr. A rare odontogenic cyst : Gingival cyst of the adult. A series of 20 new cases from a single center. J Craniomaxillofac Surg 47(4) : 647–650, 2019.

Zhu L, Yang J & Zheng JW. Radiological and clinical features of peripheral keratocystic odontogenic tumor. Int J Clin Exp Med 7(1) : 300–306, 2014.



Bhoj Raj Adhikari

1981 : Birth (Jhapa, Nepal)

2007 : Bachelor of Dental Surgery (Graduated : Tribhuvan University, Nepal)

2011~ : Dental Surgeon (Kathmandu University School of Medical Sciences, Nepal)

2015~ : Graduate Student, Division of Oral Medicine and Pathology, School of Dentistry, Health Sciences University of Hokkaido, Japan

2019 : PhD Dentistry (Graduated : Health Sciences University of Hokkaido, Japan)

2019~ : Lecturer (Department of Oral and Maxillofacial Pathology, Division of Dentistry, Kathmandu University School of Medical Sciences, Nepal)