

# <CLINICAL REPORT>Computed Tomography and Ultrasound Study in Craniofacial Fibrous Dysplasia

著者名(英)	Masayuki KANEKO, Hideaki TAKANO, Shuko YONETA, Yoichiro HOSOKAWA, Hirotake KAKEHI
journal or publication title	東日本歯学雑誌
volume	3
number	1
page range	59-67
year	1984-06-30
URL	<a href="http://id.nii.ac.jp/1145/00007094/">http://id.nii.ac.jp/1145/00007094/</a>

[Clinical Report]

## Computed Tomography and Ultrasound Study in Craniofacial Fibrous Dysplasia

Masayuki KANEKO, Hideaki TAKANO, Shuko YONETA,  
Yoichiro HOSOKAWA, and Hirotake KAKEHI

Department of Dental Radiology, School of Dentistry,  
HIGASHI-NIPPON-GAKUEN UNIVERSITY

(Chief : Prof. Hirotake KAKEHI)

### Abstract

In diagnosing craniofacial fibrous dysplasia observed in a 24-year-old woman, computed tomography and ultrasound study were used to define the extent of the bony lesions. Bone scintigraphy with  $^{99m}\text{Tc}$  labeled methylene diphosphonate was also carried out to differentiate the disease to be monostotic or polyostotic.

The sagittal and coronal scan CT images showed a monocystic bony lesion with a mottled appearance in the right mandible, which was growing toward the ramus. The axial scan CT images demonstrated a thickened ramus in the right mandible, an expansible bony lesion in the right maxilla, an increased osseous mass occupying the almost half of the right maxillary sinus, and the almost entirely closed right ethmoidal sinus. Expansible diploë in the right side of the patient's skull was also observed. The ultrasound images with axial scans revealed an expansible lesion in the right mandible and an osseous mass in the right maxilla. The bone scan images showed no abnormalities in the whole body skeleton except for the remarkable uptakes in the craniofacial regions.

**Key Words** : Computed tomography, ultrasound study, bone scintigraphy, craniofacial fibrous dysplasia

### Introduction

Since the introduction of  $^{99m}\text{Tc}$  labeled phosphate complex by Subramanian and McAfee (1971)<sup>1)</sup> bone scintigraphy, in addition to conventional radiography, has been used in the diagnosis of skeletal diseases.<sup>2-7)</sup> Recently, computed tomography (CT) and ultrasound study also have become utilized in dentistry. Both modalities, however, have been used primarily only in diagnosing rare diseases such as malignant tumors. In this report, a case of craniofacial fibrous dysplasia is presented which was examined with computed tomography and ultrasound study to define the extent of the bony lesions. The comparative findings are described between the CT images and ultrasound images. In addition, some discussions are carried out about conventional radiography

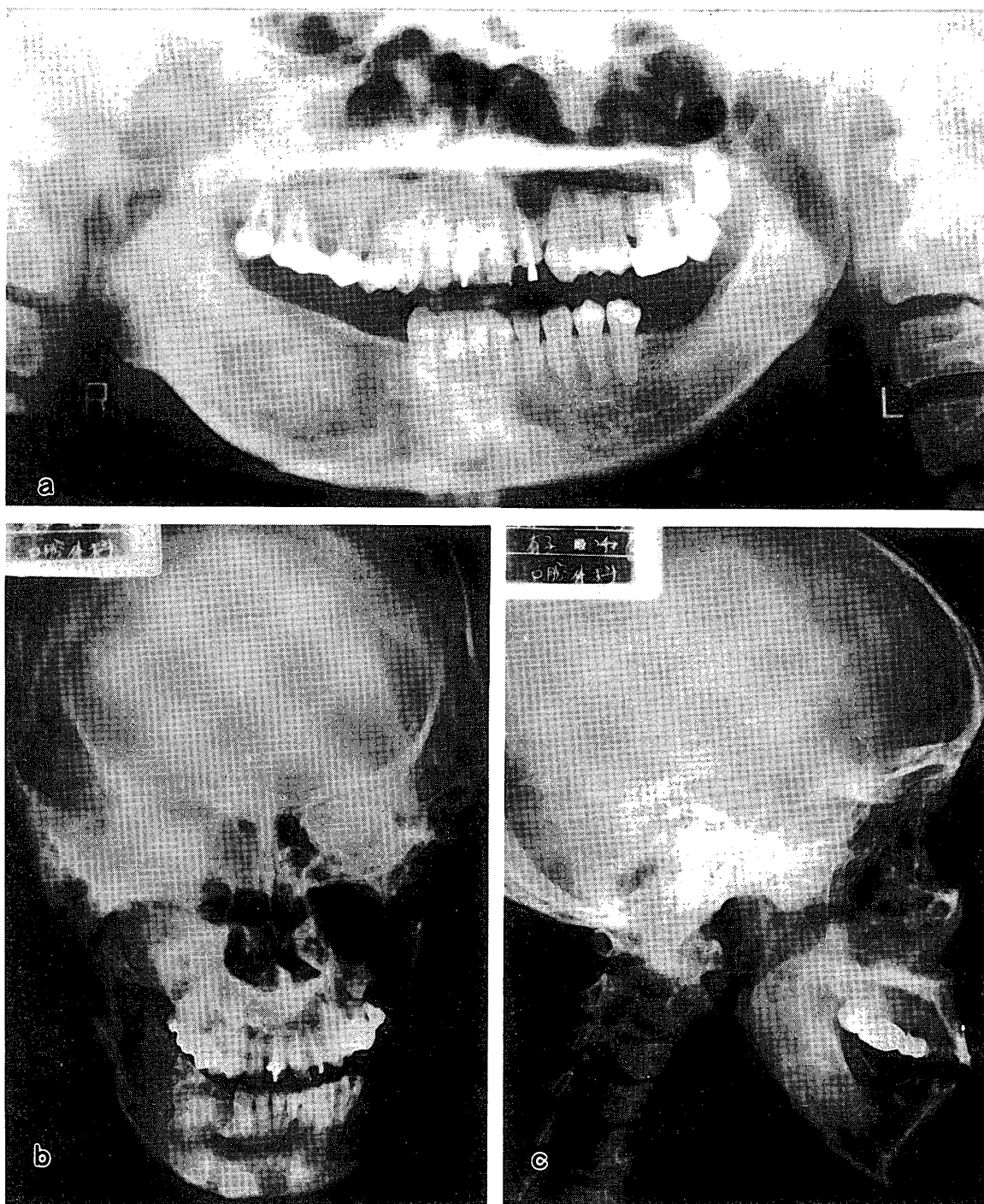
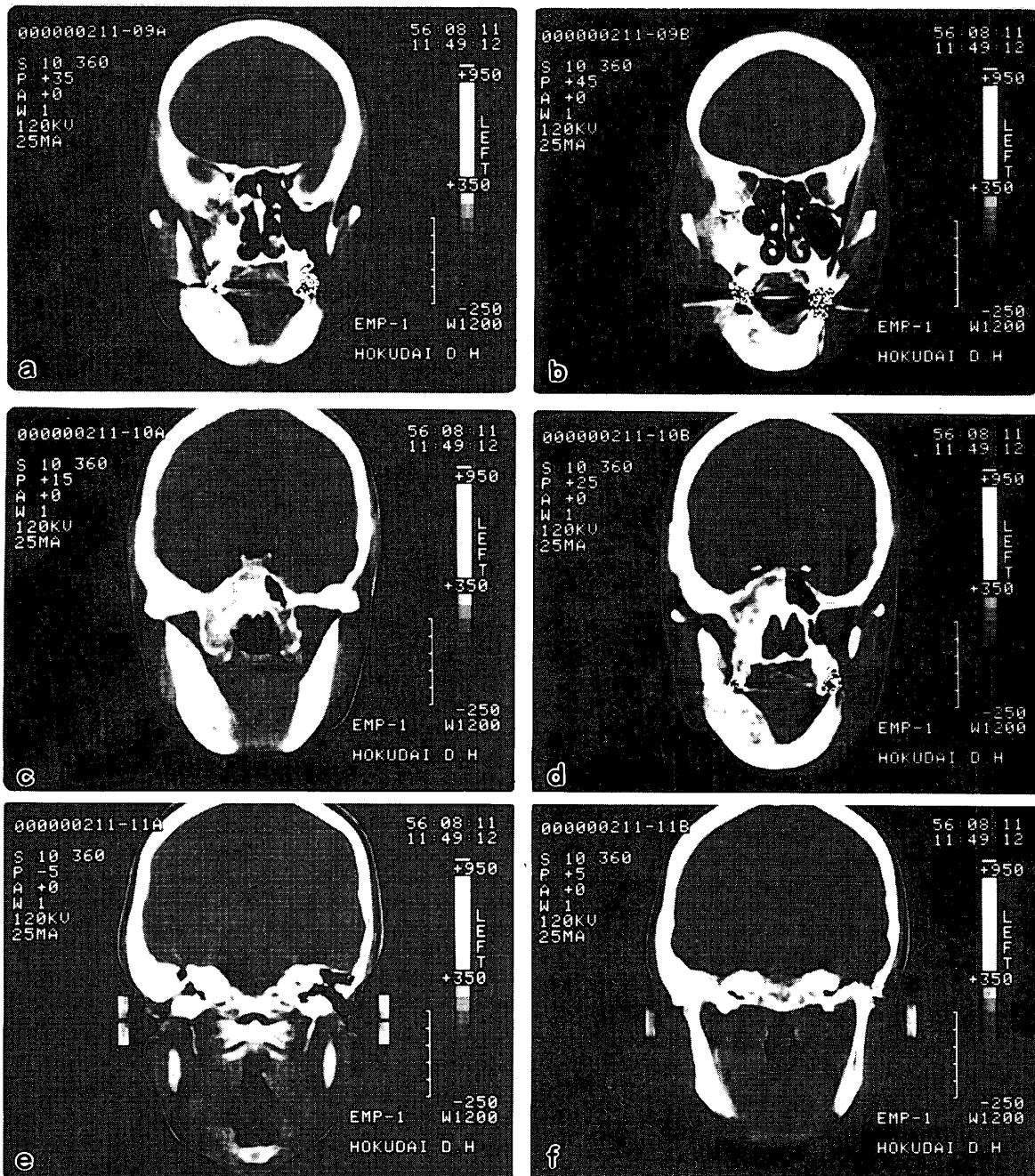


Fig. 1 a) Panoramic dental radiogram shows an expansible bony lesion in the right mandible extending toward the ramus, in which a well defined monocystic lesion is observed. b) Posteroanterior view reveals a remarkably radiopaque region in the right zygomatic arch. Extremely narrowed right maxillary sinus and the almost entirely closed ethmoidal sinus are demonstrated. c) Right lateral view shows an osseous lesion extending into the right maxillary sinus.

and bone scintigraphy which have been used widely in the diagnosis of the skeletal diseases.

#### Case Report

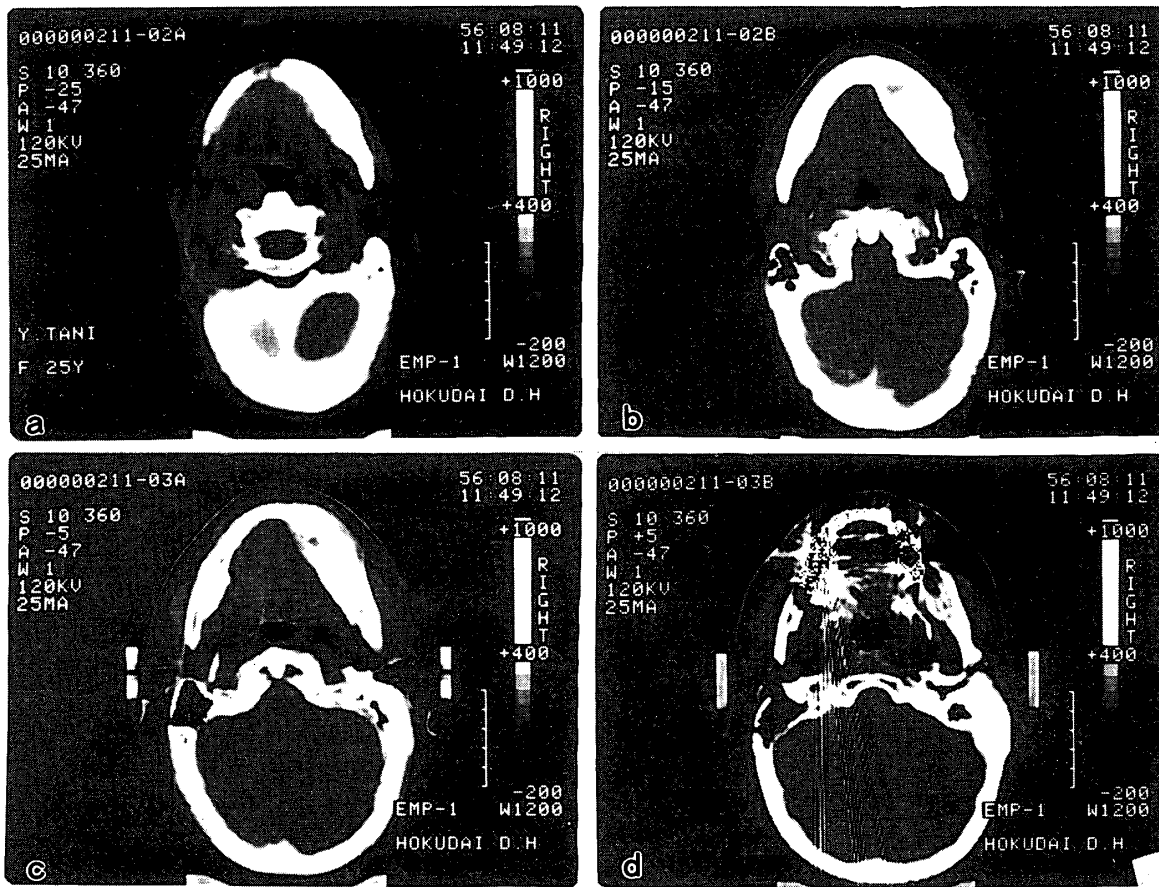
A 24-year-old woman was admitted to the Department of Dental Radiology, Higashi-Nippon-



**Fig. 2** Sagittal scan CT images show the expansible right mandible with a monocystic lesion extending toward the ramus, and the thickened diploë with a mottled appearance in the right side of the skull.

Gakuen University, with the chief complaint of a painless swelling in the right maxilla and a monocystic expansible lesion in the right mandible. Noteworthy events were seen neither in the family history nor in the past history of her own. The patient has noticed these symptoms since 2 years ago. No further growth or other symptoms, however, were noted. A biopsy of the monocystic lesion in the mandible revealed fibrous dysplasia.

In order to confirm the extent of the osseous lesions, computed tomography, ultrasound examination and bone scintigraphy with  $^{99m}\text{Tc}$  labeled methylene diphosphonate were carried out, in addi-



**Fig. 3** Coronal scan CT images show, as well as in Fig. 2, an expansible bony lesion in the right mandible, and the thickened diploë in the right side of the skull.

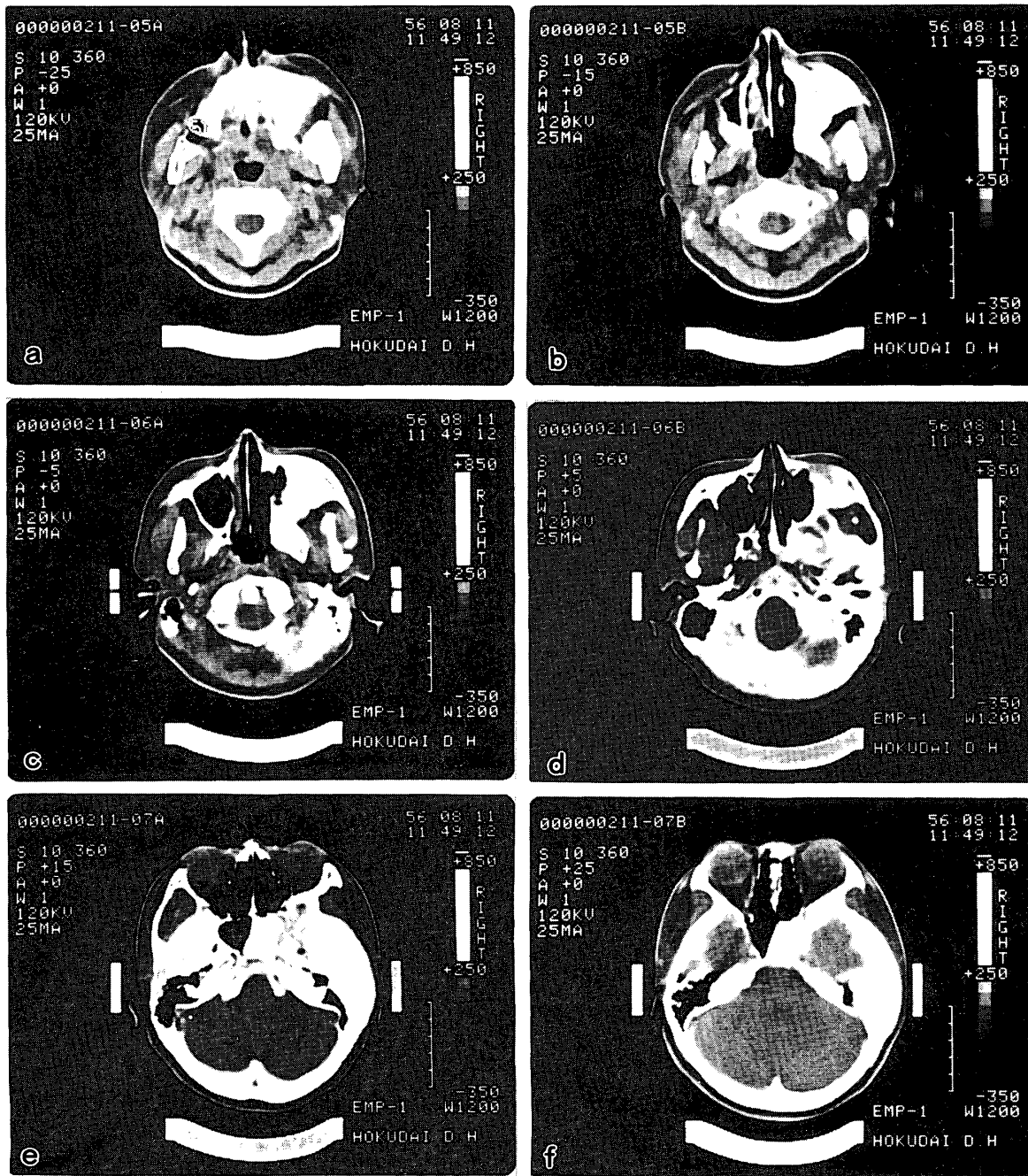
tion to conventional radiography. Computed tomography was performed with the CT-HF (HI-TACHI) cranio-scanner. Ultrasound images were obtained with the ASU-41 (ALOKA).

The whole body skeletal images were taken with a scinticamera using a pararell collimeter. Three hours before scanning,  $7.4 \times 10^8$  Bq (20mCi) of  $^{99m}\text{Tc}$  labeled methylene diphosphonate was administered intravenously.

The panoramic dental radiogram (Fig. 1, a) showed a well defined monocystic lesion with a mottled appearance in the right mandible, a widespread enlargement entirely involving the all of the right mandible, and a remarkably increased radiopaque region with a ground-glass appearance in the right maxilla. The right maxillary sinus of the patient became decreased in volume according to the growth of the bony lesion into the sinus. The nasal cavity also became narrower with the enlargement of the right maxilla.

The posteroanterior view of the skull with conventional radiography (Fig. 1, b) showed a remarkably increased radiopacity in the right zygomatic arch and in the right ethmoidal sinus. The right lateral view (Fig. 1, c) revealed a narrowed maxillary sinus which was occupied with an osseous lesion.

The CT images of the mandible obtained with sagittal and coronal scans (Fig. 2 and Fig. 3) showed a thickened bony lesion growing toward the right ramus, in which a well defined mono-



**Fig. 4** Axial scan CT images show the expansible bony lesions occupying the almost half of the right maxillary sinus and the almost entire right ethmoidal sinus. Enlarged right ramus is also observed.

cystic lesion with a mottled appearance was demonstrated. An expansible osseous lesion occupied the almost all of the right mandible.

One of the axial CT scan images (Fig. 4, c) showed an increased bony lesion which was occupying the almost half of the right maxillary sinus. Another one (Fig. 4, e) demonstrated the almost entirely closed ethmoidal sinus. Remarkably expansible diploë with a mottled appearance was observed in the right side of the patient's skull (Fig. 4, e~f). Enlarged right ramus was also observed (Fig. 4, a~c).

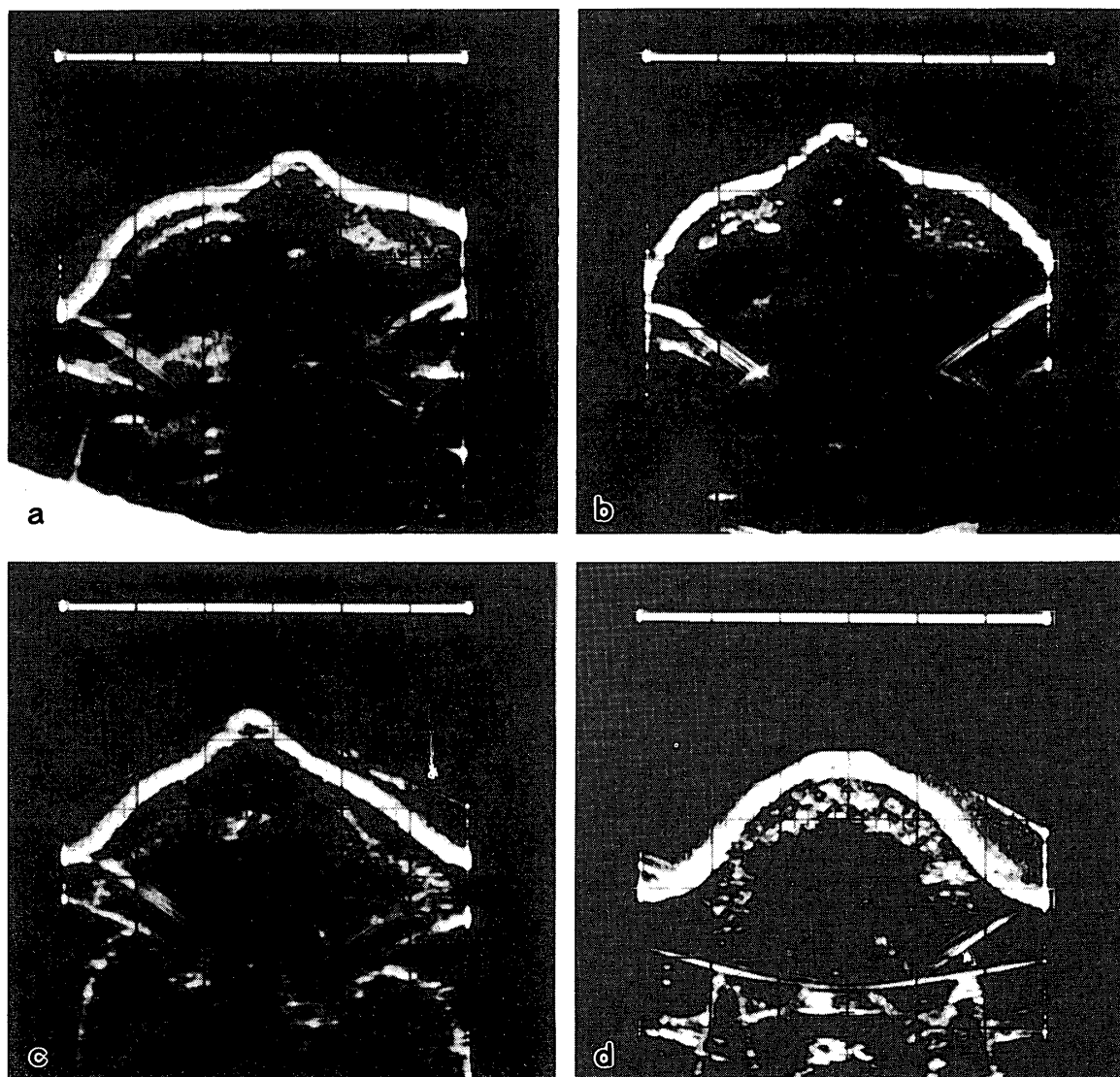


Fig. 5 Ultrasound images reveals an osseous mass in the right maxilla, and an expansible bony lesion in the right mandible.

The ultrasound images with axial scans revealed an expansible lesion in the right mandible (Fig. 5, d) and an osseous mass in the right maxilla (Fig. 5, a~b).

The bone scan images with  $^{99m}\text{Tc}$  labeled methylene diphosphonate (Fig. 6) showed no abnormalities in the whole body skeleton except for the remarkable uptakes only in the craniofacial regions.

#### Discussion

In addition to conventional radiography, computed tomography has been used occasionally in the diagnosis of dental diseases which were observed in the maxillofacial regions. Recently, ultrasound study also has become utilized as one of the newest techniques in dentistry. The utilization ratio of these modalities in the dental examinations, however, has been not higher than that in the medical surveys. That is unavoidable because of the reason that the dental examination and diagnosis with these modalities are limited only at a small area of the maxillofacial regions. The

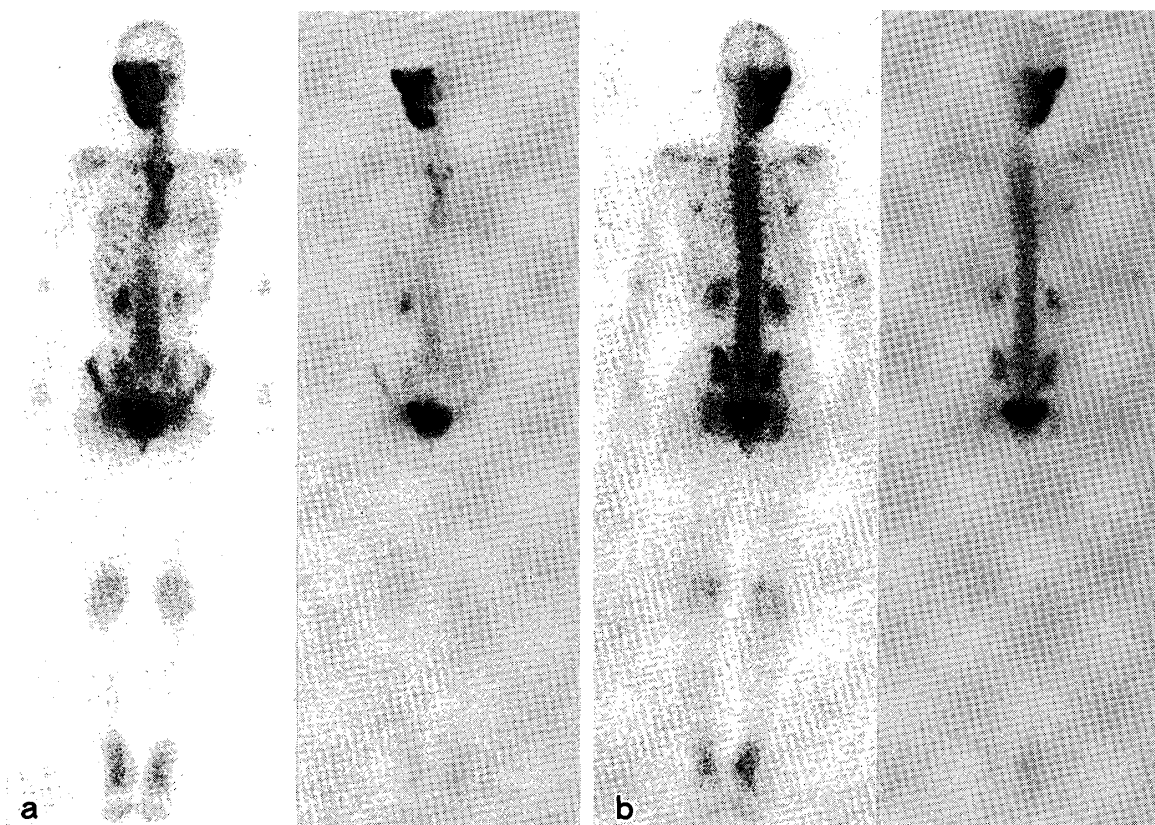


Fig. 6 Bone scan images demonstrate no abnormalities except for the remarkable uptakes in the craniofacial regions. (a : Anterior, b : Posterior)

available reports in the literature have been only a few, and they have been concerned primarily with rare diseases such as malignant tumors.

As to fibro-osseous lesions, Higashi and his colleagues (1980)<sup>8)</sup> reported a case of polystotic fibrous dysplasia diagnosed with computed tomography and bone scintigraphy. They described that the CT images were extremely useful in defining the extent of fibrous dysplasia in the craniofacial regions.

In our case, too, the enlarged mandible with a mottled appearance was clearly defined as shown in Fig. 2 and Fig. 3. The almost half of the maxillary sinus and the almost entire region of the ethmoidal sinus in the right side were occupied with the extremely radiopaque osseous lesions as shown in Fig. 2 and Fig. 4. The diploë of the skull was remarkably enlarged in the right side as shown in Fig. 2, Fig. 3 and Fig. 4. These findings obtained with computed tomography were highly helpful in defining the osseous lesions which were observed in the maxillofacial skeletal regions.

On the other hand, one of the ultrasound images with axial scans demonstrated the outline of the osseous lesion which was existed in the right maxilla as shown in Fig. 5, a. Another one showed an expansible bony lesion in the right mandible as shown in Fig. 5, d. These two images, however, could not define the extent of the bony lesions so clearly. Only the existence of the bony lesions could be revealed. These findings with ultrasound examination were not so effective to diagnose the details of the osseous lesions, compared to those obtained with computed tomography.



Although the bone images taken in the maxillofacial regions with  $^{99m}\text{Tc}$  labeled methylene diphosphonate were not shown in this report, they were highly useful in differentiating the bony disease to be monostotic or polyostotic. In our case, the whole body bone images showed no abnormalities in the whole body skeleton except for the remarkable uptakes in the craniofacial regions as shown in Fig. 6. Therefore, this case could be diagnosed to be craniofacial fibrous dysplasia.

### Summary

A case of craniofacial fibrous dysplasia was presented in which the extent of the bony lesions were defined with computed tomography and ultrasound examination in addition to conventional radiography and bone scintigraphy with  $^{99m}\text{Tc}$  labeled methylene diphosphonate. The comparative findings from the CT images and ultrasound images were discussed and compared to those from the conventional radiographic images and bone scan images. These procedures described above were proved to be helpful in the diagnosis of maxillofacial bony lesions.

### References

1. Subramanian, G., and McAfee, J. G.: A new complex of  $^{99m}\text{Tc}$  for skeletal imaging, *Radiology*, 99 ; 192, 1971.
2. Tafe, A., Francis, M. D., and Mende, C.W. : Correlation of neoplasmas with incidence and localization of skeletal metastases : An analysis of 1335 diphosphonate bone scans, *J. Nucl. Med.*, 16 ; 986—989, 1975.
3. Hamamoto, K., Morita, R., Yamamoto, I., Mori, T., and Torizuka, K. : Usefulness of bone scintigraphy with  $^{99m}\text{Tc}$ -phosphorus Compounds in staging of breast cancer, *J. Nucl. Med.*, 16 ; 532—533, 1975.
4. Siemsen, J. K., and Waxman, A. D. : Early diagnosis of hematogenous osteomyelitis, *J. Nucl. Med.*, 15; 533, 1974.
5. Schaffer, D. L., and Pendergrass, H. P. : Comparison of enzyme, clinical, radiographic and radionuclide methods of detecting bone metastases from carcinoma of the prostate, *Radiology*, 121 ; 431—434, 1976.
6. Rosenthal, L., and Kirsh, J. : Observation on radionuclide imaging hypertrophic pulmonary osteoarthropathy, *Radiology*, 120 ; 359—362, 1976.
7. Tow, D. E., Garcia, D. A., Jansons, D., Sullivan, T. M., and Niederman, R. : Bone scan in dental Diseases, *J. Nucl. Med.*, 19 ; 845—847, 1978.
8. Higashi, T., Iguchi, M., Shimura, A., and Kruglik, G.D. : Computed tomography and bone scintigraphy in polyostotic fibrous dysplasia, *Oral Surg.*, 50 ; 580—583, 1980.

## Computed Tomography および Ultrasound Study による Craniofacial fibrous dysplasia の検索

金子 昌幸, 高野 英明, 米田 修子,  
細川洋一郎, 笥 弘毅

東日本学園大学歯学部歯科放射線学講座

(主任: 笥 弘毅 教授)

### 抄 録

24歳の女性に認められた craniofacial fibrous dysplasia の検索に際して, 病変の範囲を確認する目的で, CT 検査と超音波検査を行った。また, 病変が単骨性であるか多骨性であるかを鑑別するために,  $^{99m}\text{Tc}$  標識 methylene diphosphonate による骨シンチグラフィーを実施した。

CT 検査により, 右側下顎骨に存在する嚢胞様病変と右側上顎骨に存在する骨性病変が明かにされた。また, 骨性病変の著しい増大による右側上顎洞と右側篩骨洞の縮小も明らかとなった。

超音波検査では, 病変の細部にわたる観察は不可能であったが, 右側上顎骨における骨性病変の存在と, 右側下顎骨の著しい膨隆を確認することが可能であった。

骨シンチグラフィーでは, 顎顔面領域に強い陽性像を認めるものの, その他の骨格系には何らの異常も認められなかった。従って, 本症例は, polyostotic fibrous dysplasia の1型である craniofacial fibrous dysplasia であるとの鑑別が可能であった。