

2016

# Sensorimotor Neural Plasticity following Hand Transplantation Measured with Magnetoencephalography: A Case Study

Kaitlyn McFarlane  
*Eastern Michigan University*

Susan Bowyer

Anto Bagic

Vijay S. Gorantla

Anna Haridis

*See next page for additional authors*

Follow this and additional works at: <http://commons.emich.edu/honors>

---

## Recommended Citation

McFarlane, Kaitlyn; Bowyer, Susan; Bagic, Anto; Gorantla, Vijay S.; Haridis, Anna; and Lajiness-O'Neill, Renee, "Sensorimotor Neural Plasticity following Hand Transplantation Measured with Magnetoencephalography: A Case Study" (2016). *Senior Honors Theses*. 497. <http://commons.emich.edu/honors/497>

This Open Access Senior Honors Thesis is brought to you for free and open access by the Honors College at DigitalCommons@EMU. It has been accepted for inclusion in Senior Honors Theses by an authorized administrator of DigitalCommons@EMU. For more information, please contact [lib-ir@emich.edu](mailto:lib-ir@emich.edu).

---

# Sensorimotor Neural Plasticity following Hand Transplantation Measured with Magnetoencephalography: A Case Study

## **Abstract**

This is a single case study that investigated brain connectivity (coherence) using Magnetoencephalography (MEG) in a twenty-four-year-old male who underwent hand transplantation of his right hand at 18 months after a traumatic injury. We examined the neuromagnetic fields of the whole brain during resting state. There is little research on brain reorganization and connectivity within the brain following transplantation, specifically, during resting state. Our findings revealed increased coherence within sensory cortices of the Default Mode Network (DMN) during the early phase of recovery while enhanced coherence in motor cortical regions became apparent in the later phase of recovery.

## **Degree Type**

Open Access Senior Honors Thesis

## **Department**

Psychology

## **First Advisor**

Renee Lajiness-O'Neill

## **Second Advisor**

Natalie Dove

## **Keywords**

Neural Plasticity, Hand Transplantation, Regeneration, Magnetoencephalography

## **Author**

Kaitlyn McFarlane, Susan Bowyer, Anto Bagic, Vijay S. Gorantla, Anna Haridis, and Renee Lajiness-O'Neill



### Abstract

This is a single case study that investigated brain connectivity (coherence) using Magnetoencephalography (MEG) in a twenty-four-year-old male who underwent hand transplantation of his right hand at 18 months after a traumatic injury. We examined the neuromagnetic fields of the whole brain during resting state. There is little research on brain reorganization and connectivity within the brain following transplantation, specifically, during resting state. Our findings revealed increased coherence within sensory cortices of the Default Mode Network (DMN) during the early phase of recovery while enhanced coherence in motor cortical regions became apparent in the later phase of recovery.

**Keywords:** *Neural Plasticity, Hand Transplantation, Regeneration, Magnetoencephalography*

## Introduction

The timing and course of axonal recovery following peripheral nerve injury of a limb is well established (Grinsell & Keating, 2014); however, there is still much we do not know about cortical reorganization after transplantation of peripheral limbs. Through the use of Magnetoencephalography (MEG), we were able to study brain connectivity in a 24-year old male who underwent hand transplantation of his right hand. MEG is a non-invasive whole-head imaging method that allows for the measurement of neuromagnetic fields that can provide information about brain connectivity. We examined the neuromagnetic fields of the default mode network (DMN), which includes sensory and motor cortices (fronto-parietal), during resting state as well as during sensory stimulation to the palms bilaterally during a 13-month period post transplantation.

The default mode network is the most commonly studied resting state network (RSN). The network is visible in “spatially coherent, low frequency correlations” (co-activation) between discrete brain regions or systems (Laird, 2009). The DMN includes precuneus (pC) (parietal lobe), posterior and ventral anterior cingulate (PCC and vACC, respectively), medial prefrontal cortex (MPFC), bilateral inferior parietal lobes (both right and left), and bilateral middle temporal cortices including the hippocampus. The DMN activates while an individual is lying passively, and it has been suggested to be important for thinking about others, past and future events, and for self-referential thinking. These regions are also involved in perception, emotion, and action in reciprocal ways. That is, an increase in activation in one area, say the PCC, would result in a decrease in the activation of the MPFC. Attachment A shows the

## Sensorimotor Neural Plasticity following Hand Transplantation

hypothesized pathways between the areas in the DMN along with how purported increases in activity in one region results in a decrease in activity in another.

In summary, we sought to determine how a hand transplant would alter brain connectivity in a large-scale cortical network (i.e. DMN) that included somatosensory regions and regions reciprocally connected to motor cortices as well as regions critical for body awareness and self-referential thinking.

In addition to exploring regional and whole brain differences that occur during reorganization, the rate of regeneration and reorganization is of value in understanding mechanisms for cortical recovery. Reorganization is hypothesized to follow physiological flow, which is bottom-up for sensory pathways and top-down for motor pathways (Navarro et al., 2007). Following injury to peripheral nerves, the main brain regions that are examined are both the motor and somatosensory cortices given: 1) their large surface areas, 2) the amount of knowledge that is known about their function, and 3) the accessibility to that knowledge (Navarro et al., 2007). MEG has revealed that shifts in the somatosensory map can be visualized following hand transplantation within the first weeks after an injury (Wall et al., 2002). Specifically, the region where the nerve segment is lost is replaced to allow the target organ to be reinnervated. This apparently allows the function of the nerves to come back as well (Navarro et al., 2007).

Connectivity or synchronization of neural activity, can be quantified by calculating coherence between cortical sites from MEG imaged brain activations (Elisevich et al., 2011; Moran et al., 2006). We hypothesized that a successful transplantation would reveal potentially plastic changes in the DMN over time. We hypothesized that those changes, as revealed by increased coherence, would first occur in somatosensory regions (parietal) followed by frontal

## Sensorimotor Neural Plasticity following Hand Transplantation

regions. That is, we might expect enhanced coherence (connectivity) in somatosensory regions and regions connected reciprocally to motor regions (suggesting an initial decrease in coherence in “motor/action” regions as noted in Appendix A) to precede coherence in premotor or motor regions over the course of recovery revealed during resting state.

### *Factors Involved in Regeneration*

The degree and timing of peripheral nerve regeneration must also be considered when discussing cortical reorganization following hand transplantation. Lichtman (2003) conducted studies that have shown axonal regeneration being increasingly disordered in more severe nerve injury. This “disorder” occurs because less axons reach the motor target due to increased scarring and less effective axonal regeneration since the injury to the nerve is so severe (Grinsell & Keating, 2014). Grinsell and Keating provide a visualization (Attachment B) of the steps of the regenerative process in peripheral nerves. There is a large amount of degeneration when the myelin covering of the nerve is cut along with the nerve, specifically, Wallerian degeneration. During Wallerian degeneration, macrophages enter the damaged area to remove any debris from the nerve being severed. In pane (c) of Attachment B, the growth cone of the nerve growing toward the basal lamina tube is displayed, which will eventually trigger new growth of the Schwann cells or the protective covering of the nerve. Chen and colleagues (2015) describe Wallerian degeneration as a process by which the distal portion of the injured axons within the peripheral nervous system progressively degenerates. The process of this degeneration is produced by the breakdown of both myelin and the axons. Chen and colleagues also state that, “The intrinsic degeneration of injured axons has been identified as the key event of Wallerian degeneration” (2015).

## Sensorimotor Neural Plasticity following Hand Transplantation

The first signs of degeneration are seen within twenty-four hours after the injury to the nerve. Typically, the signs of regeneration are prolonged for one to two weeks following a proximo-distal progression (Navarro et al., 2007). “In spite of the fact that peripheral axons can regenerate through the injury site towards distal territories, reinnervation of targets does not always lead to adequate recovery of motor and sensory function” (Navarro et al., 2007). There are many factors that can lead to there being poor functional recovery with peripheral nerve injuries. The first factor is that there can be damage to the neuronal cell body, which can affect the axons ability to regenerate. Another factor is that there is poor specificity of reinnervation from the regenerating axons. Poor specificity can result because target organs are reinnervated by nerve fibers that originally had a different function (Navarro et al., 2007). The plasticity of central connections within the cortex could be compensation of functionality for this lack of specificity. Nonetheless, there is typically limited change noted in the regions that underlie fine motor controls or sensory localization. Navarro (2007) has reported that, “Hand peripheral nerve injuries, for example, result in an obvious loss of evoked activity in the corresponding cortical map in response to stimulation of the skin covered by the injured nerve. Shortly thereafter, the same region becomes responsive to inputs originated in other body parts with adjacent cortical representations” (Navarro et al., 2007). Chen et al., (2002) reported that MEG revealed that there are rapid changes in the somatosensory cortex following deafferentation. Deafferentation is when the afferent connections of nerve cells are destroyed. Peripheral nerve deafferentation that affects a large surface area of the sensory cortex could result in long periods of inactivity before any neural plasticity mechanisms begin to occur.

There are a number of additional factors that also impact the degree of peripheral nerve regeneration that occurs. If a peripheral nerve is repaired and undergoes axonal regeneration,



## Sensorimotor Neural Plasticity following Hand Transplantation

cortical remodeling could be totally or partially restored depending on the severity of the injury. After a complete or partial nerve transection, there can be a rather large degree of misdirection of the axonal growth to the repair site even if there is surgical repair. Consequently, regenerating motor and sensory neurons can abruptly reinnervate onto organs that were not the original target organs even though it is a different function and territory. The result of this abrupt reinnervation can be an abnormal pattern of input or output activity that is shown in the cortical maps. The cortical map reveals reorganization of the somatosensory cortex with a new and somewhat distorted map of the skin areas that were originally innervated by the damaged peripheral nerves (Navarro et al., 2007). The neurons that are located in the reorganized cortex that are able to recover tactile responsiveness from the reinnervated skin regions have multiple receptive fields similar to the neurons at the same cortical site (Navarro et al., 2007).

### *Sensory (Input) Regeneration*

Wall et al., (2002) discuss changes at the subcortical sensory levels that accompany cortical reorganization following amputation. Three types of functional changes are purported to occur in the ventral posterolateral (VPL) nucleus of the thalamus following amputation. The first functional change that occurs is that the thalamic nuclei that have lost normal inputs from the limb become more responsive to inputs from the face or subsequent stump from the amputation. This leads to an enlarged thalamic map of those inputs. The next functional change impacts the relationship of the thalamic receptive and projection fields. Wall et al., (2002) reported that “Under normal conditions neurons at a given thalamic site have matched receptive and projections fields; however, after amputation, neurons at sites that are within enlarged stump maps, or that have face receptive fields, sometimes have mismatched projection fields on the missing limb” (Wall et al., 2002). Wall further states that the change in the relationship between

## Sensorimotor Neural Plasticity following Hand Transplantation

cortical and thalamic functioning following amputation is less well understood (2002). Lastly, the amputations can often alter the spontaneous activity and increase the bursting of the thalamic neurons. The enlargements of the maps of the stump in the thalamus and the cortex are consistent with the idea that cortical reorganization emerges in part from the thalamic neurons (Wall et al., 2002). Wall and colleagues provide a depiction (Attachment C) of the peripheral to central nervous system sensory pathway. The sensory neuron ascends up the spinal cord and to the brainstem. From the brainstem, it synapses in the thalamus and eventually terminates in the primary sensory cortex (parietal).

### *Motor (Output) Regeneration*

Injuries to peripheral nerves also block the flow of output of information from the motor cortices to the muscles that are no longer innervated (Navarro et al., 2007). The reorganization that results after the motor nerve is blocked could result in a much larger network being developed. The reorganization could also result from sensory deafferentation that subsequently deactivates the somatosensory cortex followed by disinhibition of motor neurons through cortico-cortical horizontal projections (Navarro et al., 2007). Navarro and colleagues (2007) report that “the cortical reorganization following a limb amputation can be reversed if the severed body part is reimplanted and functional use is encouraged. After early reimplantation of a traumatically amputated hand, Rörich et al., (cited in Navarro et al., 2007), reported that the cortical representation of arm muscles was enlarged and overlapping within the partially deprived cortical hand area, which was unchanged in size and activation threshold (Navarro et al., 2007). Any new peripheral inputs that are combined with any viable motor activity that is provided with a late allograft hand implantation allows for the functional reorganization to be regained. An allograft is the transplantation of cells, tissues, or organs, to a recipient from a

## Sensorimotor Neural Plasticity following Hand Transplantation

genetically non-identical donor. These findings suggest that hand and arm somatosensory and motor regions return to their original cortices and are able to recover with normal capabilities. “Such a case strongly suggests that plastic reorganization induced after severe deafferentation can be reversed even at chronic stages, thus indicating that an already remodeled cortex retains the ability to reorganize its pattern of representations regardless of the time post-injury” (Navarro et al., 2007).

Chen and colleagues (2002) suggest that increased cortical representation of the muscle that is immediately above the amputation site could improve the motor control that would be needed to compensate for the loss of the peripheral limb. Chen et al. further state that “increased somatosensory representation of the stump may improve sensory perception and discrimination. However, these ideas remain speculative and in most situations, the functional significance of reorganization following peripheral lesions remains to be demonstrated” (Chen et al., 2002).

### *Optimal Timing*

Though there is still much that we do not know about hand transplantation, there is an optimal time window when peripheral nerves can regenerate to the best of their capabilities. The accepted window of time for muscle reinnervation to occur is between twelve to eighteen months post injury. This is also the best-reported time frame for optimal functional recovery before substantial motor degeneration occurs (Grinsell & Keating, 2014). Though research is yet to be conducted to substantiate this time frame, Grinsell and Keating also report anecdotal evidence of a successful regeneration twenty-six months after injury and reconstruction suggesting that it may even occur later. The time frame for sensory reinnervation is reportedly longer than the twelve to eighteen months, but is not unlimited. In fact, (Grinsell & Keating, 2014) suggest that incomplete functional recovery may result from a combination of slow axonal regeneration,

## Sensorimotor Neural Plasticity following Hand Transplantation

structural changes in the muscle targets, and an increase in less supportive stromal environment for regeneration.

### *Specific Aim and Hypotheses*

The aim with this single case study was to characterize cortical reorganization using MEG during resting state following a traumatic hand injury and transplantation. Currently, there is very little research regarding reorganization and connectivity after hand transplantation. To our knowledge, there are no investigations examining resting state networks following hand transplantation using MEG. It was hypothesized that there would be downstream and altered activation patterns in the DMN resulting from initial alterations in primary sensory and motor regions following a traumatic transplantation. It was further hypothesized that changes in somatosensory regions (parietal) might precede changes in frontal regions consistent with physiological flow. That is, we might expect enhanced coherence (connectivity) in somatosensory regions to precede coherence in motor regions and those regions reciprocally connected with motor regions over the course of recovery.

### **Methods**

This study is a single subject design with repeated measures.

#### *Participant*

A 24-year old, former Marine underwent an allotransplant of his right hand, which he lost in an accident approximately 18 months prior to the transplantation.

#### *MEG Procedures*

**MEG Data Acquisition.** The participant underwent monthly MEG scanning (11 times over 13 months) using a 306-channel MEG System (Elekta-Neuromag, Helsinki, Finland) that

## Sensorimotor Neural Plasticity following Hand Transplantation

recorded neuromagnetic field responses during rest (5 minutes) with the participant's eyes remaining open throughout the scan. Three EEG channels were also recorded with the 306 MEG channels. The data that was collected was sampled at 1000Hz and from 0.1 to 330 Hz. MEG measures the magnetic field strength associated with intracellular current flow from populations of 50-100K cortical neurons.

MEG Post-processing. Data were band-passed filtered from 3-85 Hz. Cardiac and movement artifacts were removed by an independent components analysis (ICA) if needed.

### *Cortical Connectivity*

Synchronization of neuronal activity during rest was quantified by calculating coherence between brain regions from MEG imaged brain activations (Moran, Bowyer, & Tepley, 2005) utilizing a MEG-coherence source imaging (CSI) technique. A model of the participants' brain surface was used to create a cortical model of 4000 dipoles based on the gray matter from a standard MRI file. The model was then morphed to fit a digitized head shape that was collected at the time of the MEG scan. When calculating coherence, the data was first divided into 80 segments each containing 7.5-s segments of data. Then a second ICA method is employed to identify the burst of neuronal activity during rest. These burst of high amplitude brain activity are imaged into the cortical model using MR-FOCUS, a current distribution imaging method. At the same time a FFT is performed to identify the frequency content of each imaged location. Using the time sequence of imaged activity, coherence between active cortical model sites were calculated for each data segment and then averaged for the completed study. The calculation of cortical coherence levels (0: no coherence to 1:full coherence) allowed us to inspect differences in network connectivity.

### *Data Analysis and Depiction*

We used a region of interest (ROI) tool that is implemented in MEG Tools to identify 54 regions in the brain (27 in each hemisphere). MEG Tools uses a non-linear volumetric transformation of the participant's brain to reconstruct MEG coordinates to be able to access an atlas to identify Brodmann's area identifiers (Lajiness-O'Neill et al., 2014). The top three regions of interest with the highest coherent activity at each time point over the 13-month period were displayed as the primary dependent variables.

To visualize the regions with the highest coherence at each time point, we loaded the coherence solutions into MEG-TOOLS. Using a solution viewer, we were able to navigate and view the top five areas of activation while at rest. To simplify the results, only the top three are reported here.

### **Results**

Visual inspection of the results revealed that the strongest coherent activity (connectivity) over the course of scanning appeared to be predominately between parietal and temporal regions, while increased coherence in the frontal/motor cortices occurred during the latter months supporting the hypothesis. Moreover, during the first six months, enhanced coherence was particularly evident in temporal regions purported to be active while motor/action regions are reciprocally deactivated in the DMN.

In general, increased coherent activity between other cortical regions and the parietal cortex, which includes the primary sensory cortex (Postcentral gyrus) (See Table 1), emerged in the right hemisphere (ipsilateral to this right hand transplant) during the first month of scanning and shifted to the expected, left hemisphere at later dates, possibly consistent with potential "normalization." Enhanced coherence between other cortical regions and temporal cortical

## Sensorimotor Neural Plasticity following Hand Transplantation

regions (i.e. fusiform, parahippocampal) also dominated. Frontal coherent activity emerged slightly later, potentially suggesting a normalization of somatosensory regions that precedes motor regions.

During the first MEG resting state scan (March 14, 2009), the top three areas of the greatest coherent activity were all right lateralized and temporoparietal: right fusiform, right postcentral, and right inferior temporal (See Table 1 for all time periods). At the time of the second scan (May 5, 2009), the most coherent activity was between the bilateral temporal regions: left hippocampus, left fusiform, and right parahippocampal. During time period three (May 28, 2009), the most coherent activity was between right parietal and left temporoparietal regions: right postcentral, left superior parietal, and left parahippocampal. At time point four (July 10, 2009), the highest coherent activity was between bilateral temporal and right frontal regions: right fusiform, right superior frontal, and left hippocampus. This was the first time frontal regions emerged. At time point five (August 14, 2009), the most coherent activity was left lateralized and between left parahippocampal and middle occipital cortices. At time point six (September 15, 2009), the most coherent activity was between bilateral inferior temporal cortices. During time point seven (October 15, 2009), the most coherent activity was between right frontotemporal and left parietal regions: right parahippocampal, right precentral, and left postcentral regions. During time point eight (December 17, 2009), the most coherent activation was between right temporoparietal and left occipital regions: right superior parietal, left lingual, and right superior temporal. At time point nine (January 7, 2010), the most coherent activity was between left postcentral and insular cortices and right fusiform. During time point ten (February 25, 2010), the most coherent activity was between right frontotemporal and left temporal regions: left fusiform, right precentral, and right inferior temporal. At the final time point (March

## Sensorimotor Neural Plasticity following Hand Transplantation

22, 2010), the most coherent activity was between bilateral parietal and left temporal regions: left parahippocampal, right precuneus, and left angular gyrus.

Throughout each the 11 time points for the scans, the top areas for coherence were primarily in the temporal and parietal cortices. There was also activation present in frontal cortices at multiple time points. Minimal activation occurred in the occipital cortices, but that is to be expected due to the participant's eyes staying open throughout the scan. These findings revealed an increase of coherence within sensory cortices of the DMN within the early phases of recovery, while coherence in motor cortical regions became enhanced in the later phases of recovery.

### Discussion

These preliminary results support the feasibility of monitoring brain reorganization by examining a large-scale resting state networks such as the DMN. The results suggest a potential pattern of “normalization” that is even evident in this large-scale network suggesting possible downstream effects. In adults without injury, the precuneus (parietal) and cingulate are primary regions of the DMN and evident in activation during resting state. Secondary regions include other parietal and temporal cortices. While significant connectivity at rest was not evident in parietal and frontal regions early in recovery, greater activation in temporal cortical areas (secondary DMN) was evident. Later in recovery, typical regions of the DMN came back “on line” (e.g. precuneus). As hypothesized, greater connectivity in sensory (parietal) cortical regions of the DMN and temporal regions that would reciprocally deactivate motor regions was evident in the early phase of recovery following hand transplantation while connectivity within motor regions appeared later in recovery.



## Sensorimotor Neural Plasticity following Hand Transplantation

Navarro and colleagues (2007) discuss the physiological flow of somatosensory and motor pathways and the relationship to plastic reorganization. Consistent with this tenant and our results, the MEG results provide very preliminary support for sensory reorganization via parietal and temporal cortices that occurs prior to frontal or motor cortices as is evident in resting state. This study could provide insight into how transplantation affects larger, resting state networks in terms of recovery. The delay of coherence between the “primary DMN regions” could be related to the time frame required for regeneration and reinnervation of target organs or muscles.

Navarro and colleagues (2007) further discuss lasting plastic reorganization of the cortex that occurs through excitatory mechanisms following injury. Navarro and colleagues suggest that a mechanism of plastic change could occur through the removal of inhibition (i.e. decrease in GABAergic inhibition) of excitatory synapses that could contribute to short-term plastic changes in the cortex (2007). In addition, “The consolidation of longer lasting plastic reorganization might require structural processes consisting in the generation of new projections through sprouting of axon collaterals, dendritic elongation and branching and formation of new synaptic connections” (Navarro et al., 2007). This long-term reorganization may be reflected in a trend revealing a shift from the temporal/parietal regions of the DMN during resting state to the more typical regions of activation of the DMN, such as the precuneus, later over the course of the recovery.

Though there is still much to learn about how transplantation of a limb can affect reorganization and plasticity within the cortex, these results reveal how a large scale resting state network such as the DMN may be affected post transplantation. Further single subject or group investigations could provide additional characterization of cortical regions implicated in reorganization and estimated time frame for recovery of other large-scale networks.

References

Chen, P., Piao, X., & Bonaldo, P. (2015). Role of macrophages in Wallerian degeneration and axonal regeneration after peripheral nerve injury. *Acta Neuropathologica Acta Neuropathol*, *130*(5), 605-618. doi:10.1007/s00401-015-1482-4

Chen, R., Cohen, L., & Hallett, M. (2002). Nervous system reorganization following injury. *Neuroscience*, *111*(4), 761-773. doi:10.1016/s0306-4522(02)00025-8

Elisevich K, Shukla N, Moran JE, Smith B, Schultz L, Mason K, Barkley GL, 61. Tepley N, Gumenyuk V, Bowyer SM: An assessment of MEG coherence imaging in the study of temporal lobe epilepsy. *Epilepsia* 2011, 62. 52:1110–1119.

Grinsell, D., & Keating, C. P. (2014). Peripheral Nerve Reconstruction after Injury: A Review of Clinical and Experimental Therapies. *BioMed Research International*, *2014*, 1-13. doi:10.1155/2014/698256

Laird, A. R., Eickhoff, S. B., Li, K., Robin, D. A., Glahn, D. C., & Fox, P. T. (2009). Investigating the Functional Heterogeneity of the Default Mode Network Using Coordinate-Based Meta-Analytic Modeling. *Journal of Neuroscience*, *29*(46), 14496-14505. doi:10.1523/jneurosci.4004-09.2009

Lajiness-O'Neill, R., Richard, A. E., Moran, J. E., Olszewski, A., Pawluk, L., Jacobson, D., . . . Bowyer, S. M. (2014). Neural synchrony examined with 3 magnetoencephalography (MEG) during eye 4 gaze processing in autism spectrum disorders: 5 preliminary findings. *Journal of Neurodevelopmental Disorders*.

## Sensorimotor Neural Plasticity following Hand Transplantation

Moran JE, Bowyer SM, Mason KM, Tepley N, Smith BJ, Barkley GL, Greene D, Morrell M: MEG coherence imaging compared to electrocortical recordings from NeuroPace implants to determine the location of ictal onset in epilepsy patients. *Int Congr Ser New Front Biomagn* 2006, 1300:673-676.

Navarro, X., Vivó, M., & Valero-Cabré, A. (2007). Neural plasticity after peripheral nerve injury and regeneration. *Progress in Neurobiology*, 82(4), 163-201.

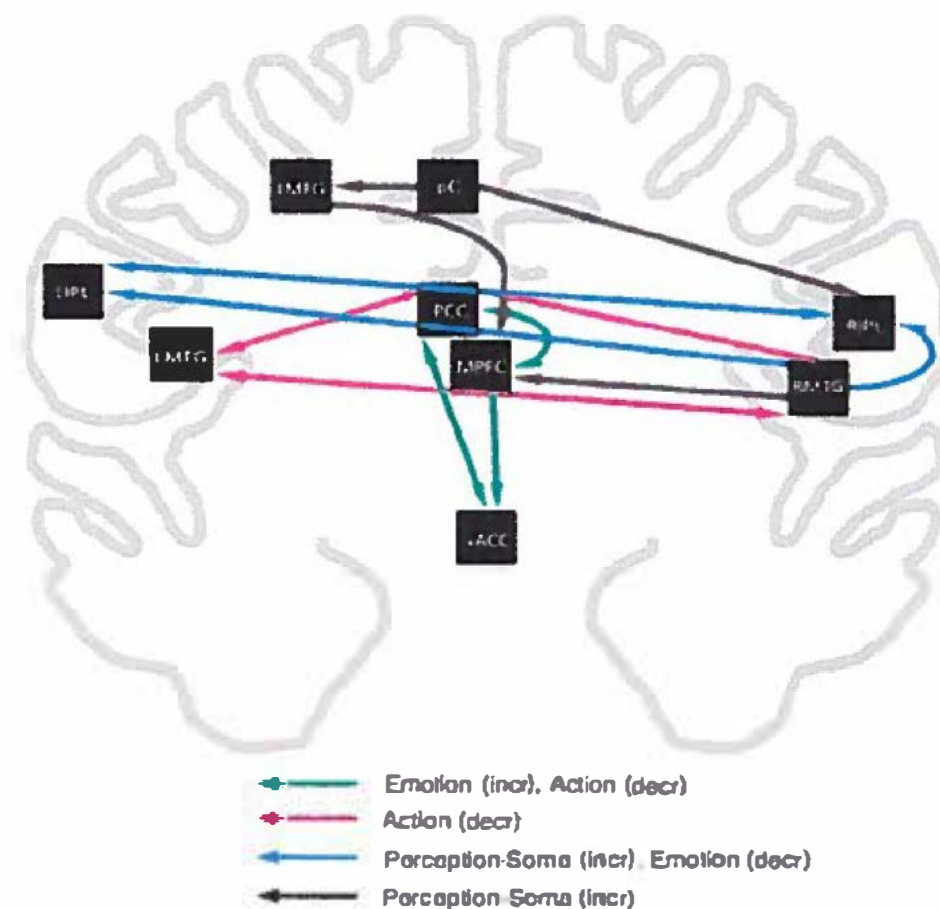
doi:10.1016/j.pneurobio.2007.06.005

Wall, J., Xu, J., & Wang, X. (2002). Human brain plasticity: An emerging view of the multiple substrates and mechanisms that cause cortical changes and related sensory dysfunctions after injuries of sensory inputs from the body. *Brain Research Reviews*, 39(2-3), 181-215.

doi:10.1016/s0165-0173(02)00192-3

Attachments

Attachment A



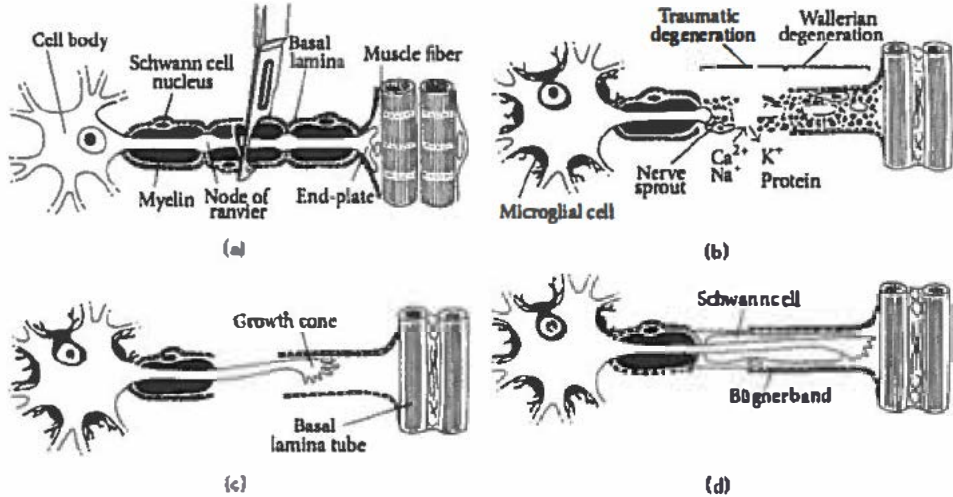
**Meta-Analytic Model of Connectivity Between DMN regions**

(Laird et al., 2009)

Meta-analytic connectivity modeling (MACM) between DMN regions. Each color represents the connections between the regions of the DMN and how a purported increase in activation in regions that underlie emotion, action, or perception reciprocally deactivate a connected brain region. Laird (2009) stated that the directionality of paths indicates that a region of interest (ROI) was observed (ending point) in another ROI's MACM (starting point).

Sensorimotor Neural Plasticity following Hand Transplantation

Attachment B

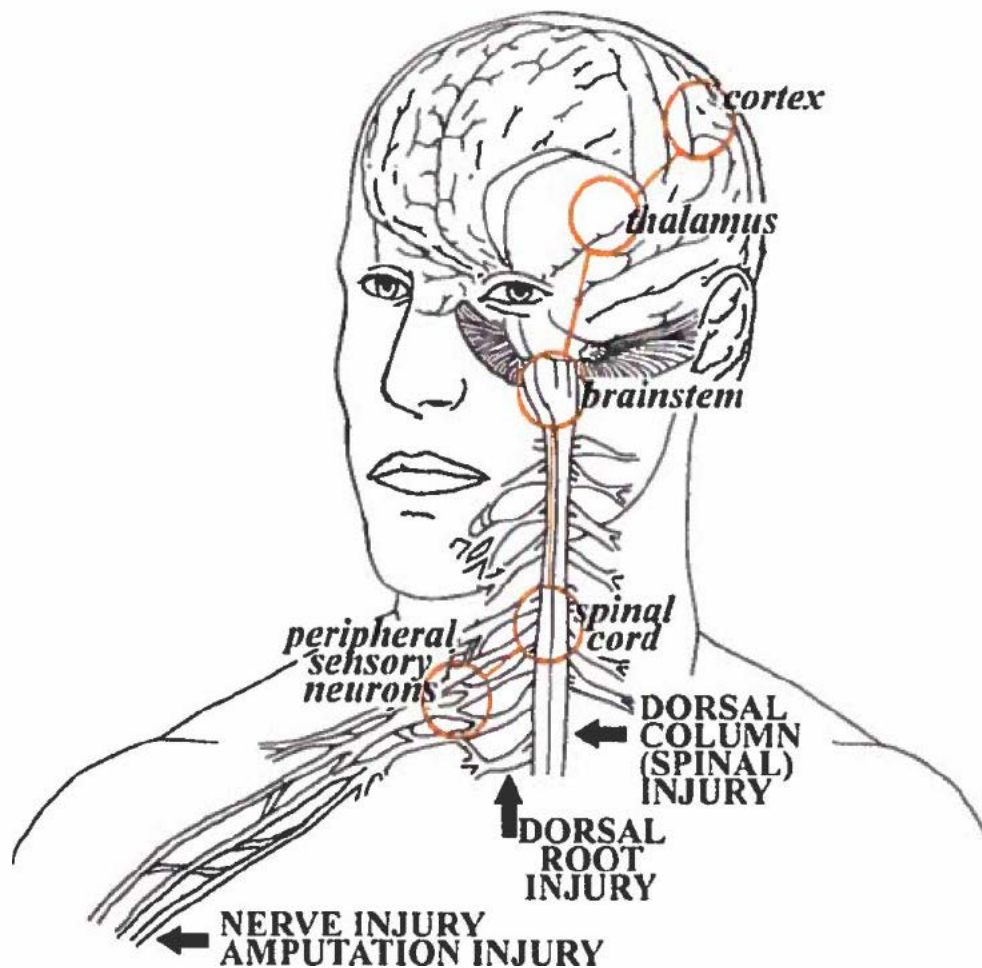


(Grinsell & Keating, 2014)

Representation of the degenerative and regenerative processes a peripheral nerve undergoes after traumatic injury.

## Sensorimotor Neural Plasticity following Hand Transplantation

### Attachment C



(Wall et al., 2002)

Pathway of sensory peripheral and cortical functional reorganization following nerve injuries.

Sensory information must ascend from the site of injury and up the dorsal root/dorsal column of the spinal cord to the brainstem, thalamus, and finally to the somatosensory cortex.

## Sensorimotor Neural Plasticity following Hand Transplantation

Table 1. Top Three Regions of Coherent Activity Over ~ 13 Months Revealed with MEG During Resting State

<u>Time Point</u>	<u>Top Region</u>	<u>Second Region</u>	<u>Third Region</u>
March 14, 2009	R Fusiform	R Postcentral	R Inferior Temporal
May 5, 2009	L Hippocampus	L Fusiform	R Parahippocampal
May 28, 2009	R Postcentral	L Superior Parietal	L Parahippocampal
July 10, 2009	R Fusiform	R Superior Frontal	L Hippocampus
August 14, 2009	L Parahippocampal	L Parahippocampal	L Middle Occipital
September 15, 2009	R Inferior Temporal	L Inferior Temporal	R Inferior Temporal
October 12, 2009	R Parahippocampal	L Postcentral	R Precentral
December 17, 2009	R Superior Parietal	L Lingual	R Superior Temporal
January 7, 2010	L Postcentral	R Fusiform	L Insular Cortex
February 25, 2010	L Fusiform	R Precentral	R Inferior Temporal
March 22, 2010	L Parahippocampal	R Precuneus	L Angular

*Note.*

Red = Temporal

Green = Parietal

Blue = Occipital

Grey = Frontal