

## Basal Cell Carcinoma of Vermilion Mucosa of Upper Lip: a Rare Case Report

**Reza Yaghoobi<sup>1</sup>, Nastaran Ranjbari<sup>2</sup>, Nader Pazyar<sup>1</sup>, Maryam Foroozan<sup>1</sup>, Amir Feily<sup>3</sup>**

<sup>1</sup> Department of Dermatology, Ahvaz Jundishapur University of Medical Sciences , Ahvaz, Iran.

<sup>2</sup> Department of Pathology, Ahvaz Jundishapur University of Medical Sciences , Ahvaz, Iran.

<sup>3</sup> Skin and Stem Cell research Center, Tehran University of Medical Sciences, Tehran, Iran.

### **Corresponding Author:**

Nader Pazyar, MD. Department of Dermatology, Imam Hospital. Azadegan Street, Ahvaz, Iran. email: dr.pazyar@gmail.com.

### **ABSTRAK**

Meskipun karsinoma sel basal (KSB) merupakan tumor kulit yang umum dijumpai, tetapi kasus-kasus KSB yang berasal dari mukosa merah bibir di bibir atas sangat jarang dilaporkan sebelumnya. Tumor ini pada dasarnya berasal dari struktur jaringan pilar dan keterlibatan bagian merah bibir sangat bertentangan dengan konsep ini sehingga struktur tersebut kekurangan folikel rambut dan kelenjar keringat. Patogenesis terjadinya KSB pada bagian merah bibir yang tepat masih belum jelas, tetapi telah dipostulasikan bahwa neoplasma tersebut berasal dari sel-sel epitel pluripoten di mukosa mulut dan epidermis. Sebaliknya, beberapa penulis memperkirakan bahwa asalnya adalah kelenjar sebacea ektopik. Di sini, kami melaporkan seorang lelaki berusia 34 tahun dengan lesi ulkus asimtomatik pada bagian merah bibir di bibir atas kiri. Diagnosis KSB dipastikan dengan pemeriksaan histopatologik setelah biopsi insisi pada mukosa neoplasma dilakukan. Setelah dilakukan pembedahan lesi bibir tersebut, tidak ditemukan kekambuhan setelah pasien dievaluasi lanjut selama 3 bulan.

**Kata kunci:** karsinoma sel basal, bibir, merah bibir, mukosa.

### **ABSTRACT**

Although basal cell carcinoma (BCC) is a common skin tumor, very rare cases of BCC arising from upper vermilion mucosa of lip have been reported previously. This tumor basically, originates from pillar structures and the involvement of the vermilion lip contrasts this concept so it is devoid of hair follicles and sweat glands. The exact pathogenesis of vermilion lip BCC is not clear but it has been postulated that the neoplasm originates from the pluripotential epithelial cells of the oral mucosa and epidermis. On the other hand, some authors consider their origin from ectopic sebaceous glands. Herein, we report a 34- year-old man with an asymptomatic ulcerated lesion on the upper left lip vermilion mucosa .The diagnosis of BCC was confirmed with histopathological examination after incisional biopsy of the mucosal neoplasm. After surgery of lip lesion, no recurrency was seen after 3 months follow-up the patient.

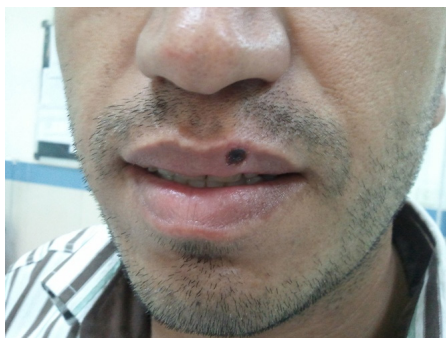**Keywords:** basal cell carcinoma, lip, vermilion, mucosa.

## INTRODUCTION

BCC is the most common human neoplasm. It occurs predominantly in the elderly patients on the sun-exposed skin of the head and neck.<sup>1,2</sup> Labial mucosa is considered an atypical site for BCC.<sup>3</sup> Lip epithelium is divided into 4 regions: the skin; the vermilion border; the outer mucosa (vermilion); and the inner mucosa. In the process of aging the upper lip lengthens, the teeth wear down, and the angle of the jaw opens, resulting in outer mucosa reduction, which is sun exposed.<sup>4</sup> BCC of the vermilion lip is in contrast with the concept of its origin from pillar structures, so it is devoid of pilosebaceous follicles.<sup>3</sup> To the best of our knowledge, there are only 5 documented cases of the BCC of vermilion lip mucosa in international literature. Here, we report an interesting case of BCC developed on the left upper vermilion mucosa which had been treated with conventional therapies as a benign ulcer.

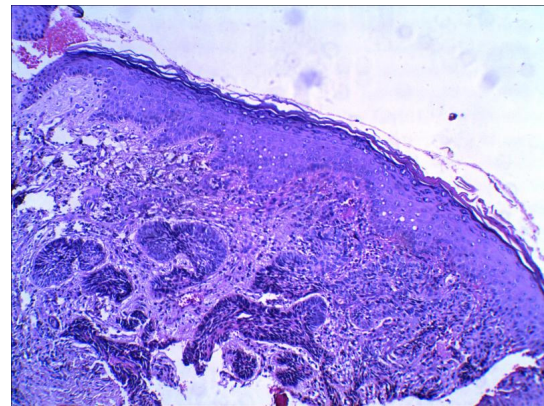
## CASE ILLUSTRATION

The patient is a 34-year-old man, who presented with an asymptomatic ulcerated lesion on the left upper vermilion lip. The patient reported that the ulcer started as a small lesion about 9 months earlier and never healed completely. The lesion had been variously treated with topical and systemic antibiotics. He had no personal history of trauma, smoking, cold sore or sunscreen use. Additionally, no personal or family history of skin neoplasm, immunodeficiency and exposure to tar or ionization detected (**Figure 1**). Clinical examination of the lip lesion revealed a non tender ulcer 6 × 6 mm diameter with hemorrhagic crust on the left vermilion mucosa of the upper lip. There was no cervical lymphadenopathy. The



**Figure 1.** BCC on the upper vermilion mucosa.

patient underwent an incisional biopsy with the clinical diagnosis of squamous cell carcinoma and factitial dermatitis. Histopathological examination revealed the islands of basaloid cells originated from the overlying epidermis and the cells with hyperchromatic nuclei, a few mitotic activity and palisading arrange in nests with clefting artifact between the epithelium and stroma (**Figure 2**). These finding are diagnostic for basal cell carcinoma, solid circumscribed variant with pushing margin. The patient referred to the ENTist and underwent the surgery for the malignancy. There was no recurrence of the tumor after the 3 months follow up.



**Figure 2.** Clusters of basal cells with hyperchromatic nuclei, mitotic figures and palisading arrange in nests (Hematoxylin-eosin x 100).

## DISCUSSION

Studies have revealed that lips are the most common site of cancer in the oral cavity.<sup>5</sup> The incidence of lip cancers is low (1-2%). Approximately 25% of all oral neoplasms are lip carcinomas in which over 90% of these tumors consist of squamous cell carcinomas (SCCs) and, in lesser numbers BCC.<sup>6</sup> Notably, the more rare BCCs are almost always located on the skin of the upper lip and do not usually present lymph node metastases.<sup>6</sup> Some authors have pointed out that BCC of the upper lip has a predilection to occur in females.<sup>7</sup> The risk of carcinoma of the lip is associated mainly with long-term exposure to UV radiation but also with geographic location, race, immune status, and other as-yet-undetermined genetic factors.<sup>8</sup> If the of BCC was entirely sun related, we would

have expected to see the tumor distribution more in favor of lower vermilion lip.<sup>4</sup>

Our report calls the attention for a rare site of BCC since the neoplasm had located on the upper vermilion lip. It has been reported a limited number of BCCs of outer mucosal surface of lip in the literature (**Table 1**). In 1949, study of 620 cases of BCC at all sites indicated that there were 2 cases of BCC on the lower lip mucosa.<sup>10</sup> In 1975, a retrospective review of 652 cases of BCC by Weitzner et al.<sup>11</sup> indicated that there were 3 cases of BCC on the vermilion mucosa. In 1998 Oriba and colleagues reported three cases of BCC of the vermilion zone of the lower lip which lesions were treated by Mohs micrographic surgery.<sup>12</sup>

To date, there is not a satisfactory explanation about the pathogenesis of BCC of the lip mucosal surface. Some authors have suggested that upper lip malignant epithelial tumor could derive from pluripotential epithelial cells of the oral mucosa and epidermis however the other authors consider their origin from ectopic sebaceous glands.<sup>7</sup> The other possibility of origin may be from traumatic epithelial implantation.<sup>4</sup> Classically, lip BCC presented with ulceration or bleeding. Differential diagnosis of the ulceration of the lip including herpes simplex, aphthous ulcer, actinic cheilitis, BCC, SCC, trauma burn, bite, bumps factitial cheilitis, lichen planus and contact dermatitis. Importantly, lip carcinoma should be quickly treated since tumor invasion occurs to deeper tissues early.<sup>4</sup> Common treatments for BCC of the head and neck include methods such as Mohs surgery, surgical excision, cryosurgery, curettage and electrodesiccation. Other less frequently employed treatment modalities include the topical application of

5-fluorouracil (5-FU), laser therapy, radiotherapy, and systemic chemotherapy.<sup>9</sup> Surgical treatment or radiotherapy of lip tumor is planned, as appropriate based on the characteristics of the neoplasm. Accordingly, the surgery of the lip cancer needs to be organized bearing in mind the site and extent of the incision, in order to permit the best possible reconstruction, avoiding scarring that could lead to undesired morphological and functional damage.<sup>6</sup>

## CONCLUSION

We report this rare case to draw attention of our colleagues, encouraging them to have early awareness against all non-healing ulcers on the upper vermilion mucosa to be BCC origin.

## REFERENCES

1. Yaghoobi R , Razi T, Feily A Clinical image: An unusual pigmented basal cell carcinoma arising from vulva. *Acta Dermatovenerol Alp Panonica Adriat.* 2011;20:81-2.
2. Kerkeni N, Jebali A, Zghal M, Debbiche A, Ayed MB, Mokhtar I, Fenniche S. Basal cell carcinoma of unusual site. *Ann Pathol.* 2011;31:32-5.
3. Mlika RB, Kerkeni N, Jebali A, Zghal M, Debbiche A, Ayed MB, Mokhtar I, Fenniche S. Basal cell carcinoma of unusual site. *Ann Pathol.* 2011;31:32-5.
4. Silapunt S, Peterson SR, Goldberg LH, Friedman PM, Alam M. Basal cell carcinoma on the vermilion lip: a study of 18 cases. *J Am Acad Dermatol.* 2004;50:384-7.
5. Gözü A, Ergen A, Dayicioglu D, Yaylim I, Ozsoy Z, Isbir T. L-myc polymorphism in head and neck nonmelanoma skin and lower lip cancers. *Arch Otolaryngol Head Neck Surg.* 2008;134:725-8.
6. Moretti A, Vitullo F, Augurio A, Pacella A, Croce A. Surgical management of lip cancer. *Acta Otorhinolaryngol Ital.* 2011;31:5-10.
7. Luna-Ortiz K, Güemes-Meza A, Villavicencio-Valencia V, Mosqueda-Taylor A. Upper lip malignant

**Table 1.** Cases reports of vermilion lips basal cell carcinoma

Authors	Year	Cases	Age	Sex	Site	Pathology
Welton et al <sup>10</sup>	1949	2	-	man	mucosal surface	-
Weitzner and Heutel <sup>13</sup>	1968	1	74	man	vermillion area	multicentric
Weitzner <sup>11</sup>	1975	1	81	man	vermillion mucosa	heterotpic sebaceous gland
Hume and Turner <sup>14</sup>	1982	1	60	man	mucosal surface	keratinizing BCC
Oriba et al <sup>12</sup>	1998	1	91	woman	vermillion area	solid BCC
		1	69	man	vermillion area	solid BCC
		1	73	woman	vermillion area	miconodular BCC

- neoplasms. A study of 59 cases. *Med Oral Patol Oral Cir Bucal*. 2012;17(3):e371–e376.
8. Ferreira CB, Diniz LM, Souza Filho JB. Multiple basal cell carcinomas in the pubic area in a patient with skin type IV: case report. *An Bras Dermatol*. 2011;86:589-91.
  9. Nakayama M, Tabuchi K, Nakamura Y, Hara A. Basal cell carcinoma of the head and neck. *J Skin Cancer*. 2011;20:496910.
  10. Welton DG, Elliott JA, Kimmelstiel P. Epithelioma: clinical and histologic data on 1025 lesions. *Arch Dermatol*. 1949;60:277-933.
  11. Weitzner S. Basal cell carcinoma of the vermilion mucosa and skin of the lip. *Oral Surg Oral Med Oral Pathol*. 1975;39:634-7.
  12. Oriba HA, Sandermann S, Kircik L, Snow SN. Basal cell carcinoma of the vermilion zone of the lower lip: a report of 3 cases. *Oral Oncol*. 1998;34:309-12.
  13. Weitzner S, Heutel W. Multicentric basal cell carcinoma of vermilion mucosa and skin of lower lip: report of a case. *Oral Surg Oral Med Oral Pathol*. 1968;26:269-72.
  14. HumeWJ, Turner EP. Basal cell carcinoma of lip mucosa. *Br J Oral Surg*. 1982;20:248-55.