

CASE REPORT

Traumatic Inhalation due to Merapi Volcanic Ash

Ika Trisnawati, Eko Budiono, Sumardi, Andang Setiadi

Department of Internal Medicine, Faculty of Medicine, Gadjah Mada University - dr. Sardjito Hospital, Yogyakarta, Indonesia.

Correspondence mail:

Department of Internal Medicine, Faculty of Medicine, Gadjah Mada University - dr. Sardjito Hospital. Jl Kesehatan 1, Sekip, Yogyakarta, Indonesia. email to : ika_interna@yahoo.co.id.

ABSTRAK

Pneumonoultramicroscopicsilicovolcanoconiosis adalah penyakit fibrosis pada parenkim paru setelah inhalasi kronis debu anorganik yang mengandung kristal silikon dioksida. Manifestasi akut terjadi setelah hujan abu berat termasuk serangan asma dan bronkitis, dengan peningkatan sesak dan batuk, dan mengi akibat iritasi pada lapisan saluran nafas. Kondisi kesehatan kronis paling memprihatinkan adalah silikosis, suatu fibrosis nodular difus paru-paru, berkembang perlahan-lahan, biasanya muncul 10 sampai 30 tahun setelah paparan pertama.

Seorang pria 35 tahun dirawat di RUSP Sardjito Yogyakarta dengan keluhan dispnea progresif, nyeri dada sisi kanan sejak 3 bulan terakhir dan episode periodik batuk kering. Dia memiliki riwayat kontak dengan abu vulkanik di lokasi sekitar gunung meletus selama 10 bulan. Pada pemeriksaan fisik didapatkan kondisi hyperresonant di paru kanan bawah, suara vesikuler melemah terdengar di sisi kanan bawah dada. Foto toraks dada menunjukkan adanya bula. Berdasarkan kecurigaan klinis dan radiologis pneumokoniosis, dilakukan CT-scan dada pada pasien dengan hasil beberapa bula bilateral terutama di bagian paru kanan. Spesimen biopsi diambil untuk diangnosa anthrocosilicosis. Tidak ada terapi spesifik yang telah terbukti untuk segala bentuk silikosis. Terapi simptomatik mencakup pengobatan keterbatasan aliran udara dengan bronkodilator, terapi agresif infeksi saluran pernapasan dengan antibiotik, dan penggunaan oksigen tambahan (jika diindikasikan) untuk mencegah komplikasi hipoksemia kronis.

Kata kunci: *Pneumonoultramicroscopicsilicovolcanoconiosis, inhalasi partikel inorganik, sesak napas, bula.*

ABSTRACT

Pneumonoultramicroscopicsilicovolcanoconiosis is fibrotic lung diseases of the pulmonary parenchyma following chronic inhalation of inorganic dusts containing crystalline silicon dioxide. The acute manifestations observed after heavy ashfalls include attacks of asthma and bronchitis, with an increased reporting of cough, breathlessness, chest tightness, and wheezing due to irritation of the lining of the airways. The chronic health condition of most concern is silicosis, a diffuse nodular fibrosis of the lungs, develops slowly, usually appearing 10 to 30 years after first exposure.

A 35 years old male was admitted to Sardjito Hospital, Yogyakarta with complaints of progressive dyspnoea, right side chest pain since last 3 month and periodic episodes of dry cough. He had history of exposure to volcanic ash at the location around volcano eruption for about 10 month. Examination revealed hyperresonant note, diminished vesicular breath sounds in lower right side of the chest. The chest X-ray presence leads to bleb. Based on the clinical and radiological suspicion of pneumoconiosis the patient was submitted to computed tomography of the chest and revealed bilateral multiple bullae mainly at the right lung field. The biopsy specimen verified the diagnosis of anthrocosilicosis. There is no proven specific therapy for any form of

silicosis. Symptomatic therapy should include treatment of airflow limitation with bronchodilators, aggressive management of respiratory tract infection with antibiotics, and use of supplemental oxygen (if indicated) to prevent complications of chronic hypoxemia.

Key words: *Pneumonoultramicroscopicsilicovolcanoconiosis, inorganic particles inhalation, dyspnoea, bullae.*

INTRODUCTION

The Merapi volcano in Central Java began erupting in October 2010 and its activity has continued to date. Volcanic ash has fallen on surrounding area at times throughout the eruption. The ash contains substantial quantities of respirable particles and crystalline silica mineral. We report a patient who presented with bilateral bullae due to pneumonoultramicroscopicsilico-volcanoconiosis which developed within a period of 10 month of silica exposure.

Traumatic inhalation is one of the direct impact of volcanic eruption. Nine percent of the world's population (455 million people) live within 100 km of an historically active volcano.¹ Of all eruptive hazards, ashfall can affect the most people because of the wide areas that can be covered by fallout.² Although eruptions are often short-lived, ashfall deposits can remain in the local environment for years to decades, being remobilized by human activity or simply re-suspended by wind. It is also important to be aware that volcanic ash forms the soils of many parts of the world,³ exposure to which may occur in dust storms⁴ and in agriculture, construction work and quarrying.

Inhalation injury has now become the most frequent cause of death in burn patients. Although mortality from smoke inhalation alone is low (0–11 percent), smoke inhalation in combination with coetaneous burns is fatal in 30 to 90 percent of patients. It has been recently reported that the presence of inhalation injury increases burn mortality by 20 percent and that inhalation injury predisposes to pneumonia. Children and the elderly are especially prone to pneumonia due to a limited physiologic reserve.

Silica (silicon dioxide) is the most abundant mineral on earth. Silica exists in both crystalline and amorphous forms. Amorphous forms, including vitreous silica and diatomite (formed

from skeletons of prehistoric marine organisms), are relatively nontoxic after inhalation. In contrast, inhaled crystalline silica is associated with a spectrum of pulmonary diseases. The toxicity of crystalline silica appears to result from the ability of crystalline silica surfaces to interact with aqueous media, to generate oxygen radicals, and to injure target pulmonary cells such as alveolar macrophages. Resultant generation of inflammatory cytokines by target cells lead to cytokine networking between inflammatory cells and resident pulmonary cells, resulting in inflammation and fibrosis.⁵

CASE ILLUSTRATION

A 35-year old male was admitted to RUSP Sardjito Yogyakarta with complaints of progressive dyspnoea and right side chest pain since last 3 month. He reported periodic episodes of dry cough as well. He had history of exposure to volcanic ash from his job at the location around volcano eruption which is approximately 10 km from the center of the eruption for about 10 month. He is a contraction worker that stay at that area for about ten months before admission to our hospital, the patient had been hospitalized for 10 days caused of shortness of breath, right side chest pain and unconsciousness. During hospitalization the patient received medical therapy and nebulizer. The patient condition was getting better and was allowed to go home. After that the patient never seek to the medical services. He was not a smoker or an alcoholic, and use illicit drugs with no history of haemoptysis, antituberculosis treatment or contact with tuberculosis. Six months later the patient complaint of shortness of breath and worsening chest pain. The family decided to take the patient to the pulmonary clinic of the hospital Dr. Sardjito.

On physical examination, the patient has normal body temperature, pulse rate, respiratory rate and blood pressure. Examination revealed hyperresonant note, diminished vesicular breath sounds in lower right side of the chest. The chest X-ray presence leads to bleb (**Figure 1**). The rest of his physical exam was unremarkable. In a laboratory examination, blood sample analysis showed that the white blood cell count was 14,200/ μl with a normal differential. Based on the clinical and radiological suspicion of pneumoconiosis, the patient was submitted to computed tomography of the chest and revealed bilateral multiple bullae mainly at the right lung field and normal cardiac configuration (**Figure 2**). The biopsy specimen verified the diagnosis of anthracosilicosis. Our final diagnosis was Pneumonoultramicroscopic-silicovolcanoconiosis and we started giving him

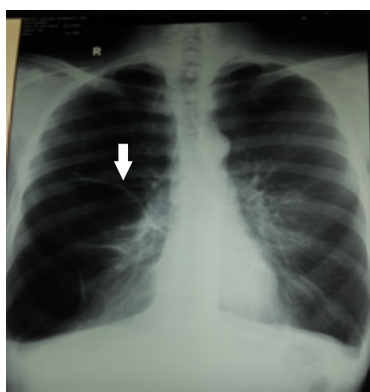


Figure 1. Thorax X-ray showing bleb (interrupted arrows).

bronchodilators, antioxidants and consultation with surgical department.

The patient was managed conservatively for the bullae by working bronchodilator, mucolytic and antioxidant.

DISCUSSION

Pneumonoultramicroscopic-silicovolcanoconiosis is a fibrotic lung disease of the pulmonary parenchyma following chronic inhalation of inorganic dusts containing crystalline silicon dioxide. The pathogenesis is retention of inhaled inorganic particles stimulates fibrosis within the lung interstitium.

With advanced disease, lung compliance will be decreased due to increased elastic recoil, destroys lung tissue, and nodules may become confluent.⁶

Particles are mostly trapped by mucus and eliminated by swallowing or coughing. Particles that penetrate the non-ciliated, alveolar region of the lung (particles in the respirable fraction, $<4 \mu\text{m}$) encounter macrophages which engulf the particles (phagocytosis) in an attempt to clear the lungs, and transport particles to the hilar lymph nodes, where they can be stored (**Figure 4**). However, macrophages can be detrimentally affected either by toxic particles such as crystalline silica.⁷

After phagocytosis, enzymes strip the particle of adsorbed matter, leaving the surface of the particles free to react. Various surface sites

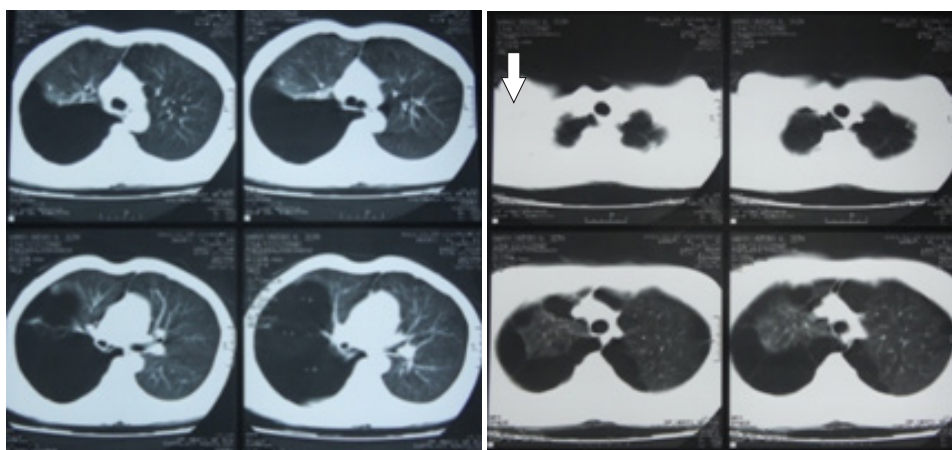


Figure 2. CT- Scan showing bilateral multiple bullae (interrupted arrows)

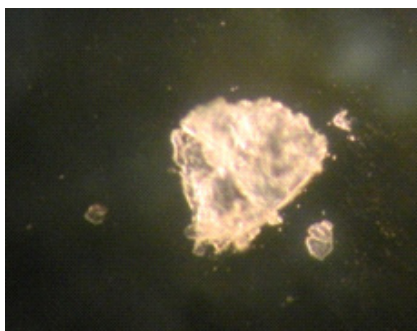


Figure 3. Crystalline forms of silica from lung biopsy

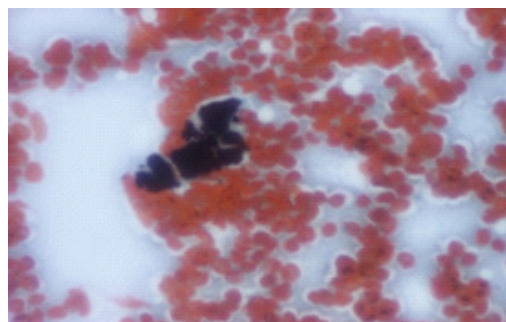


Figure 4. Phagocytosis silica by macrophages

on the particle, including free-radical-generating sites,⁸ may then react with the cell contents, producing an oxidative/respiratory burst where it rapidly synthesises an array of toxic reactive oxygen species (ROS) in an attempt to break down the pathogen. The formation of so many toxic substances may lead to macrophage death. During macrophage death, the particle and corrosive cell contents are released into the lung. The particle is then free to be engulfed again, starting a continuous cycle which may eventually stimulate persistent inflammation and abnormal production of collagen by fibroblasts, forming fibrotic nodules and eventually silicosis.⁸

Dust particles are always present in the air we breathe, and the body has defence mechanisms to enable particles to be removed or to counter their harmful effects. Despite extensive research, the mechanisms through which minerals, including crystalline silica, interact with the lung are not precisely known.⁹

The acute manifestations observed after heavy ashfalls include attacks of asthma and bronchitis, with an increased reporting of cough, breathlessness, chest tightness, and wheezing due to irritation of the lining of the airways by fine particles. Asthma attacks are not confined to known asthma patients, as many people will not have been previously diagnosed. Inhalation of fine ash can also exacerbate previously present disease, e.g. chronic bronchitis.¹⁰ In this case patient experience for acute even that occur 10 days after exposure to volcanic ash with his complaint of dyspneu, chest pain and cough. He admitted to Wirosoaban Yogyakarta Hospital and hospitalized for 10 days.

Accelerated silicosis develops within 10

years of initial exposure. Accelerated silicosis is associated with high-level exposure to silica, and has the same radiographic appearance as chronic silicosis. Accelerated silicosis is differentiated from chronic disease only by its more rapid development following first exposure.¹¹

Physical examination of the chest is usually unremarkable, although a variety of abnormal breath sounds, including fine crackles, coarse crackles (often at end inspiration), rhonchi, and/or wheezes, have been reported to occur in a substantial proportion of affected individuals.¹¹

PMF is associated with more severe symptoms than simple silicosis. The progressive coalescence of silicotic nodules leads to respiratory impairment, including air trapping and emphysema. Physical examination frequently demonstrates decreased or other abnormal breath sounds. Signs of chronic respiratory failure and cor pulmonale may be present. Crackles do not occur as a result of the interstitial changes, but adventitious sounds may be present.¹¹

The chronic health condition of most concern is silicosis, a diffuse nodular fibrosis (scarring) of the lungs. Silicosis would occur, if three main conditions were fulfilled: (1) a high proportion of fine particles in the ash; (2) a high concentration of crystalline silica (quartz, cristobalite or tridymite) and (3) exposure to the ash in significant amounts, typically over a period of years to decades. Early lung changes cause no symptoms and most sufferers remain in this mild category, but the condition can progress even after exposure has ceased and may lead to premature death.⁸

Chronic silicosis develops slowly, usually appearing 10 to 30 years after first exposure. It is not uncommon for silicosis to first become

radiographically apparent many years after cessation of employment in a job associated with exposure. Chronic silicosis usually has the radiographic pattern described below as simple silicosis. In a minority of those with chronic disease, nodules coalesce resulting in Progressive Massive Fibrosis (PMF).¹¹ In this case there is exposure to dust of Mount Merapi for about 8 to 10 months. Although not included in the criteria for chronic exposure, but in the examination has begun to get to the chronic symptoms. The possibility of another analysis in this chronic case occurred because there were high concentrations of crystalline silica exposure.

There is no proven specific therapy for any form of silicosis. Symptomatic therapy should include treatment of airflow limitation with bronchodilators, aggressive management of respiratory tract infection with antibiotics, and use of supplemental oxygen (if indicated) to prevent complications of chronic hypoxemia.¹¹

Glucocorticoid therapy has been used in an attempt to interrupt the inflammation that leads to progressive silicosis. In the largest study to date, a six-month trial of prednisolone was carried out in 34 patients with chronic silicosis.¹² Lung transplantation should be considered for people with endstage silicosis.¹³

Several experimental treatment measures have been proposed for use in patients with silicosis. Whole lung lavage has been attempted as a therapeutic measure, based on its ability to reduce pulmonary dust burden and remove inflammatory cells from the lung.¹⁴ While current data shows the procedure to be safe and technically feasible, its clinical utility is unclear. There is speculation that the continued recirculation of sequestered silica limits the potential benefit of this approach.¹¹

Bullae formation at chest imaging is a rare event in the course of silicosis and is usually unilateral.

It is more commonly seen in chronic silicosis having progressive massive fibrosis. It is quite rare event in acute silicosis. Sporadic cases of spontaneous pneumothorax have been reported in accelerated silicosis.¹⁵

The complication which occur in silicosis include lung infection. The crystalline silica

less than 1 mm is believed to be most deadly pathogen.¹⁶ Aerodynamic considerations appear to favour the entry and retention of particulates in the upper lobes of lungs. Direct tissue injury by silica particles leads to imbalance between products of inflammatory response affecting the elastica of alveolar walls and formation of alveolar blebs in upper lobes or some congenital alveolar defect and dysfunction of type II cells which may finally culminate in the development of bilateral pneumothorax.¹⁷

Nowadays, the diagnosis of silicosis is presumptive and based on combination of typical radiological feature in chest radiograph. CT scan of chest is also helpful in detection of concurrent tubercular infection.¹⁸

The time of presentation and intervention may greatly reduce the morbidity and mortality and help patient lead purposeful and productive lives.

CONCLUSION

Over exposures of silica in short periode of time will become silicosis. It is well recognized that silicosis can cause significant lung function impairment. The diagnosis of silicosis is presumptive and based on combination of typical radiological feature in chest radiograph. CT scan of chest is also helpful in detection of concurrent tubercular infection. Direct tissue injury by silica particles leads to alveolar blebs in the several lobes of this case and sporadic cases of spontaneous pneumothorax have been reported in accelerated silicosis. There is a need to educate inhabitants, workers and employers in the visiting of the eruption to ensure that the health risk is minimized.

REFERENCES

1. Small C, Naumann T. Holocene volcanism and the global distribution of human population. *Environ Hazards*. 2001;3:93–109.
2. Blong R. Volcanic hazards risk assessment. In: Scarpa R, Tilling RI, eds. *Monitoring and mitigation of volcanic hazards*. New York: Springer, Berlin Heidelberg; 1996. p. 675–98.
3. Ping C-L. Volcanic soils. In: Sigurdsson H, ed. *Encyclopedia of volcanoes*. San Diego: Academic Press; 1999. p. 461–82.
4. Hefflin BJ, Jalaludin B, McClure E, Cobb N, Johnson CA, Jecha L, Etzel RA. Surveillance for dust storms

- and respiratory diseases in Washington State. *Arch Env Health*. 1994;49:170-4.
5. Rimal B, Greenberg AK, Rom WN. Basic pathogenetic mechanisms in silicosis: current understanding. *Curr Opin Pulm Med*. 2005;11:169.
 6. Shellito J. Occupational/inhalational/environmental disease. In: J Ali, Warren R, S Michael, eds. 3rd edition. *Pulmonary pathophysiology clinical approach*. New Orleans, Louisiana: McGraw-Hill Companies; 2010. p. 149-54.
 7. Cullen RT, Jones AD, Miller BG, Donaldson K, Davis JMG, Wilson M, Tran CL. Toxicity of volcanic ash from Montserrat. Edinburgh: Institute of Occupational Medicine; 2002. p. 55.
 8. Horwell CJ, Fenoglio I, Ragnarsdottir KV, Sparks RSJ, Fubini B. Surface reactivity of volcanic ash from the eruption of Soufrière Hills volcano, Montserrat, with implications for health hazards. *Environ Res*. 2003; 93:202-15.
 9. Fubini B, Fenoglio I, Elias Z, Poirot O. Variability of biological responses to silicas: effect of origin, crystallinity, and state of surface on generation of reactive oxygen species and morphological transformation of mammalian cells. *J Environ Pathol Toxicol Oncol*. 2001;20:95-108.
 10. Horwell CJ, Baxter P.J. The respiratory health hazards of volcanic ash: a review for volcanic risk mitigation. *Bull Volcanol*. 2006;69:1-24.
 11. Rose C, Talmadge EK, Helen H. Silicosis. Up To Date 19.1. UpToDate Inc. Netherlands. 2011.
 12. Sharma SK, Pande JN, Verma K. Effect of prednisolone treatment in chronic silicosis. *Am Rev Respir Dis*. 1991;143:814.
 13. Burton CM, Milman N, Carlsen J, et al. The Copenhagen National Lung Transplant Group: survival after single lung, double lung, and heart-lung transplantation. *J Heart Lung Transplant*. 2005; 24:1834.
 14. Wilt JL, Banks DE, Weissman DN, et al. Reduction of lung dust burden in pneumoconiosis by whole-lung lavage. *J Occup Environ Med*. 1996;38:619.
 15. Natarajan AS, Gajalakshmi L, Karunakaran S. Accelerated silicosis in a silica flour mill worker. *Lung India*. 1992;10:33-7.
 16. Zaidi SH. Experimental pneumoconioses. *Am Rev Respir Dis*. 1992;145:630-1.
 17. Arora VK, Seetharaman ML, Veliath AJ. Silicotic alveolar proteinosis with bilateral spontaneous pneumothorax. *J Assoc Physicians India*. 1992;40: 760-2.
 18. Gupta KB, Manchada M, Kour P. Bilateral spontaneous pneumothorax, *J Assoc Physicians Indian J Chest Dis Allied Sci*. 2006;48:201-3.